

Case 12910

Carpal coalition: 4 cases of a rare bony coalition between the capitate and trapezoid bone, with MRI findings in a symptomatic case.

M. Mespreuve^{1, 2}

K. De Cuyper¹

M. Vansevenant^{1, 2}

K. Verstraete²

AZ St Maarten, Radiology; Leopoldstraat 2 2800 Mechelen, Belgium;

Email:marc.mespreuve@emmaus.be

Section: Musculoskeletal System

Published: 2015, Aug. 31

Patient: 49 year(s), female

Clinical History

A 49-year-old female patient with persistent pain during several months around the third carpometacarpal joint was referred for a radiological control and MRI analysis with the clinical suspicion of carpal boss. The patient was treated conservatively with anti-inflammatory medication. In three other patients the same variant was a coincidental finding.

Imaging Findings

The radiography revealed a capitate-trapezoid coalition (CTC). The capitate-trapezoid joint (CTJ) was narrowed with irregular, sclerotic margins. There were no arguments for a carpal boss. MRI moreover showed a CTJ filled with fibrovascular tissue, a surrounding kissing bone marrow oedema, the presence of small subchondral cysts and irregular joint margins around the complete joint (Minnaar type 1 coalition). No other bony or soft tissue anomalies were detected.

Discussion

Carpal coalition may occur in two or more adjacent bones in almost any combination (most frequently lunotriquetral 89, 3%, rarely capitate-trapezoid 2, 9% [1]) Most coalitions occur between carpals within the same carpal row [2]. Coalitions between carpals from different rows are rare [3]. Fusion of carpal bones is hereditary (transmitted as a dominant factor which is not sex linked [4]). The coalition is caused by a failure of cavitation of the cartilaginous hand bud precursor (during the fourth to eighth week of gestation) or of cartilaginous segmentation of a common cartilaginous carpal precursor [5]. The malsegmentation results in a carpal coalition, which may be fibrous (syndesmosis), cartilaginous (synchondrosis), frequently a mixture of both or osseous. CTC - a rare coalition type - is usually considered asymptomatic. In very rare cases however fibrocartilaginous (type 1) CTC may be a cause of focal pain due to the pseudarthrosis or a post-traumatic disruption of CTC. The most frequently used classification on plain film is of de Villiers Minnaar [6] (four types). Minnaar type 1 resembles a pseudarthrosis due to its incomplete fibrocartilaginous coalition. The type 1 coalition may become symptomatic due to the pseudarthrosis or - as for all structures - in case of fracture. The weaker fibrocartilaginous coalition appears to be more susceptible to stress or trauma. The deficient intra-articular cartilage formation at the joint results in a clinical and anatomic condition similar to degenerative osteoarthritis [7]. The cartilage of the surrounding joints may become damaged as well due to disturbed motion. Although carpal fusion is mostly an asymptomatic condition, symptoms may appear after intense and repeated movements. A possible alteration of the normal biomechanics of the wrist may cause an abnormal stress. CTC type 1 resembles a pseudarthrosis on plain film radiography with irregular sclerotic margins, a narrowed joint space and eventually subcortical cysts. This non-osseous coalition may result in degenerative osteoarthritis [8]. MRI shows without the use of radiation more clearly the pseudarthrosis with irregular sclerotic margins, subchondral cysts and a narrowed joint space filled with fibrocartilage. It may in symptomatic cases additionally show bone marrow edema adjacent to joint on fluid-sensitive sequences. 3D-gradient echo sequences also offer a more accurate classification than plain films due to the elimination of bony superposition. MRI may give the necessary information about the condition of the surrounding articular cartilage and may also exclude concomitant (soft tissue) pathology of the wrist.

Final Diagnosis

A rare case of symptomatic capitate-trapezoid carpal coalition, Minnaar-type 1.

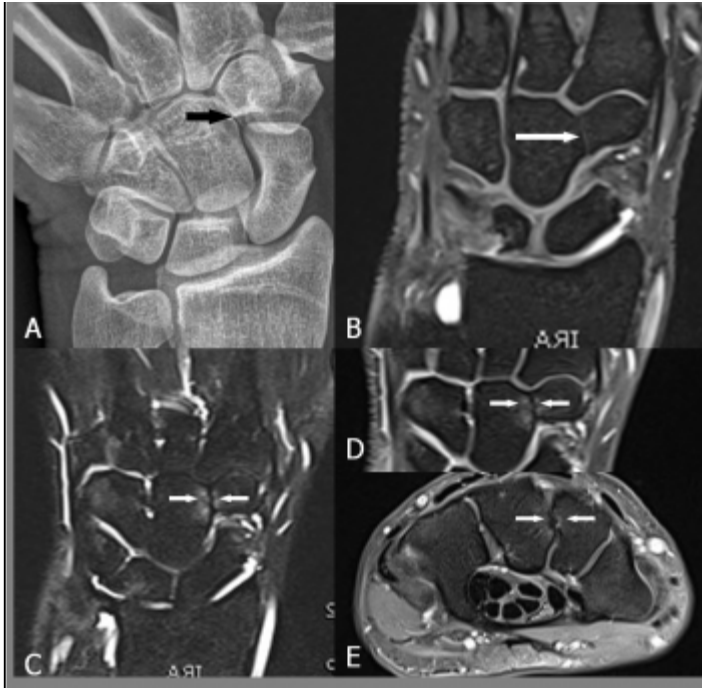Differential Diagnosis List

Acquired fusion secondary to arthritis, Surgery, Trauma, Acquired fusion after drug intake during pregnancy, Metaplastic conversion of intra-articular structures, Carpal coalitions associated with other hand and/or wrist abnormalities, (Symptomatic) carpal boss

Figures

Figure 1 Symptomatic CTC Minnaar type 1 in a 49-year-old female (patient 1).



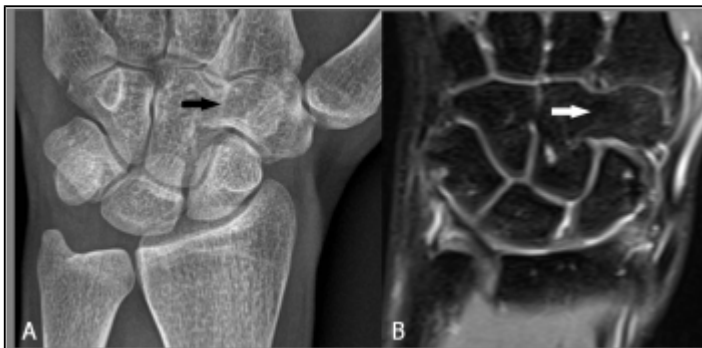

(A) Narrowed CTJ with irregular, sclerotic margins (arrow). (B) CTJ filled with fibrovascular tissue (long arrow), (B-E) There is a surrounding bone marrow oedema, presence of subchondral cysts and the margins are irregular (short arrows).

© Department of Radiology, St.-Maarten General Hospital, Leopoldstraat 2, 2800 Mechelen, Belgium

Area of Interest: Bones;
 Imaging Technique: MR;
 Procedure: Diagnostic procedure;
 Special Focus: Congenital;

Figure 2 CTC Minnaar type 3, an asymptomatic variant (24-year-old male)




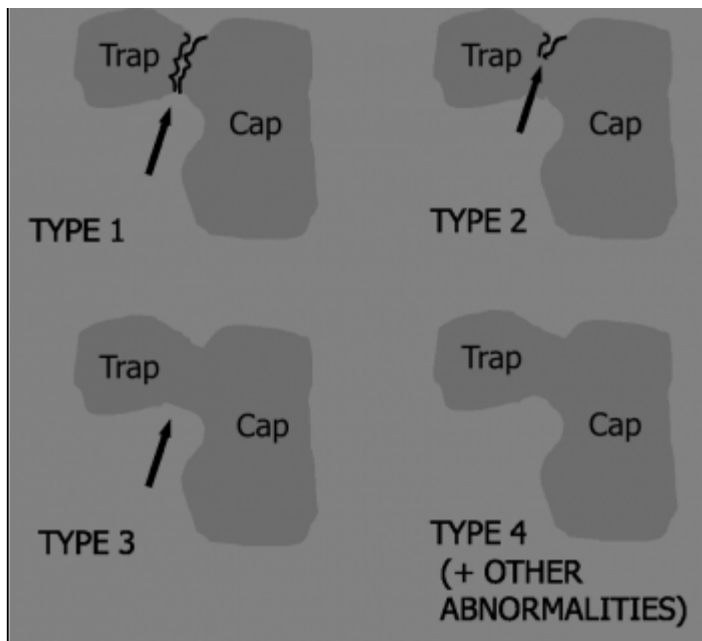
(A) Plain radiography. (B) Coronal SE T2-WI FS. Carpal coalition with complete osseous bridging. No adjacent bone marrow oedema.

© (1) Department of Radiology, St.-Maarten General Hospital, Leopoldstraat 2, 2800 Mechelen, Belgium

Area of Interest: Bones;
 Imaging Technique: MR;
 Procedure: Diagnostic procedure;
 Special Focus: Congenital;

Figure 3 Carpal coalition Minnaar types 1 to 4. Schematic view



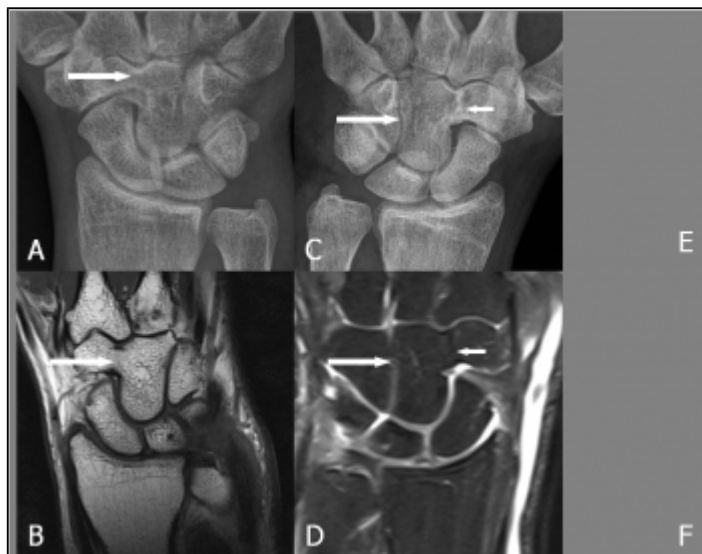

Type 1: narrowed CTJ, irregular sclerotic margins. Type 2: incomplete osseous fusion with (small, mostly distal) joint space remnant Type 3: complete osseous fusion. Type 4: = type 3 with other carpal congenital bony abnormalities.

© (1) Department of Radiology, St.-Maarten General Hospital, Leopoldstraat 2, 2800 Mechelen, Belgium

Area of Interest: Bones;
 Imaging Technique: Conventional radiography;
 Procedure: Diagnostic procedure;
 Special Focus: Congenital;

Figure 4 Isolated and combined asymptomatic CTC



(A-B) 38-year-old female (patient 3) with isolated CTC. Incomplete osseous fusion with distal joint space remnant (Minnaar type 2). (C-D) 63-year-old male (patient 4) with combined capitate-hamate (large arrows) and capitate-trapezoid (small arrows) coalition.

© (1) Department of Radiology, St.-Maarten General Hospital, Leopoldstraat 2, 2800 Mechelen, Belgium

Area of Interest: Bones;
 Imaging Technique: MR;
 Procedure: Diagnostic procedure;

Figure 5 (de Villiers) Minnaar classification

| Coalition | Plain Film | MR | Histopathology | Clinical correlation |
|-----------|----------------------------------------------------------------------------------------------------------|---------------------------------------------------------------------------------------------------------------------------------------------------------------------------------------------------|--------------------|--------------------------------------|
| Type 1 | increased CT joint irregular articular margins eventually subchondral cysts | increased CT joint irregular articular margins eventually subchondral cysts eventually bone marrow edema eventually damage to the surrounding cartilage eventually osteoarthralgia | Non-collapse | Osteoarthralgia |
| Type 2 | Incomplete osseous fusion small residual space | Incomplete osseous fusion small remnant of the joint space | Incomplete osseous | Asymptomatic |
| Type 3 | Complete osseous fusion between the capitula and trapezoid bone | Complete osseous fusion between the capitula and trapezoid bone 3D type 1 and 2 | Complete osseous | Asymptomatic |
| Type 4 | Complete osseous fusion between the capitula and trapezoid bone Other carpal-coalition bones abnormal | Complete osseous fusion between the capitula and trapezoid bone Other carpal-coalition bones abnormal eventually proximal of the wrist bones | Complete osseous | Other carpal-coalition abnormalities |

(de Villiers) Minnaar classification of carpal coalitions (plain film) with MRI correlation, histopathology and clinical correlation

© (1) Department of Radiology, St.-Maarten General Hospital, Leopoldstraat 2, 2800 Mechelen, Belgium

Area of Interest: Bones;
Imaging Technique: MR;
Procedure: Diagnostic procedure;
Special Focus: Congenital;

References

- [1] De Fazio M, Cousins B, Miversuski R et al. (2013) Carpal coalition Hand 8: 157-163.
- [2] Garn SM, Frisancho R, Poznanski AK et al. (1971) Analysis of Triquetral-Lunate fusion Am J Physical Anthropology 34: 431-434.
- [3] Poznanski AK, Holt JF (1971) The carpals in congenital malformation syndromes Am J Roentgenol Radium Ther Nucl Med 112: 443-459.
- [4] Henry MB (1945) Anomalous fusion of the scaphoid and the greater multangular bone Archives of Surgery 50: 240-241.
- [5] Cockshott WP (1963) Carpal fusions Am J Roentgenol Radium Ther Nucl Med 89: 1260-1271.
- [6] de Villiers Minnaar AB (1952) Congenital fusion of the lunate and triquetral bones in the South African Bantu J Bone Joint Surg Br 34: 45-48.
- [7] Gross SC, Watson HK, Strickland JW et al. (1989) Triquetral-lunate arthritis secondary to synostosis J. Hand Surg Am 14(1): 95-102.
- [8] Ganos DL, Imbriglia JE (1991) Symptomatic congenital coalition of the pisiform and hamate J Hand Surg Am 16: 646-650.

Citation

M. Mesprenve^{1, 2}
K. De Cuyper¹
M. Vansevenant^{1, 2}
K. Verstraete²

AZ St Maarten, Radiology; Leopoldstraat 2 2800 Mechelen, Belgium;

Email: marc.mespreuve@emmaus.be (2015, Aug. 31)

Carpal coalition: 4 cases of a rare bony coalition between the capitate and trapezoid bone, with MRI findings in a symptomatic case. {Online}

URL: <http://www.eurorad.org/case.php?id=12910>