



## Case 15701

### Distal clavicular osteolysis in a bodybuilder

Aliaksandr Anisau<sup>1, 2</sup>

Filip M. Vanhoenacker<sup>1, 2, 3</sup>

1. General Hospital AZ Sint-Maarten Duffel-Mechelen, Leopoldstraat 2, B-2800 Mechelen, Belgium.

2. University Ghent, Department of Medicine and Health Sciences.

3. University Hospital Antwerp, University Antwerp, Department of Radiology, University Hospital Antwerp; Wilrijkstraat, 10, 2650 Antwerp, Belgium; Email: [filip.vanhoenacker@telenet.be](mailto:filip.vanhoenacker@telenet.be)

University Hospital Antwerp, Department of Radiology, University Hospital Antwerp; Wilrijkstraat, 10 2650 Antwerp, Belgium; Email: [filip.vanhoenacker@telenet.be](mailto:filip.vanhoenacker@telenet.be)  
University Hospital Antwerp

**Section:** Musculoskeletal System

**Published:** 2018, May. 2

**Patient:** 33 year(s), male

## Clinical History

A 33-year-old amateur body-builder presents with left shoulder pain since about 5 months, without a history of preceding acute trauma. Palpation of the acromioclavicular joint is painful. Mobilization of the left shoulder is normal and painless.

## Imaging Findings

Standard radiography showed cortical irregularity of the articular side of the distal clavicle (figure 1a and 1b). The acromion appeared to be normal. The patient underwent an MR arthrography, because initially, rotator cuff pathology was suspected. The rotator cuff tendons and capsulolabral system were normal. There was marked bone marrow edema in the distal clavicle and whereas the signal of the distal acromion was almost normal (figure 2a and 2b). The subchondral cortex of the distal clavicle appeared thinned and was irregularly delineated (figure 2a). A mild AC-joint effusion

and hypertrophy of the joint capsule was present (figure 2a and 2c). Follow-up radiographs 2 months after their initial presentation showed a normal right AC joint (figure 3a), whereas residual osteolysis was seen at the superolateral aspect of the left clavicle (figure 3b).

## Discussion

---

Distal clavicular osteolysis (DCO) follows both chronic repetitive stress and single acromioclavicular trauma [1]. The exact etiopathogenesis is unclear, but AC-joint trauma and subchondral microfractures seem to be involved [1, 2]. Subsequent attempts at repair are insufficient and the final result is osteolysis [1, 4]. It's unclear why changes predominate in the distal clavicle while the acromion is relatively spared [1].

DCO has been most frequently reported in weightlifters and bodybuilders [1, 2]. Overhead sports, especially when combined with supplemental weight training, are also at increased risk [4].

Professional activities requiring similar movements or exposure to chronic repetitive stress (e.g. pneumatic drill operation) can also cause DCO [5].

Clinical findings are often nonspecific and frequently overlap with those of labral or rotator cuff tears [5]. Patients experience pain in the AC-joint region, exacerbated by weight training and relieved by prolonged rest [2]. Targeted clinical examination reveals point tenderness over the AC-joint and painful cross-body adduction [2, 4].

Conventional radiographs may remain normal during the first months or years after the onset of training [1, 3]. A 15° cephalad inclination avoids superposition of the scapular spine with the AC-joint [2]. Radiographic changes include cortical thinning, irregularity and microcysts in distal clavicle and mild AC-joint widening [1, 2]. A late finding is tapering of the distal clavicle [2]. MRI is far more sensitive to detect DCO in an early stage [1]. The most common MR-finding is bone marrow oedema in the distal clavicle, sometimes also in the articular part of the acromion, but less distinct [1, 3]. Often, a hypo-intense line is seen in this area of clavicular bone marrow edema, representing a subchondral fracture [1, 4]. AC-joint abnormalities are common, and include effusion, mild widening, intra-articular bone fragments and capsule hypertrophy [2, 5]. Other MR-findings are similar to those seen on radiographs, as described above.

Treatment is essentially conservative, consisting of rest and nonsteroidal anti-inflammatory drugs (NSAID's), is usually successful [2, 4]. In severe cases, resection of the distal clavicle is indicated [1, 2]. If left untreated, the process may cause progressive resorption of lateral aspect of the clavicle, erosions and cupping of the acromion and dystrophic calcifications [3].

DCO should be considered in the differential diagnosis of shoulder pain in the appropriate population. Therefore, analysis of MR arthrographic studies of the shoulder should not be restricted to evaluation of the rotator cuff and capsulolabral system, but the AC-joint should be scrutinized as well.

## Final Diagnosis

---

Distal clavicular osteolysis.

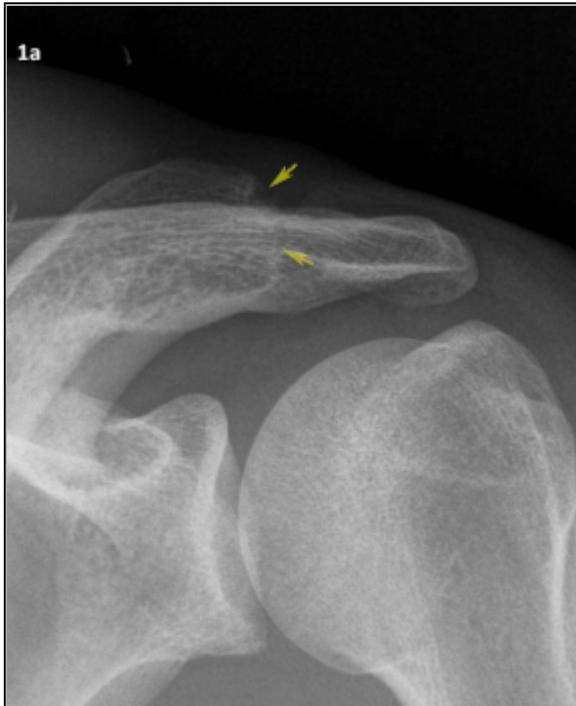## Differential Diagnosis List

---

Septic arthritis, Rheumatoid arthritis, Hyperparathyroidism, Gout, Corticosteroid induced

## Figures

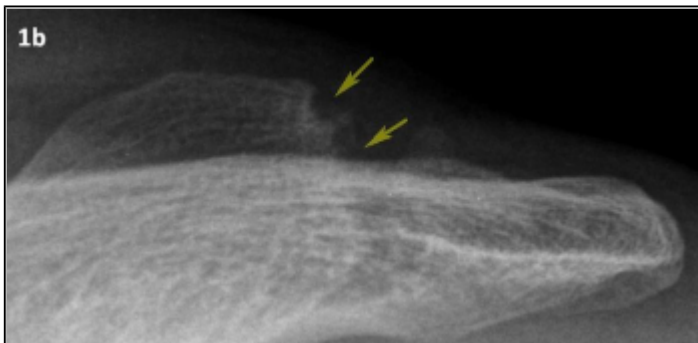
**Figure 1 Conventional radiograph of the left shoulder**



Yellow arrows: irregular delineation of the of the articular cortex of the acromial end of the clavicle.

© Department of Radiology, AZ Sint-Maarten, Mechelen, Belgium

Area of Interest: Extremities; Musculoskeletal bone; Musculoskeletal joint;  
Imaging Technique: Conventional radiography;  
Procedure: Diagnostic procedure;  
Special Focus: Athletic injuries;

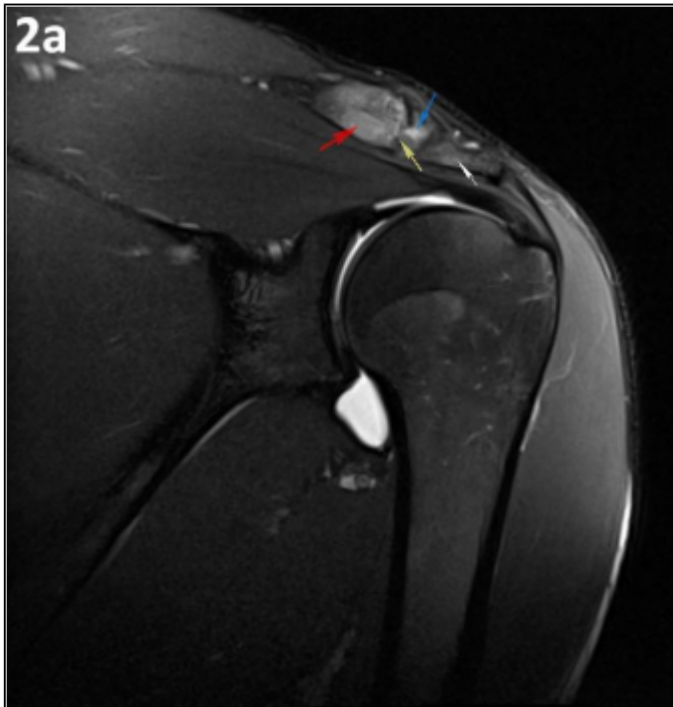


Enlarged view of the AC-joint. Yellow arrows: irregular delineation of the of the articular cortex of the acromial end of the clavicle.

© Department of Radiology, AZ Sint-Maarten, Mechelen, Belgium

Area of Interest: Extremities; Musculoskeletal bone; Musculoskeletal joint;  
Imaging Technique: Conventional radiography;  
Procedure: Diagnostic procedure;  
Special Focus: Athletic injuries;

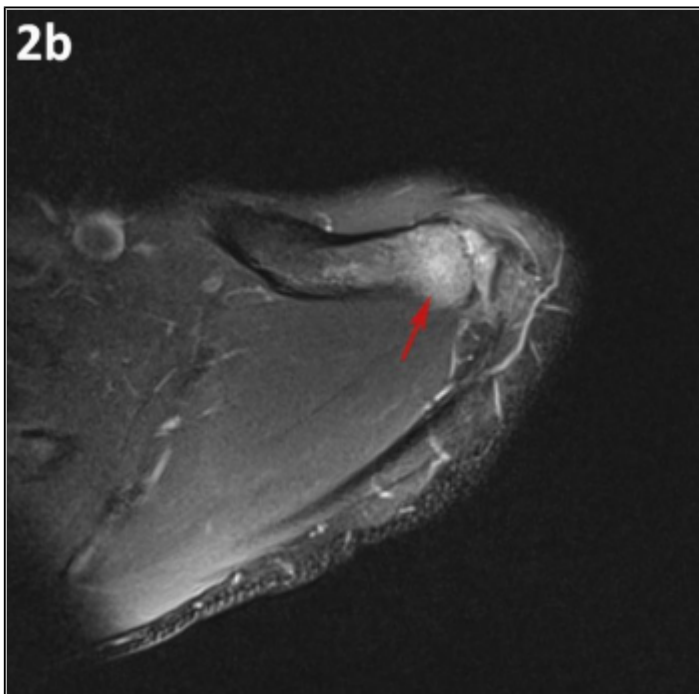
**Figure 2 arthro-MRI of the left shoulder**



MRI T2 fs, coronal image. Red arrow: bone marrow edema in distal clavicle. White arrow: very subtle bone marrow edema in acromion. Yellow arrow: subchondral cortical irregularity in the distal clavicle. Blue arrow: AC-joint effusion.

© Department of Radiology, AZ Sint-Maarten, Mechelen, Belgium

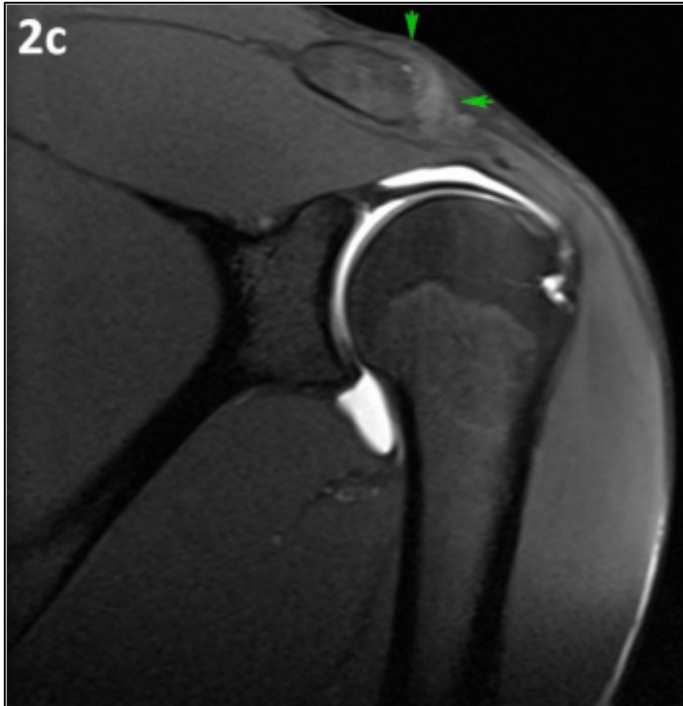Area of Interest: Extremities; Musculoskeletal bone; Musculoskeletal joint;  
Imaging Technique: MR;  
Procedure: Diagnostic procedure;  
Special Focus: Athletic injuries;



MRI T2 fs, axial image. Red arrow: bone marrow edema in the distal clavicle.

© Department of Radiology, AZ Sint-Maarten, Mechelen, Belgium

Area of Interest: Extremities; Musculoskeletal bone; Musculoskeletal joint;  
Imaging Technique: MR;  
Procedure: Diagnostic procedure;  
Special Focus: Athletic injuries;

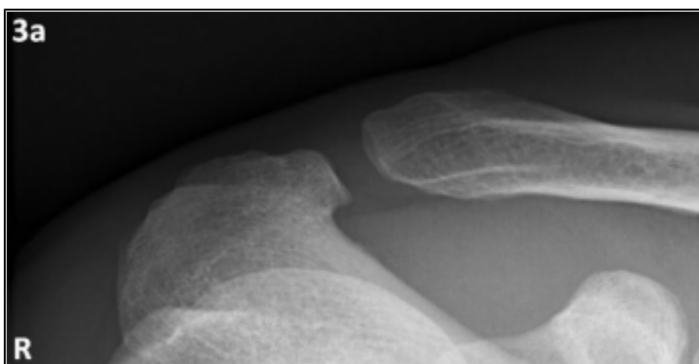


MRI T1 fs, coronal image. Green arrows: hypertrophy of the AC-joint capsule.

© Department of Radiology, AZ Sint-Maarten, Mechelen, Belgium

Area of Interest: Extremities; Musculoskeletal bone; Musculoskeletal joint;  
Imaging Technique: MR;  
Procedure: Diagnostic procedure;  
Special Focus: Athletic injuries;

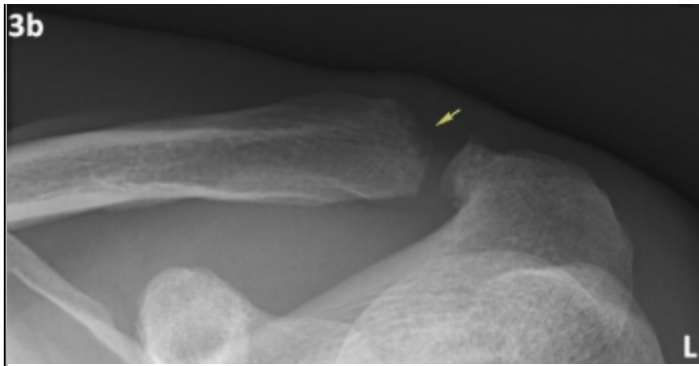
**Figure 3 Follow-up radiograph of both AC joints**



Right AC joint with 15° cephalad inclination 2 months later. Normal delineation of the AC joint.

© Department of Radiology, AZ Sint-Maarten, Mechelen, Belgium

Area of Interest: Extremities; Musculoskeletal bone; Musculoskeletal joint;  
Imaging Technique: MR;  
Procedure: Diagnostic procedure;  
Special Focus: Athletic injuries;



Left AC joint with 15° cephalad inclination 2 months later. Yellow arrow: there is still irregular delineation and osteolysis of the superolateral aspect of the left clavicle.

© Department of Radiology, AZ Sint-Maarten, Mechelen, Belgium

Area of Interest: Extremities; Musculoskeletal bone; Musculoskeletal joint;  
Imaging Technique: MR;  
Procedure: Diagnostic procedure;  
Special Focus: Athletic injuries;

## References

- [1] Kassarian A, Llopis E, Palmer WE (2007) Distal clavicular osteolysis: MR evidence for subchondral fracture Skeletal radiol 36(1): 17-22
- [2] Schwarzkopf R, Ishak C, Elman M, Gelber J, Strauss DN, Jazrawi LM (2008) Distal clavicular osteolysis Bull NYU Hosp Jt Dis 66(2): 94-101
- [3] De La Puente R, Boutin RD, Theodorou DJ, Hooper A, Schweitzer M, Resnick D (1999) Post-traumatic and stress-induced osteolysis of the distal clavicle: MR imaging findings in 17 patients Skeletal radiol 28(4): 202-208
- [4] Roedl JB, Nevalainen M, Gonzalez FM, Dodson CC, Morrison WB, Zoga AC (2015) Frequency, imaging findings, risk factors, and long-term sequelae of distal clavicular osteolysis in young patients Skeletal radiol 44(5): 659-666
- [5] Patten RM (1995) Atraumatic osteolysis of the distal clavicle: MR findings J Comput Assist Tomogr 19(1): 92-95

## Citation

Aliaksandr Anisau<sup>1, 2</sup>  
Filip M. Vanhoenacker<sup>1, 2, 3</sup>

1. General Hospital AZ Sint-Maarten Duffel-Mechelen, Leopoldstraat 2, B-2800 Mechelen, Belgium.
2. University Ghent, Department of Medicine and Health Sciences.
3. University Hospital Antwerp, University Antwerp, Department of Radiology, University Hospital Antwerp; Wilrijkstraat, 10, 2650 Antwerp, Belgium; Email: filip.vanhoenacker@telenet.be

University Hospital Antwerp, Department of Radiology, University Hospital Antwerp;  
Wilrijkstraat, 10 2650 Antwerp, Belgium; Email:filip.vanhoenacker@telenet.be (2018, May. 2)

**Distal clavicular osteolysis in a bodybuilder {Online}**

URL: <http://www.eurorad.org/case.php?id=15701>