

Accepted Manuscript

Morgagni hernia repair in children over two decades: Institutional experience, systematic review, and meta-analysis of 296 patients

Yew-Wei Tan, Debasish Banerjee, Kate M. Cross, Paolo De Coppi, Simon C. Blackburn, Clare M. Rees, Stefano Giuliani, Joe I. Curry, Simon Eaton, for the GOSH team



PII: S0022-3468(18)30248-3
DOI: doi:[10.1016/j.jpedsurg.2018.04.009](https://doi.org/10.1016/j.jpedsurg.2018.04.009)
Reference: YJPSU 58649

To appear in:

Received date: 21 September 2017
Revised date: 30 March 2018
Accepted date: 3 April 2018

Please cite this article as: Yew-Wei Tan, Debasish Banerjee, Kate M. Cross, Paolo De Coppi, Simon C. Blackburn, Clare M. Rees, Stefano Giuliani, Joe I. Curry, Simon Eaton, for the GOSH team , Morgagni hernia repair in children over two decades: Institutional experience, systematic review, and meta-analysis of 296 patients. The address for the corresponding author was captured as affiliation for all authors. Please check if appropriate. Yjpsu(2018), doi:[10.1016/j.jpedsurg.2018.04.009](https://doi.org/10.1016/j.jpedsurg.2018.04.009)

This is a PDF file of an unedited manuscript that has been accepted for publication. As a service to our customers we are providing this early version of the manuscript. The manuscript will undergo copyediting, typesetting, and review of the resulting proof before it is published in its final form. Please note that during the production process errors may be discovered which could affect the content, and all legal disclaimers that apply to the journal pertain.

TITLE:

Morgagni hernia repair in children over two decades: Institutional experience, systematic review, and meta-analysis of 296 patients.

AUTHORS:

Yew-Wei Tan¹, Debasish Banerjee¹, Kate M. Cross¹, Paolo De Coppi^{1,2} for the GOSH team (Simon C. Blackburn¹, Clare M. Rees¹, Stefano Giuliani¹, Joe I. Curry¹, Simon Eaton²)

AFFILIATIONS:

¹Specialist Neonatal and Paediatric Surgery (SNAPS) Department, Great Ormond Street Hospital.

²Stem Cells & Regenerative Medicine, DBC, Great Ormond Street Institute of Child Health, University College London.

GOSH team (Simon C. Blackburn¹, Clare M. Rees¹, Stefano Giuliani¹, Joe I. Curry¹, Simon Eaton²)

CORRESPONDING AUTHOR:

Paolo De Coppi, MD, PhD

NIHR Professor of Paediatric Surgery

Nuffield Professor of Paediatric Surgery

Head of Stem Cells & Regenerative Medicine Section, DBC, UCL

Surgery Offices

UCL Institute of Child Health

30 Guilford Street

London WC1N 1EH

Tel: 020 7905 2641(Administrator)

Fax: 020 7404 6181

Email: p.decoppi@ucl.ac.uk

No conflict of interest declared

ABSTRACT

Background/Purpose: Morgagni diaphragmatic hernia (MH) is rare. We report our experience based on routine patch use in MH repair to curb recurrence. A systematic review and meta-analysis were performed to study the recurrence and complications associated with minimally invasive surgery and the use of patch.

Methods: We retrospectively reviewed all cases of MH who underwent first-time repair in 2012-2017 in our institution to determine recurrence and complication rate. A MEDLINE search related to minimally invasive surgery (MIS) and patch repair of MH was conducted for systematic review. Eligible articles published from 1997-2017 with follow-up data available were included. Primary outcomes measured were recurrence and complication.

Metaanalysis to compare open versus MIS and primary versus patch repair in the MIS group were performed in comparative cohorts. Continuous data were presented as median (range), and statistical significance was $P < 0.05$.

Results: In our institution, 12 consecutive patients aged 17-month-old (22 days-7 years), underwent laparoscopic patch repair of MH, with one conversion to laparotomy. No recurrence or significant complication occurred over a follow-up period of 8 months (1-48 months).

Thirty-six articles were included from literature review and were combined with the current series. All were retrospective case reports or series, of which 6 were comparative cohorts with both MIS and open repairs. A total of 296 patients from 37 series were ultimately used for analysis: 80 had open repair (4 patch) and 216 had MIS repair (32 patch), with a patch rate of 12%. There were 13 recurrences (4%): no difference between open and MIS repairs (4/80 vs 9/216, $P = 0.75$); recurrence rate following primary repair was 13/260 (5%), but no recurrence occurred with 36 patch repairs. Meta-analysis showed no difference in recurrence between open and MIS repair ($P = 0.83$), whereas patch repair was associated with 14% less recurrence compared with primary repair, although it did not reach statistical significance ($P = 0.12$). There were 13 complications (5%): no difference between open and MIS repairs (5/80 vs 8/216, $P = 0.35$). One small bowel obstruction occurred in a patient who had laparoscopic patch repair.

Conclusion: In MH, recurrence and complication rates are comparable between MIS and open repairs. Use of patch appeared to confer additional benefit in reducing recurrence.

Keywords: Morgagni, Larrey, diaphragmatic hernia, recurrence, patch, minimally invasive surgery.

Type of Study: Systematic review **Level of Evidence:** 3A

Background and aims:

Named after the Italian anatomist Giovanni Battista Morgagni (1682-1771), Morgagni hernia (MH) was first described in *Seats and Causes of Diseases* in 1761 [1,2]. It is characterised by a defect in the retrosternal area with herniation of abdominal contents through the sternocostal triangle. MH is also known as Larrey hernia, or anterior diaphragmatic hernia. It constitutes 3-5% of all congenital diaphragmatic hernias (CDH) [3,4], and is significantly associated with other congenital anomalies [4,5]. Despite a congenital anomaly, MH is mostly asymptomatic in childhood and typically presents late in life with pulmonary symptoms and pain [6]. In children, chest infection is the typical presentation often leading to a chest X-ray which reveals the diagnosis [4]. Right sided anterior diaphragmatic defect is much commoner than the left sided and bilateral types [4,6].

Surgical repair of MH has evolved over time, primarily by means of increasing popularity of minimally invasive surgical techniques since early 1990s in the adult literature. Several modifications in the technique, including the use of intracorporeal suturing, extracorporeal subcutaneous knot tying and the use of patch [7-9] were then introduced. The first paediatric laparoscopic MH repair was reported in 1997 [10], with robotic repair (2005) [11] and single-port surgery (2013) subsequently emerging [12], all demonstrating safety and feasibility of minimally invasive surgery (MIS).

The benefit of MIS over open repair in postoperative outcome has been demonstrated [13]. The benefit or risk of using a patch, however, has yet to be fully established in MH repair. Our experience with primary repair was associated with a 42% recurrence rate [14] which led us to using patch for all MH repair since 2012, in attempt to reduce this complication. The aim of this study was to report our experience with the regular use of patch for MH repair in the MIS era. To validate our results and compare them to the latest literature, we performed a systematic review and meta-analysis to further evaluate the effect of MIS and patch repair of MH on recurrence and complications.

Methods:

A retrospective review was conducted for all children who underwent repair of MH from January 2012 to February 2017 in Great Ormond Street Hospital for Children. Our preoperative assessment included an anterior-posterior and lateral chest X-ray, computed tomography of thorax, and a cardiac evaluation. Data related to age, gender, associated malformations, surgical approach, use of patch, recurrence and complications were collected. Patient with concurrent thoracic surgery performed were excluded.

Surgical techniques

For MIS (laparoscopic) repair at our institution, the patient is positioned in reverse Trendelenburg position with the surgeon standing at the foot of the bed. Routinely, three ports (5 mm) are placed. A Hasson cannula is inserted at the umbilicus and a 30 degree 5 mm laparoscope is used, and two further 3- or 5-mm working ports are inserted in the midclavicular lines for instruments. The defect and herniated organs including the hernia sac (if present) are defined. Following reduction of the hernia contents, the falciform ligament is divided using diathermy or Ligasure to better expose the diaphragm. The hernia sac is not excised. The size of the defect is then evaluated. We use a synthetic non-absorbable polyester patch (Bard® Sauvage Filamentous Fabric) to close the defect in all cases. The posterior aspect of the patch is first sutured to the posterior rim of the hernia defect using continuous or interrupted polypropylene sutures tied intracorporeally. Anteriorly, the patch is sutured onto the full thickness of the anterior abdominal wall muscles, or the rib cage, using non-absorbable sutures passed into the peritoneal cavity through tiny stab incisions at the epigastrium. Each suture was retrieved using EndoClose® (Metronic, Covidien), or a looped monofilament suture as a snare passed through a 14G cannula sheath introduced through the same stab incisions. The suture is completed by tying the knot extra-corporeally and buried in the subcutaneous layer.

The open (laparotomy) approach was utilised when the condition of the patient's comorbidities precluded safe or efficient laparoscopic approach. Typically, laparotomy involved a supraumbilical transverse muscle cutting incision to access the MH, with all the steps as in laparoscopic surgery, with the repair performed by suturing the same patch aforementioned in a similar fashion, except the knots were tied intracorporeally.

Systematic review and meta-analysis

This was performed according to Meta-analysis Of Observational Studies in Epidemiology (MOOSE) guideline. MEDLINE database was searched electronically on 1st of May 2017 by the primary researcher, with the search of the title and abstracts using a combination of relevant medical subject heading terms, keywords, and word variants for “Morgagni”, “Larrey”, “anterior”, “diaphragm”, “hernia”, “laparoscopy”, “minimally invasive surgery”, “patch”, and “mesh”. The search was limited by age (birth to 18 years) and language (English) since 1997. The reference lists of relevant articles and reviews were searched by hand for additional reports, and further web links suggested by the journal publishers were meticulously reviewed by one author (YWT). The abstract and full-text articles of the identified citations were reviewed to determine their eligibility (**Figure 1**).

Inclusion criteria were all cases of congenital MH in the literature, in full or in part of any congenital diaphragmatic hernias (CDH) series, as long as adequate information was given to suggest that follow-up evaluation had taken place to assess recurrence and/or complications. Exclusion criteria were: Bochdalek (posterolateral) diaphragmatic hernia present, Pentalogy of Cantrell association due to its potential association with abdominal wall defect precluding laparoscopy, concomitant thoracic surgery (e.g. cardiac, pectus excavatum) whereby thoracotomy or sternotomy is often the choice of access, subjects over 18 years of age, reports lacking explicit follow-up for recurrence and/or complication (i.e. immediate postoperative outcome alone was not deemed adequate), and presence of inflammatory abdominal pathology (e.g. appendicitis) which could be regarded as a relative contraindication for patch. If more than one study was published for the same cohort with identical end points, only the article with the most comprehensive information on the population was included in order to avoid data overlapping. In some series where some, but not all, subjects met the exclusion criteria, the series was still included with those subjects excluded for analysis.

The primary and secondary outcome measures of the review were hernia recurrence and complications, respectively. All relevant data from eligible studies were collated (**Tables 2 and 3**) in order for outcomes to be compared between MIS and open cases, and also between primary and patch repair. The ultimate approach used was regarded as the definitive approach, therefore MIS converted to open would be categorised in the open group. Statistical analyses were performed using Fisher's exact test for categorical data, and continuous data were compared using Mann Whitney U-test, $P < 0.05$ was considered statistically significant.

Meta-analysis was then performed for reported series consisted of comparative groups of patients who underwent open versus MIS repair, and for those that underwent primary versus patch MIS repair. Our institution's data in the two periods, i.e. 2002-2011 [14] and 2012-2017 (i.e. the current series), were combined and analysed as the "GOSH series". These patients were included for meta-analysis with Forest plot constructed. Recurrence was analysed using a random effects model. As several reports had a zero rate of recurrence in either group, risk difference was chosen as the outcome measure, and is reported with 95% confidence intervals. Review Manager version 5.3 was used for meta-analysis.

Results:

In the last 5 years, 13 patients with MH underwent surgical repair at our institution. One patient was excluded because a small MH was found incidentally during cardiac surgery who underwent a successful primary correction through the same sternotomy. The remaining 12 consecutive patients (8 boys) had a median age at surgery of 17 months (22 days – 7 years), all underwent laparoscopic repair using a non-absorbable patch measuring from 3cm x 3cm to 10cm x 10cm. One of these patients was an 11-month old boy with a large MH defect (7cm x 3cm) started as a laparoscopic procedure, but necessitated conversion to laparotomy for efficiency of the surgery. Nine (75%) of these patients had significant associated anomalies: Trisomy 21 (n=3), cardiac anomalies (n=3), a history of anterior abdominal wall defect repaired (n=3), absent corpus callosum (n=1), anorectal malformation (n=1), and tracheomalacia (n=1). No recurrence was seen in a median follow-up of 8 months (1-48 months). One minor wound infection and one umbilical port site hernia were found following laparoscopic patch repair (**Table 1**).

Briefly, the “GOSH series” comprised the current cohort described above, as well as the 2002-2011 [14] cohort: Twelve patients with MH, aged 2 months to 11 years old, underwent open primary (n=2) and MIS (n=9) repairs. All were primary repairs except one MIS repair used patch. Five recurrences occurred in 5 primary repairs (1 open, 4 MIS) (**Table 2**).

Systematic review

The MEDLINE search identified 75 papers: 44 relevant articles related to MIS and patch repair of MH, with an additional 31 papers identified through hand search, cross-referencing, and following publishers’ suggested web links. Thirty-six unique articles out of the 75 were included from the literature review based on the predefined criteria, and were combined with the current series, producing a total of 296 patients included for analysis. 6 series were comparative studies allowing comparison between open and MIS repairs (N=139) (**Table 2**) [13-17], 31 others were either case reports or case series (n=157) (**Table 3**) [12,18-47]. Articles included were published between 1999 and 2017. Patients had been operated between 1990 and 2017. The majority were series from single centres, except three which were multicentre studies [13,46,47].

Among the 296 patients: 80 had open repair (4 patch) and 216 had MIS repair (32 patch) (P=0.03), with an overall patch rate of 12%. There were 13 recurrences (4%) with no difference between open and MIS repairs (4/80 vs 9/216, P=0.75). All thirteen recurrences were found in patients who had primary repair (n=260), in comparison, there was no

recurrence with any of the patch repairs (n=36). Complications were present in 5 open and 9 laparoscopic cases (5%) (P=0.54) (**Table 4**).

Patch repairs

Of the 36 patients who underwent patch repair, the majority used non-absorbable synthetic materials (n=26) including PTFE (Gore-Tex), Polyester (Dacron, Bard® Sauvage Filamentous Fabric) and Mersilene patches. Others had used absorbable synthetic patches including Surgisis or Surgisis Gold (n=8). The remainder did not specify the type of patch used (n=5).

Meta-analysis on effect of patch on recurrence

Meta-analysis was performed on those series reporting comparative data between patch and primary repair using MIS. As several papers reported a zero recurrence rate (in both MIS and open patients), it was decided to use risk difference as the outcome measure; otherwise those papers with no overall recurrences do not contribute to the meta-analysis [48]. The Forest plots are shown in **Figure 2 and 3**, showing no difference in recurrence between MIS and open repair, and there was a 14% lower risk of recurrence in patch repair than in primary repair (95% CI -0.32,0.04), but this was not significant (p=0.12). There was no evidence for significant heterogeneity ($I^2=0\%$) and the risk of publication bias could not be reliably assessed by a funnel plot because of the small number of events.

Discussion:

Utilisation of MIS in MH has been extensively reported in the literature over the last two decades. This is the first systematic review of MH repair in children showing low recurrence and complication rate, which is comparable between open surgery and MIS. Our institution's experience and the meta-analysis would suggest that use of patch confers advantage in reducing the recurrence in MH. In fact, the reported experience to date has suggested that none of the patch repairs have resulted in any hernia recurrence, and it is associated with low risk of complications. Such findings are in keeping with the suggestion that the use of patch repair for MH differs in nature when compared with the typical Bochdalek CDH whereby significant risk of recurrence and complications have been reported, especially with biological patches [49]. In our study, the types of patch used did not seem to make any difference and they all produced good outcomes. It is not clear if this relates to the unique anatomy around the sternocostal triangle (of Larrey) where MH occurs. In our experience we have adopted the use of a patch in all cases of MH because, unless the defect is very small, the closure is done under tension and it is likely to recur [14]. The use of patch reduces such tension, and also increases the likelihood of adhesion in the area which may explain how it could help prevent recurrences. As the liver is anatomically positioned between the repaired hernia defect (and the patch when used) and the bowel, adhesional bowel obstruction risk is reduced significantly with only one case reported in the literature and none observed in our experience [16]. Such advantage could be further garnered when laparoscopy is utilised. Therefore, theoretically laparoscopic patch repair of MH could be regarded as the gold standard approach based on the current evidence available.

Our own institutions' experience of switching to regular patch repair from primary repair reduced the recurrence rate from 42% to zero. We learned the lesson by noticing that all the redo surgeries (n=3) with the use of patch led to resolution of the problem, whilst repair without patch had continued to cause further recurrence in the majority [14]. It is, however, important to report that such findings had not been observed by other authors, and that the outcomes of primary repairs performed elsewhere do seem to have a higher success rate than our own. As recurrence cannot always be detected unless a standardised follow-up process with chest X-ray is performed, it is conceivable that variation in reported experience and results would exist, which may at least in part explain such discrepancy. Nonetheless, our experience taught us that patients who developed a recurrence were likely to have MH repair that failed due to significant tension of the repair, and therefore the re-repair should be done with the use of a patch. The use of patch has been theorised to increase the risk of infection and restrict growth [21], but we have not seen these complications ourselves, nor has it been reported in the literature. As our practice evolved, the use of a non-absorbable

patch at the first surgery is now performed routinely as standard which produced significantly better results, with no recurrence in the last 5 years.

Our systematic review selected publications dated back to 1997, as MIS repair of MH was first reported by Georgacopulo et al. that year [10]. MIS continues to be utilised for its advantages in recovery time, length of stay, and analgesia requirement compared to the open approach and more importantly laparoscopy in experienced centres produced less complication and equally good results [13,17]. Effective laparoscopic primary repair has been made possible with the development of various modifications with use of Endo Stitch (Covidien) for intracorporeal suturing [26], or application of extracorporeal knot-tying techniques with knots buried in the subcutaneous layer [25]. Various needle retrieving techniques through the same epigastric incision using hollow-needle snare [42], or indeed in our experience with use of Endo Close (Metronic, Covidien). Placing a 'hitch' stitch to the midpoint of the posterior diaphragmatic rim also enables the rest of the sutures to be tied to the anterior abdominal wall or rib cage without tension [32,47].

The use of patch in laparoscopic surgery for MH appeared to be less well adopted in comparison, as our systematic review showed only a 13% patch rate. This is mainly due to the threshold for patch repair being variable between institutions. Two technical considerations possibly influence surgeons' practice: to suture the patch in place increases the technical demand with the need for intracorporeal suturing, which would otherwise be less necessary for primary repair; and secondly it prolongs the procedure because of the additional suture line between the patch and the posterior diaphragmatic muscle rim. Also, patches are expensive and may deter surgeons from lower income countries from using them. This, of course, has to be balanced against the risk of recurrence which will potentially be more costly, beside the direct consequences on the patients and their families.

Despite widespread acceptance of MIS in MH, the open technique continues to serve as an important alternative strategy. We have shown that open surgery confers equal recurrence rate compared to MIS, and we have found it to be particularly useful for patients with severe scoliosis, extensive adhesions [14], very large defect precluding efficient suturing by MIS [our current series], and in children with small peritoneal cavity resulting in little working space for laparoscopy [44]. The smallest patient who underwent a successful MH repair in the literature was reported by Golden et al., which was a 14-day old infant with corrected gestation of 29 weeks who weighed 625g during surgery [44]. Another consideration for open surgery over MIS is the effect of laparoscopy on diaphragmatic splinting, which could potentially put infants with respiratory distress syndrome at increased risk. Nevertheless,

laparoscopic repairs in infant as small as one month old have been successfully performed by our group and reported by others [17,27], suggesting appropriate patient selection is the key to success. Traditionally in adult practice when open repair was performed for MH, both thoracotomy and laparotomy had produced equal results [6,50]. However, thoracotomy carries increased morbidity of higher likelihood of postoperative ventilator support and pneumothorax requiring a chest drain; and in the long run the potential for chest wall deformity given evidence based on neonatal thoracotomies for oesophageal atresia [51,52]. An abdominal approach, on the contrary, avoids all the morbidity of thoracotomy and has several distinct advantages in MH, namely assessment for laterality of the hernia in case of bilaterality, less likelihood of injury to the heart, and allowing for correcting malrotation. So far only one patient within this review underwent MH repair via a right exploratory thoracotomy as a consequence of a soft tissue mass detected within the cardiophrenic angle which transpired to be the left lobe of the liver herniating through a MH [4,13]. One more patient of ours from the current series, excluded from the analysis, underwent repair during cardiac surgery via the sternotomy approach used for the heart repair. All the others were open repair via a laparotomy.

The majority of MH present with a sac, and sac excision continues to be controversial. Proponents of this practice suggested that sac excision enables the posterior muscle rim to be better visualised and included in the suture therefore providing a stronger repair [15]. There has also been one report of fluid accumulation between the sac and the repaired hernia but this did not require specific intervention or cause any specific physiological problem [32]. However, it has been theorised that excising the sac increases the risk of injury to the phrenic nerve, pleura and pericardium [24]. However, only one problem of sac excision has ever been reported in association with arrhythmia [25]. Akbiyik et al. reported eight open primary repairs [31], whilst Alkhatrawi et al. [43] and Mallick et al. [34] reported nine and fifteen primary laparoscopic MH repairs respectively, without sac excision, all with no recurrence or complication. Similarly, our institution has performed 12 laparoscopic repairs without sac excision and encountered no recurrence since 2002, as long as a patch was used [14]. Lamas-Pinheiro et al. reported all 13 of their patients, from a multi-centre study in Portugal, who did not have sac excision but had 2 recurrences, although these were at risk patients who had absorbable suture used in one, and both had Down's syndrome [46]. Therefore, our opinion is that sac excision is not necessary if a sound repair can be achieved, thereby reducing operative time and preventing the potential problems described. On the other hand, we understand that removing the sac may have reduced the recurrence rate observed in our initial series, and appreciate the fact we do not offer a definitive answer to this issue [14].

Other limitations of this systematic review are related to the fact we have included case reports and series even when they were non-comparative studies, because we appreciate the rarity of the condition makes large cohort uncommon. This could result in reporting bias and potentially under-reporting of negative outcomes. However, by being able to include these cohorts, which consisted of over half the patients with follow-up outcome reported, we hope to more accurately represent the bulk of the literature avoiding selection bias. The most obvious limitation of this systematic review is associated with the nature of the published papers, which consists of only retrospective series, with 28 (76%) had cohorts fewer than 10 patients, and 32 (86%) were non-comparative series. The most significant of all is the wide range of follow-up, from 2 to 108 months, and four selected series did not specify the duration (**Tables 2 & 3**). In our effort to standardise reporting of recurrence rate, we used the loose exclusion criteria (i.e. reports lacking explicit follow-up for recurrence) applied strictly as a practical means of achieving this. This resulted in 15 otherwise eligible reports being excluded as shown in **Figure 1**. Another weakness of this this systematic review was it did not take into account of variables that might influence patient outcomes including age and presence of trisomy 21, a common association with MH [2]. Up to 4/1000 children with Trisomy 21 develop MH [2], and these patients are more likely to develop a recurrence, possibly related to the associated hypotonia and delay in diagnosis [13,15,46].

This systematic review has reinforced our experience during the period when MIS has emerged to be the predominant approach in the repair of MH. During this time we have evolved from performing primary repair, to the regular use of patch, with an associated improved outcome. Meta-analysis of comparative studies has shown that there is an advantage in using patch for MH repair in reducing recurrence. The choice of whether routine patch repair should be performed remains an institutional and individual surgeon's choice, although the use of a patch should be given consideration when the repair is under tension, because the complications associated with patch repair are comparable to primary repair. Multicentre randomization of MIS repair with or without patches may offer the answer to this controversial issue but maybe difficult to realise.

References:

1. Adams EW. Founders of Modern Medicine, Giovanni Battista Morgagni (1682-1771). *Medical Library and Historical Journal* 1903;1:270–277.
2. Paris F, Tarazona V, Casillas M, Blaseo E, Canto A, Pastor J, Acosta A. Hernia of Morgagni. *Thorax*.1973;28:631–636.
3. Simson JN, Eckstein HB. Congenital diaphragmatic hernia: a 20 year experience. *Br J Surg* 1985;72:733–736.
4. Al-Salem AH. Congenital hernia of Morgagni in infants and children. *J Pediatr Surg* 2007;42:1539–1543.
5. Honoré LH, Torf CP, Curry CJR. Possible association between the hernia of Morgagni and trisomy 21. *Am J Med Gen* 1993;47:255-256.
6. Horton JD, Hofmann LJ, Hetz SP. Presentation and management of Morgagni hernias in adults: a review of 298 cases. *Surg Endosc*, 2008;22:1413-1420.
7. Kuster G, Kline L, Garzo G. Diaphragmatic hernia through the foramen of Morgagni: Laparoscopic repair case report. *J Laparosc Surg*. 1992;2:93–100.
8. Rau H, Schardey H, Lange V. Laparoscopic repair of a Morgagni Hernia. *Surg Endosc*. 1994;8:1439–1442.
9. Newman L, Eubank S, Briges W, Lucas G. Laparoscopic diagnosis and treatment of Morgagni Hernia. *Surg Laparosc Endosc*. 1995;5:27–31.
10. Georgacopulo P, Franchella A, Mandrioli G, Stancanelli V, Perucci A. Morgagni-Larrey hernia correction by laparoscopic surgery. *Eur J Ped Surg* 1997;7:241-242.
11. Knight CG, Gidell KM, Lanning D, et al. Laparoscopic Morgagni hernia repair in children using Robotic instruments. *J Laparoendosc Adv Surg Tech A*. 2005;15:482-486.
12. Van Nierkerk ML. Laparoscopic morgagni hernia repair using single-site umbilical and full-thickness abdominal wall repair: Technical report of two cases. *Afr J Paediatr Surg*. 2013;10:55-57.
13. Al-Salem AH, Zamakhshary M, Al Mohaidly M, et al. Congenital Morgagni's hernia: A national multicenter study. *J Ped Surg* 2014;49:503–507.
14. Garriboli M, Bishay M, Kiely EM, et al. Recurrence rate of Morgagni diaphragmatic hernia following laparoscopic repair. *Pediatr Surg Int* 2013;29:185–189.
15. Jetley NK, Al-Assiri AH, Al-Helal AS, et al. Down's syndrome as a factor in the diagnosis, management, and outcome in patients of Morgagni hernia. *J Ped Surg* 2011;46:636–639
16. Laituri CA, Garey CL, Ostlie DJ, et al. Morgagni hernia repair in children: comparison of Laparoscopic and Open results. *J Laparoendosc Adv Surg Tech A*. 2011;21:89-91.
17. Golden J, Barrey WE, Jang G, et al. Pediatric Morgagni diaphragmatic hernia: a descriptive study. *Pediatr Surg Int*. 2017;33:771–775.
18. Becmeur F, Horta-Geraud P, Schwaab C, et al. Laparoscopic treatment of Morgagni hernia in a child: case report and literature review. *Ped Endosc Inn Tech*. 1999;3:19-22.
19. Lima M, Domini M, Libri M, et al. Laparoscopic repair of Morgagni-Larrey hernia in a child. *J Pediatr Surg*. 2000;35:1266-1268.
20. Soylyu H, Koltuksuz U, Kutlu NO, et al. Morgagni Hernia: an unexpected cause of respiratory complaints and a chest Mass. *Pediatr Pulmonology* 2000;30:429-433.
21. Lima M, Lauro V, Domini M, et al. Laparoscopic surgery of diaphragmatic diseases in children: our experience with five cases. *Eur J Pediatr Surg* 2001;11:377-381.
22. De Vogelaere KE, de Backer A, Delvaux G. Laparoscopic Repair of Diaphragmatic Morgagni Hernia. *J Laparoendosc Adv Surg Tech*. 2002;12:457-460.
23. Ponsky T, Lukish JR, Nobuhara K, et al. Laparoscopy is useful in the diagnosis and management of Foramen of Morgagni hernia in children. *Surg Laparosc Endosc Percutan Tech*. 2002;12:375–377.
24. De Voelaere K. Laparoscopic repair of Morgagni diaphragmatic hernia. *Surg Laparosc Endosc Percutan Tech*. 2003;13:401-403.
25. Azzie G, Maoate K, Beasley S, et al. A simple technique of laparoscopic full-thickness anterior abdominal wall repair of retrosternal (Morgagni) hernias. *J Pediatr Surg*. 2003;38:768-770.

26. Ozmen V, Gun F, Polat C, et al. Laparoscopic repair of a Morgagni hernia in a child, a case report. *Surg Laparosc Endosc Percutan Tech.* 2003;13:115-117.
27. Arca MJ, Barnhart DC, Lelli JL, et al. Early experience with minimally invasive repair of congenital diaphragmatic hernias: results and lessons learned. *J Pediatr Surg.* 2003;38:1563-1568.
28. Papia G, Gerstle JT, Langer JC. Laparoscopic repair of Morgagni diaphragmatic hernia in children: technical challenges and results. *Ped Endosurg Inn Tech.* 2004;8:245-249.
29. Holcomb GW, 3rd, Ostlie DJ, Miller KA. Laparoscopic patch repair of diaphragmatic hernias with Surgisis. *J Ped Surg.* 2005;40:E1–E5.
30. Al-Qahtani AR, Almaramhi H. Minimal access surgery in neonates and infants. *J Ped Surg* 2006; 41:910– 913.
31. Akbiyik F, Tiryaki TH, Senel E, et al. Is hernial sac removal necessary? Retrospective evaluation of eight patients with Morgagni hernia in 5 years. *Pediatr Surg Int.* 2006;22:825–827.
32. Korkmaz M, Guvenc BH, Senel U. Minimal access surgical repair of Morgagni hernia: the fate of the unresected hernia sac. *J Laparoendosc Adv Surg Tech.* 2007;17:833-836.
33. Dutta S, Albanese CT. Use of a prosthetic patch for laparoscopic repair of Morgagni diaphragmatic hernia in children. *J Laparoendosc Adv Surg Tech.* 2007;17:391-394.
34. Mallick MS, Alqahtani A. Laparoscopic-assisted repair of Morgagni hernia in children. *J Ped Surg.* 2009;44:1621-1624.
35. Van Nierkerk ML. Laparoscopic repair of Morgagni diaphragmatic hernia in children. *S Afr J Surg.* 2009;47:14-16.
36. Marhuenda C, Guillen G, Sanchez B, et al. Endoscopic repair of late-presenting Morgagni and Bochdalek hernia in Children: case report and review of the literature. *J Laparoendosc Adv Surg Tech.* 2009;19:S95-S101.
37. Shah SR, Wishnew J, Barsness K, et al. Minimally invasive congenital diaphragmatic hernia repair: a 7-year review of one institution's experience. *Surg Endosc.* 2009;23:1265–1271.
38. Anderberg M, Kockum CC, Arnbjornsson E. Morgagni hernia repair in a small child using da Vinci robotic instruments – a case report. *Eur J Pediatr Surg* 2009;19:110–112.
39. Tsui KP, Chan KW, Lee KH. Acute complications of late-presenting congenital diaphragmatic hernia in children: report of 2 cases and review of literature. *HK J Paediatr* 2010;15:157-160.
40. Van De Winkel N, De Vogelaere K, De Backer A. Laparoscopic repair of diaphragmatic Morgagni hernia in children: review of 3 cases. *J Ped Surg.* 2011;46:E23–E26.
41. Akkoyuna I, Keçecioglu M. A new, easy, and safe suturing technique for laparoscopic repair of Morgagni hernias. *J Ped Surg.* 2012;47:1626–1628.
42. Al-Jazaeri A. Simplified technique for minimally invasive repair of congenital diaphragmatic hernia using hollow-needle snare and transthoracic traction stitches. *J Ped Sur.* 2012;47:258–263.
43. Alkhatrawi T, Elsherbini R, Ouslimane D. Laparoscopic repair of Morgagni diaphragmatic hernia in infants and children: do we need to resect the hernia sac?
44. Golden J, Barlow Meade, Mitchell I, et al. Repair of a bilateral Morgagni hernia in a premature, extremely low birth weight infant. *J Ped Surg Case Reports.* 2014;2:145-149.
45. Zouaria M, Jalloulia M, Bendhaoua M, et al. Percutaneous suturing technique and singlesite umbilical laparoscopic repair of a Morgagni hernia: Review of three cases. *Arch de Pe´diatrie* 2015;22:1272-1275.
46. Lamas-Pinheiro R, Pereira J, Carvalho F, et al. Minimally invasive repair of Morgagni hernia – a multicenter case series. *Rev Port Pneumol.* 2016;22:273-278.
47. Esposito C, Escolino M, Varlet F, et al. Technical standardization of laparoscopic repair of Morgagni diaphragmatic hernia in children: results of a multicentric survey on 43 patients. *Surg Endosc.* 2017;31:3320–3325.
48. Eaton S. Combining data from multiple studies: An introduction to meta-analysis in paediatric surgery. *J Ped Surg* 2013;48:281–287.

49. St Peters SD, Valusek PA, Tsao KJ, et al. Abdominal complications related to type of repair for congenital diaphragmatic hernia. *J Surg Res* 2007;140:234-236.
50. Aydin Y, Altuntas B, Ulas AB, et al. Morgagni Hernia : Transabdominal or Transthoracic Approach? *Acta Chir Belg.* 2014;114:131-135.
51. Vaiquez JJ, Murcia J, DiezPardo JA. Morbid musculoskeletal sequelae of thoracotomy for tracheoesophageal fistula. *J Pediatr Surg* 1995;20:511–4.
52. Durning RP, Scoles PV, Fox OD. Scoliosis after thoracotomy in tracheoesophageal fistula patients. *J Bone Joint Surg Am* 1980;62:1156–1158.

Figure 1: Flow diagram of systematic review of literature in combination with current series
Figure 2: Meta-analysis: recurrence in MH repair comparing open versus MIS repairs
Figure 3: Meta-analysis: recurrence in MH repair comparing patch versus primary repair in patient who underwent MIS repair

Table 1: Current GOSH series of patient who underwent MH repair

Patient number	Age at surgery (months)	Gender	Associated malformations	Diagnostic investigations	Symptoms at presentation	Conversion to open	Type of Patch	Complications	Recurrence	Follow up (months)
1	16 m	M	Exomphalos major	CXR	Recurrent chest infections	No	Bard	No	No	48
2	17 m	F	Trisomy 21	CXR	Bronchiolitis	No	Dacron	No	No	28
3	84 m	M	Trisomy 21	CXR & CT	Recurrent chest infections	No	Bard	No	No	3
4	13 m	M	Gastroschisis	CT	Pectus carinatum	No	Dacron	Port site hernia	No	9
5	17 m	M	Tracheomalacia, Gastroesophageal reflux disease	CXR & CT	Abdominal pain, noisy breathing	No	Bard	No	No	3
6	96 m	F	Trisomy 21, coarctation of aorta, VSD, PDA	CT for other indication	Incidental finding on CT	No	Bard	No	No	3
7	13 m	M	Anorectal malformation, poly- and syndactyly, VSD, PDA	US	Incidental finding on US	No	Bard	Wound infection	No	12
8	18 m	M	No	CXR	Right chest wall indentation	No	Bard	No	No	7
9	22 days	F	Absent corpus callosum, feet	CXR, US	Incidental finding on CXR	No	Bard	No	No	12

			dysmorphisms, ASD							
10	11m	M	No	CXR	Incidental finding on CXR	Yes	Bard	No	No	1
11	2 m	M	No	CXR,CT	Incidental finding on CXR	No	Bard	No	No	9
12	28 m	F	Gastroschisis	CXR,CT	Incidental finding on CXR	No	Bard	No	No	3

M = male, F = female, CXR = chest x-ray, CT = computed tomography, VSD = ventricular septal defect, PDA = patent ductus arteriosus

Table 2: Comparative series of Morgagni hernia in children in the literature, with the current series, included for systematic review

Author	Year	No. of M H	Reported age (years)	Open		MIS		Recurrence	Complications	Follow-up (months)
				Primary	Patch	Primary	Patch			
Jetley [15]	2011	5	1 (0.25-10)			5		1	0	14.5 (5-84)
		17	1 (0.25-10)	17				1	0	14.5 (5-84)
Laituri [16]	2011	9	0.75 (4mth-14y)			4	5	0	2	Not specified
		8	0.7 (6d-11y)	7	1			0	1	Not specified
Garriboli [14]	2013	10	2m-11y			9	1	4	0	36 (5-48)
		2	2m-11y	2				1	0	36 (5-48)
Al-Salem [13]	2014	24	1.25 (0.67-3.5)			24		0	0	Not specified
		28	0.77 (0.1-5)	28				2	1	Not specified
Golden [17]	2017	16	1.75 (0.1-13)			14	2	0	0	37.5 (2-108)
		8	0.2 (1wk-20mth)	6	2			0	2	37.5 (2-108)
Current series	2017	12	1.25 (22d-7y)				11	0	2	23 (1-48)
		1	1.25 (22d-7y)		1			0	0	23 (1-48)
Total		139		60	4	56	19	9	8	

Table 3: Case series and case reports of Morgagni hernia in children in the literature, included for systematic review

Author	Year	No. of patients	Age at surgery	Open		MIS		Recurrence	Complications	Follow-up (months)
				Primary	Patch	Primary	Patch			
Becmeur [18]	1999	1	11y				1	0	0	12
Lima [19]	2000	1	5y			1		0	0	6
Soylu [20]	2000	7	Mean 1.7y (0.5-7y)	7				0	0	Not specified
Lima [21]	2001	2	2-3y			2		0	0	3-12
de Vogelaere [22]	2002	1	5y			1		0	0	12
Ponsky [23]	2002	1	3y			1		0	0	6
De Vogelaere [24]	2003	1	0.7y			1		0	0	12
Azzie [25]	2003	4	Median 1.2y (0.9-1.5y)			4		0	2	1-11
Ozmen [26]	2003	1	4y			1		0	0	2
Arca [27]	2003	11	Median 0.9y (3d-2y)			10	1	1	0	2-18
Papia [28]	2004	3	Median 5y (1-9y)			3		0	0	Not specified
Holcomb [29]	2005	2	0.75-13y				2	0	0	24-48
Al-Qahtani [30]	2006	1	0.5y			1		0	0	6
Akbiyik [31]	2006	8	0.3-9y	8				0	0	2-40
Korkmaz [32]	2007	1	7y			1		0	1	4
Dutta [33]	2007	7	Median 3y (1.7-				7	0	0	13-28

			12y)							
Mallick [34]	2009	15	1.8y			15		0	0	20
van Niekerk [35]	2009	4	Median 1.5y (1-9y)			3	1	0	1	24-88
Marhueda [36]	2009	1	2.5y			1		0	0	6
Shah [37]	2009	5	Median 1y (1-6y)			5		0	0	12-48
Anderberg [38]	2009	1	1.5y			1		0	0	12
Tsui [39]	2010	1	3y			1		0	0	9
van De Winkel [40]	2011	3	0.7, 0.9, 5			3		0	0	3-24
Akkoyun [41]	2012	1	0.5			1		0	0	3
Al-Jazaeri [42]	2012	3	1.5 (0.9 - 3)			3		0	0	7.7-16.5
Alkhatrawi [43]	2012	9	1.3 (0.25-3.2)			9		0	0	32.8 (6-54)
van Niekerk [12]	2013	2	0.75, 2			2		0	0	8-9
Golden [44]	2014	1	14d	1				0	1	24
Zouari [45]	2015	3	0.75, 1.3, 1.5			3		0	0	3-12
Lamas-Pinheiro [46]	2016	13	Mean 1.9 (0.3-4.6)			13		2	0	Mean 56 (9-62)
Esposito [47]	2017	43	Mean 3.3y (1.5-10)			42	1	1	1	50.4
Total		157		16	0	128	13	4	6	

Table 4: Complications associated with MH repair in the literature

Open (N=80)	MIS (N=216)
<ul style="list-style-type: none">• Incisional hernia (2)• Wound infection (2)• Pulmonary haemorrhage associated with prematurity (1)	<ul style="list-style-type: none">• Port site hernia (3)• Port site infection (1)• Stitch abscess in epigastrium (1)• Cardiac arrhythmia from sac eversion (1)• Fluid accumulation between sac and diaphragm (1)• Inadvertent pleural opening (1)• Small bowel obstruction (1)

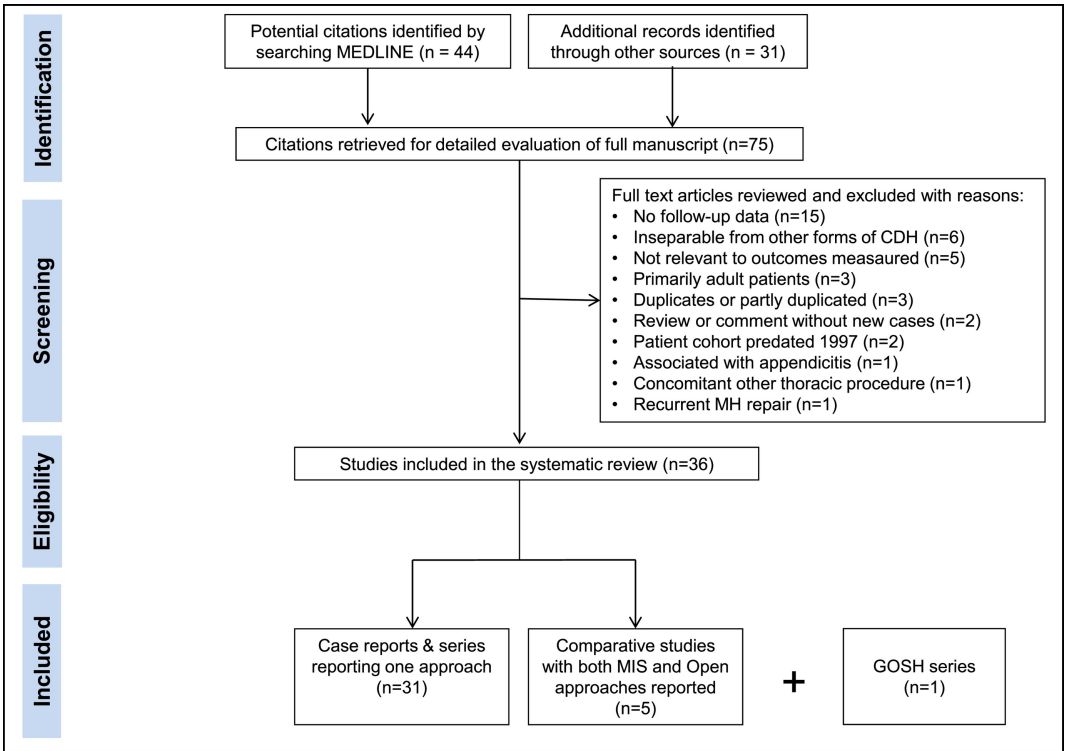


Figure 1

Study or Subgroup	Open		MIS		Weight	Risk Difference
	Events	Total	Events	Total		M-H, Fixed, 95% CI
Jetley 2011	1	17	1	5	13.3%	-0.14 [-0.51, 0.23]
Laituri 2011	1	8	2	9	14.6%	-0.10 [-0.45, 0.26]
Golden 2017	0	8	0	16	18.4%	0.00 [-0.17, 0.17]
Al-Salem 2014	2	28	0	24	44.6%	0.07 [-0.04, 0.19]
GOSH 2017	1	3	4	22	9.1%	0.15 [-0.41, 0.71]
Total (95% CI)		64		76	100.0%	0.01 [-0.10, 0.12]
Total events	5		7			
Heterogeneity: $\text{Chi}^2 = 2.29$, $\text{df} = 4$ ($P = 0.68$); $I^2 = 0\%$						
Test for overall effect: $Z = 0.23$ ($P = 0.82$)						

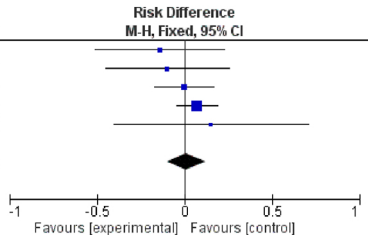


Figure 2

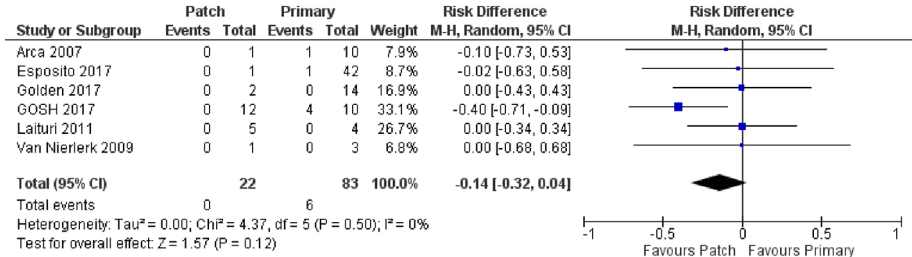


Figure 3