



## 3D printing and high tibial osteotomy

Gareth G. Jones  
Martin Jaere  
Susannah Clarke  
Justin Cobb

- High tibial osteotomy (HTO) is a relatively conservative surgical option in the management of medial knee pain. Thus far, the outcomes have been variable, and apparently worse than the arthroplasty alternatives when judged using conventional metrics, owing in large part to uncertainty around the extent of the correction planned and achieved.
- This review paper introduces the concept of detailed 3D planning of the procedure, and describes the 3D printing technology that enables the plan to be performed.
- The different ways that the osteotomy can be undertaken, and the varying guide designs that enable accurate registration are discussed and described. The system accuracy is reported.
- In keeping with other assistive technologies, 3D printing enables the surgeon to achieve a preoperative plan with a degree of accuracy that is not possible using conventional instruments. With the advent of low dose CT, it has been possible to confirm that the procedure has been undertaken accurately too.
- HTO is the 'ultimate' personal intervention: the amount of correction needed for optimal offloading is not yet completely understood.
- For the athletic person with early medial joint line overload who still runs and enjoys life, HTO using 3D printing is an attractive option. The clinical effectiveness remains unproven.

**Keywords:** high tibial osteotomy; osteotomy; osteoarthritis; patient-specific instrumentation; patient-specific guides; 3D printing

Cite this article: *EFORT Open Rev* 2018;3  
DOI: 10.1302/2058-5241.3.170075.

### Introduction

High tibial osteotomy (HTO) is typically used to treat early isolated medial tibiofemoral compartment osteoarthritis

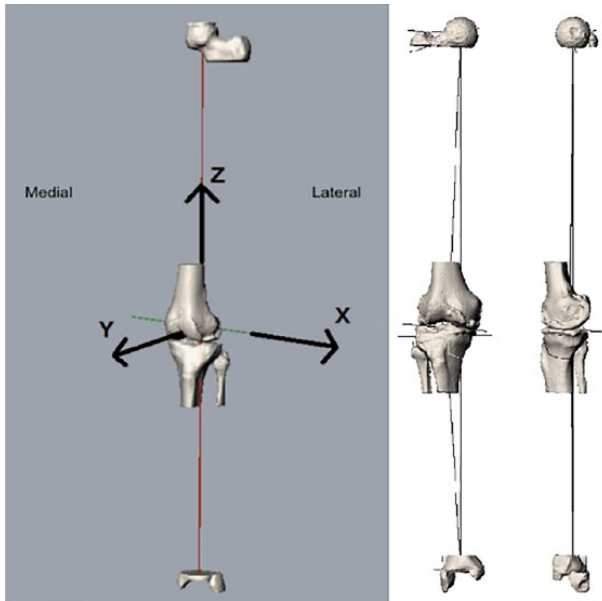
in younger, and physically active, patients for whom knee arthroplasty is associated with higher revision rates.<sup>1,2</sup> The strong relationship between varus malalignment and knee osteoarthritis (gonarthrosis) indicates that if performed early enough, HTO also has the potential to delay, or even possibly prevent, development of end-stage disease.<sup>3</sup>

Whilst the advent of angular stable locking-plate technology has led to a relative increase in the use of HTO, it still accounted for less than 1.5% of procedures recorded in the most recent Swedish Knee Arthroplasty Register.<sup>4</sup> The reasons for this are multifactorial. However, two key factors are evident: outside of specialist centres the procedure is associated with relatively poor survivorship, and there is a high rate of local complications.<sup>5,6</sup> This is unsurprising given that it is a procedure with a small tolerance for error; the degree of angular correction in the coronal plane is considered critical to the operation's long-term success, and current surgical techniques rely on basic tools such as diathermy cables to achieve a 2D plan.<sup>7</sup> Similarly, small errors in osteotomy positioning can lead to local complications such as hinge fractures.<sup>8</sup>

Assistive technology in the form of 3D printed patient-specific instrumentation (PSI) is one method of addressing the need for accuracy in HTO planning and execution, especially for inexperienced surgeons and low-volume centres. The encouraging results reported in a proof of concept study of PSI for osteotomies around the knee by Victor and Premanathan<sup>9</sup> suggests that it is a solution that merits further focus. This review article explores the use of PSI for HTO, including our experience with this technology in the MSk lab at Imperial College London, United Kingdom.

### Preoperative planning

Double-limb weight-bearing anteroposterior view radiographs are considered the benchmark for measuring the mechanical leg axis (hip-knee-ankle angle [HKA]), and are used to plan HTOs.<sup>10</sup> However, it has long been



**Fig. 1** CT scan-derived 3D bone model reliably orientated in space according to established frames of reference.

recognized that HKA measurement varies depending on both knee rotation and flexion, meaning that errors will be introduced if the leg is not consistently positioned preoperatively, intraoperatively and postoperatively.<sup>11,12</sup> It is also possible to determine from radiographic plans where along the anteroposterior tibia a surgeon should measure the calculated osteotomy opening distance, which is necessary if the desired angular correction is to be achieved in both the sagittal and coronal planes.<sup>13</sup>

3D preoperative planning (CT or MRI based), which is the precursor to the production of PSI for HTO, overcomes these issues. In our laboratory a low-dose CT scan of the

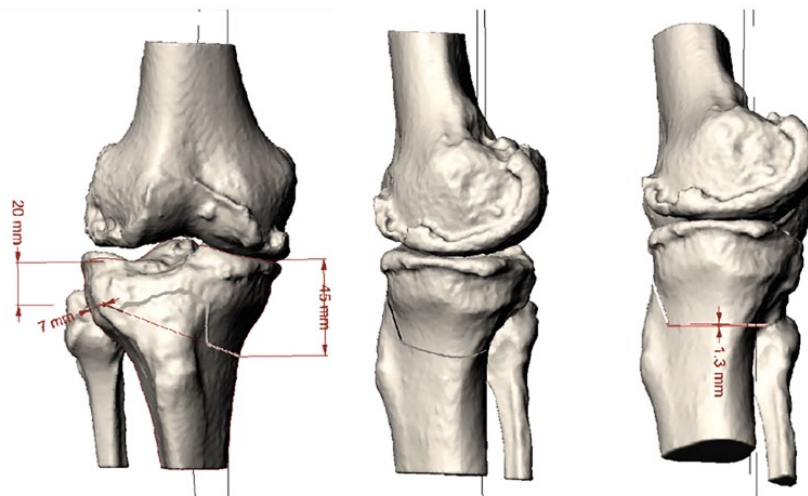
hips, knees and ankles, is obtained according to our established protocol (others are available).<sup>14</sup> The scans are then segmented using commercially available software (Mimics; Materialise NV, Leuven, Belgium) to produce a 3D bone model. To ensure reliable and repeatable HTO planning this model is then positioned in space using established frames of reference; the tibial mechanical axis in the Z plane, and the anatomical tibial axis in the X and Y planes<sup>15</sup> (Fig. 1). Deformity analysis is performed using the sagittal and coronal plane measurements as described by Paley and Pfeil,<sup>16</sup> modified for use in a 3D model, to confirm that a HTO is indicated, and to determine the desired correction in the medial proximal tibial angle and posterior proximal tibial angle.

Using 3D HTO planning software (in our case a Grasshopper script for Rhino software [Robert McNeel & Associates; Seattle, Washington]), a virtual osteotomy cut can then be created in the proximal tibia, with a thickness of bone removed equivalent to that of the intended sawblade (Fig. 2). The starting point for the osteotomy, along with the desired hinge axis, can be positioned according to preference. Simulated opening of the osteotomy is then performed around the hinge point until the desired angular correction in the coronal, sagittal, and occasionally axial, planes is achieved (Fig. 3).

## Guide design

The next challenge is translating this 3D surgical plan to the operating table accurately and economically; a task for which additive layer manufacturing of PSI appears well suited, although a robot could also deliver the required accuracy.<sup>17</sup>

In general, two HTO PSI design philosophies exist. The first PSI design (Materialise) used by Victor and



**Fig. 2** A virtual biplanar osteotomy cut is made using a known sawblade thickness.

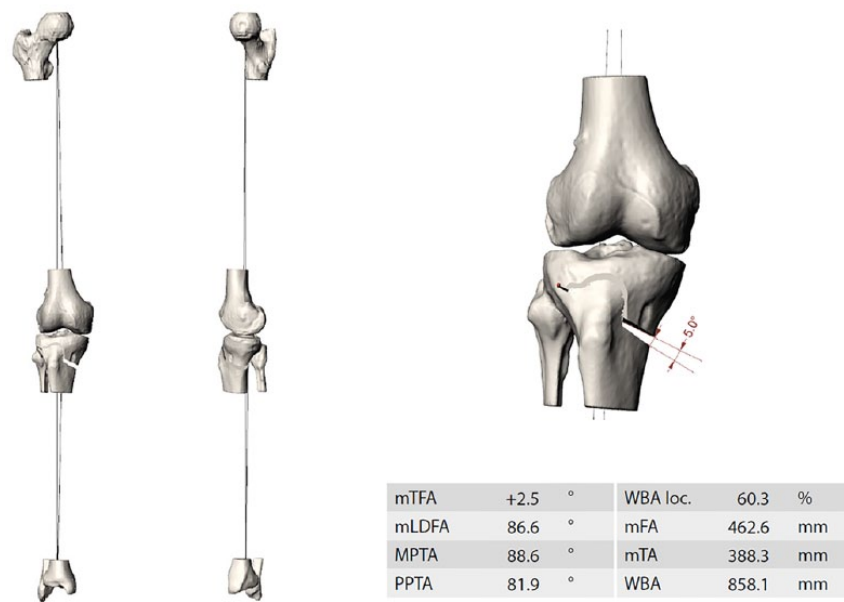


Fig. 3 Simulated opening of the osteotomy until the desired angular correction (coronal, sagittal +/- axial planes) is achieved.

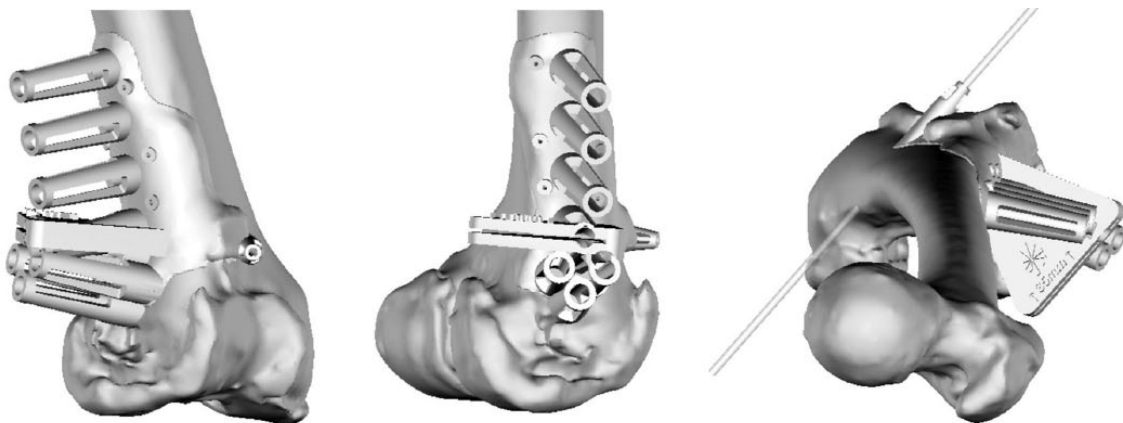


Fig. 4 Virtual example, albeit for a distal femoral osteotomy, of the patient-specific instrument design philosophy used by Materialise (Leuven, Belgium) to guide a plate's screw positions, as well as cut position and direction (reproduced with permission from The British Editorial Society of Bone & Joint Surgery).<sup>9</sup>

Premanathan,<sup>9</sup> and also recently introduced by Newclip Technics (Nantes, France), aims to guide the placement of drill holes in the tibia, relying only on local bone references, i.e. the contour of the underlying bone, to position the guide. A saw cut is then performed through the guide, and the osteotomy opened in a conventional manner until the drill holes line up with holes in the chosen fixation plate, thereby confirming angular correction (Fig. 4).

The advantage of this design is that if correctly located, the drill holes should very accurately guide the planned angular correction. The principal limitation is that it

requires a larger than normal skin incision and soft-tissue dissection. This is because the PSI needs to be almost the same length as the fixation plate in order to guide the drill holes, and the underlying bone in the proximal tibia is relatively featureless, which means that the surface area of the guide needs to be correspondingly large to ensure accurate placement. This is contrary to the minimally-invasive plate osteosynthesis technique used by most expert osteotomy surgeons, with a small skin incision to perform the osteotomy, and separate stab skin incisions to insert the distal screws.<sup>18</sup> Theoretically this reduces the incidence of wound problems, and lowers the risk of



**Fig. 5** Patient-specific distant landmarks (malleoli [blue circle] and fibular head [green circle]) are used in addition to local bony landmarks on the proximal tibia (red circle) to aid global positioning of the guide. Once positioned, Kirschner-wires can be inserted through the patient-specific instrument to guide the osteotomy according to the preoperative plan.

delayed union and nonunion,<sup>19</sup> although Victor and Premanathan's only case of delayed union (out of 14 patients) was a multi-planar distal femoral osteotomy in a heavy smoker.<sup>9</sup>

In contrast, the HTO PSI design philosophy pursued by a spin-off company in our laboratory (Embody; London, United Kingdom) uses distant bony landmarks, in the form of the medial and lateral malleoli, and fibular head, to help initial positioning of the guide. These patient-specific distant landmarks help with global positioning of the guide, and mean that the footprint of the cutting guide resting on the bony contour of the proximal tibia can be relatively small, and *ipso facto* can be used via a standard minimally-invasive HTO skin incision. Once secured in position, three 3.5 mm pins are inserted either

side of the osteotomy using the guide. Depending on surgeon preference, the planned osteotomy can then either be performed through a slot in the guide, or the guide can be used to position Kirschner-wires under which the saw cut is performed after PSI removal (Fig. 5). The osteotomy is then opened in a conventional manner until a patient-specific 'correction block' can be placed onto the 3.5 mm pins – confirming and maintaining the planned angular correction in all three planes until plate fixation has been performed (Fig. 6).

As well as its suitability for use through a standard minimally-invasive incision, this approach allows the surgeon freedom to use the plate of his/her choice, and position this plate intraoperatively. The potential downside is that more steps are involved, and attainment of the planned correction is reliant on the 'correction block' and three pins, which might be less accurate than using pre-determined screw holes for a plate fixator.

### Guide production and sterilization

Once designed, the PSI is built using additive layer manufacturing (3D printing). The most commonly used material is nylon, which is attractive because it is biochemically inert, and both the raw material and medical grade nylon 3D printers are relatively cheap. Once printed, the nylon guides can be safely sterilized in a standard fashion using a steam autoclave, in accordance with International Organization for Standardization (ISO) 17665 guidelines.<sup>20</sup>

### Results

A recent systematic review of studies reporting on whether their postoperative correction was within an 'acceptable range' (determined by the authors of each paper, and



**Fig. 6** The desired angular correction is achieved and maintained by the positioning of a patient-specific 'correction block' onto the 3.5 mm pins. This remains in situ during plate fixation.

very variable) concluded that ‘modern HTO operations seem to bear a surprisingly low accuracy with respect to the targeted angle’ and stress the importance of ongoing efforts to improve accuracy in modern HTO.<sup>22</sup> It is perhaps telling that very few HTO papers report on whether they achieved their intended correction, preferring to report mean angular corrections, which can be misleading. A retrospective review by Marti et al<sup>22</sup> looked at this relationship and found that their planned correction was only achieved in 16 out of 32 cases, even allowing for a 5% error (correction was measured using tibial width).

In this context, the results from Victor and Premanathan’s proof of concept study for osteotomies around the knee using PSI are encouraging, with mean deviation between the planned wedge angle and the executed angle of 0° (-1 to 1, SD 0.72) in the coronal plane and 0.3° (-0.9 to 3, SD 1.14) in the sagittal plane.<sup>9</sup> Albeit, the postoperative measurements were made using 2D radiographs, which introduces a potential source of error.<sup>23</sup> A soon to be published study from our laboratory of 18 HTOs performed by expert surgeons using Embody PSI through a standard skin incision, found the mean angular correction to be within 3° of the 3D preoperative plan in all three planes (determined using postoperative CT scans).

## Discussion

HTO is an effective joint-preserving procedure for younger patients with isolated tibiofemoral compartment arthritis. Indeed, in 50- to 60-year-olds, Markov modelling suggests that HTO has a higher likelihood of being cost effective than both unicompartmental and total knee arthroplasty.<sup>5,24</sup> Given the existing gap between the need and provision for knee arthroplasty surgery, and with the prevalence of gonarthrosis widely predicted to rise, HTO might also have an important role to play in the primary prevention of end-stage disease, both as an adjunct in the treatment of meniscal and ligamentous pathology, and potentially as a means of delaying or preventing the progression of arthritis in the varus knee.<sup>25,26</sup>

However, before HTO becomes mainstream, the procedure needs to be reliable, and the early indications are that PSI is capable of delivering a higher level of accuracy in angular correction than conventional techniques. As discussed above, the 3D planning process also has inherent advantages over 2D radiographs, facilitating reliable measurements, simple planning of deformity correction in more than one plane and the potential to customize osteotomy geometry in an effort to maximize the cut bone surface area available for healing.

PSI is not without disadvantages. Patients require additional imaging in the form of an MRI, or more usually a CT scan. This introduces extra cost (approximately £78 for a CT compared with £25 for a radiograph using current

United Kingdom NHS tariffs),<sup>27</sup> and extra radiation for the patient. However, novel low-dose radiation CT protocols, which include the hip and ankle, have been shown to be comparable in radiation dose to long-leg radiographs.<sup>14</sup> Whilst 3D planning has numerous advantages, it should be remembered that supine and weight-bearing HKA angles differ, which must be considered when calculating the desired angular correction, and may introduce error. We are exploring the use of merged 2D weight-bearing and supine 3D images to overcome this problem, although the solution may lie in the use of EOS scans, or cone beam CT technology to obtain weight-bearing 3D images. The caveat here is that even with weight-bearing images it is unclear what the ideal angular correction is for HTO, and in the future, planning is likely to use a combination of static radiographs and dynamic gait data.

Drawbacks common to PSI for both arthroplasty and HTO include the need for engineers to segment the CT/MRI scan and produce a surgical plan, the cost of which is difficult to quantify as it depends on the degree of automation involved. Yet as automation inevitably increases, prices are likely to fall. To optimize results, surgeons also need to engage with the operative planning process, as is the case with conventional HTO planning, with the added advantage that PSI may improve theatre efficiency. In surgical practices with short waiting times, the turnaround for the design and production of PSI for HTO might be problematic, although with an onsite 3D printer, this can be as short as 24 hours if required urgently.

## Conclusions

It is uncertain what level of accuracy is required for HTO surgery. However, preliminary results suggest that PSI, in the hands of expert surgeons, is more accurate than conventional techniques. 3D planning and PSI also facilitate multi-planar angular corrections, which are particularly challenging using conventional techniques. The real test will be whether PSI can deliver similar levels of accuracy in low-volume units or by inexperienced surgeons, and if long-term clinical studies establish whether improved accuracy is associated with excellent clinical outcomes.

### AUTHOR INFORMATION

MSk Lab, Imperial College London, London, UK.

Correspondence should be sent to: Gareth G. Jones, MSk Lab, Imperial College London, 7th Floor Lab Block, Charing Cross Hospital, London, W6 8RF, United Kingdom.

Email: ggjones@imperial.ac.uk

### ICMJE CONFLICT OF INTEREST STATEMENT

G. Jones declares grants from The Frances and Augustus Newman Foundation, and from The Michael Uren Foundation, activity relating to the submitted work. M. Jaere

declares consultancy for Embody Orthopaedic, activity outside the submitted work. S. Clarke declares provision of equipment from Embody Orthopaedic, activity relating to the submitted work; board membership, royalties and stocks/stock options from Embody Orthopaedic, activity outside the submitted work. J. Cobb declares grant funding from the Michael Uren Foundation, activity relating to the submitted work; patents and stocks/stock options for Embody Orthopaedic, activity outside the submitted work.

#### FUNDING STATEMENT

The author or one or more of the authors have received or will receive benefits for personal or professional use from a commercial party related directly or indirectly to the subject of this article.

#### LICENCE

© 2018 The author(s)

This article is distributed under the terms of the Creative Commons Attribution-Non Commercial 4.0 International (CC BY-NC 4.0) licence (<https://creativecommons.org/licenses/by-nc/4.0/>) which permits non-commercial use, reproduction and distribution of the work without further permission provided the original work is attributed.

#### REFERENCES

1. Brinkman J-M, Lobenhoffer P, Agneskirchner JD, et al. Osteotomies around the knee: patient selection, stability of fixation and bone healing in high tibial osteotomies. *J Bone Joint Surg [Br]* 2008;90-B:1548-1557.
2. Hip and Knee Arthroplasty Annual Report 2015. Australian Orthopaedic Association National Joint Replacement Registry, 2015. <https://aoanjrr.sahmri.com/documents/10180/217745/Hip%20and%20Knee%20Arthroplasty> (date last accessed 3 December 2017).
3. Brouwer GM, van Tol AW, Bergink AP, et al. Association between valgus and varus alignment and the development and progression of radiographic osteoarthritis of the knee. *Arthritis Rheum* 2007;56:1204-1211.
4. No authors listed. Annual Report 2017 - Swedish Knee Arthroplasty Register. [www.icagruppen.se/globalassets/rapportportal/arsredovisning-2016/01.-omslag/ica-gruppen\\_annual\\_report\\_2016.pdf](http://www.icagruppen.se/globalassets/rapportportal/arsredovisning-2016/01.-omslag/ica-gruppen_annual_report_2016.pdf) (date last accessed 10 January 2018).
5. Konopka JF, Gomoll AH, Thornhill TS, Katz JN, Losina E. The cost-effectiveness of surgical treatment of medial unicompartmental knee osteoarthritis in younger patients: a computer model-based evaluation. *J Bone Joint Surg [Am]* 2015;97:807-817.
6. Martin R, Birmingham TB, Willits K, et al. Adverse event rates and classifications in medial opening wedge high tibial osteotomy. *Am J Sports Med* 2014;42:1118-1126.
7. Sprenger TR, Doerzbacher JF. Tibial osteotomy for the treatment of varus gonarthrosis. Survival and failure analysis to twenty-two years. *J Bone Joint Surg [Am]* 2003;85-A:469-474.
8. Han SB, Lee DH, Shetty GM, et al. A "safe zone" in medial open-wedge high tibia osteotomy to prevent lateral cortex fracture. *Knee Surg Sports Traumatol Arthrosc* 2013;21:90-95.
9. Victor J, Premanathan A. Virtual 3D planning and patient specific surgical guides for osteotomies around the knee: a feasibility and proof-of-concept study. *Bone Joint J* 2013;95-B(11 Suppl A):153-158.
10. Sharma L, Song J, Felson DT, et al. The role of knee alignment in disease progression and functional decline in knee osteoarthritis. *JAMA* 2001;286:188-195.
11. Swanson KE, Stocks GW, Warren PD, Hazel MR, Janssen HF. Does axial limb rotation affect the alignment measurements in deformed limbs? *Clin Orthop Relat Res* 2000;371:246-252.
12. Koshino T, Takeyama M, Jiang LS, Yoshida T, Saito T. Underestimation of varus angulation in knees with flexion deformity. *Knee* 2002;9:275-279.
13. Noyes FR, Goebel SX, West J. Opening wedge tibial osteotomy: the 3-triangle method to correct axial alignment and tibial slope. *Am J Sports Med* 2005;33:378-387.
14. Henckel J, Richards R, Lozhkin K, et al. Very low-dose computed tomography for planning and outcome measurement in knee replacement. The imperial knee protocol. *J Bone Joint Surg [Br]* 2006;88-B:1513-1518.
15. Cobb JP, Dixon H, Dandachli W, Iranpour F. The anatomical tibial axis: reliable rotational orientation in knee replacement. *J Bone Joint Surg [Br]* 2008;90-B:1032-1038.
16. Paley D, Pfeil J. Principles of deformity correction around the knee. *Orthopade* 2000;29:18-38.
17. Maillet P, Nahum B, Blondel L, Poignet P, Dombre E. BRIGIT, a robotized tool guide for orthopedic surgery. <http://ieeexplore.ieee.org/document/1570121/> (date last accessed 10 January 2018).
18. Endo H, Asaumi K, Mitani S, et al. The minimally invasive plate osteosynthesis (MIPO) technique with a locking compression plate for femoral lengthening. *Acta Med Okayama* 2008;62:333-339.
19. Li Q, Zeng BF, Luo CF, et al. Limited open reduction is better for simple-distal tibial shaft fractures than minimally invasive plate osteosynthesis. *Genet Mol Res* 2014;13:5361-5368.
20. International Organization for Standardization. Sterilization of health care products – Moist heat – Part 1: Requirements for the development, validation and routine control of a sterilization process for medical devices (ISO Standard Number 17665), 2016. <https://www.iso.org/standard/43187.html> (date last accessed 30 January 2018).
21. Van den Bempt M, Van Genechten W, Claes T, Claes S. How accurately does high tibial osteotomy correct the mechanical axis of an arthritic varus knee? A systematic review. *Knee* 2016;23:925-935.
22. Marti CB, Gautier E, Wachtl SW, Jakob RP. Accuracy of Frontal and Sagittal Plane Correction in Open-Wedge High Tibial Osteotomy. *Arthrosc - J Arthrosc Relat Surg* 2004;20:366-372.
23. Kawakami H, Sugano N, Yonenobu K, et al. Effects of rotation on measurement of lower limb alignment for knee osteotomy. *J Orthop Res* 2004;22:1248-1253.
24. Smith WBII, Steinberg J, Scholtes S, Mcnamara IR. Medial compartment knee osteoarthritis: age-stratified cost-effectiveness of total knee arthroplasty, unicompartmental knee arthroplasty, and high tibial osteotomy. *Knee Surg Sport Traumatol Arthrosc* 2015;25:924-933.
25. Culliford DJ, Maskell J, Kiran A, et al. The lifetime risk of total hip and knee arthroplasty: results from the UK general practice research database. *Osteoarthritis Cartilage* 2012;20:519-524.
26. Arthritis Research UK. Osteoarthritis in general practice. *Med Pr* 2013;222:253-258.
27. NICE. Costing Tool: Osteoarthritis Implementing the NICE Guideline on Osteoarthritis (CG177) Putting NICE Guidance into Practice. <https://www.nice.org.uk/guidance/cg177/resources/costing-report-pdf-191756125> (date last accessed 3 December 2017).