



Swansea University  
Prifysgol Abertawe



## Cronfa - Swansea University Open Access Repository

---

This is an author produced version of a paper published in:

*MedEdPublish*

Cronfa URL for this paper:

<http://cronfa.swan.ac.uk/Record/cronfa40528>

---

### Paper:

Galusko, V., Bodger, O., Rees, E. & Ionescu, A. (2018). Hand-held ultrasonography: An opportunity for “hands-on” teaching of medicine. *MedEdPublish*, 7(2)

<http://dx.doi.org/10.15694/mep.2018.0000103.1>

---

This item is brought to you by Swansea University. Any person downloading material is agreeing to abide by the terms of the repository licence. Copies of full text items may be used or reproduced in any format or medium, without prior permission for personal research or study, educational or non-commercial purposes only. The copyright for any work remains with the original author unless otherwise specified. The full-text must not be sold in any format or medium without the formal permission of the copyright holder.

Permission for multiple reproductions should be obtained from the original author.

Authors are personally responsible for adhering to copyright and publisher restrictions when uploading content to the repository.

<http://www.swansea.ac.uk/library/researchsupport/ris-support/>

# Hand-held ultrasonography: An opportunity for “hands-on” teaching of medicine

Victor Galusko[1], Owen Bodger[2], Emma Rees[3], Adrian Ionescu[4]

**Corresponding author:** Dr Victor Galusko vgalusko91@gmail.com

**Institution:** 1. Swansea University Medical School, Swansea, 2. Swansea University Medical School, Swansea, 3. College of Human and Health Sciences, Swansea University, Swansea, 4. Morriston Cardiac Regional Centre, ABMU LHB, Swansea

**Categories:** Educational Strategies, Research in Medical Education, Teaching and Learning

Received: 25/04/2018

Published: 16/05/2018

## Abstract

**Background:** As ultrasound offers students an opportunity to study anatomy, physiology and pathophysiology actively, we used hand-held ultrasound (HHU) devices to augment current teaching of cardiac murmurs and pathology.

**Methods:** Three types of teaching sessions (of different duration) were explored: 1) compulsory teaching on cardiac murmurs (n=40); 2) extra-curricular teaching of cardiac murmurs (n=8); 3) extra-curricular ultrasound course (n=6). We assessed students' ability to identify valvular lesions on auscultation, and anatomy and pathology on echocardiography, and sought qualitative feedback.

**Results:** Using echocardiography to teach murmurs improved murmur recognition by auscultation alone from 23% pre-test to 93% post-test ( $p=0.017$ ). Students were able to identify major cardiac anatomical landmarks on echo images (57% vs 98% ( $p=0.027$ )) in the voluntary teaching session lasting 90 minutes, and 40% vs 82% ( $p=0.027$ ) after the 3 week cardiac ultrasound course. The mean accuracy for diagnosing cardiac pathology on a printed image alone after the 3 week ultrasound course was 71%. Students unanimously found the sessions useful and engaging, and reported they would like further teaching about using ultrasound.

**Conclusion:** Medical students found the sessions engaging, enjoyed this novel way of teaching and would like further teaching using ultrasound. Using hand-held ultrasound scanners to augment the teaching of cardiac murmurs to medical students is feasible and effective.

**Keywords:** Hand-held ultrasound, undergraduate medical education, echocardiography

## Introduction

---

In the hands of a trained user, a hand-held ultrasound (HHU) device offers quick, accurate<sup>(1)(2)</sup> and cost-effective clinical assessment<sup>(3)</sup> by providing point-of-care ultrasound (POCUS) imaging<sup>(4)(5)</sup>, which is often sufficient to change patient management<sup>(5)(6)</sup>. As HHU use in clinical practice expands, doctors in training would benefit from early exposure to HHU scanning, and from acquisition of the skills to use HHU.

Many medical schools have already integrated ultrasound teaching into their curricula using high-end ultrasound devices<sup>(7)(8)</sup>, and a "national ultrasound curriculum" has been developed in the USA<sup>(9)</sup>. In the UK, the lack of allocated time in medical curricula and the absence of funding make such changes hard to implement<sup>(10)(11)</sup>. HHU devices are cheaper, easier to operate, and are more portable than high-end, stationary ultrasound equipment, and therefore have the potential to assist the integration of ultrasound into medical school curricula.

The European Association of Echocardiography<sup>(12)</sup> supports the use of HHU in medical education; however, the literature available on the topic is limited. The published use of HHU devices has focused on teaching medical students to recognise a small number of mainly cardiac pathologies<sup>(13)(14)(15)(16)</sup>. Few publications report the use of HHU to teach other organ areas<sup>(16)(17)</sup>. Formal ultrasound imaging has been successfully used to improve the medical students' knowledge of living anatomy and physiology<sup>(11)(18)</sup>, as well as their motivation to learn<sup>(19)</sup>. Whether the same is true for HHU, is not known.

Most of the published studies report the use of radiologists, cardiac sonographers and cardiologists to teach ultrasound to medical students. We set out to assess the feasibility of using a final-year medical student to teach the basics of cardiac ultrasound and to augment the teaching of cardiac murmurs using HHU, and we assessed the impact of HHU on student performance.

## Methods

---

### *Structure of the teaching sessions*

We conducted a systematic literature review on the use of HHU in medical education (in press) to inform the structure and objectives of the teaching sessions. We investigated the feasibility and views of medical students on the use of HHU to deliver cardiovascular teaching. To do this we conducted three teaching sessions of differing lengths - Table 1 summarises the three teaching sessions, their learning objectives and participant characteristics. The sessions varied in length, and therefore the depth of the subject cover. This was done to try and ascertain the depth of knowledge that needs to be delivered, and how best to deliver it (hands on vs didactic). Full details of the learning objectives are in Appendix 1-3 for the three respective teaching sessions.

### *Using echocardiography to augment understanding of cardiac murmurs*

#### *Session 1*

The session started with a test (Appendix 4). Participants had to label landmarks of cardiac anatomy on printouts of frozen-frames of echocardiographic cross-sections, then they had to listen to various murmurs on a simulator (SimMan, Laerdal Medical Limited, Laerdal House, Orpington, UK) and formulate a diagnosis; finally, they were shown colour-flow mapping video loops illustrating the pathologies they had listened to and had the opportunity to

change their diagnosis in the light of this supplementary information. After a teaching session lasting 1 ½ h and consisting of both didactic lectures and hands-on scanning, participants re-sat the pre-session test, using a different set of images and simulated murmurs.

### ***Using echocardiography to augment understanding of systolic cardiac murmurs***

#### ***Session 2***

The forty students attending the usual clinical skills teaching, were divided into groups of 6-10 students and rotated through the different clinical skills stations. One of these compulsory "stations" was a 25-minute, practical session teaching using the HHU and covering the pathophysiology of systolic murmurs. They gave qualitative feedback as well as free text comments upon completion of the session (Appendix 5).

#### ***Extracurricular HHU course***

##### ***Session 3***

Six students attended a total of five hours of teaching split over three weeks, one session per week. The aim was to familiarise students with echocardiography and its use in medical practice as well as to teach them to identify anatomy on printed echocardiography images, identify basic valvular pathology and severe LV systolic dysfunction. Students completed pre-test and a post-test questionnaires and gave qualitative feedback (Appendix 6a-6b). During the course we trialled projecting the images from the HHU using a high-definition web camera onto a larger screen to facilitate the teaching.

The ethic dimensions of the study were considered and discussed among the authors, and found to be similar to those applying to the standard teaching of clinical skills. This project was exempt from ethics approval at Swansea University because this was an evaluation of a teaching program approved by the Medical School and the principles of the Declaration of Helsinki were followed.

#### ***Facilitator***

One of the authors (VG) who was, at the time, a final-year medical student devised and delivered the teaching sessions. VG received hands-on training in an echocardiography clinic supervised by a cardiologist, supplemented by self-directed learning (SDL) from books.

#### ***Assessment and feedback***

The students provided feedback from the teaching sessions using a questionnaire with free text boxes and multiple choice questions. Appendix 4-6 contains the respective assessments and feedback questionnaires that the students received for the three teaching sessions. The ability of the students to identify cardiac anatomy and pathology on echocardiographic images was assessed in two of the teaching sessions – 1) the 90 minute cardiac murmur teaching session; 2) the 3-week cardiovascular ultrasound course. Only qualitative feedback and free text comments were collected for the 25-minute teaching session on systolic due to time constraints of the clinical skills teaching session. We did not assess students' ability to recognise anatomy and physiology on echo, or their diagnostic ability to identify murmurs.

#### ***HHU scanner***

The Vscan (GE Vingmed Ultrasound AS, Strandpromenaden 45, N-3191 Horten, Norway) uses a phased-array

probe with a frequency range from 1.7 to 3.8 MHz; it weighs 390 g and fits inside a normal pocket. It displays grey-scale images with a fixed sector angle of 75°; the depth can be adjusted up to a 25 cm; colour flow has a fixed box size and a fixed pulse repetition frequency. There are no spectral Doppler capabilities.

### ***Statistical analysis***

Statistical analysis was performed using XLSTAT statistical package (Addinsoft, 28 West 27<sup>th</sup> Street, New York, NY10001) to calculate the *p* values for the data (using Wilcoxon Signed Rank test where appropriate). The values were compared to the significance level of  $p < 0.05$ .

## **Results**

---

### ***Using echocardiography to augment understanding of cardiac murmurs***

#### ***Session 1***

Eight students attended the session, and were taught as a group over an hour and a half. Prior to the teaching, students could correctly identify the anatomy of the heart in the apical 4-chamber (A4C) and parasternal-long axis (PLAX) views in 57% of cases (only one student had exposure to cardiology during a clinical attachment). Labelling of chambers correctly on echocardiography images improved from 57% before the teaching, to 98% ( $p=0.027$ ) after. The average accuracy for identification of murmurs with auscultation alone improved from 29% before the teaching, to 93% afterwards ( $p=0.017$ ). The availability of the echo images did not change the students accuracy of murmur detection during the assessment. All students enjoyed the teaching session, and the feedback showed that they found it relevant and useful (see Table 2 and 3, and Appendix 7).

### ***Using echocardiography to augment understanding of systolic murmurs***

#### ***Session 2***

During the clinical skills session we taught a total of forty students in rotations of 6-10 students at a time (25 minutes per group). They all found it "...useful to have hands-on murmur training" and the HHU allowed for an interactive teaching session with a "good mix of teaching approaches". The live echo images enhanced the understanding of the pathophysiology of murmurs, and the students engaged well by asking questions on murmurs and clinical signs. Feedback from the session is summarised in Table 3. A selection of the comments from the session are given in Appendix 8. In summary, the students want more teaching about and with ultrasound, more hands-on time with the HHU, and more teaching on murmurs and how to pick them up on auscultation.

The time constraints of the session were evident, as many students did not get much "hands-on time" with the HHU device, and the large group size (6-10) did not aid the process. The session was too short for the number of students involved, as not all managed to get hands-on experience with the Vscan. We trialled projecting the HHU images onto a bigger screen using the high-definition web camera to facilitate the teaching, but were unsuccessful as the on-screen resolution was poor.

### ***Extracurricular HHU course***

As feedback from students clearly revealed an appetite for further instruction in cardiac ultrasound imaging, we designed and delivered a 3-week extra-curricular course on echocardiography. The course received overwhelmingly

positive feedback (Table 5 and Appendix 9) from the six student volunteers that attended it. Some of the students reported feeling more at ease with a student facilitator teaching a subject they were not familiar with.

Students developed the skills necessary to acquire and interpret the basic echocardiographic views of the heart (PLAX, PSAX and A4C) using HHU. Their ability to recognise the basic anatomy on an echo image of the heart improved significantly after teaching (40% vs 82% ( $p=0.027$ )). Furthermore, their ability to recognise valvular pathology and severe LV systolic impairment improved from 4.2% to 71% ( $p=0.027$ ). The feedback and assessment results are summarised in Tables 5 and 6.

## Discussion

---

We report that using HHU to teach cardiac murmurs, alone or in addition to simulated cardiac sounds, is feasible and effective. Students were able to correctly recognise up to 93% of murmurs after the teaching, and were able to discern the cardiac anatomy on echocardiography images. Longer teaching sessions (lasting 5 hours) can teach students to recognise correctly identify cardiac pathology in most cases (71%). A trained medical student can act as an effective facilitator pitching the information at the right level, making those taught feel more at ease, and were more likely to ask questions. We received consistently good feedback from the students for both voluntary and compulsory (as part of clinical skills) teaching sessions. As doctors' clinical skills decline<sup>(20)</sup>, the HHU becomes a tool that can both enhance a physical examination<sup>(4)</sup> and improve the teaching of the physical examination and pathology.

### *Group Size and Device Choice*

Students found it hard to see the HHU screen when the groups were large (as large as 10 students), and not everyone had the chance to use the HHU in the available time. We trialled using a high-definition web camera to display images from the HHU on a bigger screen, as previously reported in order to stream images to an off-site expert<sup>(21)</sup>, however we were unsuccessful as this achieved poor on-screen resolution. The 3-week teaching course was conducted using a single HHU device and accommodated 6 students well. A large amount of literature exists about the use of portable, as opposed to HHU, ultrasound in medical education<sup>(22) (23) (24) (25) (26) (27)</sup>. Portable ultrasound equipment is available if larger group sizes need to be taught, some of which can be connected to a larger screen such as a projector<sup>(25)</sup>.

### *Limited availability of qualified trainers, and integrating the changes into the curriculum*

Professionals such as cardiologists, radiologists and clinical scientists are probably best placed to teach ultrasound examination, however they are not readily available. The role of senior medical students and cardiac physiology/cardiac sonography students with prior experience in the area is potentially a fertile area of research<sup>(17) (28)</sup>. As confirmed by the current study, medical students are able to acquire enough experience, and be knowledgeable enough to teach, at least to a basic level of competence.

To help and aid the learning process, a number of free online SDL resources are available, that have been tailored to medical student education, which include podcasts<sup>(17)</sup>, i-books<sup>(29)</sup> and e-modules<sup>(30)</sup>. SDL resources provide a valuable source of information to support learning<sup>(30)</sup>. We suggest universities develop their own resources in the field which are tailored to their curriculum.

### *Where do we go next with HHU?*

Most of literature published to date reports the use of HHU devices to teach medical students to recognise cardiac pathology<sup>(13)(14)(15)(16)</sup>. Figures 2 and 3 illustrate that there are exciting concepts yet to be explored by educators when using ultrasound to teach medical students. The cardiac cycle can be brought to life by studying heart conditions with the aid of simulators and live scanning. Valvular dysfunction and septal defects can be studied using colour-flow mapping, and demonstrating its effects on the physiology of the heart. The jugular venous pulse (JVP) and its changes in patients with tricuspid regurgitation or congestive heart failure are probably relatively easy ‘targets’ for HHU-aided learning that need to be explored by future researchers.

We feel it is preferable to use ultrasound to complement clinical-skill teaching in medical school, rather than to teach the intricacies of ultrasound imaging. Ultrasound can enhance the current teaching by engaging multiple senses and allowing a more individualised self-paced learning experience<sup>(31)</sup>. This allows more effective teaching without necessitating for extra space in the medical school curriculum and would indirectly introduce the students to the basics of ultrasound. Furthermore, ultrasound can improve the students’ clinical knowledge by improving their knowledge of surface anatomy.

Teaching in the early years of medical school often focuses on surface anatomy, anatomy and physiology. Ultrasound can be used to link surface anatomy to the physical examination<sup>(7)(23)</sup> making the teaching clinically relevant, and complement pathology teaching in later years of medical school<sup>(7)</sup>. Unique portability of HHU allows it to be used as a teaching tool both within the clinical lab setting and out in clinical practice.

There is still uncertainty about long-term retention of skills in ultrasound imaging<sup>(32)(33)</sup>, and that may be a reason for which ultrasound teaching is still underdeveloped as its impact on whether it makes for more competent clinicians is unknown. However, as HHU is spreading widely in the medical community, threatening to render the stethoscope obsolete<sup>(34)</sup>, it would be advantageous to become accustomed to this increasingly popular and powerful imaging modality early in a medical career.

## Limitations

---

We only delivered a single ‘cycle’ of HHU-aided teaching involving a limited number of students. The larger of the sessions was compulsory to all medical students whereas the other two were not, and therefore could have attracted only the interested students. Recurring usage over at least one year of study would be ideal before drawing firm conclusions. Ideally, assessing the impact of HHU on teaching medical students should incorporate formal results of tests and exams, or at least a broader array of competencies than we report here. Only then could we say with certainty that it is worthwhile to include HHU as a routine component of medical training

## Conclusion

---

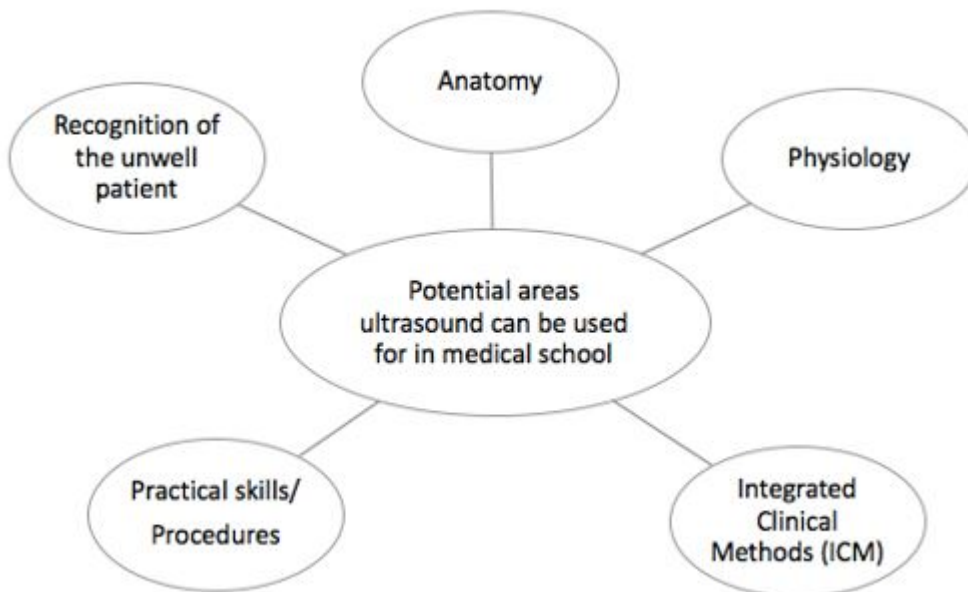
The introduction of HHU as an aid to the teaching of cardiac murmurs markedly improved the accuracy of the clinical diagnosis of heart valve pathology. Students taking part in the teaching sessions found the teaching useful, relevant to their stage of training and understand the potential utility of HHU in their future clinical career. The resolution of the HHU devices appears sufficient for hands-on practice, to image major anatomical landmarks of the heart and to teach valvular pathology. The use of medical students, cardiac physiology students and junior doctors to teach ultrasound appears feasible but requires further research.

## Figures

---

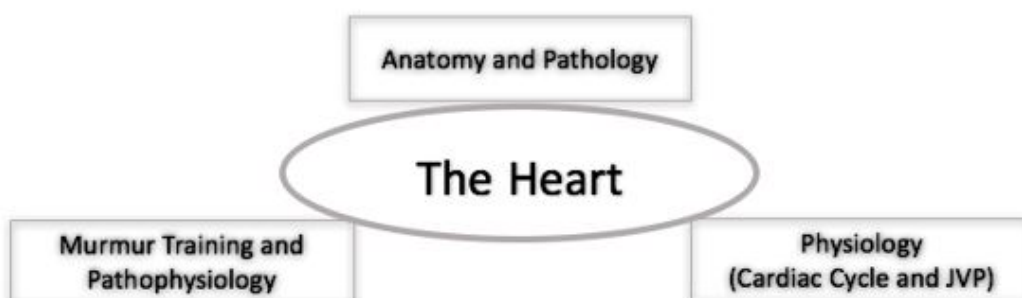
**Figure 1**

*The figure below shows the five broad categories that ultrasound can be used for in medical education, a selection of these was trialled during our teaching sessions described in the report*



**Figure 2**

*Important areas relating to the heart that we suggest should be taught using ultrasound in the curriculum*



## Tables

---

**Table 1**

*Showing the content of the three sessions carried out. The first and third sessions were voluntary, whilst the second*



session was compulsory for all medical students attending clinical skills teaching. Didactic content consisted of a slide show based interactive teaching session, while hands-on sessions involved the students using Vscan to scan and explore the heart and its anatomy on normal subjects

	Using echocardiography to augment understanding of cardiac murmurs – Session 1	Using echocardiography to augment understanding of systolic murmurs – Session 2	Extracurricular HHU course – Session 3
<b>Main learning objectives</b>	To be able to identify the anatomy in PLAX and A4C views. To understand that valvular lesions can be visualised using HHU (focusing on AS, AR, MR and MS); and to link the pathophysiology of valvular lesions to understand the clinical signs they produce	To be able to identify the anatomy in PLAX and A4C views. To understand that valvular lesions can be visualised using HHU (focusing on AS and MR); and to link the pathophysiology of valvular lesions to understand the clinical signs they produce	To be able to identify the anatomy in PLAX, PSAX and A4C. To be able to identify valvular dysfunction (AS, AR, TR, MS, MR), to be able to assess LV function and be able to identify dilated LV
<b>Students</b>	2 <sup>nd</sup> year GEM students at the end of their pre-clinical years	1st year GEM students at the end of their pre-clinical year	GEM students at the end of their 2 <sup>nd</sup> pre-clinical year
<b>Facilitator</b>	Final year medical student		
<b>Duration</b>	90 minutes	25 minutes	5 hours (delivered over 3 weeks)
<b>Percentage of didactic vs hands-on time</b>	45% - hands-on 55% - didactic	80% - hands-on 20% - didactic	50% - hands-on 50% - didactic SDL videos and handouts were freely available to supplement the teaching
<b>Setting</b>	Clinical lab scanning of volunteer students and use of simulation mannequin to produce murmur sounds	Clinical lab scanning of student volunteers	Clinical lab scanning of student volunteers
<b>Assessment</b>	The students labelled echo images in PLAX and A4C; and diagnosed murmurs by listening to four murmur sounds on a mannequin and then looking at an echo clip, marking which murmur they thought it was at each stage (pre- and post- intervention)	Quantitative feedback	Quantitative feedback + ability to interpret printed echo images and the anatomy visualised in PLAX and A4C. Diagnose three valvular lesions and a dilated LV on a printed image.

**Key:** PLAX – parasternal long axis; PSAX – parasternal short axis; A4C – apical 4-chamber; AS – aortic stenosis; AR – aortic regurgitation; MS – mitral stenosis; MR – mitral regurgitation; TR – tricuspid regurgitation; LV – left ventricle; GEM – graduate entry medicine; SDL – self-directed learning

**Table 2**

First teaching session improved the student's ability to identify anatomy correctly on echocardiographic images and to detect valvular lesions by auscultation

	Average Student Score		
Average Student Score	Pre-test	Post-test	p-value
<b>Auscultation</b>	29%	93%	0.017
<b>Auscultation + Echo image</b>	29%	93%	0.017
<b>Chamber Identification</b>	57%	98%	0.027

**Table 3**

*Qualitative feedback from the first teaching session*

<b>Feedback</b>	
<b>Found the session useful</b>	100%
<b>I now feel more confident identifying murmurs</b>	100%
<b>I think HHU will influence my future practice as a clinician</b>	100%
<b>I want more teaching on ultrasound/with ultrasound</b>	100%
<b>I would like further teaching on:</b>	
<b>Jugular Venous Pulse</b>	75%
<b>Cardiac Cycle</b>	75%
<b>Cardiac Anatomy</b>	87.5%

**Table 4**

*Qualitative feedback from the second teaching session*

<b>Feedback</b>	
I found the session useful	100%
I feel I understand more about murmurs and the clinical signs they cause	98%
I feel I understand more about the pathophysiology of murmurs	100%
I feel more confident at interpreting murmurs	90%
I think the use of HHU devices will influence my future practice as a clinician	100%
I would like more teaching on ultrasound	98%

**Table 5**

*Qualitative feedback from the third teaching session*

<b>Feedback</b>	
I found the sessions interesting	100%
I found the sessions useful/relevant to my stage of training	100%
I understand more about the clinical indications for echocardiography, and how it's used in clinical practice	100%
I see how HHU would be useful for me as a future clinician	100%
Improved my anatomy/physiology of the heart	100%
I would like more teaching on echocardiography	29%
The 3-week course was too long	0%

**Table 6**

*After the third teaching session students' scores increased significantly for correct identification of anatomy and detection of pathology in PLAX and A4C*

	<b>Mean student score</b>		
	<b>Pre-test</b>	<b>Post-test</b>	<b>p-value</b>
<b>Identification of anatomy</b>	40.3%	81.9%	0.027
<b>Identification of pathology</b>	4.2%	70.8%	0.027

## **Take Home Messages**

---

1. Medical students found the sessions engaging, enjoyed this novel way of teaching and would like further teaching using ultrasound.
2. Using HHU scanners to augment the teaching of cardiac murmurs to medical students is feasible and effective.
3. Final year medical students can be used as instructors.

## **Notes On Contributors**

---

**Victor Galusko MBBCh<sup>a</sup>, Owen Bodger PhD<sup>a</sup>, Emma Rees PhD<sup>b</sup>, Adrian Ionescu MD<sup>c</sup>**

a – Swansea Medical School, Swansea University, Singleton Park, Swansea, UK

b - College of Human and Health Sciences, Swansea University, Swansea, UK

c – Morriston Cardiac Regional Centre, ABMU LHB, Swansea, UK

## Acknowledgements

---

We would like to thank Dr CW for providing the equipment and ideas to initiate the project and Dr MH for taking time to train VG in echocardiography.

## Bibliography/References

---

1. Lapostolle F, Petrovic T, Lenoir G, Catoire J, Galinski M, Metzger J, Chanzy E and Adnet F. Usefulness of hand-held ultrasound devices in out-of-hospital diagnosis performed by emergency physicians. *Am J Emerg Med.* 2006; 24(2):237-242.

<https://doi.org/10.1016/j.ajem.2005.07.010>

2. Wright J, Noriega O and Ho H. The Application of Hand-Held Ultrasound Scanner in Teaching of Telemedicine and Rural Medicine. *Donald School J Ultrasound Obstet Gynecol.* 2014; 8(1):87-91.

<https://doi.org/10.5005/jp-journals-10009-1340>

3. Greaves K, Jeetley P, Hickman M, Dwivedi G, Sabharwal N, Lim T, Janardhanan R and Senior R. The use of hand-carried ultrasound in the hospital setting--a cost-effective analysis. *J Am Soc Echocardiogr.* 2005; 18(6):620-625.

<https://doi.org/10.1016/j.echo.2004.09.015>

4. Kobal SL, Trento L, Baharami S, Tolstrup K, Naqvi TZ, Cercek B, Neuman Y, Mirocha J, Kar S, Forrester JS and Siegel RJ. Comparison of effectiveness of hand-carried ultrasound to bedside cardiovascular physical examination. *Am J Cardiol.* 2005; 96(7):1002-1008.

<https://doi.org/10.1016/j.amjcard.2005.05.060>

5. Kimura BJ, Shaw DJ, Agan DL, Amundson SA, Ping AC and DeMaria AN. Value of a cardiovascular limited US examination using a hand-carried US device on clinical management in an outpatient medical clinic. *Am J Cardiol.* 2007; 100(2):321-325.

<https://doi.org/10.1016/j.amjcard.2007.02.104>

6. Egan M and Ionescu A. The pocket echocardiograph: a useful new tool? *Eur J Echocardiogr.* 2008; 9(6):721-725.

<https://doi.org/10.1093/ejechocard/jen177>

7. Hoppmann RA, Rao VV, Bell F, Poston MB, Howe DB, Riffle S, Harris S, Riley R, McMahon C, Wilson LB, Blanck E, Richeson NA, Thomas LK, Hartman C, Neuffer FH, Keisler BD, Sims KM, Garber MD, Shuler CO, Blaivas M, Chillag SA, Wagner M, Barron K, Davis D, Wells JR, Kenney DJ, Hall JW, Bornemann PH, Schrift D, Hunt PS, Owens WB, Smith RS, Jackson AG, Hagon K, Wilson SP, Fowler SD, Catroppo JF, Rizvi AA, Powell CK, Cook T, Brown E, Navarro FA, Thornhill J, Burgis J, Jennings WR, McCallum JB, Nottingham JM, Kreiner J, Haddad R, Augustine JR, Pedigo NW and Catalana PV. The evolution of an integrated ultrasound curriculum (iUSC) for medical students: 9-year experience. *Critical Ultrasound Journal*. 2015; 7:18.

<https://doi.org/10.1186/s13089-015-0035-3>

8. Tshibwabwa ET, Cannon J, Rice J, Kawooya MG, Sanii R and Mallin R. Integrating Ultrasound Teaching into Preclinical Problem-based Learning. *J Clin Imaging Sci*. 2016; 6:38.

<https://doi.org/10.4103/2156-7514.190897>

9. Baltarowich OH, Di Salvo DN, Scoutt LM, Brown DL, Cox CW, DiPietro MA, Glazer DI, Hamper UM, Manning MA, Nazarian LN, Neutze JA, Romero M, Stephenson JW and Dubinsky TJ. National ultrasound curriculum for medical students. *Ultrasound Q*. 2014; 30(1):13-19.

<https://doi.org/10.1097/RUQ.0000000000000066>

10. Dinh VA, Fu JY, Lu S, Chiem A, Fox JC and Blaivas M. Integration of Ultrasound in Medical Education at United States Medical Schools: A National Survey of Directors' Experiences. *J Ultrasound Med*. 2016; 35(2):413-9.

<https://doi.org/10.7863/ultra.15.05073>

11. Sweetman GM, Crawford G, Hird K and Fear MW. The benefits and limitations of using ultrasonography to supplement anatomical understanding. *Anat Sci Educ*. 2013; 6(3):141-148.

<https://doi.org/10.1002/ase.1327>

12. Sicari R, Galderisi M, Voigt JU, Habib G, Zamorano JL, Lancellotti P and Badano LP. The use of pocket-size imaging devices: a position statement of the European Association of Echocardiography. *Eur J Echocardiogr*. 2011; 12(2):85-87.

<https://doi.org/10.1093/ejechocard/jeq184>

13. Decara JM, Kirkpatrick JN, Spencer KT, Ward RP, Kasza K, Furlong K and Lang RM. Use of hand-carried ultrasound devices to augment the accuracy of medical student bedside cardiac diagnoses. *J Am Soc Echocardiogr*. 2005; 18(3):257-263.

<https://doi.org/10.1016/j.echo.2004.11.015>

14. Stokke TM, Ruddox V, Sarvari SI, Otterstad JE, Aune E and Edvardsen T. Brief group training of medical students in focused cardiac ultrasound may improve diagnostic accuracy of physical examination. *J Am Soc Echocardiogr*. 2014; 27(11):1238-1246.

<https://doi.org/10.1016/j.echo.2014.08.001>

15. Panoulas VF, Daigeler AL, Malaweera AS, Lota AS, Baskaran D, Rahman S and Nihoyannopoulos P. Pocket-size hand-held cardiac ultrasound as an adjunct to clinical examination in the hands of medical students and junior doctors. *Eur Heart J Cardiovasc Imaging*. 2013; 14(4):323-330.

<https://doi.org/10.1093/ehjci/jes140>

16. Andersen GN, Viset A, Mjølstad OC, Salvesen O, Dalen H and Haugen BO. Feasibility and accuracy of point-of-care pocket-size ultrasonography performed by medical students. *BMC Medical Education*. 2014; 14(159).

<https://doi.org/10.1186/1472-6920-14-156>

17. Fox JC, Schlang JR, Maldonado G, Lotfipour S and Clayman RV. Proactive medicine: the "UCI 30," an ultrasound-based clinical initiative from the University of California, Irvine. *Acad Med*. 2014; 89(7):984-989.

<https://doi.org/10.1097/ACM.0000000000000292>

18. Tshibwabwa ET and Groves HM. Integration of ultrasound in the education programme in anatomy. *Med Edu*. 2005; 39(11):1148.

<https://doi.org/10.1111/j.1365-2929.2005.02288.x>

19. Hammoudi N, Arangalage D, Boubrit L, Renaud MC, Isnard R, Collet JP, Cohen A and Duguet A. Ultrasound-based teaching of cardiac anatomy and physiology to undergraduate medical students. *Arch Cardiovasc Dis*. 2013; 106(10):487-491.

<https://doi.org/10.1016/j.acvd.2013.06.002>

20. Oddone EZ, Waugh RA, Samsa G, Corey R and Feussner JR. Teaching cardiovascular examination skills: results from a randomized controlled trial. *Am J Med*. 1993; 95(4):389-96.

[https://doi.org/10.1016/0002-9343\(93\)90308-C](https://doi.org/10.1016/0002-9343(93)90308-C)

21. Mai TV, Ahn DT, Phillips CT, Agan, DL and Kimura BJ. Feasibility of remote real-time guidance of a cardiac examination performed by novices using a pocket-sized ultrasound device. *Emerg Med Int*. 2013; 20113:627230.

<https://doi.org/10.1155/2013/627230>

22. Patten D, Donnelly L and Richards S. Studying living anatomy: the use of portable ultrasound in the undergraduate medical curriculum. *International Journal of Clinical Skills*. *International Journal of Clinical Skills*. 2010; 4(2):72-77.

23. Mouratev G, Howe D, Hoppmann R, Poston MB, Reid R, Varnadoe J, Smith S, McCallum B, Rao V and DeMarco P. Teaching medical students ultrasound to measure liver size: Comparison with experienced clinicians using physical examination alone. *Teach Learn Med*. 2013; 25(84):88.

<https://doi.org/10.1080/10401334.2012.741535>

24. Connolly K, Beier L, Langdorf MI, Anderson CL and Fox JC. Ultrafest: a novel approach to ultrasound in medical education leads to improvement in written and clinical examinations. *West J Emerg Med*. 2015; 16(1):143-148.

<https://doi.org/10.5811/westjem.2014.11.23746>

25. Paganini M and Rubini A. Chest ultrasound integrated teaching of respiratory system physiology to medical students: a first experience. *Adv Physiol Educ.* 2015; 39(2):129-130.

<https://doi.org/10.1152/advan.00084.2014>

26. Wright SA and Bell AL. Enhancement of undergraduate rheumatology teaching through the use of musculoskeletal ultrasound. *Rheumatology (Oxford).* 2008; 47(10):1564-1566.

<https://doi.org/10.1093/rheumatology/ken324>

27. Osborn SR, Borhart J, and Antonis MS. Medical students benefit from the use of ultrasound when learning peripheral IV techniques. *Crit Ultrasound J.* 2012; 4(1): p. 2.

<https://doi.org/10.1186/2036-7902-4-2>

28. Garcia-Casasola G, Sánchez FJ, Luordo D, Zapata DF, Frías MC, Garrido VV, Martínez JV, de la Sotilla AF, Rojo JM and Macho JT. Basic Abdominal Point-of-Care Ultrasound Training in the Undergraduate: Students as Mentors. *J Ultrasound Med.* 2016; 35(11):2483-2489.

<https://doi.org/10.7863/ultra.15.11068>

## Appendices

---

### **Appendix 1 – learning objectives for the first teaching session (using echocardiography to augment understanding of cardiac murmurs)**

- To understand the uses of ultrasound in everyday practice
  - To be aware the advantages and disadvantages of the HHU devices, and how these devices can be used to augment a standard physical examination and be used in emergency situations
  - To understand the heart can be visualised in PLax and A4C, and the anatomy that can be seen
  - To understand that valvular lesions can be visualised using ultrasound (focusing on AS, AR, MR and MS)
  - To link the pathophysiology of valvular lesions to the findings on a standard physical examination
- 

### **Appendix 2 – learning objectives for the second teaching session (using echocardiography to augment understanding of systolic murmurs)**

- To understand the uses of ultrasound in everyday practice
- To be aware the advantages and disadvantages of the HHU devices, and how these devices can be used to augment a standard physical examination and be used in emergency situations
- To understand basic echocardiography views (PLax, PSax and A4C), and the anatomical structures visible
- To understand that valvular lesions can be visualised using ultrasound (focusing on the systolic murmurs (AS and MR))

- To link the pathophysiology of valvular lesions to the findings on physical examination
- 

### **Appendix 3 – learning objectives for the extracurricular HHU 3-week course**

#### **Learning Objectives**

##### **Basics (30-minute lecture) + Introduction to echocardiographic views (30-minute lecture)**

- Understand the importance of infection control and patient communication during ultrasound procedures
- Understand the importance of image archiving and documentation
- Become aware of the advantages and disadvantages of ultrasound, and recognize the limitations of portable ultrasound devices and when they should not be used
- Use surface anatomy to correlate probe placement with the cardiac structures visualized by echocardiography
- Be able to identify the structures in the heart, its chambers, vessels and pericardium on echocardiography images acquired in PLax, PSax and A4C
- Understand the indications for echocardiography and that formal echocardiography involves other views and is more accurate than HHU

##### **Echocardiography views and valvular anatomy (1 hour lecture + 1 hour hands-on practice)**

- Ability to identify the structures in the heart, its chambers, vessels and pericardium on given ultrasound images in PLAX, PSAX and A4C
- Ability to assess valvular function (stenotic and regurgitant lesions of the aortic, mitral, tricuspid valves)
- To understand that formal echocardiography is more accurate for the assessment of the severity of valvular lesions

##### **LV function (1 hour lecture + 1 hour hands-on practice)**

- To understand the basics of LV ejection fraction and the context in which it is important in clinical practice
  - To be able to assess LV visually function and understand how this may affect patient management
- 

### **Appendix 4 – pre- and post-test for the first teaching session on echocardiography**



**Echocardiography Test**

Student Number: .....  
Gender ..... Male/Female  
Have you had any cardiology placements? Yes/No  
Have you been a cardiac physiologist or have had similar experience? Yes/No

**Image 1 – Label the vessels, chambers and valves**

**Valves**  
A.....  
B.....  
  
**Chambers/Vessels**  
1.....  
2.....  
3.....

**Image 2 – Label the vessels, chambers and valves**

**Valves**  
C.....  
D.....  
  
**Chambers/Vessels**  
4.....  
5.....

**Murmur 1**

- Normal
- Aortic Stenosis
- Tricuspid Regurgitation
- Aortic Regurgitation
- Mitral Stenosis
- Pulmonary Stenosis
- Mitral Regurgitation

**Murmur 2**

- Normal
- Aortic Stenosis
- Tricuspid Regurgitation
- Aortic Regurgitation
- Mitral Stenosis
- Pulmonary Stenosis
- Mitral Regurgitation

**Murmur 3**

- Normal
- Aortic Stenosis
- Tricuspid Regurgitation
- Aortic Regurgitation
- Mitral Stenosis
- Pulmonary Stenosis
- Mitral Regurgitation

**Murmur 4**

- Normal
- Aortic Stenosis
- Tricuspid Regurgitation
- Aortic Regurgitation
- Mitral Stenosis
- Pulmonary Stenosis
- Mitral Regurgitation

**Now, after you've seen the echo, please tick the corresponding box, giving your final diagnosis**

**Murmur 1 + Echo 1**

- Normal
- Aortic Stenosis
- Tricuspid Regurgitation
- Aortic Regurgitation
- Mitral Stenosis
- Pulmonary Stenosis
- Mitral Regurgitation

**Murmur 2 + Echo 2**

- Normal
- Aortic Stenosis
- Tricuspid Regurgitation
- Aortic Regurgitation
- Mitral Stenosis
- Pulmonary Stenosis
- Mitral Regurgitation

**Murmur 3 + Echo 3**

- Normal
- Aortic Stenosis
- Tricuspid Regurgitation
- Aortic Regurgitation
- Mitral Stenosis
- Pulmonary Stenosis
- Mitral Regurgitation

**Murmur 4 + Echo 4**

- Normal
- Aortic Stenosis
- Tricuspid Regurgitation
- Aortic Regurgitation
- Mitral Stenosis
- Pulmonary Stenosis
- Mitral Regurgitation

**Feedback**

*I found the session useful*

**Yes/No**

*I now feel more confident at interpreting murmurs*

**Yes/No**

*Why did you find it useful/not useful?*

*What was done well?*

*What was done poorly/can be improved on?*

**I think the use of hand-held ultrasound devices will change my future practice as a clinician**

**Yes/No**

*I would like sessions like this to help me understand*

JVP waveform **Yes/No**

Cardiac Cycle **Yes/No**

Cardiac Anatomy **Yes/No**

**I would like more teaching on ultrasound** **Yes/No**

---

**Appendix 5 – questionnaire/feedback form for the second teaching session (using echocardiography to augment understanding of cardiac murmurs)**

**Feedback**

<i>I found the session useful</i>	<b>Yes/No</b>
<i>I feel like I understand more about murmurs and the clinical signs they cause</i>	<b>Yes/No</b>
<i>I feel like I understand more about the pathophysiology of murmurs</i>	<b>Yes/No</b>
<i>I now feel more confident at interpreting murmurs</i>	<b>Yes/No</b>
<i>I think the use of hand-held ultrasound devices will change my future practice as a clinician</i>	<b>Yes/No</b>
<i>I would like more teaching on ultrasound</i>	<b>Yes/No</b>

*Why did you find it useful/not useful?*

*What was done well?*

*What was done poorly/can be improved on?*

---

**Appendix 6a – pre-test/post-test questionnaire for the third teaching session**

**Echocardiography Test**

1) What type of waves does ultrasound use?

.....

2) State an advantage and a disadvantage of using ultrasound in clinical practice

**Advantage**.....

**Disadvantage**.....

**Picture 1 – printed image of the PLAX view showing dilated cardiomyopathy**

(Intentionally left blank)

<p><b>Identify the anatomical structures:</b></p> <p>1)..... .....</p> <p>2)..... .....</p> <p>3)..... .....</p> <p><b>Is this a normal scan/what is the pathology?</b></p> <p>..... ..... .....</p>
--

**Picture 2 – a printed image of the A4C view with colour flow showing mitral regurgitation**

(Intentionally left blank)

<p><b>Identify the anatomical structures:</b></p> <p>1)..... .....</p> <p>2)..... .....</p> <p>3)..... .....</p> <p><b>Is this a normal scan/what is the pathology?</b></p> <p>..... ..... .....</p>
--

**Picture 3 - a printed image of the A4C view showing tricuspid regurgitation**

(Intentionally left blank)

<p><b>Identify the structures:</b></p> <p>1)..... .....</p> <p>2)..... .....</p> <p>3)..... .....</p> <p><b>Is this a normal scan/what is the pathology?</b></p> <p>..... ..... .....</p>
---

**Picture 3 - a printed image of the PLAX view with colour flow showing aortic regurgitation**

(Intentionally left blank)

<p><b>Identify the structures:</b></p> <p>1)..... .....</p> <p>2)..... .....</p> <p>3)..... .....</p> <p><b>Is this a normal scan/what is the pathology?</b></p> <p>..... ..... .....</p>
---

---

**Appendix 6b – post-test questionnaire and feedback form for the third teaching session**

*I found the cardiac part of the ultrasound course interesting*

**Yes/No**

*I found the cardiac part of the ultrasound course useful, and relevant to my stage of training*

**Yes/No**

*I feel like I understand more about the clinical indications for echocardiography, and how it's used in clinical practice*

**Yes/No**

*I can see how HHU (hand-held ultrasound) would be a useful skill for me to have as a future clinician*

**Yes/No**

*The sessions have improved my understanding of anatomy/physiology of the heart*

**Yes/No**

*I would like more teaching on cardiac ultrasound*

**Yes/No**

*If yes, what would you like covered?*

.....  
*Did you feel that the 3 week course was too long? I.e. was the course too much in depth*

**Yes/No**

*Why did you find it useful/not useful?*

*What was done well?*

*What was done poorly/can be improved on?*

*What did you think of having a "peer" instructor teaching you ultrasound? (BE HONEST!)*

*(i.e. what was his knowledge and abilities like? Pitching at the right level? Clear delivery? Pace?)*

---

### Appendix 7 – feedback from the first teaching session

**What was done well?**

"Practical bit of teaching was great! Teaching was very clear and structured"

"Useful session because full teaching of murmurs was not covered in university well"

"Very useful – feel a lot more confident with murmurs now! Listening to SimMan was good + seeing echos"

"Murmur teaching – descriptions/characteristics of murmurs v. useful"

"Very clear description of murmurs – excellent teaching"

"Listening to the murmurs was really useful. Teaching was very effective and appropriate to our level of knowledge"

"Really helpful, did not know anything about echos and very little about ultrasound prior to this"

"Going over the heart sounds and effectively the pathophysiology of murmur was really good"

### ***What can be improved on?***

"May be too many murmurs to interpret took too long"

"Go a bit slower through the slides, may be a handout"

"I would have appreciated some sounds of the different murmurs being played as you discussed them"

"Teaching on the sound of each murmur was a bit fast, but still quite clear – might need a little longer to get my head around the sounds"

"Can the murmurs be played on loudspeaker before listening to them on the dummy – would be easier as we could get used to know what to listen for"

"The timing 3 weeks before exams"

---

### ***Appendix 8 – some selected feedback from the second teaching session***

"useful mnemonic to help to remember murmurs"

"well explained and practical"

"Useful to have a hands-on aspect to murmur training"

"Good mix of teaching approaches. Very interactive"

"taught in a nice simple way. Concise."

"useful to have real-time images of the heart with explanation"

"It was useful to consider the anatomy of healthy hearts and compare them to diseased hearts"

"Clear and easy to understand, good structure"



"Very clear teacher. Subject knowledge was very good. Cool use of ultrasound"

"All of it was done well! Very knowledgeable guide!"

"Never seen the heart on echo before"

***What can be improved on?***

"perhaps make it a double station in the future"

"I need more practice at listening to murmurs"

"More on interpreting murmurs please"

"Some audio clips of murmurs would be useful!"

"Was good but would be helpful to be longer – still unsure on some murmurs"

"Large group today, so hard to see!"

"Would like more teaching to consolidate – maybe next year"

"would have liked some hands-on time"

"More time would be useful!"

"May be more time matching the anatomy to the scan"

"Slide show could be more in depth with sounds"

"Access to device for practice"

---

**Appendix 9 – feedback from the third teaching session**

**General**

"I have never done any ultrasound before so the course was an ideal introduction and a good recap of cardiac anatomy. Very clear teaching. VG made the topic interesting and aimed it at the right level"

"I was able to understand the views and what I was looking at. Practice was invaluable as was the exposure of seeing lots of scans"

"It was useful to gain a basic understanding of ultrasound + how echocardiography is used, and I now know what I'm looking at generally. I also learnt a lot about cardiac diseases and why they result in the symptoms + structural"

alterations seen. Teaching was clear and easy to follow. Good to practice using the HHU!"

"Teaching + practical + cases helped with learning and understanding"

"More understanding of heart anatomy and good to have a go at echocardiography myself. Well taught. Victor has really good knowledge and good extra info for exams"

"Useful to understand the different views of the heart and what they can be used to measure/detect. The hands-on part was really good"

### **Improvements**

"May be a big more hands-on time with the HHU"

"Perhaps arrangement for clinics where we could practice with the cardiac ultrasound technicians"

"A couple more machines might have been good. Then we could split up into smaller groups and get more hands-on time"

### **Peer instructor**

"very good, knew about the level to pitch the teaching at"

"It didn't feel pressured and I didn't mind asking a stupid question"

"VG was great and his teaching was excellent. It made it applicable to our level of learning. Very interactive. He asks questions in a way that allow you to really think + understand the information"

"Really good – felt more comfortable taking guesses/ asking Qs. Whilst also can see he knows a lot about what he is teaching. Smaller group made the course comfortable/accessible"

"Really good. Think it helped as it was pitched at our level"

"Brilliant! Students tend to know the level to pitch information at as they have been in our position. I would like more peer teaching for other things (interpretation of blood results)"

### **Declaration of Interest**

---

*The author has declared that there are no conflicts of interest.*