

Evidence-based practice

Diagnosis and management of lobular capillary haemangioma (pyogenic granuloma) in an adult female lactating bonobo (*Pan paniscus*)

S. Chapman, P. Dobbs¹, V. Strong^{1,2}, H. Barlow, D. Zebedee, S. Childs and M.F. Stidworthy³

¹Twycross Zoo, Atherstone, United Kingdom

²University of Nottingham, School of Veterinary Medicine and Science, Nottingham, United Kingdom

³International Zoo Veterinary Group, Keighley, United Kingdom

Correspondence: Sarah Chapman; sarahhewittvet@googlemail.com

Keywords:

anaesthesia, great ape, risk management

Article history:

Received: 3 February 2016

Accepted: 25 November 2017

Published online: 31 January 2017

Abstract

An adult female lactating bonobo (*Pan paniscus*) presented with an acutely enlarging skin nodule, readily susceptible to haemorrhage, on the third digit of her left foot, which was subsequently removed under anaesthesia when it had reached a diameter of approximately 10 mm. The bonobo had five-year-old and three-month-old infants, which had to be managed sensitively during the procedure. Risk management was carefully planned with the keeping team. Oral benzodiazepines were used in the dam and five-year-old infant to reduce stress, and careful planning ensured a time-efficient anaesthetic procedure. Radiographs were taken to investigate the involvement of underlying tissue, and the skin mass was removed by partial amputation of the digit including a segment of bone. Histopathology yielded a diagnosis of lobular capillary haemangioma (pyogenic granuloma). Although the clinical presentation was extremely similar to that seen in humans, the entity has not been commonly reported in apes.

Background

A female bonobo (*Pan paniscus*), aged 19 years, presented with a 3 mm round wart-like lesion on digit three of her left foot. She had arrived at the zoo 11 years previously as part of the European breeding programme and had a five-year-old and a three-month-old infant. The mass was not causing irritation but did produce minor haemorrhage if traumatised. Mild swelling of the second interphalangeal joint was treated with oral paracetamol (500 mg twice daily, Paracetamol^{IPOM} 500 mg tablets, generic). The mass continued to increase in size and one month after initial presentation was a 1 cm round, well demarcated, red polypoid lesion which bled when traumatised, and had a conspicuous rim of epidermal hyperplasia and

hyperkeratosis around its base (Figure 1). The decision was made to remove the mass under anaesthesia, with positive reinforcement training commencing to present the foot for follow up examination and treatment as required. The risk of oral drug use in lactating females was discussed and accepted as low, but close monitoring of the infant was undertaken (Royal Pharmaceutical Society 2012). Concerns about reducing the risk of trauma to the infant were discussed as were doubts about the ability to separate the five-year-old youngster from the dam. The decision was made to separate the dam and her youngsters on the morning of the procedure and give oral benzodiazepines to the dam and older youngster to reduce stress. The infant would then be left on the dam during the

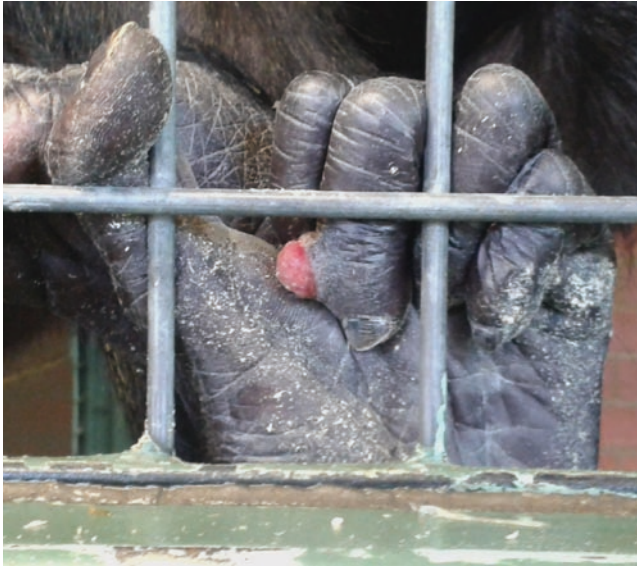

Figure 1. Digital mass on the third digit of the left foot of an adult female bonobo (*Pan paniscus*). Note the ulcerated fleshy polypoid lesion, prone to haemorrhage, and the basal rim of epidermal hyperplasia and hyperkeratosis.

procedure with minimal intervention planned. The procedure was also limited to minimal essential staff and additional procedures, e.g. cardiac and abdominal ultrasonographies were excluded from the procedure to limit anaesthetic time.

Action

On the morning of the procedure, the bonobo was separated from the group, with her two youngsters, and had been starved for 16 hours. The adult female and the five-year-old infant were both given oral midazolam (0.5 mg/kg, Hypnovel® 5 mg/ml, Roche, United Kingdom) and the five-year-old infant was then separated from the dam. Both animals were mildly sedated within 30 minutes of ingestion of midazolam. The youngest infant remained with the dam throughout the procedure.

Induction of anaesthesia of the adult female was achieved following remote delivery of 70 mg zolazepam/tiletamine (2 mg/kg, Zoletil®500, Virbac, Finland) and 0.7 mg medetomidine (0.02 mg/kg, Domitor®, 1 mg/ml, Vetoquinol, United Kingdom), into the left vastus lateralis muscle. This resulted in light anaesthesia within ten minutes when she was in a sitting position with the infant on her abdomen. She was positioned in dorsal recumbency with the infant on her chest (Figure 2). The infant was covered with a towel during the procedure. The mother was intubated with a size six uncuffed endotracheal tube. A supplementary intravenous dose of injectable anaesthesia (175 mg ketamine, Narketan®10, 100 mg/ml, Vetoquinol, United Kingdom) was given and anaesthesia was subsequently maintained on gaseous isoflurane, as required, in three litres of oxygen using a circle circuit with a two-litre re-breathing bag. Throughout the procedure heart and respiration rates were monitored and remained between 80-100 bpm and 20-48 rpm respectively. Saturated oxygen levels remained at 93-95% and end tidal carbon dioxide measurements were obtained, ranging between 31 and 42 mmHg. Body temperature reduced from 34.3 to 33.5 °C. Blood pressure was measured using a medium cuff on a forearm (Orion R1 Blood Pressure Monitor, Orion, Hamburg) and mean blood pressure ranged from 84 to 100mmHg. A 20G intravenous catheter was placed in the left cephalic vein and fluid therapy was given at 10 ml/kg/hr using Hartmann's solution

(Vetivex 11, Isolec Hartmanns solution, Dechra, United Kingdom).

On physical examination the bonobo weighed 30.5 kg and was in fair body condition, with reasonable hair condition but dry skin with patchy areas of alopecia. No abnormalities were detected on abdominal palpation or thoracic auscultation. External examination was unremarkable apart from the left foot digit mass. The dental formula was 2 (2/2, 1/1, 2/2, 3/3) with all teeth in excellent condition. Lateral and dorso-plantar feet radiographs were taken, which showed no bone invasion by the mass (Figure 3). Body measurements were taken as standard (hip-ankle 55 cm, shoulder-wrist 60 cm, biceps circumference 22 cm and thigh circumference 35 cm). 40 ml of blood was taken from the right femoral vein and placed into plain serum, heparin, fluoride oxalate and EDTA blood tubes. Three blood smears were also made. Samples were sent for haematology and biochemistry which were normal. In house blood glucose (5.4 mmol/l Accu-check® Aviva, Roche, United Kingdom) and white cell count ($3.8 \times 10^9/l$ Hemacue®WBC, Woodley Equipment Company, United Kingdom) were measured. EDTA and serum samples were stored. A rectal swab was taken for bacterial culture and was normal. A hair sample was taken and stored for genetic purposes. During the procedure the following medications were given: 1.7 mg metoclopramide (0.5 mg/kg, Maxalon®, 5 mg/ml, Amdipharm, United Kingdom) subcutaneously; 440 mg amoxicillin/clavulanic acid (Co-amoxyclov 500 mg/100 mg, Workhart, United Kingdom) and 500 mg paracetamol (Perfalgan® 10 mg/ml, Bristol-Myers Squibb, United Kingdom) intravenously.

Prior to commencement of surgery, a tourniquet was placed around the base of the affected digit. The digit was amputated at the second interphalangeal joint and placed whole into formalin for histopathology. The subcutaneous tissue and skin were sutured using simple interrupted absorbable sutures (1 metric Vicryl™, Ethicon, United Kingdom). Tissue glue was also used along the wound edges (Gluture®, Abbott Laboratories, United Kingdom).

3.5 mg atipamezole (0.1 mg/kg, Antisedan®, 5 mg/ml, Vetoquinol, United Kingdom) was administered in the right biceps muscle giving a total anaesthesia time of 103 minutes. Prior to full recovery of the dam, the infant was weighed, a hair sample was taken for genetic testing and a microchip (Trovan®, Germany) was



Figure 2. Positioning of an adult female bonobo and her infant during the investigation of a skin mass.

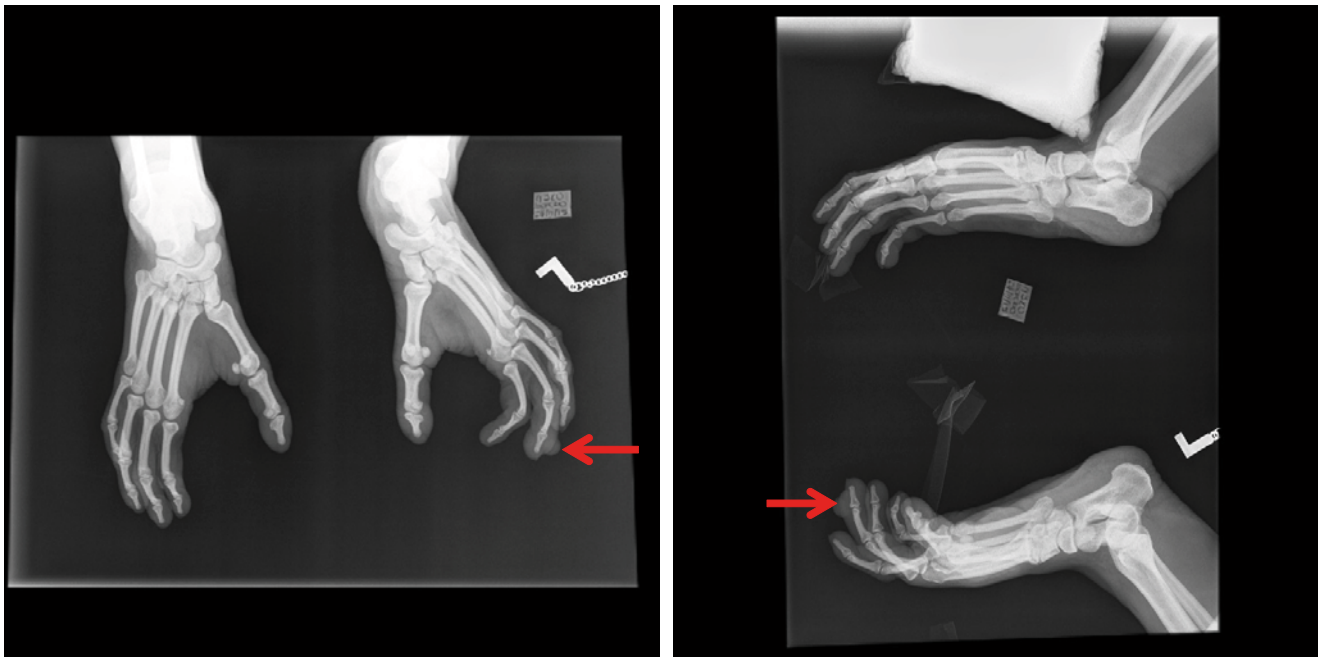

Figure 3. Radiographs of feet of an adult female bonobo taken during the investigation of a skin mass (red arrows).

placed between the scapulae. The adult female was extubated eight minutes after reversal of anaesthesia. Recovery was normal with no anaesthetic complications.

The bonobo was mixed back with the group on the same day and given follow-up treatment of oral meloxicam (0.2 mg/kg once daily, Metacam® 15 mg/ml, Boehringer Ingelheim, United Kingdom), paracetamol (500 mg twice daily, Paracetamol^{PO} 500 mg tablets, generic), clavulanate-potentiased amoxicillin (15 mg/kg twice daily, Synulox™ 500 mg tablets, Zoetis, United Kingdom) and probiotics (two capsules daily, Bio-kult®, Protexin, United Kingdom). The five-year-old infant showed no signs of stress due to the short period of separation from the dam. During the afternoon of the same day, the bonobo removed all the sutures from the digit wound.

Consequences

The wound healed by secondary intention within four weeks of the surgery. There were no known adverse effects on the nursing infant from the oral treatment given to the dam. Four months after surgery there had been no recurrence of the lesion. Positive reinforcement training was useful for close monitoring of the area. The bonobo would readily present the foot for safe inspection by the veterinary and keeping teams.

Histopathology was performed on the fixed tissue sample. A transverse section was examined through the full thickness of the nodular lesion down to the periosteal surface of the bone. The epidermis at the margins of the lesion was markedly hyperplastic, acanthotic and hyperkeratotic (Figure 4A). The lesion had a central domed moderately exophytic area of full-thickness epidermal ulceration, with exposed surfaces comprising a sheet of fibrinonecrotic and neutrophilic cytotoxic debris admixed with small clumps of Gram-negative rod-shaped bacteria. Fibrinonecrotic and degenerative inflammatory material blended with underlying granulation tissue, with remnant bundles of dermal collagen

interlaced with areas of sprouting capillaries and fibroblasts, intermingled with pockets of fibrin and mild multifocal infiltrates of neutrophils. Embedded in the deep dermis/hypodermis and extending into the deeper connective tissue, continuous with the granulation tissue, were multiple poorly circumscribed lobules of vasoproliferation (Figure 4B). These consisted of multiple variably-sized capillary-like vessels interwoven with delicate collagen fibrils and containing small numbers of red blood cells. Vessels were lined by slightly pleomorphic variably plump endothelial cells, whose oval finely stippled nuclei bulged into the vascular lumina. Mitoses or cellular atypia were not features. Some foci had plumper perivascular spindle populations and denser stromal collagen deposits, and vessels were interspersed with minimal perivascular lymphocytic infiltrates. A transverse section through the entire digit in the plane of the original soft tissue section was examined after decalcification, and a further section at 90° to the original. The lesion had been completely excised and there was no bone invasion, with a margin of several millimetres between the lesion and the periosteum of the digital bone.

The clinical presentation and histological appearance were considered consistent with lobular capillary haemangioma, a well recognised cutaneous vascular proliferation of humans. In human medicine this lesion is referred to clinically as pyogenic granuloma (or *granuloma pyogenicum*), following the nomenclature of Hartzell (1904), even though it is neither granulomatous nor pus-forming. In fact, current thinking suggests that the lesion may be a part of a spectrum of reactive vascular proliferative lesions characterised by the presence of numerous endothelial-lined vascular spaces, proliferating fibroblasts and budding endothelial cells (Marla et al. 2016), and the term telangiectatic granuloma has also been proposed (Kamal et al. 2016). Since this may be a reactive rather than neoplastic lesion the term haemangioma may itself be inappropriate, but lobular capillary haemangioma is nonetheless the nomenclature more typically used in veterinary medicine for lesions of this sort. Pyogenic granuloma continues to

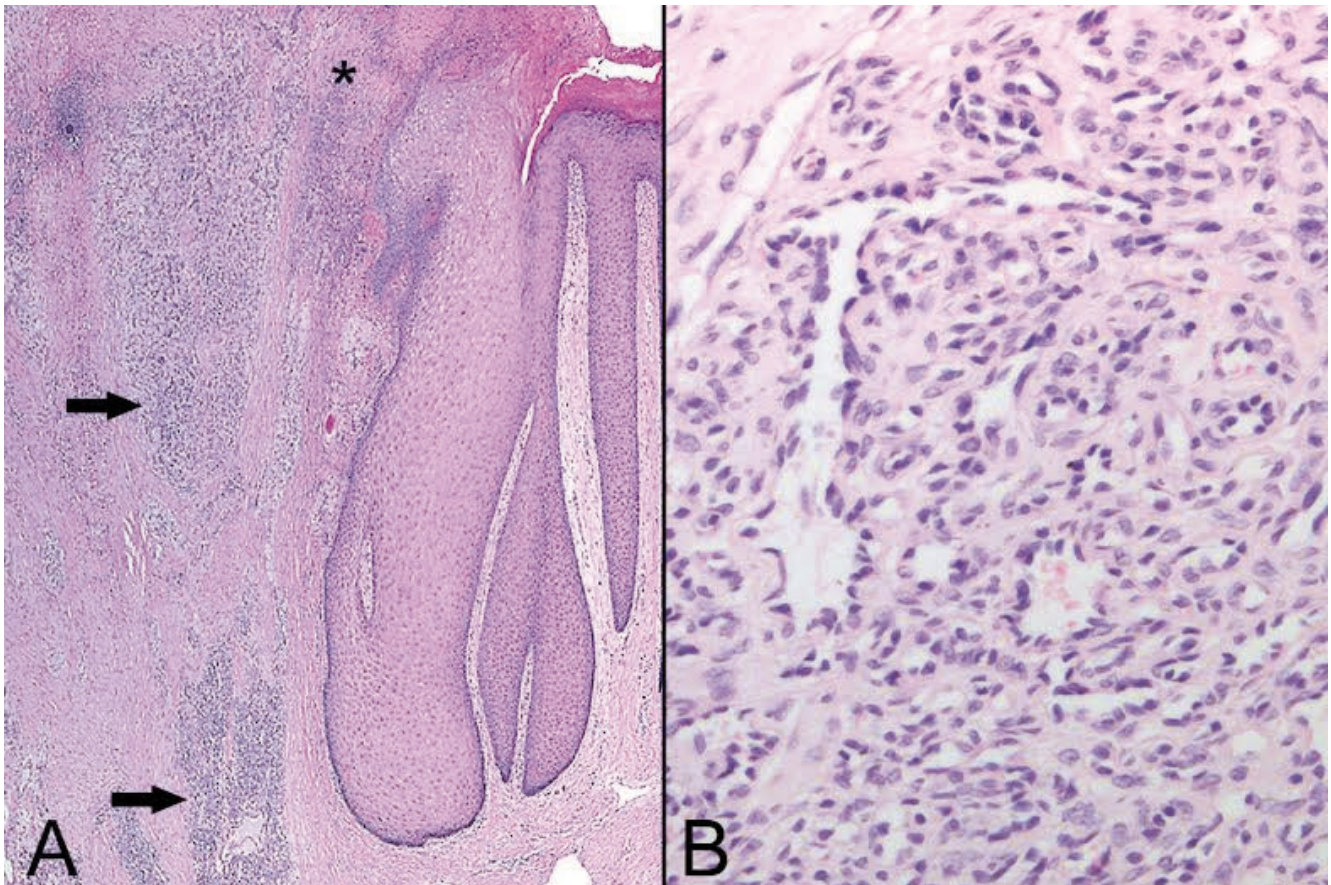


Figure 4. Histological appearance of lobular capillary haemangioma (pyogenic granuloma) lesion of an adult female bonobo. A. Transverse section through the margin of the lesion, demonstrating the ulcerated and inflamed surface (asterisk) above a layer of granulation tissue blending with lobules (arrows) of capillary vasoproliferation. Note also the marked acanthosis and hyperkeratosis of the epidermis at the lesion margin (to right); H and E, original magnification 20 x.

be used as an entity in the veterinary literature in some locations including the oral cavity (Uzal et al. 2015; Breithaupt 2016).

Lobular capillary hemangioma is a relatively common benign vascular lesion of the skin and mucosa in humans, of unknown aetiology (Mills et al. 1980; Pierson and Tam 2015). Trauma, hormonal influences, viral infections, underlying microscopic arteriovenous malformations or cytogenetic abnormalities, and the production of angiogenic growth factors as a result of tissue injury have all been suggested. Lesions are typically on the head, neck, extremities, and upper trunk. Lesions often arise in pregnancy (oral contraceptive usage is rarely involved), in which case they are usually in the oral mucosa. In humans, the lesion makes up 0.5% of all skin nodules in children in the United States (Patrice et al. 1991), and occurs in up to 5% of pregnancies (Sills et al. 1996). There is no sex predisposition other than for the oral mucosal lesions, which are twice as frequent in females due to the pregnancy effect (Harris et al. 2000). Typically, lesions are solitary and grow rapidly to maximum size (usually around 10 mm diameter) over a few weeks, to form a painless red raspberry-like polypoid lesion with a basal epidermal collarette, prone to bleeding spontaneously or after mild trauma. There may be a history of trauma or peripheral nerve injury, or rarely, an underlying systemic inflammatory disease (Piraccini et al. 2010).

Untreated pyogenic granulomas do eventually atrophy, fibrose and regress, but in practice, most cases are surgically removed and submitted for histological confirmation. Full-thickness skin excision provides the lowest chance of recurrence (2.94%) (Lee et al. 2010). Removal is typically curative although occasional recurrence has been reported and in such cases the diagnosis should be reviewed and persistent underlying inciting factors eliminated, such as persistent foreign body or trauma. Differential diagnoses include other tumours of vascular origin, granulation tissue, hamartoma, heavily vascularised acrochordon, persistent foreign body, bacillary angiomatosis, neurofibroma, melanoma and tumours of epithelial origin either primary cutaneous or metastatic. Lobular capillary haemangioma (pyogenic granuloma) is less clearly characterised as a distinct entity in veterinary medicine, and similar lesions have been variously classified as granulation-tissue-type haemangioma in dogs (Gross et al. 2005), lobular capillary haemangiomas in calves and horses (van der Gaag et al. 1988; Vos et al. 1986) and as cutaneous angiomatosis in cattle (Cotchin et al. 1963). A lesion referred to as pyogenic granuloma is also amongst the differential diagnoses for oral epulides in dogs (Uzal et al. 2015) and cats (Riehl et al. 2014), but whether this is truly equivalent or merely exuberant vascularised granulation tissue is uncertain. A number of similar lesions are also likely to have been recorded

in the veterinary literature amongst the heterogeneous groups of vascular proliferations classified as angiomas (Gross et al. 2005). It is recognised that in older macaques, pink to red 1–3-mm benign angiomas (“age spots”) are often found on the face and chest (Lowenstine 2003), and there are occasional reports of other forms of haemangioma in non-human primates (Burke and Stookey 1973; Miller 2012), but in general vascular neoplasia is rare in non-human primates and no report of a similar lobular capillary haemangioma was identified by the authors.

The clinical presentation in this case bears a striking similarity to that seen with the entity known as pyogenic granuloma in humans. This lesion should be considered in the differential diagnosis of acutely-presenting nodular skin lesions, particularly those that bleed easily, on the digits of non-human primates. This is particularly pertinent to suspected traumatic lesions of the digits, which are extremely frequent in such populations in zoos. This case had the added challenge of managing the infant during general anaesthesia of the dam. Careful planning and discussion with the animal team took place and the procedure resulted in minimal disruption to the individuals, other offspring and the rest of the bonobo group.

Acknowledgements

The authors would like to acknowledge Dr Daniela Denk (IZVG Pathology) for helpful discussions, and the ape keepers and veterinary team for their care of this individual.

References

- Breithaupt A. (2015) Alimentary tumors. In: Klopffleisch R. (ed.). *Veterinary Oncology: A Short Textbook*. Cham, Switzerland: Springer Nature, 168–193.
- Burek J.D. and Stookey J.L. (1973) Sclerosing capillary hemangioma in a rhesus monkey. *Veterinary Pathology* 10: 12–15.
- Cotchin E and Swarbrick O. (1963) Bovine cutaneous angiomas: a lesion resembling human “pyogenic granuloma” (“*Granuloma telangiectaticum*”). *Veterinary Record* 75: 437–444.
- Harris M.N., Desai R, Chuang T.Y., Hood A.F. and Mirowski G.W. (2000) Lobular capillary hemangiomas: An epidemiologic report, with emphasis on cutaneous lesions. *Journal of the American Academy of Dermatology* 42: 1012–1016.
- Hartzell M. E. (1904) Granuloma pyogenicum. *Journal of Cutaneous Diseases Including Syphilis* 22: 520–525.
- Gross T.L., Ihrke P.J., Walder E.J. and Affolter V.K. (2010) Vascular tumors. In: Gross T.L., Ihrke P.J., Walder E.J. and Affolter V.K. (eds). *Skin Diseases of the Dog and Cat: Clinical and Histopathologic Diagnosis*, 2nd edn. Oxford: Blackwell Science, 735–758.
- Kamal R., Dahiya P. and Puri A. (2012) Oral pyogenic granuloma: various concepts of etiopathogenesis. *Journal of Oral and Maxillofacial Pathology* 16:79–82.
- Lee J., Sinno H., Tahiri Y. and Gilardino M.S. (2011) Treatment options for cutaneous pyogenic granulomas: a review. *Journal of Plastic, Reconstructive and Aesthetic Surgery* 64: 1216–1220.
- Lowenstine L.J. (2003) A primer of primate pathology: lesions and nonlesions. *Toxicologic Pathology* 31(1 suppl): 92–102.
- Marla V., Shrestha A., Goel K. and Shrestha S. (2016) The histopathological spectrum of pyogenic granuloma: a case series. *Case Reports in Dentistry*. doi:10.1155/2016/1323798.
- Miller A.D. (2012) Neoplasia and proliferative disorders of nonhuman primates. In: Abee C.R., Mansfield K., Tardif S. and Morris T. (eds). *Nonhuman primates in Biomedical Research Volume 2: Diseases*, 2nd edn. London: Academic Press, 325–356.
- Mills S.E., Cooper P.H. and Fechner R.E. (1980) Lobular capillary hemangioma: the underlying lesion of pyogenic granuloma. A study of 73 cases from the oral and nasal mucous membranes. *American Journal of Surgical Pathology* 4: 470–479.
- Patrice S.J., Wiss K. and Mulliken J.B. (1991) Pyogenic granuloma (lobular capillary hemangioma): a clinicopathologic study of 178 cases. *Pediatric Dermatology* 8: 267–276.
- Pierson J.C. and Tam C.C. (2015) Dermatologic manifestations of pyogenic granuloma (lobular capillary hemangioma). <http://emedicine.medscape.com/article/1084701-overview> (accessed online 03 February 2016).
- Piraccini B.M., Bellavista S., Misciali C., Tosti A., de Berker D. and Richert B. (2010) Periungual and subungual pyogenic granuloma. *British Journal of Dermatology* 163: 941–953.
- Riehl J, Bell C.M., Constantaras M.E., Snyder C.J., Charlier C.J. and Soukup J.W. (2014) Clinicopathologic characterization of oral pyogenic granuloma in 8 cats. *Journal of Veterinary Dentistry* 31: 80–86.
- Royal Pharmaceutical Society (2012) Prescribing in breast feeding. In: *British National Formulary*. London: Pharmaceutical Press, 19.
- Sills E.S., Zegarelli D.J., Hoschander M.M. and Strider W.E. (1996) Clinical diagnosis and management of hormonally responsive oral pregnancy tumor (pyogenic granuloma). *Journal of Reproductive Medicine* 41: 467–470.
- Uzal F.A., Plattner B.L. and Hostetter J.M. (2015) Alimentary system. In: Maxie G.M. (ed.). *Jubb, Kennedy and Palmer’s Pathology of Domestic Animals, Volume 2*, 6th edn. London: Elsevier Health Sciences, 1–257.
- van der Gaag I., Vos J.H. and Goedegebuure S.A. (1988) Lobular capillary haemangiomas in two calves. *Journal of Comparative Pathology* 99: 353–356.
- Vos J.H., van der Gaag I., van Dijk J.E. and Wouda W. (1986). Lobular capillary haemangiomas in young horses. *Journal of Comparative Pathology* 96: 637–644.