

Manuscript Details

Manuscript number	YFOOT_2017_82_R2
Title	Anatomical variation of the Dorsalis pedis artery in a South African population- A Cadaveric Study
Article type	Research paper

Abstract

Abstract Background: The dorsalis pedis artery is responsible for blood supply to the dorsal aspect of the foot and is vital in the clinical assessment of the arterial supply thereof. Clinical assessment should consider anatomical variations of dorsalis pedis artery. Clearly, a thorough understanding of the potential variations of the vasculature in the area is important for precise clinical assessment of arterial supply to the foot. The aim of this study was to investigate the different branching patterns of the dorsalis pedis artery that exist in a South African population. Methods: Cadaveric study in which a total of 33 dissected lower limbs (27 adult cadavers and 6 partial wet lower limb specimens) of a South African population sample were studied. The course and branching pattern of the dorsalis pedis artery were photographed and documented. Results: Nine variations of the dorsalis pedis artery were recorded, with the standard branching pattern being the most common with an incidence of 36.36% and a completely absent dorsalis pedis artery variation was noted in 6.06% of the sample. Conclusion: Nine variations of the arterial anatomy of the dorsalis pedis artery were identified in this current study. Each of these may possibly alter the location or strength of the dorsalis pedis pulse affecting clinical assessment outcomes. Knowledge of dorsalis pedis variations may be useful to clinicians when making clinical decisions.

Keywords	Dorsalis pedis variations; Vascular Pattern; South African Population, Clinical significance of arterial variations,
Corresponding Author	Simiso Ntuli
Corresponding Author's Institution	University of Johannesburg
Order of Authors	Simiso Ntuli, Shahed Nalla, Kardem Kiter
Suggested reviewers	Bernhard Zipfel

Submission Files Included in this PDF

File Name [File Type]

Cover Letter.docx [Cover Letter]

Response to comments from the editors and reviewers.docx [Response to Reviewers (without Author Details)]

Highlights.docx [Highlights]

Acknowledgements.docx [Title Page (with Author Details)]

Authors Details.docx [Title Page (with Author Details)]

Anatomical variation of the Dorsalis pedis artery corrected 10.01.18.docx [Manuscript (without Author Details)]

Conflict of Interest.docx [Conflict of Interest]

To view all the submission files, including those not included in the PDF, click on the manuscript title on your EVISE Homepage, then click 'Download zip file'.

Anatomical variation of the *Dorsalis pedis* artery in a South African population- A Cadaveric Study

S.Ntuli¹

S. Nalla²

A. Kiter³

¹ Department of Podiatry, Faculty of Health Sciences, University of Johannesburg P O Box 524 Auckland Park 2006, South Africa.

² Department of Human Anatomy and Physiology, Faculty of Health Sciences, University of Johannesburg P O Box 524 Auckland Park 2006, South Africa.

³ Department of Podiatry, Faculty of Health Sciences, University of Johannesburg P O Box 524 Auckland Park 2006, South Africa.

1 **Abstract**

2 **Background:** The *dorsalis pedis* artery is responsible for blood supply to the dorsal aspect of the foot
3 and is vital in the clinical assessment of the arterial supply thereof. Clinical assessment should consider
4 anatomical variations of *dorsalis pedis* artery. Clearly, a thorough understanding of the potential
5 variations of the vasculature in the area is important for a precise clinical assessment of arterial supply
6 to the foot. The aim of this study was to investigate the different branching patterns of the *dorsalis pedis*
7 artery that exist in a South African population.

8 **Methods:** a Cadaveric study in which a total of 33 dissected lower limbs (27 adult cadavers and 6 partial
9 wet lower limb specimens) of a South African population sample were studied. The course and
10 branching pattern of the *dorsalis pedis* artery were photographed and documented.

11 **Results:** Nine variations of the *dorsalis pedis* artery were recorded, with the standard branching pattern
12 being the most common with an incidence of 36.36% and a completely absent *dorsalis pedis* artery
13 variation was noted in 6.06% of the sample.

14 **Conclusion:** Nine variations of the arterial anatomy of the *dorsalis pedis* artery were identified in this
15 current study. Each of these may possibly alter the location or strength of the *dorsalis pedis* pulse
16 affecting clinical assessment outcomes. Knowledge of *dorsalis pedis* variations may be useful to
17 clinicians when making clinical decisions.

18

19

20

21

22

23

24 **Key Words**

25 *Dorsalis pedis* variations; Vascular Pattern; South African Population, Clinical significance of arterial
26 variations,

1 **Introduction**

2 The *dorsalis pedis* artery (DPA) (*arteria dorsalis pedis*), is an artery that carries blood to the dorsum of
3 the foot. It arises at the anterior aspect of the ankle joint and is a continuation of the anterior tibial artery.
4 It terminates at the proximal part of the first intermetatarsal space, where it divides into two branches,
5 the first dorsal metatarsal artery and the deep plantar artery [1, 2].

6 In clinical practice, the *dorsalis pedis* artery is clinically invaluable in the assessment of blood
7 circulation to the foot [3]. During clinical training the importance of this artery is emphasised, for
8 example, the absence of the DPA pulsation in a child can lead to contracture and retard the trophic
9 growth of foot [4] and in a diabetic patient may be indicative of an at-risk foot [3]. Therefore, correct
10 assessment of blood supply to the foot is essential, as inaccurate findings have the potential to become
11 limb threatening conditions, such as necrosis and gangrene [3].

12 In order to ensure an accurate clinical assessment takes place, clinicians should have a thorough
13 understanding of the foot anatomy including the vascular anatomy of the foot, and variations thereof.
14 This will enable clinicians, to differentiate anatomical variations from clinical conditions such as
15 *dorsalis pedis* aneurysm, deep vein thrombosis and peripheral arterial diseases [4, 5]. Many anatomical
16 reference books provide a standardised anatomical location of the arteries of the foot, however, it is
17 important to recognise that there are variations of anatomy, which are crucial to consider during a
18 clinical assessment [2, 6, 7]. Therefore, a full understanding of the vascular supply of the foot taking
19 into consideration anatomical variations is needed. In our context with a particular emphasis on the
20 South African demographics, such variations must include population background.

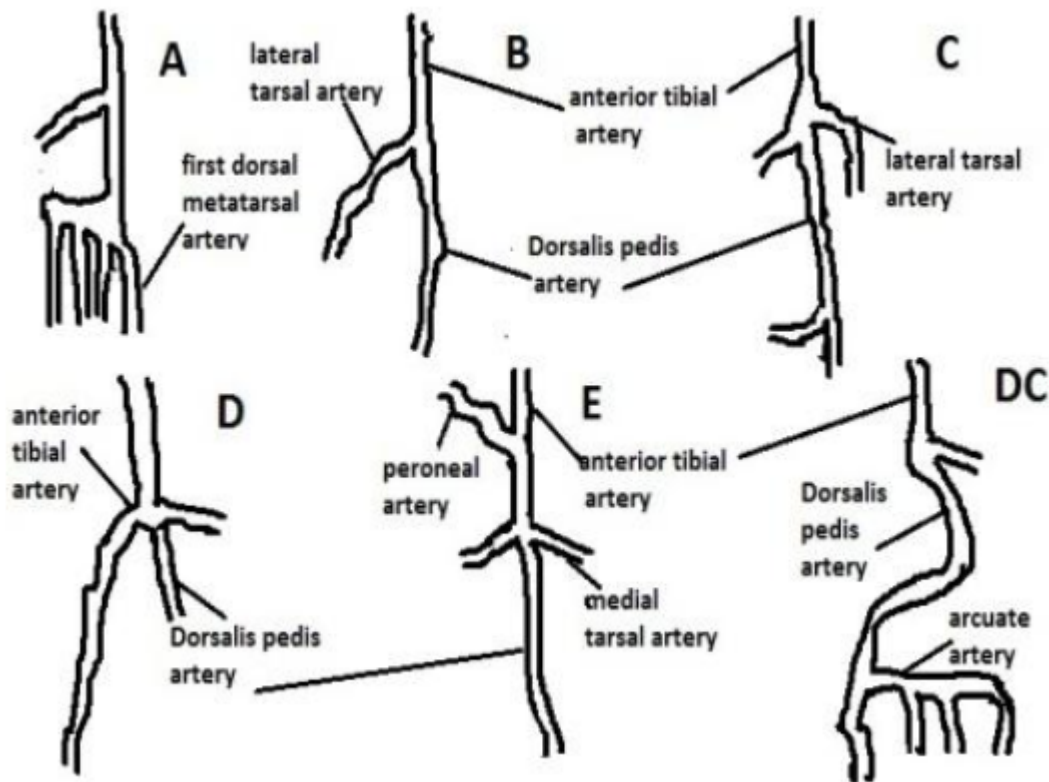
21 A number of studies have previously examined and confirmed the anatomical variations in the *dorsalis*
22 *pedis* artery [5, 7, 8-10] and only one, which investigated the size and branching pattern of the DPA
23 [11] in a South African population.

24 A recent study by Kulkarni and Ramesh classified branching differences of the *dorsalis pedis* artery
25 into five types, each representative of a particular branching pattern of the artery [8]. They collected
26 data from 33 partial limbs, all of which were from Indian population. They subsequently classified
27 variations into five types and their incidence noted. In addition to these classification types, Kulkarni
28 and Ramesh found that only two of the partial specimens demonstrated a laterally deviated *dorsalis*
29 *pedis* artery, and as such, no classification was assigned to this variation [8]. The standardised pattern
30 of vascularisation was an uncommon finding in their study, with only 15.2% of specimens
31 demonstrating this pattern.

32

33

34



1
 2 **Figure 1** Types of variations of *dorsalis pedis* artery. (with permission Kulkarni & Ramesh 2012)
 3 Suggested key to Types or patterns *dorsalis pedis* artery variations as suggested by Kulkarni & Ramesh
 4 is presented in the figure legend.
 5 **Figure legend 1.** Key to Types (Kulkarni & Ramesh 2012)

<p>Type A— Usual pattern of arterial tree of the dorsum of the foot. Dorsalis pedis artery along its course divided into lateral and medial tarsal artery, first dorsal metatarsal artery and arcuate artery.</p>
<p>Type B —Anterior tibial artery divides into a larger lateral tarsal artery and a smaller <i>dorsalis pedis</i> artery.</p>
<p>Type C — Dorsalis pedis artery is absent as an independent vessel and becomes merely a loop in the dorsum arterial pattern.</p>
<p>Type D — Reduction of the anterior tibial artery and its branches and increasing participation of arteries of sole in the supply of dorsum. Dorsalis pedis artery is not recognizable even as a loop and anterior tibial artery continue downwards as a central channel with reduced size. Pulses not clinically palpable.</p>
<p>Type E — Increasing presence of anterior peroneal branch from the posterior tibial artery. Plantar tibial vessels still take a prominent part in arterial supply. Dorsalis pedis artery along with its branch lateral tarsal artery is clinically not palpable.</p>
<p>Type DC — <i>dorsalis pedis</i> artery exhibits lateral deviation.</p>

1 Rajeshwari et al. on a sample of 42 Indian population specimens found the classic vascularisation
2 pattern in 54.76% of the specimens and they described six types of variations of the *dorsalis pedis* artery
3 and its branches [12]. Their results were similar to a study conducted by Vijayalakshmi et al., which
4 also established six types of variation in the vascular pattern of the *dorsalis pedis* artery and its branches
5 within a sample of 50 Indian specimens [5]. Similar to Rajeshwari et al., Vijayalakshmi et al. recorded
6 the classic pattern in 56% of specimens; the only exception was the arcuate artery forming a U-shaped
7 loop.

8 In that study, Yamada et al. noted an absent *dorsalis pedis* artery in 6.7% of cases within a sample of
9 17 cadavers from the USA and 33% of the sample demonstrated an absent arcuate artery [13]. A study
10 conducted by McKeon et al. utilising a sample of 60 USA specimens also found variations in the
11 branching of the *dorsalis pedis* artery [14].

12 Vazquez et al. studied the variations of the *dorsalis pedis* artery and the anterior tibial artery and found
13 two patterns of branching of the *dorsalis pedis* artery in a sample of 150 cadavers from Spain [15]. The
14 majority of the sample 95.7% had the standard vascularisation pattern and in 1.3% of the sample, the
15 perforating branch of the fibular artery replaced the *dorsalis pedis* artery's course. Reich looked at a
16 sample of 70 individual specimens from a North American population (of different populations and
17 sex) and found that 74% of specimens exhibited a classic vascular pattern and only 14.2% had an absent
18 *dorsalis pedis* artery [16]. Adachi examined 250 individual specimens obtained from a Japanese
19 population, which demonstrated the standardised vasculature in 51.6% of specimens [17], whilst Salvi
20 found the classic pattern in 68.5% of 200 individual specimens taken from an Italian population, as
21 reported by Reich [16].

22 The *dorsalis pedis* artery is one example of an anatomical structure that potentially shows variation as
23 witnessed from several studies, which have established the presence of a number of variations of the
24 *dorsalis pedis*, and have sought to classify them. However, the researchers found no current studies of
25 the *dorsalis pedis* artery and its branching patterns on any African population. Therefore, this study
26 aimed to investigate and document the arterial variations of the *dorsalis pedis* artery observed within
27 the South African population.

28 The population of South Africa is estimated at 56.52 million, with the Black African population in the
29 majority at 80.8% (45.6 million), Coloured 8.8% (4.96 million), Indian/ Asian 2.5% (1.40 million) and
30 the White population estimated at 8.0% (4.49 million). Fifty-one percent (28.9 million) of the
31 population is female [18]. Population background in this study was documented as either Black African
32 or White in accordance with the South African Mid-year population estimates, 2015 [18]. This is in line
33 with the sample population of the study as Black Africans and females were in the majority.

34

1 **2. Materials and Methods**

2 **2.1 Population and Sample**

3 Convenience purposive sampling methods were used to include the entire cadaver population in this
4 descriptive study. The sample consisted of 27 adult cadavers and 6 partial lower limb formalin preserved
5 specimens of both sexes i.e. 17 females and 16 males giving a total of 33 pairs of lower limbs. The
6 sample demographics were of 19 Black African and 8 White cadavers, and 4 Black African and 2 White
7 partial wet specimens. Both feet were examined. Only Black African and White cadavers or wet
8 specimens were available for inclusion in this study.

9 The study population includes all cadavers at the Anatomy Complex of the Faculty of Health Sciences,
10 University of Johannesburg and the School of Anatomical Sciences of the Faculty of Health Sciences,
11 University of the Witwatersrand, Johannesburg.

12 Research Ethics Committee of the Faculty of Health Sciences, University of Johannesburg issued
13 ethical clearance for this study (Ethics Numbers: REC-241112-035).

14 **2.2 Data Collection**

15 The population group i.e. Black African or White and sex of each cadaver were documented
16 accordingly. In cases where Health Sciences students had already dissected the dorsum of the foot, the
17 branching pattern of the *dorsalis pedis* artery was observed. If the artery had not been exposed yet at
18 the time of data collection, the researcher completed the dissection. The *dorsalis pedis* artery and its
19 branches were photographed using a Sony Alpha SLT-A33 digital camera. The pattern of
20 vascularisation was classified into groups based on the branching pattern groupings used by Kulkarni
21 & Ramesh [8], and Rajeshwari et al. [12]. This classification was chosen as the most descriptive
22 classification available in the literature and would allow an ease of comparison between the results from
23 the current study and the literature.

24 *2.2.1. Dissection Protocol*

25 In cases where the dorsum of the foot was not yet exposed, the dissection process was kept very
26 superficial with the cadaver in a supine position. A short longitudinal incision was made at the midline
27 of the foot just lateral to the *extensor hallucis longus* tendon from the ankle to the base of the third toe.
28 The extensor retinacula were left intact.

29 Thereafter, two short transverse incisions were made across the ankle joint and across the base of the
30 toes from medial to lateral. The skin was lifted from the subcutaneous fatty tissue with blunt dissection
31 to reveal the *dorsalis pedis* artery. The artery was cleaned with a probe, and the origin of the branches
32 of the artery was documented, therefore the dissection remained superficial with no disturbance of
33 deeper tissues.

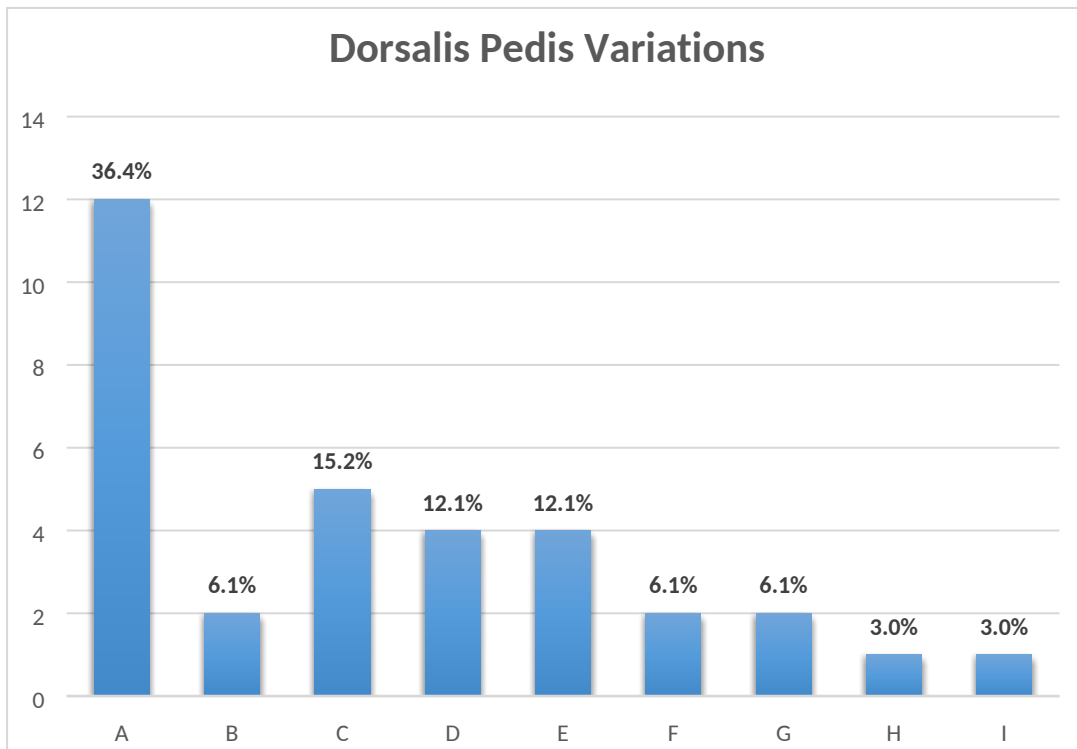
1 **2.3 Data Analysis**

2 Collected data were analysed with the use of descriptive statistics. Frequency and percentages were
3 used to describe the variations in *dorsalis pedis* artery. During the analysis, comparisons were made
4 between the groups: male and female as well as between the two population groups. The results are
5 presented in the form of photographs, diagrams, tables, and charts which were compiled in Microsoft
6 Excel 2013.

7 **3. Results**

8 **3.1 *Dorsalis pedis* Variations**

9 In this study, we observed nine *dorsalis pedis* arterial patterns and the distribution of these patterns in
10 the studied sample as presented in Figure 2.



11
12 **Figure 2.** *Dorsalis pedis* patterns. (For the definitions of A to I, refer to Table 2 and Figures 3.1 to
13 3.9).

14
15 **3.2 *Dorsalis pedis* variation per sex and population group**

16 Table 1 presents the findings of *dorsalis pedis* patterns observed in the two population groups and
17 between males and females.

18
19

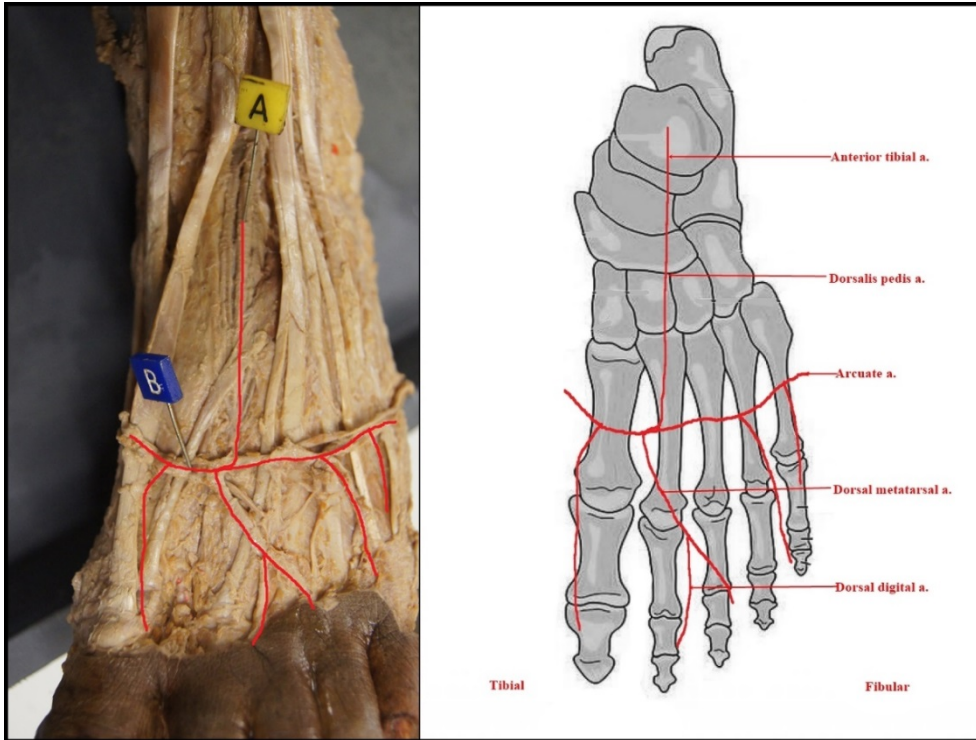
1 **Table 1** Variations of the *dorsalis pedis* artery per sex and population group.

Type	Pattern	Total n = 33 (%)		Black African n = 23 (%)		White n = 10 (%)	
		Male n = 16	Female n = 17	Male n = 14	Female n = 9	Male n = 2	Female n = 8
A	Standard vascular pattern	6 (37.50)	6 (35.29)	6 (42.86)	2 (22.22)		4 (50.00)
B	<i>Dorsalis pedis</i> artery absent	2 (12.50)		2 (14.29)			
C	Arcuate artery absent	1 (6.25)	4 (23.53)		3 (33.33)	1 (50.00)	1 (12.50)
D	Absence of arcuate artery and variation in the number of lateral tarsal arteries	1 (6.25)	3 (17.65)	1 (7.14)			3 (37.50)
E	Variation in the origin of second dorsal metatarsal artery	1 (6.25)	3 (17.65)	1 (7.14)	3 (33.33)		
F	<i>Dorsalis pedis</i> present with variation in branching pattern	1 (6.25)	1 (5.88)	1 (7.14)	1 (11.11)		
G	Variation of origin of <i>dorsalis pedis</i> and lateral tarsal arteries	2 (12.50)		1 (7.14)		1 (50.00)	
H	Poorly formed <i>dorsalis pedis</i> artery and lateral tarsal artery	1 (6.25)		1 (7.14)			
I	Arcuate artery forms a U-shaped loop	1 (6.25)		1 (7.14)			

2

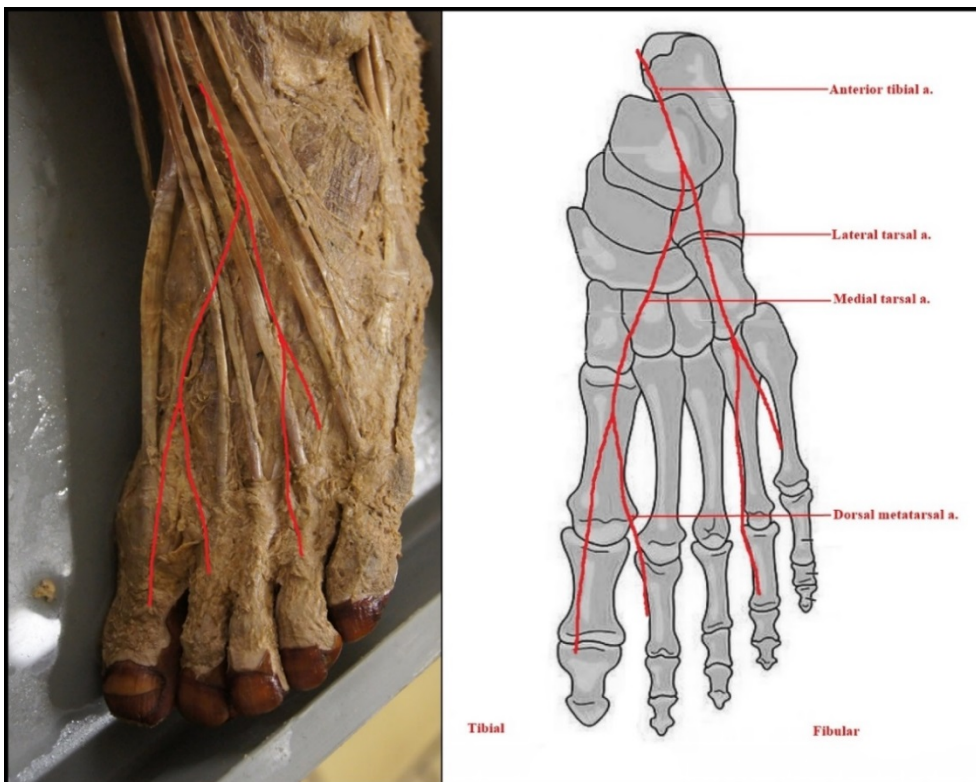
3 Figures 3.1–3.9 illustrates the *dorsalis pedis artery* patterns observed in this study. The most common
 4 branching pattern recorded 36.4% in this study was Pattern type A, which is representative of the
 5 standard pattern of vascularisation of the *dorsalis pedis* artery as seen in figure 3.1.

6



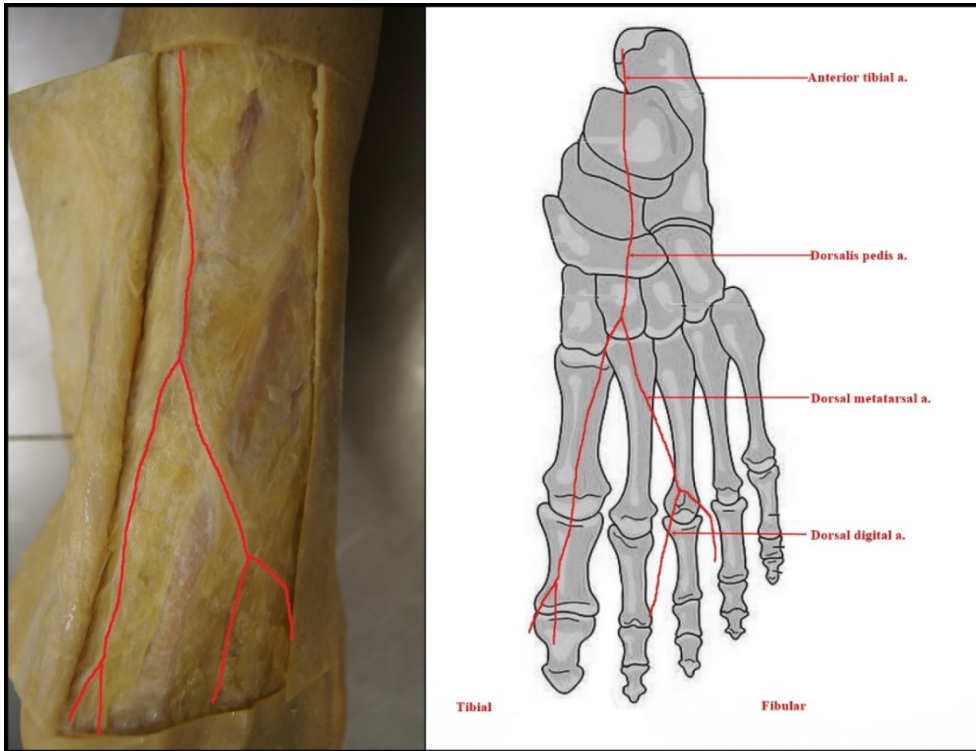
1
2 **Figure 3.1. Pattern A - Standard Vascular Pattern**

3 Pattern type B demonstrates specimens in which the *dorsalis pedis* artery is absent. Only 6.1% of the
4 total sample population had this anomaly present, making it a rare finding. This variation is presented
5 in figure 3.2



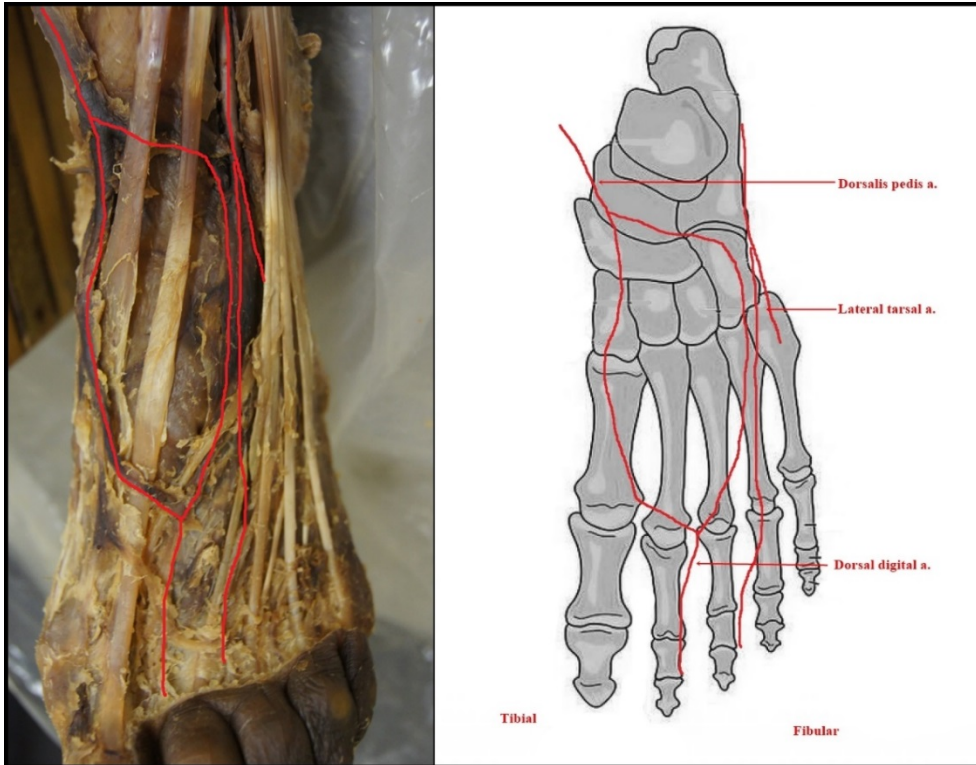
6
7 **Figure 3.2: Pattern B – *Dorsalis pedis* artery absent**

1 Pattern type C recorded in 15.2% of the population, which lacked an arcuate artery. This was the second
2 most common variation of the branching pattern of the *dorsalis pedis* artery observed in this study.



3
4 **Figure 3.3: Pattern C - Arcuate artery absent**

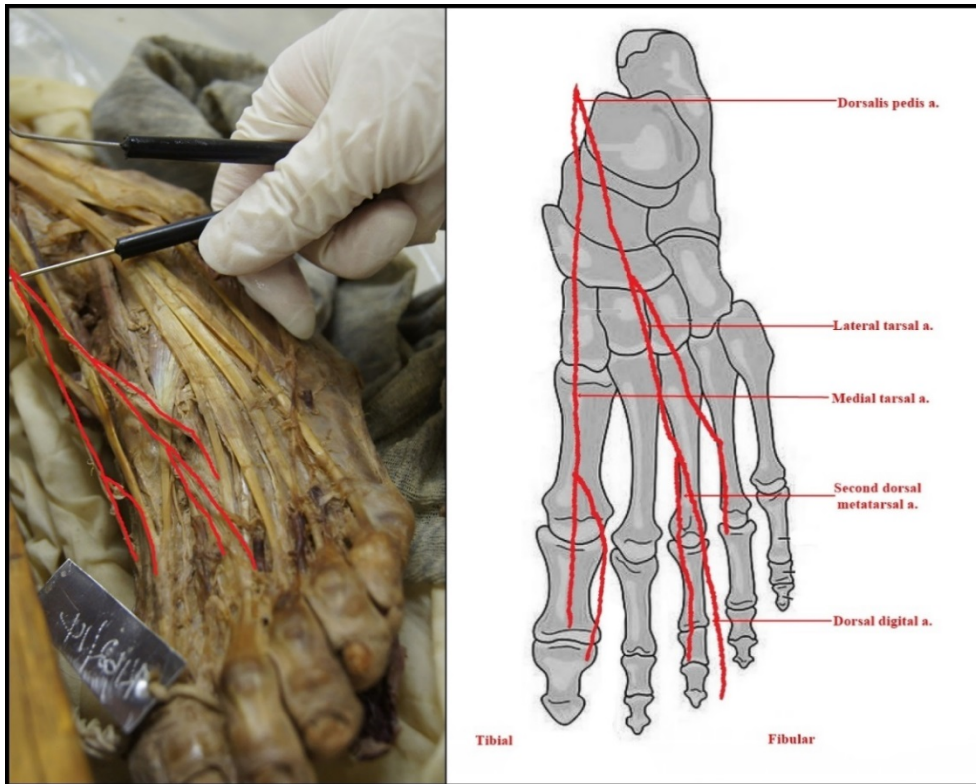
5 Pattern type D is similar to type C in that the arcuate artery is absent. However, type D is different from
6 type C as the lateral tarsal arteries that branch off from the *dorsalis pedis* artery vary in number. This
7 pattern was recorded in 12.1% of the total sample population demonstrate this variation and is presented
8 in figure 3.4.



1
2
3
4
5
6
7

Figure 3.4: Pattern D - Absence of arcuate artery and variation in the number of lateral tarsal arteries.

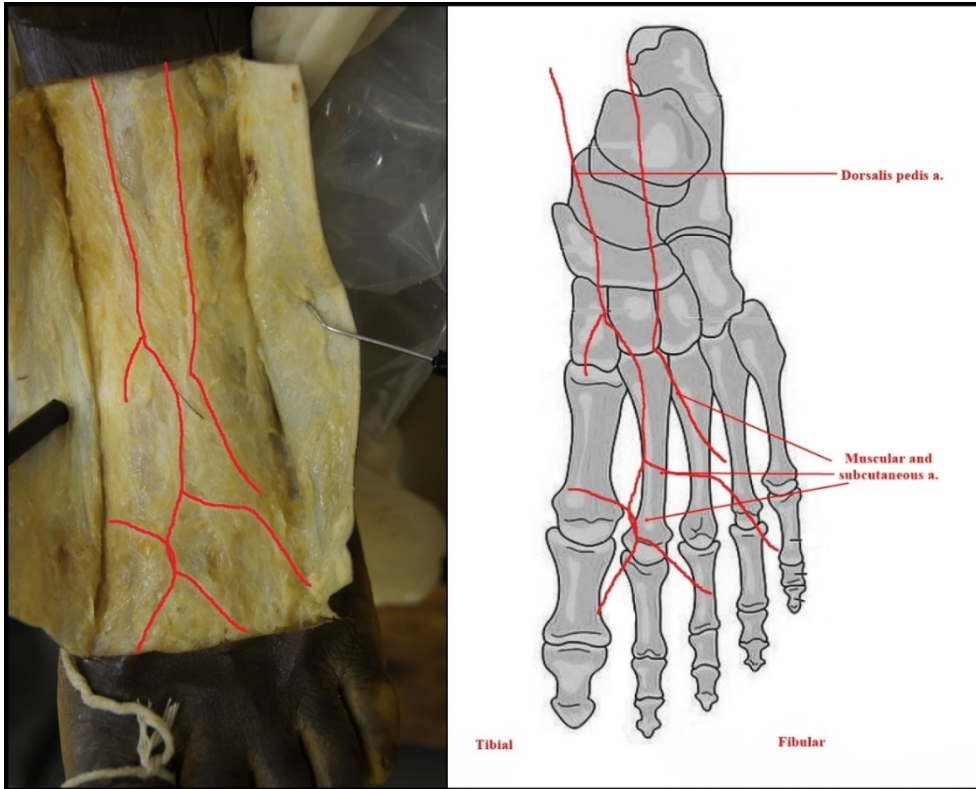
Pattern type E is representative of the population that have variations in the origin of the second dorsal metatarsal artery. As with type D, only 12.1% of our study population demonstrated this variation in their vascular pattern as seen in figure 3.5.



1

2 **Figure 3.5: Pattern E** - Variation in the origin of the second dorsal metatarsal artery.

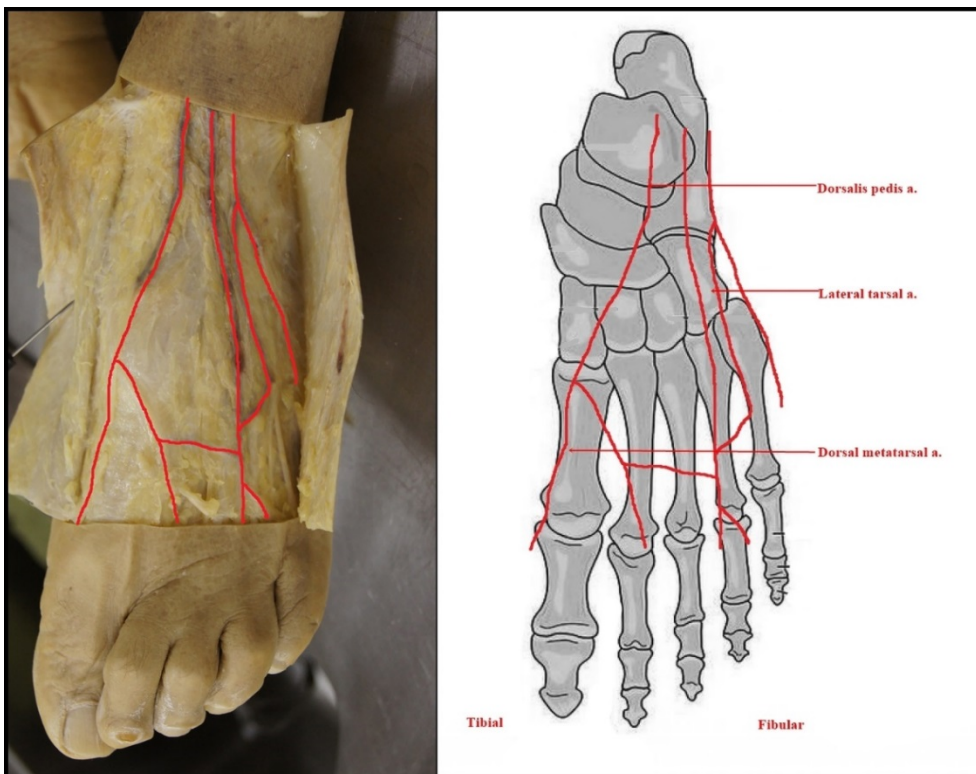
3 Pattern type F consists of the population in which the *dorsalis pedis* artery is present with variation in
 4 the branching pattern. The 6.1% of the study population that had this pattern of vascularisation had the
 5 *dorsalis pedis* artery present, however, its branches to the rest of the foot were somewhat arbitrary, and
 6 did not follow any discernable pattern. See figure 3.5 for the actual presentation of this pattern.



1

2 **Figure 3.6: Pattern F** - *Dorsalis pedis* present with variation in the branching pattern.

3 Pattern type G was recorded in 6.1% of the sample population in which both the origin of the *dorsalis*
 4 *pedis* artery and the lateral tarsal arteries were varied.

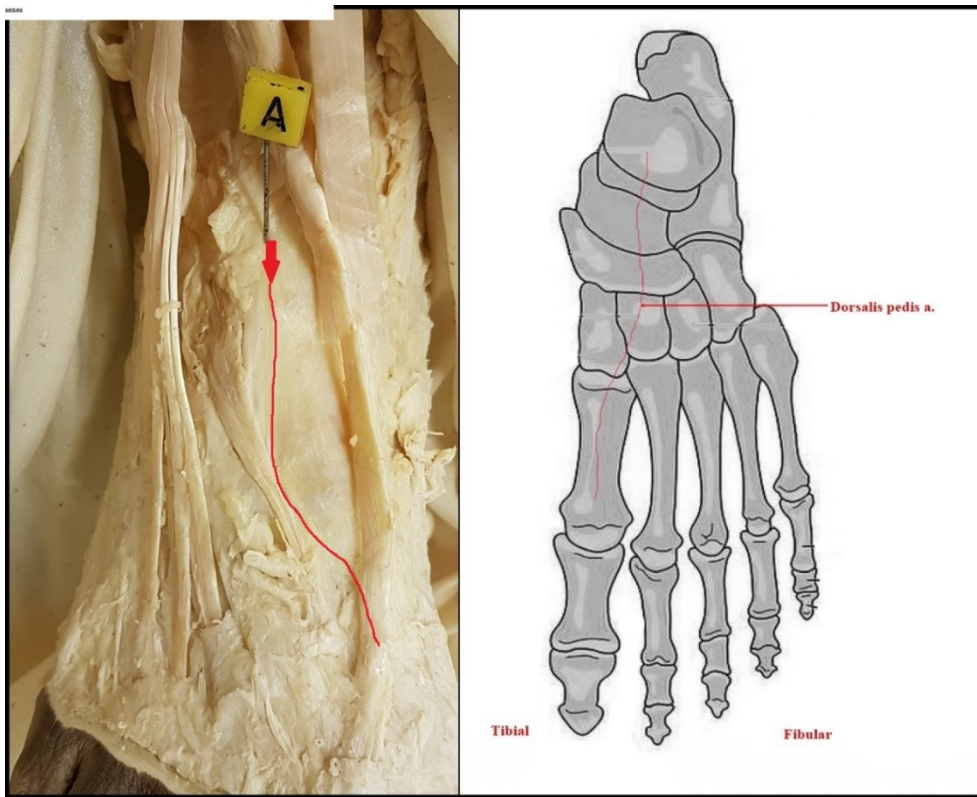


5

6 **Figure 3.7: Pattern G** - Variation of origin of *dorsalis pedis* and lateral tarsal arteries

1 Pattern type H was noted in 3.0% of the study population and represents a poorly formed *dorsalis pedis*
2 artery and lateral tarsal arteries.

3

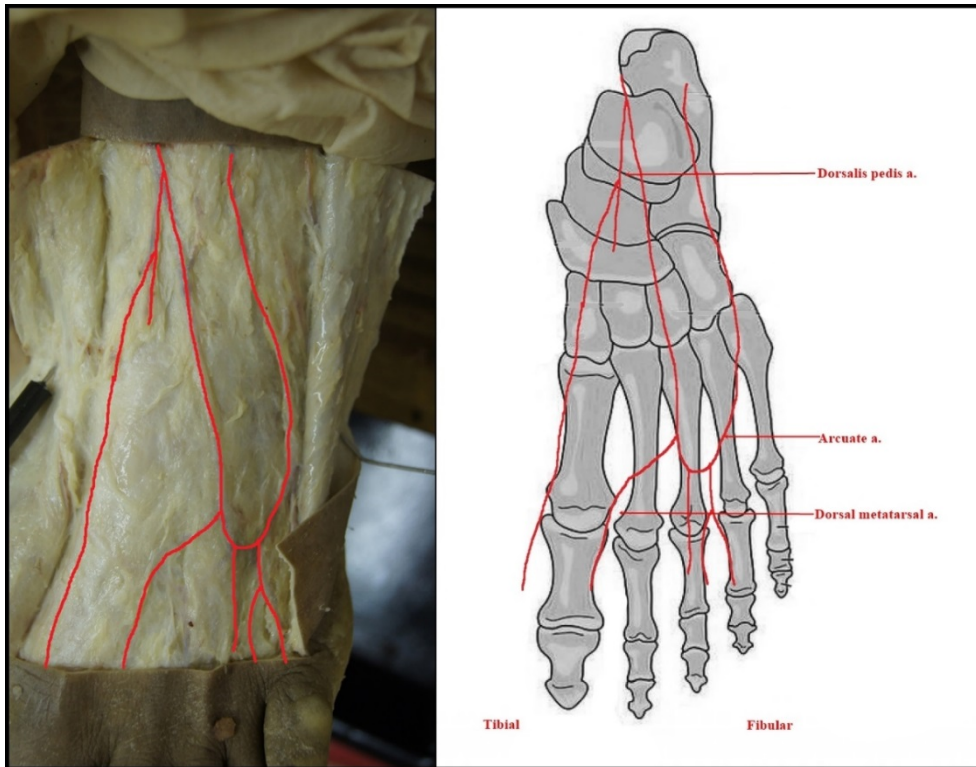


4

5 **Figure 3.8: Pattern H** - Poorly formed *dorsalis pedis* artery and lateral tarsal artery

6 Pattern type I was found in 3.0% of the population and consists of an arcuate artery that forms a U-
7 shaped loop, rather than the standard pattern of vascularisation.

8



1
2 **Figure 3.9: Pattern I - Arcuate artery forms a U-shaped loop**

3
4 **4. Discussion**

5 This study recorded the anatomical variation of the *dorsalis pedis* artery in a South African population
6 sample. Pattern B; E; F; H & I was noted only on “Black Africans specimens”, pattern B; G; H & I only
7 in males, C & D more in whites. The findings suggest that there are variations in *dorsalis pedis* artery
8 (DPA) patterns within the South African population. However, the limited sample does not allow the
9 researchers to make definitive conclusions on population specific variations.

10 *Dorsalis pedis* artery is the main source of blood supply to the dorsum of the foot and as such, the
11 knowledge of any variation in its course and distribution is clinically important. In clinical practice,
12 DPA is assessed to evaluate patients with arterial disease and to record peripheral arterial supply.
13 Normally, in its course, it provides the medial tarsal artery, lateral tarsal artery, first dorsal metatarsal
14 artery, arcuate artery and deep plantar artery, which enters the sole after passing between the two heads
15 of first *dorsal interosseous* muscle and takes part in the formation of the plantar arch [19].

16 Pattern A, which represents the standard pattern of vascularisation of the *dorsalis pedis* artery, was the
17 most commonly observed branching type in our sample population at 36.36%. It was present equally
18 amongst male and female specimens though, more common in Black African specimens. However, this
19 may be due to the higher number of Black African specimens compared to White specimens in this
20 study. While the current study has found a lower percentage of cases with pattern A, the findings
21 compare well with those of Rajeshwariet al. [12] and Vijayalakshmi et al. [5] who also found pattern A

1 to be the most prevalent. In their studies, they were using one population group, which make the current
 2 findings compare moderately well as we had two population groups. In Table 2 the findings of the
 3 current study and those of three recent similar studies are presented.

Table 2: Comparison of current study findings with recent other findings.

Type	Pattern	Current Study	Kulkarni & Ramesh (2012)	Rajeshwari et al. (2013)	Vijayalakshmi (2011)
A	Standard vascular pattern	36.36%	15.2%	54.76%	56%
B	Dorsalis pedis artery absent	6.06%	42.4%	9.52%	2%
C	Arcuate artery absent	15.15%	N/A	16.67%	6%
D	Absence of arcuate artery and variation in the number of lateral tarsal arteries	12.12%	N/A	2.38%	N/A
E	Variation in the origin of second dorsal metatarsal artery	12.12%	N/A	N/A	N/A
F	Dorsalis pedis present with variation in branching pattern	6.06%	N/A	14.29%	16%
G	Variation of origin of <i>dorsalis pedis</i> and lateral tarsal arteries	6.06%	9.1%	2.38%	8%
H	Poorly formed <i>dorsalis pedis</i> artery and lateral tarsal artery	3.03%	18.2%	N/A	N/A
I	Arcuate artery forms a U-shaped loop	3.03%	N/A	2.38%	N/A

4
 5 Pattern B represents an absence of the *dorsalis pedis* artery. In this variation of the branching pattern,
 6 the anterior tibial artery bifurcates to form the medial and lateral tarsal arteries but does not form the
 7 *dorsalis pedis* artery. This is an uncommon finding; the current study found 6.06% of specimens
 8 demonstrated a complete absence of the *dorsalis pedis* artery. Both of these specimens were Black
 9 African males. This finding is comparable to that of Rajeshwari et al. who found that 9.52% of their
 10 specimens lacked a *dorsalis pedis* artery [12]. In this regard, the current study and that of Rajeshwari et
 11 al. are at odds with Kulkarni and Ramesh who reported the absence of the *dorsalis pedis* artery in 42.4%
 12 of their 33 Indian specimens [7]. The current findings are also in line with Yamada et al., Reich and
 13 Huber who all described an absence of the *dorsalis pedis* artery in a small percentage of their specimens'
 14 [13, 16, 20]. Huber reported an absence of *dorsalis pedis* artery in 14% in 200 cases [20] and Yamada
 15 et al. reported a complete absence of *dorsalis pedis* in 6.7% of their sample [13].

16 Pattern C is indicative of an absent arcuate artery, that is to say, the arcuate artery was not present in
 17 any capacity within the vascularisation of the dorsum of the foot. This pattern variation was observed
 18 in 15.15% of the sample and predominantly in the Black African female specimens. The findings of the

1 study are consistent with those of Rajeshwari et al. who reported an absent arcuate artery in 16% of
2 their sample whilst Yamada et al. reported this finding in 33% of specimens [12, 13].

3 Pattern D is similar to pattern C; however, it differs from type C by the variation in the number of lateral
4 tarsal arteries supplying the dorsum of the foot as a form of compensation for the lack of an arcuate
5 artery. These lateral tarsal arteries arise from the *dorsalis pedis* artery as it courses distally over the foot.
6 We found this variation in 12.12% of the specimens observed and mostly in White females. This is an
7 unusual finding and only one other study has reported this pattern of compensation for an absent arcuate
8 artery. Only Rajeshwari et al. has previously reported similar finding and they reported a 2.38%
9 incidence of this vascular variation [12].

10 Pattern E is indicative of a variation in the origin of the second dorsal metatarsal artery. This occurs
11 when the *dorsalis pedis* artery bifurcates to form the medial and lateral tarsal arteries, and the former
12 further divides to form the first and second dorsal metatarsal arteries. Modification of the origin of the
13 artery may result from an embryological developmental interruption in the expected area, causing the
14 vasculature to adapt and form an arterial supply via an alternate course. [21]. The current study found
15 this pattern in 12.12% of the sample population and predominantly in Black African female specimens.

16 Pattern F occurs when the *dorsalis pedis* artery is present with variation in the branching pattern.
17 Rajeshwari et al. described this as arbitrary branches arising from the *dorsalis pedis* artery to supply the
18 dorsum of the foot [12]. This pattern of vasculature arise due to individual inconsistencies in the
19 formation of vessels, and not because of any impairment or disruption during angiogenesis [21]. These
20 indiscriminate branches supply the dorsum of the foot sufficiently, consequently, making the presence
21 of additional arteries redundant, hence, they simply do not develop [7, 21]. The current study found
22 this branching pattern in 6.06% of cases, equally distributed between male and female specimens (both
23 specimens were Black African). As alluded to, Rajeshwari et al. reported a higher incidence of 14.29%
24 of this pattern [12]. Hamada et al. and Saeed et al. both observed a similar percentage of specimens
25 with pattern type F [22, 23].

26 Pattern G is indicative of a variation of the origin of *dorsalis pedis* artery and lateral tarsal arteries. This
27 can occur when the tibialis anterior artery divides into additional branches that then form the *dorsalis*
28 *pedis* artery and lateral tarsal artery. Literature suggests that the alternative origin of arteries can follow
29 disruption of embryological development of the vasculature supplying the area [6, 7]. This pattern was
30 observed in only two specimens 6.1%, both males one Black African and one White. Huber found a
31 small percentage of cases where the *dorsalis pedis* artery arose from the peroneal artery; possibly, due
32 to developmental disruption of the anterior tibial artery [20] and Lee et al [24] reported this pattern in
33 9.4% of cases.

34 Pattern H occurs when the *dorsalis pedis* artery and lateral tarsal artery do not develop fully, remaining
35 poorly formed and clinically not palpable. This is most likely due to suboptimal conditions during

1 embryological development leading to the incomplete formation of the arteries [19]. Only 3.0% (one
2 Black African male specimen) in the study exhibited this pattern. Adachi reported only a 3% incidence
3 of this pattern type, confirming the infrequency of pattern type H [17].

4 Pattern I, this pattern of vascularisation occurs when the arcuate artery forms a U-shaped loop through
5 the unification of the lateral tarsal arteries. This is most likely a product of the anterior tibial artery or
6 the *dorsalis pedis* artery merging with the arcuate artery during development in utero [7]. This pattern
7 was observed in 3.0% (one Black male African specimen) had this variation in the current study.
8 Rajeshwari et al. confirmed the small frequency of this pattern type with a finding of only 2.38% of
9 their sample population [7].

10 Variations of the arteries of the lower limb, including absence, variant courses and replacement areas
11 of vascularisation have important clinical significance and implications for clinicians [15, 25, 26].

12 In most cases, an absence of *DPA* pulsations is associated with peripheral vascular disease such as
13 Buerger's disease, Pseudo – occlusion of *dorsalis pedis* artery, diabetic autonomic neuropathy [27].
14 However, there is a need to consider an absence of the *DPA* pulsation as one of the *DPA* patterns as
15 seen 6.06% and 15.15% of specimens in this study in whom we observed pattern B & C respectively
16 both associated with the absence of the *dorsalis pedis* artery and arcuate artery. In pattern D & E seen
17 in 12.12%, *DPA* along with its branch lateral tarsal artery may be clinically impalpable [8]. In a clinical
18 environment such presentations may be misinterpreted as a pathological state, hence the need for
19 knowledge of anatomical variations in the course and distribution of the *dorsalis pedis* artery. In most
20 cases, clinicians use the presence of pedal pulses to rule out rules out vascular insufficiencies. However,
21 anatomical variations my make *dorsalis pedis* artery interesting if not a little complex. Thus, awareness
22 of the *DPA* variations is useful to clinicians during an arterial assessment of patients. Precise knowledge
23 of the vascular anatomy of foot and ankle is indispensable to clinicians for example knowledge of the
24 vascular course of *dorsalis pedis* artery to understand for example avascular necrosis of talus [28].

25 Anatomical variations in *dorsalis pedis* artery might be prevalent in patient population. Thus, it is
26 essential that clinicians have sound knowledge about this artery. Clinicians are mindful of the factors
27 that may impede *DPA* pulsation including systolic perfusion pressure, arterial size, and amount of
28 subcutaneous fat, oedema, fingertip insensitivity and *ligamentum laciniatum* [28]. However, it remains
29 unclear how familiar are clinicians with potential anatomical variations of the *dorsalis pedis* artery and
30 how these may influence their clinical practice.

31 Therefore, there is a need for these and many other similar findings to begin to influence clinical
32 practice. Further studies should be done on larger samples and clinical correlations of *dorsalis pedis*
33 artery variations within the South African population should be investigated.

34

1 **5. Conclusion**

2 The *dorsalis pedis* artery is subject to variation, ranging from an abnormal course, origin, distribution
3 to complete absence. In this study, nine *dorsalis pedis* artery variations were identified in the sample.
4 Each of these may have an impact of possibly altering the location or strength of the *dorsalis pedis*
5 pulse during clinical examination. Furthermore, some pattern types may present with a clinically
6 impalpable pulse due to the absence of a fully developed *dorsalis pedis* artery. Knowledge of the
7 different possible patterns of vascularisation would assist the clinician in identifying alternative
8 locations of the *dorsalis pedis* artery on the dorsum of the foot. Therefore, understanding of possible
9 DPA variations should be useful to clinicians when making a clinical decision on whether the absence
10 of pulsating *dorsalis pedis* artery is due to pathology of the vessel or the artery variation.

11 **Brief Summary**

12 **Type A** Standard vascular pattern: most observed pattern noted predominantly in Black Africans.

13 **Type B** Dorsalis pedis artery absent: observed only in Black African males.

14 **Type C** Arcuate artery absent: observed predominantly in females

15 **Type D** Absence of arcuate artery and variation in the number of lateral tarsal arteries: observed
16 predominantly in females of both population groups but predominantly in Whites.

17 **Type E** Variation in the origin of second dorsal metatarsal artery: observed predominantly in Black
18 African females.

19 **Type F** Dorsalis pedis present with variation in branching pattern: observed only in Black Africans

20 **Type G** Variation of origin of dorsalis pedis and lateral tarsal arteries: observed only in males

21 **Type H** Poorly formed dorsalis pedis artery and lateral tarsal artery: observed only in Black Africans

22 **Type I** Arcuate artery forms a U-shaped loop: observed only in Black Africans males.

23

24 **Authors Contribution**

25 SN— concept and study design development, supervision, initial draft, and revisions.

26 SN— concept and study design development, supervision and draft revisions.

27 AK—concept, data collection, analysis and interpretation.

28

29 **Disclosure**

30 Authors declare no conflicts of interest in relation to this work and approve the draft.

31 **Abbreviations**

32 DPA— *dorsalis pedis artery*

1 UJ— University of Johannesburg

2 SA— South Africa

3

References

1. Janhawi J Bhandarkar. International Journal Of Advances In Case Reports, 2016;3(6):273-275.
2. Drake RL, Vogl AW, Mitchell AWM. Gray's Anatomy for Students. 2nd ed. PA: Churchill Livingstone; 2010.
3. Frowen P, O'Donnell M, Lorimer D, Burrow G. Neale's Disorders of the Foot. 8th ed. Edinburgh: Churchill Livingstone; 2010.
4. Kennedy Legel, Maxime Savard, Christopher J Blanco and Chaminda Jayanetti, *Dorsalis pedis* aneurysm: A case report and review of the literature, The foot and ankle Journal, 1 (11), 2008, 1.
5. Vijayalakshmi S, Raghunath G, Shenoy V. Anatomical study of *Dorsalis pedis* Artery and Its Clinical Correlations. JCDR. 2011;5(2):287-290.
6. Romanes GJ. Cunningham's Manual of Practical Anatomy: Volume I: Upper and Lower Limbs. UK: Oxford University Press; 1986.
7. Willan PLT, Humpherson JR. Concepts of Variation and Normality in Morphology: Important Issues at Risk of Neglect in Modern Undergraduate Medical Courses. Clin Anat. 1999;12(3):186-190.
8. Kulkarni V, Ramesh BR. A Morphological Study of *Dorsalis pedis* Artery and Its Clinical Correlation. IOSR-JPBS. 2012;2(3):14-19.
9. Cheung CC, Keogh M, Alashkham A. Variations in origin and course of the *Dorsalis pedis* artery: A case study. Int J Anat Var. 2017;10(1):001-3.
10. Parikh S, Dawe E, Lee C, Whitehead-Clarke T, Smith C, Bendall S. Ann R. Coll Surg Engl. 2017 Apr; 99(4): 286–288. Published online 2016 Sep 23. doi: 10.1308/rcsann.2016.0288
11. Prigge L, Briers N. 2016. A Description of the Size and Distal Branching Pattern of the *Dorsalis pedis* Artery: A Cadaveric Study. Anatomy Journal of Africa. 5: 644 – 649.
12. Rajeshwari MS, Roshankumar BN, Vijayakumar. An Anatomical Study on *Dorsalis pedis* artery. IJAR. 2013;1(2):88-92.
13. Yamada T, Gloviczki P, Bower TC, Naessens JM, Carmichael SW. Variations of the arterial anatomy of the foot [abstract]. Am J Surg. 1993;166(2):130-135
14. Kathleen E. McKeon, Jeremy J. McCormick, Jeffrey E. Johnson, Sandra E. Klein Foot Ankle Int. 2012 Oct; 33(10): 857–861. doi: DOI: 10.3113/FAI.2012.0857
15. Vazquez T, Rodríguez-Niedenfuhr M, Parkin I, Viejo F, Sanudo JR. Anatomic study of blood supply of the dorsum of the foot and ankle [abstract]. Arthroscopy. 2006; 22(3):287–290.
16. Reich RS. The Pulses of the Foot: Their Value in the Diagnosis of Peripheral Circulatory Disease. Ann Surg. 1934; 99(4):613-622.

17. Adachi, B. Das Arteriensystem der Japaner. Kyoto, 1928.
18. Statistics South Africa. Mid-year population estimates: 2017 available at <https://www.statssa.gov.za/publications/>.
19. Gray H. Development of arteries of Lower limb, Gray's textbook of Anatomy, The Anatomical basis of Medicine and Surgery, Churchill living stone. London .1995, 38th edition. pp 320
20. Huber JF. The arterial network supplying the dorsum of foot. Anatomical Records 1941; 80: 373.
21. Kelikian AS, editor. Sarrafian's Anatomy of the Foot and Ankle. 3rd ed. PA: Lippincott Williams & Wilkins; 2011.
22. Hamada N, Ikuta Y, Ikeda A. Arteriographic study of the arterial supply of the foot. Surgical and Radiological Anatomy.1993;15:187-92
23. Saeed EM, Amal Abd El-monisif Madiha A. El-Sayed, Aly NM., Gezlan NA. Anatomical study of *dorsalis pedis* artery and its surgical importance in Reconstr.surg: Alexandria Journal of medicine 2008;44(2).557-571
24. Lee.J.H, Dauber W. Anatomical study of Dorsalis pedis artery and first dorsal metatarsal artery, AnnPlast.Surg; 1997;Jan38(1);50-5.
25. Ali MW, Mohajir AM. Dorsalis pedis artery: variations and clinical significance. J Indian Med Assoc. 1996; 94: 417–418.
26. Maydew M. Dorsalis pedis aneurysm: ultrasound diagnosis. Emergency Radiology. 13 (5): 277-280, 2007.
27. Unnikrishnan AG. Everyday Practice: Diabetes Mellitus Approach to a patient with a diabetic foot, The National Medical Journal of India, 21(3), 2008,134-137.
28. Mulfinger G.L, Pasadena and Trueta J. The blood supply of the talus, The Journal of Bone and Joint Surgery, 52 B (1), 1970, 160-167.

Conflict of Interest

The authors declares no conflict of interest