

Pneumomediastinum and pneumoperitoneum caused by tracheostomy displacement

Christopher M Kniese,¹ Muhammad Y Jan,¹ Khalil Diab²

¹Department of Medicine, Indiana University School of Medicine, Indianapolis, Indiana, USA

²Division of Pulmonary, Critical Care, Sleep, and Occupational Medicine, Indiana University School of Medicine, Indianapolis, Indiana, USA

Correspondence to

Dr Khalil Diab, kdiab@iu.edu

Accepted 16 June 2015

DESCRIPTION

A 20-year-old woman with a history of morbid obesity secondary to Prader-Willi syndrome and recent acute-on-chronic respiratory failure requiring tracheostomy placement presented to the emergency department of a regional hospital with respiratory distress and concern for tracheostomy obstruction. Her tracheostomy was exchanged, and mechanical ventilation was initiated prior to transfer to our hospital. She continued to experience respiratory distress; plain chest radiography demonstrated pneumomediastinum ([figure 1A](#)). Dedicated CT of the chest and abdomen demonstrated a left-sided pneumothorax, pneumomediastinum and pneumoperitoneum, which

appeared to track down from the thoracic cavity ([figure 1B–D](#)). At the time, the patient was in acute kidney failure and urine output was decreased. Bladder pressure was measured at 23 cm H₂O. Her constellation of findings was believed to be secondary to creation of a false tract during tracheostomy exchange.

Otolaryngology was consulted; a guided tracheostomy replacement with a 6.0 Shiley cuffed tracheostomy tube was performed. A left-sided 20 Fr thoracostomy tube was placed with lung re-expansion confirmed on repeat imaging ([figure 1E](#)). Bladder pressure decreased to 14 cm H₂O the next day, and urine output improved. The patient's chest tube was removed on day 7, and she required

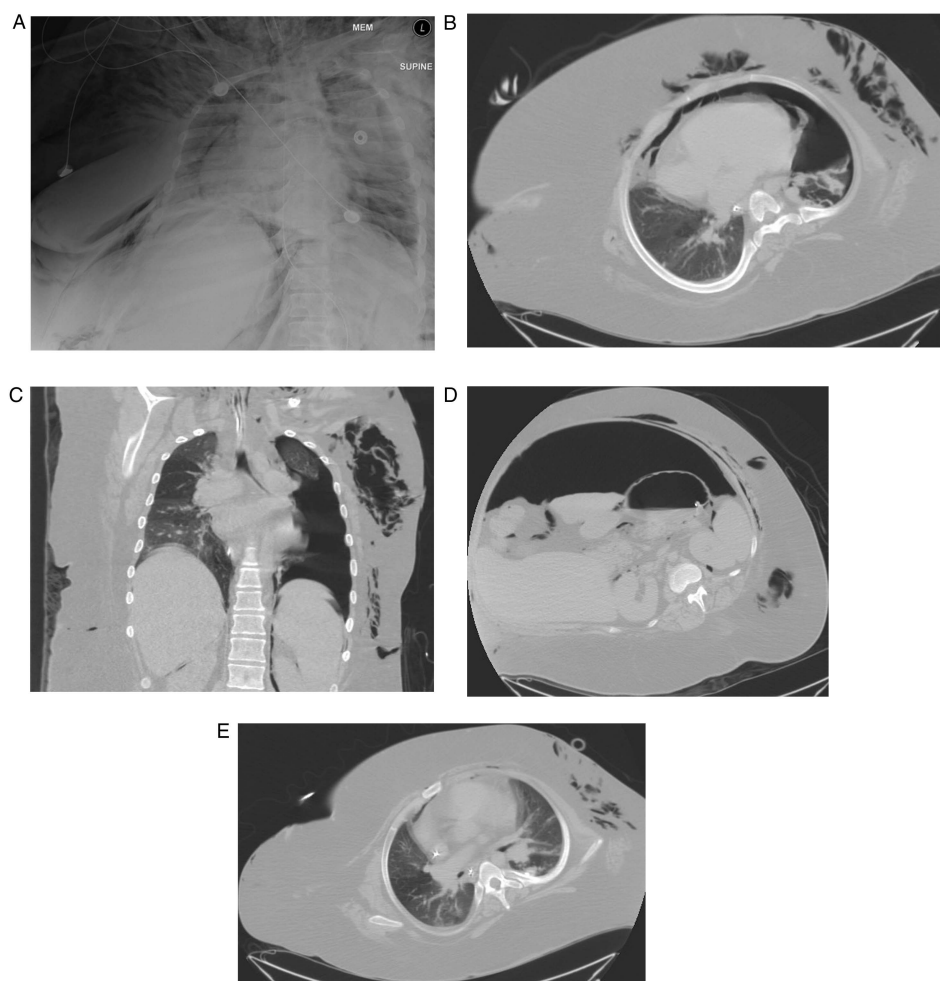


Figure 1 (A) Chest X-ray showing bilateral pneumomediastinum and left-sided apical pneumothorax; (B) transverse view of CT of the chest showing a large left-sided pneumothorax with pneumomediastinum; (C) coronal view of CT of the chest revealing the left-sided pneumothorax with air tracking down towards the mediastinum; (D) CT of the abdomen showing extensive pneumoperitoneum and (E) CT of the chest showing resolution of the left-sided pneumothorax after the chest tube was placed.



To cite: Kniese CM, Jan MY, Diab K. *BMJ Case Rep* Published online: [please include Day Month Year] doi:10.1136/bcr-2015-211238

mechanical ventilation for approximately 8 days before weaning to tracheostomy collar.

Surgical and percutaneous tracheostomy procedures are associated with a significant number of complications (up to 66% in some series); however, most of these complications are considered minor. Most common major complications include tracheal stenosis, haemorrhage, tracheocutaneous fistula, infection and tube decannulation/obstruction.¹ Morbid obesity is associated with a significant increase in the number of surgical as well as percutaneous tracheostomy complications with an OR of 4.4 compared with non-obese patients.²

Learning points

- ▶ Tracheostomy placement can be associated with major complications especially in obese patients, such as those with Prader-Willi syndrome.
- ▶ Pneumothorax and tension pneumoperitoneum can result from tracheostomy displacement and rare complications of tracheostomy placement.
- ▶ A defined tracheostomy care protocol for patients and their caregivers is of utmost importance to prevent and manage tracheostomy displacement.

Pneumomediastinum and tension pneumothorax are rare early and late complications. Pneumomediastinum leading to tension pneumoperitoneum and abdominal compartment syndrome, as in our case, has been very rarely reported. Measures to prevent and manage complications include a defined tracheostomy care protocol for patients and their caregivers, including education on reinsertion of a displaced tube. Instructions to seek immediate care if a displaced tube cannot be reinserted, or if it is displaced within 1–2 weeks of tracheostomy placement, should be provided to the families. In such situations, urgent guided replacement of the tube or endotracheal intubation is needed.³

Twitter Follow Khalil Diab at @khalildiab

Contributors KD provided the preliminary and final reviews for this article. MYJ wrote part of the initial version of this article. CMK wrote the final version of this article and updated it.

Competing interests None declared.

Patient consent Obtained.

Provenance and peer review Not commissioned; externally peer reviewed.

REFERENCES

- 1 Goldenberg D, Ari EG, Golz A, *et al.* Tracheostomy complications: a retrospective study of 1130 cases. *Otolaryngol Head Neck Surg* 2000;123:495–500.
- 2 El Solh AA, Jaafar W. A comparative study of the complications of surgical tracheostomy in morbidly obese critically ill patients. *Critical care* 2007;11:R3.
- 3 Mitchell RB, Hussey HM, Setzen G, *et al.* Clinical consensus statement: tracheostomy care. *Otolaryngol Head Neck Surg* 2013;148:6–20.

Copyright 2015 BMJ Publishing Group. All rights reserved. For permission to reuse any of this content visit

<http://group.bmj.com/group/rights-licensing/permissions>.

BMJ Case Report Fellows may re-use this article for personal use and teaching without any further permission.

Become a Fellow of BMJ Case Reports today and you can:

- ▶ Submit as many cases as you like
- ▶ Enjoy fast sympathetic peer review and rapid publication of accepted articles
- ▶ Access all the published articles
- ▶ Re-use any of the published material for personal use and teaching without further permission

For information on Institutional Fellowships contact consortiasales@bmjgroup.com

Visit casereports.bmj.com for more articles like this and to become a Fellow