

# **Ocular Graft-versus-Host Disease**

**By**

**Paul John Tomlins**

**MBChB, FRCOphth**

**A thesis submitted to**

**The University of Birmingham**

**For the degree of**

**DOCTOR OF MEDICINE**

**Academic Unit of Ophthalmology**

**Institute of Inflammation and Ageing**

**College of Medical and Dental Sciences**

**University of Birmingham**

**September 2017**

UNIVERSITY OF  
BIRMINGHAM

**University of Birmingham Research Archive**

**e-theses repository**

This unpublished thesis/dissertation is copyright of the author and/or third parties. The intellectual property rights of the author or third parties in respect of this work are as defined by The Copyright Designs and Patents Act 1988 or as modified by any successor legislation.

Any use made of information contained in this thesis/dissertation must be in accordance with that legislation and must be properly acknowledged. Further distribution or reproduction in any format is prohibited without the permission of the copyright holder.

## **Abstract**

Haemopoietic Stem Cell Transplant (HSCT) is used as a treatment for a number of conditions, particularly leukaemias. Following conditioning and HSCT, there is a 'resetting' of the immune system, which reconstitutes over a number of months. Graft-versus-Host Disease (GvHD) is a life-threatening complication of HSCT that can be associated with sight-threatening dry eye disease. In GvHD, transplanted immune cells mount an immune response against the host.

This thesis investigated how the immune cells of the conjunctiva reconstitute following HSCT. A non-invasive technique, ocular surface impression cytology (OSIC), was used to demonstrate that, whilst there was no apparent depletion of innate immune cells in the conjunctiva, there was a marked reduction in the lymphocytes, which gradually reconstitute, returning to normal levels at the 6 month time point.

Secondly OSIC was used to profile the conjunctival leukocyte population in a cohort of patients post-HSCT with and without eye disease and compared to the leukocyte conjunctival leukocytes in both healthy volunteers and patients with another form of aqueous deficient dry eye disease, primary Sjogren's Syndrome (pSS). In patients with dry eye disease following HSCT, the conjunctiva contained increased numbers of CD8+ lymphocytes, macrophages and neutrophils when compared to healthy volunteers and increased numbers of macrophages when compared to patients with pSS. These data demonstrate

that in dry eye disease post-HSCT, there is active inflammation, and this is distinct to the inflammation found in pSS supporting the hypothesis that there is a Graft-versus-Host reaction in the conjunctiva that is distinct to that caused by aqueous deficiency dry eye disease alone.

## **Acknowledgments**

I am indebted to my Supervisors. John Curnow and Saeeha Rauz, without whose help, advice and patience, this work would not have been possible.

I am grateful for the support of the Hale-Rudd Memorial Fund for their generosity and to Professor Murray to giving me the opportunity to get my feet wet in the lab.

I am grateful to all those who helped me in many different ways, Professor Simon Bowman; Professor Tony Bron; Lindsay Durant, for her help in keeping the Cyan Machine in check (and her macarons!); Peter Nightingale; Jane Nunnick, for relentlessly chasing up study participants, Marie Voice and Geraint Williams, for help with lab work and as a patient sounding board.

Finally, I am grateful to my wife Abigail whose devoted support can make anything possible, and to my children Charlotte and Hector who provided me with support, emotionally and otherwise.

# Table of Contents

<b>Chapter 1 Introduction</b>	<b>1</b>
Haemopoietic Stem Cell Transplant	1
<i>Reconstitution</i>	3
Graft-versus-Host Disease	6
<i>Mechanism of GvHD</i>	6
<i>Graft Versus Leukaemia Effect</i>	8
<i>Classification of GvHD</i>	8
<i>Classification of Ocular GvHD</i>	10
<i>Skin GvHD</i>	16
<i>Oral GvHD</i>	20
<i>Intestinal GvHD</i>	21
<i>Pulmonary cGvHD</i>	22
Ocular GvHD	23
<i>The Ocular Surface System</i>	23
<i>Immune microenvironment of the Conjunctiva</i>	26
<i>Epidemiology of Ocular GvHD</i>	33
<i>Pathogenesis of GvHD affecting the Ocular Surface and Lacrimal Apparatus</i>	37
Dry Eye Disease	42
<i>Definition of Dry Eye Disease</i>	42
<i>Classification</i>	42
<i>The Tear Film</i>	44
<i>Pathophysiology of Dry Eye Disease</i>	45
<b>Hypothesis and Aims</b>	<b>49</b>
Hypothesis	49
Aims	49
<b>Materials and Methods</b>	<b>50</b>
Clinical Studies	50

<i>Ethical Approval</i>	50
<i>Clinical Examination</i>	50
<i>OSIC Sampling Method</i>	56
Ex vivo experimentation	58
<i>Conjunctival Cell Recovery</i>	58
<i>Lysed Blood Preparation</i>	58
<i>Antibody Staining</i>	59
<i>Flow Cytometry</i>	60
<i>Fluorescence Compensation</i>	61
<i>Gating Strategy</i>	61
Statistical Analysis	68
<i>Longitudinal Cohort</i>	68
<i>Cross-Sectional Cohort</i>	68
<b>Chapter 3 Longitudinal Cohort</b>	<b>69</b>
Patient Recruitment	69
Results	70
<i>Characteristics of Participants</i>	70
<i>Clinical Features</i>	71
<i>Clinical Signs of dry eye</i>	71
<i>Resident Conjunctival Leukocyte Population</i>	73
<i>Reconstitution of Myeloid Derived Cells in the Blood and Conjunctiva</i>	74
<i>Reconstitution of Lymphocytes in the Blood and Conjunctiva</i>	76
Discussion	81
<b>Chapter 4 Cross-Sectional Cohort</b>	<b>86</b>
Patient Recruitment	86
Results	86
<i>Ocular GvHD and Dry Eye Disease</i>	88
<i>Cicatricial Lid Features</i>	91
<i>Conjunctival Leukocyte Populations and Ocular GvHD</i>	92
<i>Post-HSCT new onset KCS and comparison with healthy volunteers and patients with Sjögren's Syndrome</i>	95

<i>Lysed Blood Leukocyte populations and Ocular GvHD</i>	97
<i>Source of Donor Cells, ocular GvHD and Conjunctival Leukocyte Populations</i>	97
<i>Systemic GvHD and Conjunctival Leukocyte Populations</i>	97
Conclusions	101
<i>Scoring Scales and Diagnostic Criteria</i>	101
<i>Cicatrisation and Ocular Surface Fibrosis following HSCT</i>	104
<i>Changes in the ocular surface leukocyte populations in patients with KCS post-HSCT.</i>	104
<b>Chapter 5 Summary of Thesis and Conclusions</b>	<b>111</b>
Clinical Grading of Ocular GVHD	111
Conjunctival Immune Populations Post-HSCT	112
Ocular GVHD Pathophysiology	114
Suggestions for Future Work	116
Clinical Applications/Translation	118
<b>Appendices</b>	<b>119</b>
Appendix 1 Use of lissamine green before conjunctival impression cytology and flow cytometry in patients with Sjögren’s syndrome	119
Appendix 2 Assessment of the EyePRIM Device for Conjunctival Impression for Flow Cytometry	121
Appendix 3 Supplementary Data	123
<b>References</b>	<b>124</b>



## List of Figures

Figure 1 From Bosch et al <sup>21</sup> , depicting the different rates of reconstitution of different blood cellular components following myeloablation and transplant. Innate cells reconstitute early on, reaching normal levels within week or months, whereas lymphocytes take longer, reaching normal level months or years following HSCT. ....	4
Figure 2 Grading scale for conjunctival injection from the International Ocular GVHD Consensus Group Proposed Diagnostic Criteria of Chronic GVHD from Ogawa et al <sup>6</sup> . ....	14
Figure 3 Corneal Fluorescein Staining Grading System from the International ocular GVHD Consensus Group Proposed Diagnostic Criteria of Chronic GVHD from Ogawa et al <sup>6</sup> . ....	14
Figure 4 The Ocular Surface System taken from Gipson. <sup>7</sup> a sagittal section illustrating the continuous epithelial surface of the cornea and conjunctiva (pink) with associated glandular structures. b Frontal view of the ocular surface system, note the systemic involvement of the nervous, vascular, immunological and endocrine systems required to maintain a healthy ocular surface. ....	23

Figure 5 The Lacrimal Functional Unit taken from Bauerman et al. The Lacrimal Functional Unit in <i>Dry Eye and Ocular Surface Disorders</i> (Marchel Dekker, Inc., New York, 2004) p11-39 .....	24
Figure 6 The lower eyelid margin, stained with fluorescein, lissamine green and rose bengal to demonstrate Marx Line from Yamaguchi et al. <sup>9</sup> MO – Meibomian orifices, MI Marx line.....	33
Figure 7 Bullous Separation of conjunctival epithelium with migration of lymphocytes into basal layer from Jabs et al. <sup>8</sup> .....	37
Figure 8 Immunohistochemistry of lacrimal gland from patient with ocGVHD demonstrating periductal infiltrate of CD34+ fibroblasts, CD4+ and CD8+cells from Ogawa et al. <sup>3</sup> .....	39
Figure 9 Electron microscopy of human lacrimal gland in patient with ocular GVHD demonstrating lymphocyte and macrophages attached to fibroblasts in the perivascular area - Inset: Typical primitive contact (arrow). Ogawa et al 2001 <sup>4</sup> .....	40
Figure 10 Histological and Immunohistochemical slide from lacrimal gland of mouse model of ocular GVHD demonstrating lacrimal gland stasis (arrowhead) and a dense cellular infiltrate composed of CD11b, CD4 and CD8 cells Herretes et al. <sup>5</sup> .....	41

Figure 11 DEWS II Aetiological Classification of Dry Eye Disease from 2017 DEWS II report. Note how dry eye can manifest as a number of clinical entities, all requiring a tailored approach to treatment. ....	43
Figure 12 From Robinson et al <sup>1</sup> . Representative grading photos for conjunctival Inflammation associated with chronic GVHD. Arrows illustrate the subtle cicatricial changes associated with Grade 2. ....	53
Figure 13 Diagram to show how the ocular surface is subdivided in the modified Oxford Schema. The cornea is divided into 5 sections, including the visual axis. The medial and lateral conjunctiva are each divided into 3 sections.	55
Figure 14 Mathematically random dot patterns used to describe the severity of ocular surface staining in each area of the ocular surface. Each panel contains a randomly generated dot pattern with increasing density.....	55
Figure 15 Ocular Surface Impression Cytology with Supor 200 filter .....	56
Figure 16 Ocular Surface Impression Cytology with the EyePRIM device .....	57
Figure 17 Gating strategy to identify lymphocytes. A Counting beads are counted and cells identified excluding debris. B Sytox and CD45 (panleukocyte marker) used to find living leukocytes. C CD45 <sup>high</sup> (CD3 <sup>+</sup> lymphocytes) and CD45 <sup>dim</sup> (CD14 <sup>+</sup> cells) on the same fluorochrome are defined. D This is then backgated onto FS and SS to ensure only lymphocyte shaped cells are included. E CD4 and CD8 lymphocytes are subdivided. F CD56 is used to describe NKT cells. ....	63

Figure 18 Gating Strategy for NK Cells and Neutrophils in a lysed blood sample.

A Counting beads are counted and cells identified excluding debris. B Sytox and CD45 (panleukocyte marker) used to find living leukocytes. C NK cells are defined as CD56+ D Neutrophils are those cells that are both CD16+ and CD11+ ..... 65

Figure 19 Gating Strategy for Monocytes in Lysed Blood A Counting beads are

counted and cells identified excluding debris. B Sytox and CD45 (panleukocyte marker) used to find living leukocytes. C Since CD3 (lymphocytes) and CD14 (monocytes) were on the same marker, CD45 was used to separate CD45dim cells and these were then backgated D to ensure cells with a FS and SS profile typical of monocytes were included. .... 66

Figure 20 Gating strategy for NK cells, neutrophils and monocytes in a representative conjunctival sample. A shows FS and SS with R2 gating to include all cells,

excluding counting beads and debris. B Cells from gate R2 that did not stain with the dead cell exclusion dye and were CD45 (pan-leukocyte marker) positive (R3). C is gated off R3 and shows NK cells (CD56 +h CD3/CD14-) D is also gated off R3 to show neutrophils (CD16+/CD11+) high and CD11b high and are defined as neutrophils. E Shows a subset of CD3/CD14 high cells that are F back gated onto the FS and SS to define monocytes. .... 67

Figure 21 Representative Flow Cytometry Data from the conjunctiva of a

healthy volunteer after gating as previously described. A shows Neutrophils

CD16+/CD11b+). B shows CD8+ and CD4+ lymphocytes. C shows macrophages (CD45+ and CD14+) cells, note this is subsequently backgated onto FS and SS to exclude lymphocytes (CD3+) cells which shared the same fluorochromes as CD14..... 73

Figure 22 Reconstitution of Myeloid Derived Cells in lysed blood and conjunctiva showing the median and interquartile range of cell numbers. A. Monocytes B. Neutrophils, and C NK cells. Note significant fall in the number of Monocytes and NK cells and a trend to reduced neutrophils whilst there is no significant change in the numbers of any cell type in the conjunctiva..... 75

Figure 23 Representative Flow cytometry plot of a single patient. A Peripheral blood. Demonstrating high levels of CD4 and CD8 cells at baseline, with a marked reduction in cell numbers at one month post-transplant, with cell numbers returning to normal at 6 month post-transplant. This picture is mirrored in the conjunctiva in B with almost complete depletion of CD4 and CD8 lymphocytes in the conjunctiva at 3 months post-transplant, and cell numbers returning to normal at 6 months post-transplant..... 76

Figure 24 Reconstitution of Lymphoid Cells in lysed blood and conjunctiva showing the median and interquartile range of cell numbers. A. CD4+ Lymphocytes B. CD8+ lymphocytes, and C NKT cells. Note that there is a fall in the number of lymphocytes in the blood, but in contrast to the myeloid

derived cells, there is a corresponding fall in the number of CD4+, CD8+ and NKT Lymphocytes..... 78

Figure 25 Comparison of the median and range of the ratio of blood CD4 and CD8 lymphocytes that express CD45RO in patients pre-HSCT and healthy volunteers. Note there are significantly more CD45RO+/CD4+ cells in the blood of patients before HSCT and healthy volunteers..... 79

Figure 26 Median and range of the ratio of CD45RO+ and - lymphocytes in the conjunctiva A CD4+ cell and B CD8+ cells for healthy volunteers (blue) and post-HSCT patients (red) shown changing over time post-transplant. .... 80

Figure 27 Proportions of patients post-HSCT showing evidence of ocular GVHD/dry eye disease with each clinical test or scoring criteria..... 90

Figure 28 Scatter plot of time post-HSCT in days and Yamaguchi scale (averaged right and left eye) ..... 92

Figure 29 Conjunctival CD4+, CD8+, Macrophages, and Neutrophils in all patients post-HSCT, post-HSCT patients with new onset KCS, post-HSCT patients without new onset KCS, healthy volunteers and Sjögren's patients. Note significantly increased CD8+, macrophages, and neutrophils in post-HSCT patients with new onset KCS, compared to those without; and increased numbers of macrophages in patients with post-HSCT new onset KCS when compared to patients with Sjögren's syndrome..... 94

Figure 30 Conjunctival NK T-Cells and NK cells in all patients post-HSCT, post-HSCT patients with new onset KCS, post-HSCT patients without new onset KCS, healthy volunteers and Sjögren's patients. .... 95

Figure 31 Conjunctival Leukocytes populations in Healthy Volunteers, and post-HSCT patients with and without systemic GVHD (excluding ocular GVHD).  
Note there is no significant difference in the number of any of the populations examined in patients with systemic GVHD and without systemic GVHD..... 100

Figure 32 Graph to show the numbers of patients with and without KCS and evidence of GVHD in any other organ. There was no significant difference between the numbers of patients with KCS in patients with or without systemic GvHD. .... 101

## List of Tables

Table 1 NIH Classification of chronic GvHD from Filipovich et al. <sup>2</sup> The severity of GvHD depends on both the number of organs involved, and the severity of organ involvement.....	9
Table 2 NIH classification of ocular GvHD from Filipovitch et al. <sup>2</sup> . The severity of ocular disease is classified according to both symptoms and signs of ocular disease. Symptoms are described according to how the patient's activities of daily life (ADL) are affected and how often the patient needs to use treatment for their eye disease. Signs used are unspecified 'signs of keratoconjunctivitis sicca' or vision. ....	11
Table 3 International Consensus ocular GvHD proposed diagnostic criteria, numerical scoring system for each clinical component from Ogawa et al <sup>6</sup> . Severity score/points from the first are ascribed for each of the four clinical indices assessed and these four scores added together to create a composite score that is then applied to Table 4.....	15
Table 4 International Consensus proposed diagnostic criteria for ocular GvHD from Ogawa et al <sup>6</sup> . The composite score from Table 3 is used in this table to derive the diagnosis. If the patient has evidence of systemic GvHD, i.e. GvHD in another organ, then the composite score from ocular examination required to make a diagnosis of ocular GvHD is reduce, i.e. the threshold	



for making a diagnosis of ocular GvHD is less in patients with systemic GvHD. ....	16
Table 5 International Bone Marrow Transplant Acute Cutaneous GvHD Grading Scheme from Filipovich et al <sup>2</sup> . The severity of acute cutaneous GVHD is dependent on the Body Surface Area (BSA) affected, with the most severe disease characterised by bullous or necrotic skin disease.....	17
Table 6 NIH Consensus Grading Scheme for Cutaneous GvHD from Filipovich et al <sup>2</sup> . Chronic cutaneous GVHD is can manifest in a number of different clinical entities. Those are described and the severity determines by the Body Surface Areas (BSA) involved, with sclerotic skin disease classified as more severe. ....	19
Table 7 The different Ocular Manifestations of Acute and Chronic GvHD. Whilst ocular surface is the most common, less common manifestations have also been described in the literature.....	36
Table 8 Modified Bron Schema for the Scoring of Meibomian Gland Changes	52
Table 9 Antibody-fluorochrome combinations used for immunostaining of lysed blood and conjunctival impression samples.....	60
Table 10 Dry Eye Characteristics of the longitudinal cohort.....	72
Table 11 Cross-sectional cohort patient demographics, conditioning, and HSCT details.....	87

Table 12 NIH Ocular GvHD Severity Score and Dry Eye Symptom Score (OSDI) in Cross-Sectional Cohort of post-HSCT patients. These two scores describe the symptoms of patients with dry eye related disease. ....	88
Table 13 Clinical signs of Ocular GvHD and Dry Eye Disease in Cross-Sectional Cohort of post-HSCT patients. ....	89
Table 14 International Consensus Group, proposed diagnostic criteria for ocular GvHD. ....	91
Table 15 Median cell numbers and interquartile range for each conjunctival leukocyte population in all post-HSCT patients, post-HSCT patients with and without new onset KCS, healthy volunteers and patients with Sjögren’s syndrome. ....	93
Table 16 Comparison of conjunctival leukocyte populations in patients post-HSCT with healthy volunteers and Sjogren's Syndrome patients. Shaded cells demonstrate where the difference between the post-HSCT group and the control groups are significantly higher, or where there is a trend to higher numbers in the post-HSCT group.....	96
Table 17 The severity of GvHD in the Cross-Sectional Cohort of patients using the NIH Classification of GvHD severity. The majority of patients had either mild or moderate GvHD. ....	98

Table 18 Further description of the NIH severity score for patients in the cross-sectional cohort (total n=29), describing the NIH GvHD severity score (0-3) for each affected system..... 98

Table 19 Median cell numbers and interquartile range for each leukocyte population in lysed blood in all post-HSCT patients, post-HSCT patients with and without new onset KCS, healthy volunteers and patients with Sjögren's syndrome. .... 123

## List of Abbreviations

Abbreviation	
<b>Ab</b>	Antibody
<b>ADDE</b>	Aqueous Deficient Dry Eye Disease
<b>ADL</b>	Activities of Daily Living
<b>aGVHD</b>	Acute Graft-versus-Host Disease
<b>BSA</b>	Body Surface Area
<b>CALT</b>	Conjunctiva-associated lymphoid tissue
<b>CFS</b>	Conjunctival Fluorescein Staining
<b>cGVHD</b>	Chronic Graft-versus-Host Disease
<b>clGvHD</b>	Cutaneous Lichenoid GvHD
<b>csGvHD</b>	Cutaneous Sclerotic GvHD

<b>DAF</b>	Decay accelerating factor (aka CD55)
<b>DC</b>	Dendritic Cell
<b>DEWS</b>	Dry Eye Workshop
<b>DEWS</b>	Dry Eye Workshop
<b>DEWS II</b>	Dry Eye Workshop II
<b>DLI</b>	Donor Lymphocyte Infusion
<b>EDE</b>	Evaporative Dry Eye Disease
<b>EMBT</b>	European Group for Blood and Marrow Transplantation
<b>FS</b>	Forward Scatter
<b>GvHD</b>	Graft-versus-Host Disease
<b>GVL</b>	Graft-versus-Leukaemia
<b>HSC</b>	Haemopoietic Stem Cells

<b>HSC</b>	Haemopoietic Stem Cell
<b>HSCT</b>	Haemopoietic Stem Cell Transplant
<b>IBMTR</b>	International Bone Marrow Transplant Registry
<b>IEL</b>	Intraepithelial Lymphocytes
<b>IL-1RA</b>	interleukin -1 receptor antagonist
<b>KCS</b>	Keratoconjunctivitis Sicca
<b>MDSC</b>	Myeloid Derived Suppressor Cells
<b>MIRL</b>	Membrane inhibitor of reactive lysis (aka CD59)
<b>NIH</b>	National Institute for Health
<b>NK</b>	Natural Killer (cell)
<b>OSDI</b>	Ocular Surface Disease Index
<b>OSIC</b>	Ocular Surface Impression Cytology

<b>pSS</b>	Primary Sjögren's Syndrome
<b>SS</b>	Side Scatter
<b>TBI</b>	Total Body Irradiation
<b>TBUT</b>	Tear Break Up Time
<b>T<sub>CM</sub></b>	Central Memory T-cells
<b>T<sub>EM</sub></b>	Effector Memory T-cells
<b>T<sub>EMRA</sub></b>	Revertant Effector Memory T-cells
<b>TGF-β</b>	Transforming growth factor beta
<b>TIMP-1</b>	Tissue Inhibitor of Metalloproteinase - 1

# Chapter 1 Introduction

## Haemopoietic Stem Cell Transplant

Ernst Neumann first described the haemopoietic stem cell (HSC) at the turn of the last century.<sup>10</sup> HSCs are multipotent, self-renewing cells that replicate to form the variety of cells found in the blood, including erythrocytes, leukocytes and platelets. HSCs are predominantly found in the bone marrow, most notably in the long bones and the pelvis, where they form 0.01% of the total cell mass; a very small number of HSCs can also be found in the peripheral blood.

In the early part of the 20<sup>th</sup> Century, leukaemia was essentially an untreatable disease. The advent of chemotherapy agents in the post-war period, in particular antimetabolites, offered the first opportunity to treat leukaemia<sup>11</sup> but such treatment was limited both by the toxicity of the agents used and the potential for drug resistant disease.

In 1957 Thomas et al transplanted bone marrow intravenously<sup>12</sup>, although this graft failed to permanently engraft, transient engraftment occurred in one patient, proving the concept and in 1959 Thomas et al<sup>13</sup> successfully transplanted bone marrow between identical twins, but successful allogenic transplantation remained elusive. In 1958, six Yugoslavian physicists were exposed to a lethal dose of radiation following an accident at the *Vinca Nuclear Center* in Belgrade. Since HSC turnover rapidly, these cells are at a particularly high risk from radiation-induced damage and all six patients rapidly deteriorated



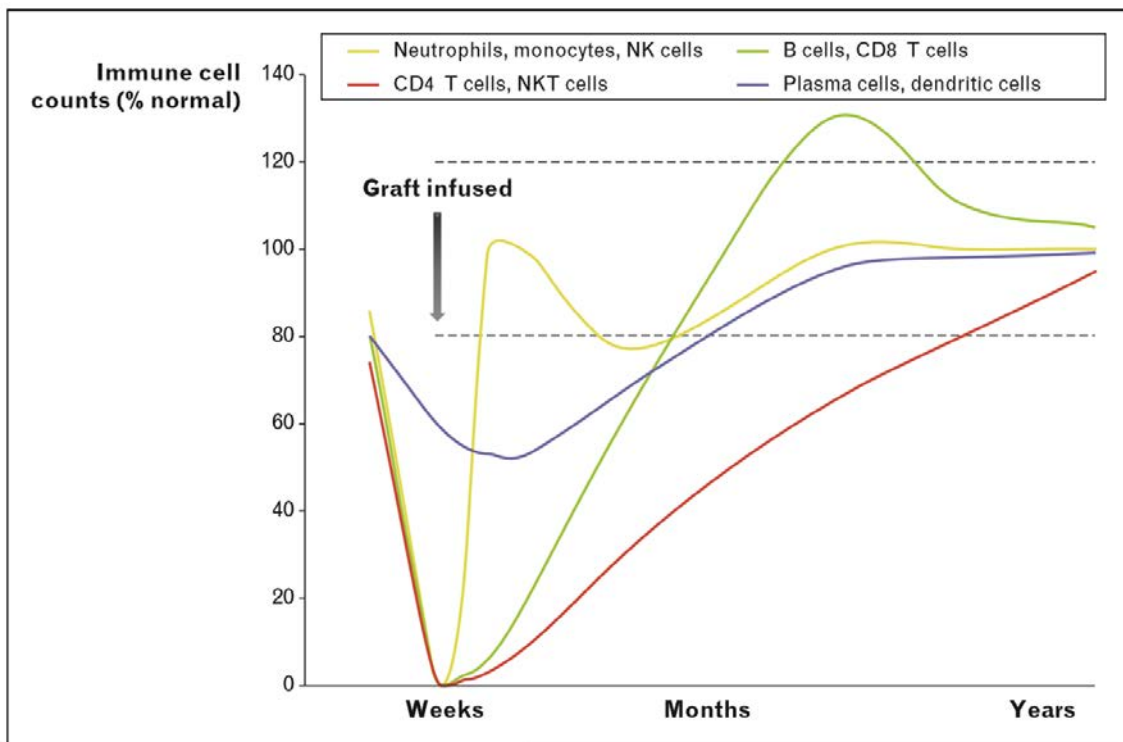
with one succumbing to the disease. The remaining 5 patients received bone marrow infusions, but engraftment failed in all cases. In 1958 Thomas et al<sup>14</sup> published successful homograft in dogs; unfortunately animals in whom engraftment successfully occurred later succumbed to a constellation of complications such failure to thrive, diarrhoea, hepatomegaly and splenomegaly. With the discovery in the 1960's of the structure and function of the MHC complex successful HSCT became a real possibility, and consequently, in 1968, the first successful HSCT was performed by Good et al.<sup>15</sup>

The European Group for Blood and Marrow Transplantation (EBMT) reported that in 2015, a record number of HSCT's were performed, 42,171 transplants were performed in 655 European centres, of which 21,596 were allogenic transplants<sup>16</sup>, an increase of almost 300% on 2005 numbers. The most common indications for HSCT are the leukaemias and lymphoproliferative disorders, however 1985 allogenic HSCTs were performed for benign disease, the most common benign indication being severe aplastic anaemia. More recently there has been increased interest in using myeloablation and autologous HSCT to treat autoimmune disease, including Systemic Lupus Erythromatosus, <sup>17</sup>, Multiple Sclerosis.<sup>18</sup> and systemic sclerosis.<sup>19</sup> When used to treat these diseases, the patient's bone marrow is terminally suppressed, so much so that the patient is unable to produce any blood cells; this myeloablation depletes the patient's autoreactive immunological compartment. The immune system is then 'reset' with autologous stem cell transplant; with

naïve lymphocytes produced from the bone marrow and thymic reactivation producing naïve T-cells and T-regulatory cells (T-reg).<sup>20</sup>

### **Reconstitution**

Following myeloablation, the bone marrow HSC population is depleted and so the bone marrow is unable to produce any blood cell components. Following HSCT, engraftment of transplanted haemopoietic stem cells allows the bone marrow to produce blood cells. In the first few days following transplant, the levels of all cellular components of blood plummet, requiring red cell transfusion and measures to prevent infections.<sup>21</sup> Leukocyte numbers subsequently rise reconstituting both leukocyte and erythrocyte populations. Reconstitution is a dynamic process with interplay between numerous factors, including surviving host leukocytes, donor leukocytes from the graft, new leukocytes originating from engrafted haemopoietic stem cells, treatment given as part of the transplant protocol, and the environment, including latent viruses. Different cell populations reconstitute at different time points; this is shown in Figure 1.



**Figure 1** From Bosch et al<sup>21</sup>, depicting the different rates of reconstitution of different blood cellular components following myeloablation and transplant. Innate cells reconstitute early on, reaching normal levels within week or months, whereas lymphocytes take longer, reaching normal level months or years following HSCT.

Innate immune cells derived from the transplanted marrow reconstitute in the early post-transplant period, with levels in the blood reaching normal in the first few weeks after HSCT. Neutrophils reconstitute first, with normal levels as soon as 11-14 days after transplant.<sup>22</sup> Monocytes and NK cells reconstitute to normal levels by day 30.<sup>23</sup> In contrast dendritic cell number fall in less than 24 hours following myeloablation and their numbers recover much more slowly, with levels approaching normal levels up to one year following HSCT.<sup>24</sup> Interestingly, in the skin, dendritic cell levels have been shown to return to a normal level by day 112.<sup>25</sup>

Lymphocytes, in general, take longer to reconstitute and the process of reconstitution is different for different subsets of lymphocytes. B-cell reconstitution follows a path remarkable similar to the natural maturation and evolution of B-cells. B-cells levels drop rapidly following myeloablation<sup>26</sup> with levels taking over a year to reach normal. Reconstituted B-cells are mainly of donor origin<sup>27</sup>, and naïve B-cells are found in the blood first, with memory B-cells appearing later. <sup>23</sup>, Despite host B-cells being barely detectable in the blood<sup>27</sup> following myeloablation, B-cells in the lymph nodes prove themselves to be highly resistant as host immunoglobulins are detectable in the serum up to two years following HSCT. <sup>28</sup> In stark contrast, T-cell reconstitution follows a distinctly different path to their normal maturation. T-cell reconstitution follows a biphasic pattern. In addition to haemopoietic cells, HSCT also transplants mature T -cells and through peripheral expansion, effector memory T-cells predominate in the early stages of reconstitution forming the first wave of T-cells. <sup>29</sup> In response to low lymphocyte numbers, naïve T-cells mature in the thymus, forming the second wave of T-cell expansion.<sup>30</sup> .This process is slow, and naïve T-cells can take decades to reach normal levels<sup>31</sup>, in part due to poor thymic function impairing T-cell maturation, especially in the elderly. <sup>32</sup> CD8+ cells reconstitute significantly earlier than CD4+ cells<sup>31</sup> and as a result the CD4:CD8 ratio changes switching in favour of CD8+cells.<sup>33</sup> This is thought to be due to herpetic viruses driving effector memory expansion with VZV<sup>34,35</sup> and CMV <sup>36-38</sup> implicated. Nevertheless, reconstitution of CD4+ cells confers increased survival and disease-free remission. <sup>39</sup> On reconstitution the balance

of regulatory to effector T-cells is skewed towards effector cells, which is clinically relevant as higher levels of effector T-cells and lower levels of T-reg cells confer an increased risk of GvHD.<sup>40</sup> Host derived T-regs have been shown to be reconstitute early on, reaching normal levels as early as 4 weeks in animal models.<sup>41</sup>

### ***Tissue Reconstitution***

Due to the difficulty in obtaining tissue samples, less is known about reconstitution of tissue resident leukocytes in humans. It has been shown that infused donor lymphocytes can enter tissues at an incredibly rapid rate, up to 10 billion cells in half an hour.<sup>27</sup> In the intestine, there are clinical implications of leukocyte trafficking to the gut; early neutrophil translocation is implicated in the initiation of acute GvHD<sup>42</sup> and blockade of T-cell entry into the intestine may help to prevent acute GvHD.<sup>43</sup>

## **Graft-versus-Host Disease**

### **Mechanism of GvHD**

Early animal models of stem cell transplantation were limited by a constellation of disease consisting of diarrhoea, dermatitis, splenomegaly and wasting, the syndrome becoming known as term 'secondary disease'<sup>44</sup> or 'runt' disease.<sup>45</sup> It was noted that the animals that were most likely to succumb, were those in whom successful engraftment had taken place. It later became apparent that secondary disease was due to the transplantation of fully functional mature

lymphocytes attacking the host, and the phenomenon became known as Graft-versus-Host Disease (GvHD).

In the late 1950's, Billingham described three pre-requisites for GvHD to occur.<sup>46</sup>

1. [The transplant] "must contain mature immunologically competent cells"
2. "The host must possess important transplantation antigens" (histocompatibility genes) which are lacking in the graft
3. "The host must itself be incapable of reacting against the graft"

This logic explains why a corneal transplant is highly unlikely to cause GvHD, since although the majority of corneal transplants are not MHC matched, the transplant does not contain a significant number of immunocompetent cells, and the host's immune system is intact. Conversely HSCT is much more likely to cause GvHD, since the transplant contains not only the desired haemopoietic stem cells but mature immunocompetent cells; there are minor histocompatibility mismatches even in a fully MHC matched transplant and the host's own immune mechanisms have been compromised by the preceding disease treatment or conditioning.

Early use of therapy targeted against T-cells in dogs<sup>47</sup> highlighted the role of T cells in the pathogenesis of GvHD. T-cell suppression with methotrexate and calcineurin inhibitors became regularly used to reduce the risk of GvHD and it was also shown that removing or depleting the 'immunocompetent' T-cells from the donor infusion was effective at reducing the formation of GvHD.<sup>48</sup> The risk

of developing chronic GvHD is also significantly increased, if there has been previous acute GvHD.<sup>49-55</sup>

### **Graft Versus Leukaemia Effect**

It also became apparent that the presence of GvHD, whilst causing significant morbidity to patients, was reducing the risk of leukaemia relapse. GvHD conferred a reduction in leukaemia relapse rate, <sup>56</sup> and overall survival<sup>57</sup>; and strategies to reduce GvHD increased the risk of relapse<sup>58</sup>. The use of Donor Lymphocyte Infusions (DLI) to induce disease remission<sup>59</sup> provided further evidence of the 'anti-leukaemic' effect of lymphocyte infusion, now known as the Graft-versus-Leukaemia effect (GVL).

### **Classification of GvHD**

Classically GvHD has been classified by time point, with manifestations occurring before 100 days being classified as acute Graft-versus-Host Disease (aGvHD), and those after 100 days as chronic Graft-versus-Host Disease (cGvHD). Modern therapeutic regimes and treatment have somewhat blurred this margin, in particular the use of reduced intensity conditioning, 'top up' HSCT/DLI and modern immunosuppression. It is entirely possible with reduced intensity conditioning for aGvHD to present 'late' or for both acute and chronic GvHD manifestations to occur simultaneously following DLI or withdrawal of systemic immunosuppression. A consensus document was therefore published by the National Institute for Health in 2005<sup>2</sup> which recommended that GvHD should not only be classified as acute or chronic based on the timing of the

clinical features, but also on the clinical pattern of disease. Furthermore, a detailed scoring system for cGvHD was proposed which splits the clinical features of cGvHD into organ systems and then assigns a score (from 0-3) according to the severity of involvement. A score of 0 denotes no involvement, 1 denotes no clinical significant functional impairment, 2 denotes clinically significant impairment and 3 denotes major disability. Depending on which organs are affected, the number of organs affected, and how severely they are affected; the severity of cGvHD is then classified as 'Mild', 'Moderate' or 'Severe'. This classification is summarised in Table 1

<b>Mild GvHD</b>	<ul style="list-style-type: none"> <li>• 1 or 2 organs involved</li> <li>• No Lung Involvement</li> <li>• Maximum severity score of 1 in any site</li> </ul>
<b>Moderate GvHD</b>	<ul style="list-style-type: none"> <li>• At least 1 with severity score of 2 but not &gt;2</li> <li style="text-align: center;">-Or-</li> <li>• 3 or more sites with severity score of 1</li> <li style="text-align: center;">-Or-</li> <li>• Lung score of 1</li> </ul>
<b>Severe GvHD</b>	<ul style="list-style-type: none"> <li>• Severity score of 3 in any organ site</li> <li style="text-align: center;">-Or-</li> <li>• Lung score of 2 or more</li> </ul>

**Table 1 NIH Classification of chronic GvHD from Filipovich et al.<sup>2</sup> The severity of GvHD depends on both the number of organs involved, and the severity of organ involvement.**

In 2015, after this study had finished, these criteria were modified and updated.

<sup>60</sup> The general principle and structure is unchanged, but there are minor



alterations and clarifications to the system. As this was published after our study finished, the 2005 NIH classification are used throughout.

### **Classification of Ocular GvHD**

#### ***NIH***

The NIH classification of GvHD describes the severity of each system that can be involved in cGvHD, including the eyes. Ocular disease is graded as mild, moderate or severe (Table 2).

The 2005 NIH classification uses unanaesthetised Schirmer's test. Schirmer's test described in the DEWS report<sup>61</sup> and is a basic measure of tear production: a strip of filter paper is inserted into the lower eyelid for five minutes. The length of the strip that is wet by the tears is then measured. The less the length that is wet, the fewer tears and the drier the eye. The NIH classification defines new onset ocular keratoconjunctivitis sicca (KCS) documented by a low unanaesthetised Schirmer test values with a mean value of both eyes <5 mm at 5 minutes; or mean values of 6 to 10 mm accompanied by evidence of dry eye disease on slit-lamp examination. Using the NIH classification new onset KCS and symptoms of cGvHD in one other system is enough to diagnose cGvHD.

<b>Mild Ocular GvHD (Score 1)</b>	Mild dry eye symptoms not affecting ADL (requiring eyedrops <3xperday)  <p style="text-align: center;"><b>OR</b></p> asymptomatic signs of keratoconjunctivitis sicca
Moderate Ocular GvHD (Score 2)	Moderate dry eye symptoms partially affecting ADL (requiring drops>3xperday or punctal plugs), <b>WITHOUT</b> vision impairment
Severe Ocular GvHD (Score 3)	Severe dry eye symptoms significantly affecting ADL (special eyewear to relieve pain)  <p style="text-align: center;"><b>OR</b></p> unable to work because of ocular symptoms  <p style="text-align: center;"><b>OR</b></p> loss of vision caused by keratoconjunctivitis sicca

**Table 2 NIH classification of ocular GvHD from Filipovitch et al<sup>2</sup>. The severity of ocular disease is classified according to both symptoms and signs of ocular disease. Symptoms are described according to how the patient’s activities of daily life (ADL) are affected and how often the patient needs to use treatment for their eye disease. Signs used are unspecified ‘signs of keratoconjunctivitis sicca’ or vision.**

This system is designed to be used both by ophthalmologists and non-ophthalmologists; and can be assessed by transplant specialists in the transplant clinic as well as in the ophthalmology clinic. As such, specialist investigations and examination techniques that are usually applied to dry eye disease, are not included in the classification. This has led to criticism of the

system as it is difficult to compare the NIH scale with other dry eye disease states, and there is a lack of granularity that might be required for more detailed purposes, such as research. Nevertheless, the classification has stood up well to scrutiny: a large multicentre study by Inamoto et al<sup>62</sup> compared the five candidate scales including NIH scale with patient and clinician reported changes in symptoms and found the NIH eye score showed fair correlation with both patient and clinician reported assessment. Furthermore, the NIH scale, which was not originally designed to measure serial changes, was found to be the most sensitive to patient reported symptom scales. Nevertheless, even given these findings, the authors recommend that for “clinical trials specifically targeting ocular symptoms, other detailed and objective ophthalmology criteria might be necessary to document ocular chronic GvHD activity”.

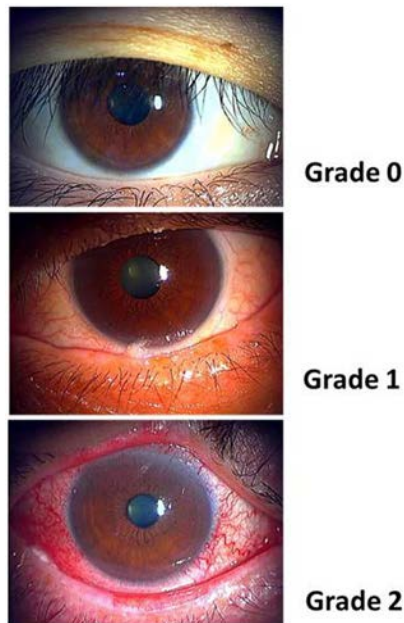
Tatematsu et al<sup>63</sup> compared the NIH score with two other scores, including the Japanese Dry Eye Score and the Dry Eye Workshop (DEWS) scale<sup>64</sup>, also finding a good correlation between the three scores, although they found a number of discrepancies, and express concern that patients with ocular GvHD as defined by the NIH criteria may have low DEWS and/or Japanese Dry Eye Scale score, leading the possibility of overtreatment and the potential complications this might entail. Furthermore, there are concerns about the use of Schirmer’s score in the NIH definition of new onset KCS. In the above study by Inamoto et al<sup>62</sup>, whilst there was a correlation between patient and clinician scores and the NIH classification, there was not a correlation with Schirmer’s. In a prospective study of 53 patients post-HSCT, found a false positive 19.4% and

a false negative of 36.4% when compared with a global assessment of dry eye disease using tear film break up time or a positive cotton thread test or ocular surface abnormality detected on slit lamp examination with fluorescein or rose bengal.

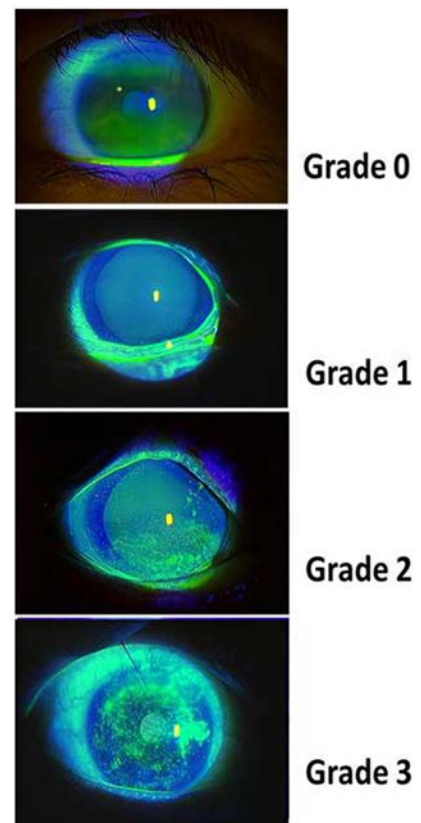
As mentioned above, in 2015 the NIH system was modified<sup>60</sup> and the ocular component was simplified, removing the Schirmer's criteria.

**International Chronic Ocular Graft-vs-Host-Disease (GvHD) Consensus Group:  
Proposed Diagnostic Criteria**

In light of these criticisms, an International Consensus group was formed and a new classification system was devised and published in 2013. <sup>6</sup> This system



**Figure 2 Grading scale for conjunctival injection from the International Ocular GVHD Consensus Group Proposed Diagnostic Criteria of Chronic GVHD from Ogawa et al<sup>6</sup>.**



**Figure 3 Corneal Fluorescein Staining Grading System from the International ocular GVHD Consensus Group Proposed Diagnostic Criteria of Chronic GVHD from Ogawa et al<sup>6</sup>.**

combines four main factors, unanaesthetised Schirmer's, corneal fluorescein staining (CFS), OSDI patient reported symptom scale and the presence and severity of conjunctival hyperaemia. Image based grading scales are provided for conjunctival injection (Figure 2) and CFS (Figure 3). Comparison with these

images allows the examiner to assign a severity score for both CFS and conjunctival inflammation. These scores are then combined with the Schirmer's score and OSDI (Table 3) to create a numerical composite score ranging from 0-11.

<b>Severity scores (points)</b>	Schirmer's test (mm)	CFS (points)	OSDI (points)	Conjunctival Inflammation (points)
<b>0</b>	> 15	0	<13	None
<b>1</b>	11-15	<2	13-22	Mild/Moderate
<b>2</b>	6-10	2-3	23-32	Severe
<b>3</b>	≤5	≥4	≥33	

**Table 3 International Consensus ocular GvHD proposed diagnostic criteria, numerical scoring system for each clinical component from Ogawa et al<sup>6</sup>. Severity score/points from the first are ascribed for each of the four clinical indices assessed and these four scores added together to create a composite score that is then applied to Table 4**

	<b>None (points)</b>	<b>Probable GvHD (points)</b>	<b>Definite GvHD (points)</b>
<b>Systemic GvHD (-)</b>	0-5	6-7	≥8
<b>Systemic GvHD (+)</b>	0-3	4-5	≥6

**Table 4 International Consensus proposed diagnostic criteria for ocular GvHD from Ogawa et al<sup>6</sup>. The composite score from Table 3 is used in this table to derive the diagnosis. If the patient has evidence of systemic GvHD, i.e. GvHD in another organ, then the composite score from ocular examination required to make a diagnosis of ocular GvHD is reduce, i.e. the threshold for making a diagnosis of ocular GvHD is less in patients with systemic GvHD.**

The patient's ocular disease is then categorised into 'None', 'Probable [ocular] GvHD' and 'Definite [ocular] GvHD' depending on the composite score and the presence or absence of systemic GvHD (Table 4). A study by Rapoport et al<sup>65</sup> retrospectively compared the consensus criteria with a composite 'best clinical practise' score on cross-sectional basis, and found that a slight agreement between the best clinical practise score and consensus criteria (kappa 0.187) with the correlation especially useful for patients with more severe disease, although they conclude that further validation through larger studies might be required.

### **Skin GvHD**

Dermatological manifestations of GvHD are common and present in with diverse clinical features. Cutaneous GvHD is the most common form of GvHD, affecting more than 80% of patients with acute GvHD<sup>66</sup>

## Acute Cutaneous GVHD

Cutaneous GvHD is usually the earliest clinical manifestation of GvHD, often presenting as an acute follicular reaction centred around the hair follicles<sup>67</sup>, which may mimic a bacterial or fungal infection. The subsequent clinical manifestations are defined using the International Bone Marrow Transplantation Registry (IBMTR) grading system<sup>68</sup> shown in Table 5.

<b>Grade</b>	<b>Clinical Manifestation</b>
Grade I	Maculopapular Rash <25% body surface area (BSA)
Grade II	Maculopapular Rash 25%-50% body surface area (BSA)
Grade III	Maculopapular Rash >50% body surface area (BSA)
Grade IV	Generalised erythroderma plus bullae +/- generalized epidermal necrosis

**Table 5 International Bone Marrow Transplant Acute Cutaneous GvHD Grading Scheme from Filipovich et al<sup>2</sup>. The severity of acute cutaneous GVHD is dependent on the Body Surface Area (BSA) affected, with the most severe disease characterised by bullous or necrotic skin disease.**

Histological features of acute cutaneous GvHD following T-Cell depleted HSCT were described by Fischer et al<sup>69</sup>. In the epidermis there is diffuse epidermal hyperplasia (acanthosis) and basal keratinocyte vacuolation. In the dermal layer, there is dermal lymphocyte exocytosis and satellitosis, accompanied by an infiltrate of neutrophils, plasma cells, macrophages<sup>70</sup> and eosinophils.



Bruggen et al<sup>71</sup> found an increased number of CD8+ lymphocytes in skin biopsies of patients with acute GvHD. Throughout both the dermis and epidermis there is keratinocyte necrosis.

Chronic cutaneous GvHD can take a number of varied clinical manifestations, but remains the most common form of cGvHD and is present in almost all patients with cGvHD. An NIH consensus document<sup>2</sup> stages cutaneous GvHD are shown in Table 6.

The histological features of chronic cutaneous GvHD are well described<sup>72,73</sup> with the earlier signs being vacuolar degeneration, characterised by apoptosis in the basal cell or lower spinosum layers of the epidermis. The histological features of cutaneous cGvHD depends on the clinical manifestations and is typically categorised into lichen-planus like (or lichenoid) and scleroderma, with sclerodermoid being further subdivided into lichen sclerosis, morpheaform and eosinophilic faciitis.<sup>74</sup>

Clinical Features	<ul style="list-style-type: none"> <li>○ Maculopapular Rash</li> <li>○ Lichen planus-like features</li> <li>○ Papulosquamous lesions or ichthyosis</li> <li>○ Hyperpigmentation</li> <li>○ Hypopigmentation</li> <li>○ Keratosis pilaris</li> <li>○ Erythema</li> <li>○ Erythroderma</li> <li>○ Poikiloderma</li> <li>○ Sclerotic features</li> <li>○ Pruritis</li> <li>○ Hair Involvement</li> <li>○ Nail Involvement</li> </ul>
Score 0	No symptoms
Score 1	<18% BSA with disease signs but <b>NO</b> sclerotic features
Score 2	29-50% BSA <b>OR</b> involvement with superficial sclerotic features “not hidebound” (able to pinch)
Score 3	>50% BSA <b>OR</b> deep sclerotic features “hidebound” (unable to pinch) <b>OR</b> impaired mobility, ulceration or severe pruritis

**Table 6 NIH Consensus Grading Scheme for Cutaneous GvHD from Filipovich et al<sup>2</sup>. Chronic cutaneous GVHD is can manifest in a number of different clinical entities. Those are described and the severity determines by the Body Surface Areas (BSA) involved, with sclerotic skin disease classified as more severe.**

Nevertheless, there are common histological features found in cutaneous cGvHD and they are similar to those found in cutaneous aGvHD. There is an interface dermatitis with basal keratinocyte vacuolation at tips of rete ridges and follicular epithelium. In the epidermis, there is mild intercellular oedema and exocytosis of individual mononuclear cells some juxtaposed to apoptotic

keratinocytes. Lymphocytic infiltrate is common and may congregate around an apoptotic keratinocyte, known as 'lymphocytic satellitosis'.<sup>73</sup> In chronic lichenoid cutaneous cGvHD, CD8+ lymphocytes producing IL-17 predominate, whereas in chronic sclerotic cGVHD, there is a mixture of CD4+ and CD8+ lymphocytes.<sup>71</sup>

Donor CD4+ T-cells are found in cutaneous lymphoid tissue as early as 2-3 days following transplantation.<sup>75,76</sup> The accompanying systemic cytokine release causes local chemokine release, including CXCL9, CXCL10, CXCL11.<sup>75</sup> Furthermore CXCL10 and its ligand CXCR3 are found in the serum of patients with acute skin GvHD.<sup>77</sup>

### **Oral GvHD**

Oral cGvHD is less common than the cutaneous disease, with clinically significant disease affecting up to 24% of patients following HSCT.<sup>78</sup> Oral GvHD may involve any site in the oral cavity, including the gingiva, hard palate, soft palate and tongue. Clinically oral GvHD has four different clinical manifestations, either as oral erythema; a lichen-planus like lesion with white lacy reticular lines possibly with hyperkeratosis/leukoplakia; a painful ulcerative lesion; or as a mucocoele occurring due to fibrous obstruction of minor salivary glands.

Histologically oral cGHVD shares a number of similarities with the cutaneous disease, a subepithelial cellular infiltrate and epithelial apoptosis and satellitosis. Imanguli et al<sup>79</sup> phenotyped these infiltrating cells as predominantly

CD3+/CD8+ T-Cells with fewer CD3+/CD8-(CD4) T-Cell, and CD68+ macrophage/dendritic cells. Keratinocytes and infiltrating cells in the oral mucosa demonstrated the CXCR3 ligand CXCL9 and other migration factors including IL-15 and type-1 IFN inducible factors. The infiltrated CD3+/CD8+ cells were of an effector/memory phenotype (CD45RO+). Infiltrating T-Cells exhibited cytotoxic features demonstrating GranzymeB and TIA1 on immunohistochemistry.

Involvement of the minor salivary glands in GvHD causes salivary hyposalivation and the sensation of a dry mouth (xerostomia). Xerostomia is found in 77% of cases and was almost always associated with dry eye disease.

<sup>80</sup> Histological findings in the salivary glands is characterised by a CD3+ lymphocytic infiltrate with preponderance of CD8+ over CD4+ cells in both parenchymal and periductal regions. As the disease progresses, there is progressive ductal fibrosis and acinar destruction.<sup>80</sup> These findings are similar to those in the lacrimal gland.

### **Intestinal GvHD**

The intestine is the most common organ to be affected in aGvHD. <sup>81</sup> Early symptoms such as nausea, vomiting, mild diarrhoea, mild abdominal pain, can often be confused with the complications of chemotherapy. At the more severe end of the spectrum, the diarrhoea becomes more voluminous, ileus may develop and the condition can become life threatening. In cGvHD, intestinal

involvement is much less common and often follows on from intestinal aGvHD.  
<sup>82</sup>Clinically intestinal cGvHD is characterized by diarrhoea and weight loss.

In the intestine, the inflammatory infiltrate accompanying cGvHD composes predominantly of mononuclear cells<sup>83</sup> and although not diagnostic, lymphocytosis and satellitosis are observed. In a mouse model, the CXCR3 ligand, CXCL10 have also been shown to be upregulated in the colon.<sup>84</sup> The microbiota of the intestine is heavily implicated in the development of intestinal GvHD,<sup>85</sup> indeed mice bred in germ-free conditions do not develop GvHD suggesting that pathogenesis is driven by dysregulated immune responses to commensal microorganisms.<sup>86</sup>

Damage to the intestinal stem cells during conditioning and radiotherapy<sup>87</sup> reduces the barrier function of the small intestine exposing of microbial products to the immune system. In response, neutrophil recruitment occurs<sup>88</sup> and dendritic cell maturation promotes T-cell recruitment.<sup>89</sup> Furthermore, dendritic cells induce infiltrating T-cells to differentiate to a TH17 phenotype.<sup>90</sup> In a mouse model of intestinal GvHD, Zhou *et al*<sup>91</sup> identified a population of central memory CD4+ T-cells that expression the  $\beta$ 2 integrin CD11c which expressed gut homing markers and were able to induce gastrointestinal inflammation on adoptive transfer.

### **Pulmonary cGvHD**

Clinically pulmonary cGvHD takes the form of Bronchiolitis Obliterans and can be diagnosed using lung function tests or radiologically.<sup>2</sup> In a mouse model of

pulmonary GvHD, Ohnuma *et al*<sup>92</sup> found a CD4+ infiltrate, and demonstrated that CD4+ T-cell production of IL-26 promoted lung fibrosis.

## Ocular GvHD

### The Ocular Surface System

The ocular surface system (Figure 4) consists of those structures that are required to create and maintain the smooth surface of the cornea. <sup>7</sup> It therefore composes of the surface epithelia of the cornea and conjunctiva, and the structures that support these epithelia, including the lacrimal glands, eyelids,

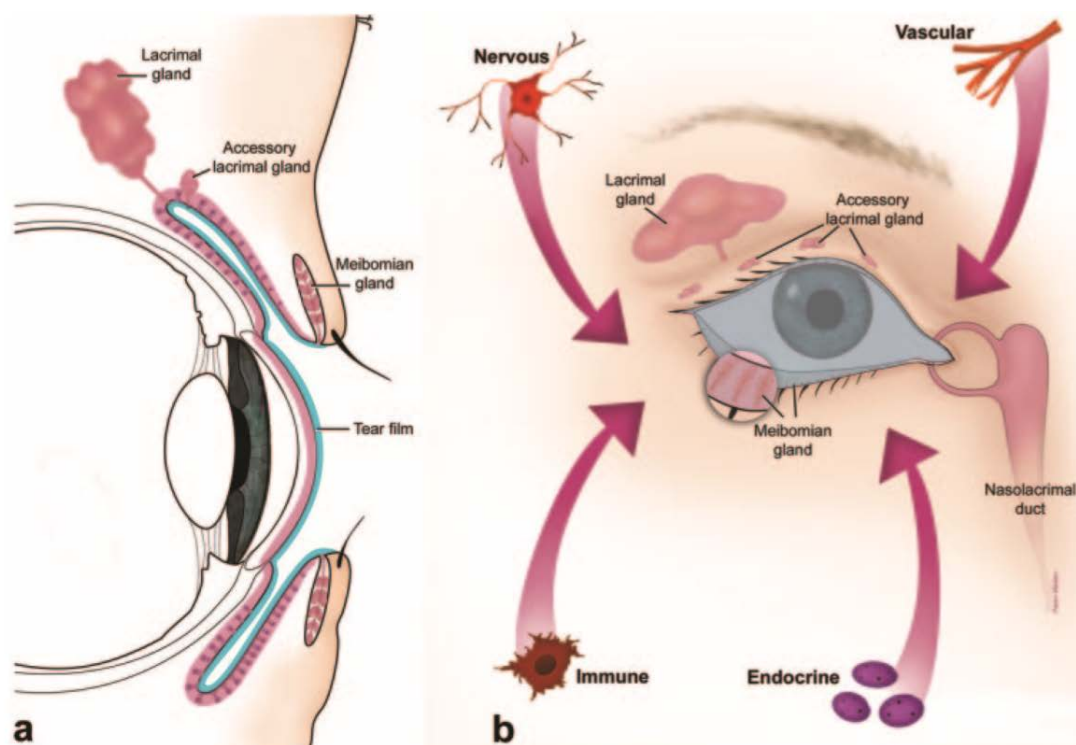


Figure 4 The Ocular Surface System taken from Gipson.<sup>7</sup>

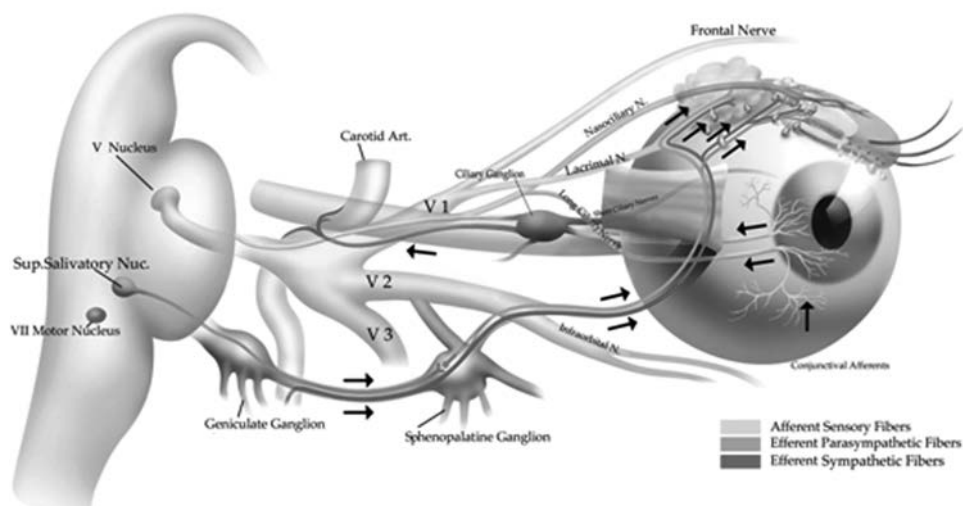
a sagittal section illustrating the continuous epithelial surface of the cornea and conjunctiva (pink) with associated glandular structures.

b Frontal view of the ocular surface system, note the systemic involvement of the nervous, vascular, immunological and endocrine systems required to maintain a healthy ocular surface.

eyelashes, Meibomian glands, and smaller glands, such as the accessory lacrimal glands, the glands of Moll and Zeiss and finally the nasolacrimal duct to drain away waste products of metabolism.

The cornea is a clear, avascular structure that composes the anterior portion of the eye, the main function of which is to allow light into the eye. The conjunctiva is a vascular tissue that covers the anterior portion of the eye, excluding the cornea, and also lines the inside or posterior aspect of the eyelids.

The tear film is a complex structure that covers the ocular surface. A functional and stable pre-ocular tear film is a prerequisite for clear vision since light entering the eye encounters the tear film first, before any other part of the eye. The structure of the tear film is complex, and any disturbance by a pathological process will have a detrimental effect on the quality of vision. The tear film is classically divided into three layers, a superficial lipid layer, a central aqueous



**Figure 5 The Lacrimal Functional Unit taken from Bauerman et al. The Lacrimal Functional Unit in *Dry Eye and Ocular Surface Disorders* (Marchel Dekker, Inc., New York, 2004) p11-39**

layer, and a mucous layer that coats the ocular surface epithelium. The ocular surface is part of the wider concept of the lacrimal functional unit (Figure 5), which consists of those tissues responsible for production and maintenance of the tear film.

## ***Cornea***

### ***Structure and Function of the Cornea***

The cornea is the clear window at the front of the eye. The primary function of the cornea is to provide a clear refractive surface for light entering the eye. In the mammalian eye, there are two refractive structures that together are responsible for focussing the light entering the eye in order to produce a clear image on the retina; namely the cornea and the crystalline lens. The total optical power of the eye is approximately 60 dioptres; the cornea is responsible for two-thirds of this. In order to maintain clarity, the central cornea is an avascular structure and hence the tear film is responsible for both providing nutrients and eliminating waste products. A healthy tear film is a prerequisite for the health of the corneal epithelium. The second function of the cornea is to act as a barrier between the external environment and the inside of the globe.



The cornea is conventionally described in 5 layers

1. The Corneal Epithelium
2. Bowman's Layer
3. Corneal stroma
4. Descemet's Layer
5. Corneal Endothelium

The corneal epithelium is a squamous non-keratinised epithelium approximately 5-7 cells and 53 microns thick.<sup>93</sup> It is maintained by a population of limbal stem cells which migrate centripetally replacing epithelial cells that are naturally shed off. The apical surface of the corneal epithelium consists of multiple microvilli, which interact with a glycocalyx that forms the mucous layer of the tear film. These microvilli are susceptible to disease, including ocular GvHD.<sup>94</sup>

### ***Conjunctiva***

#### **Immune microenvironment of the Conjunctiva**

As a mucosal surface, the conjunctiva is an interface between the body and the outside world, and as such, there is a constant risk of microbial infection. The keratinised epithelium of the epidermis provides significant protection from infection; the epithelium of the conjunctiva, however, is not keratinised and so is significantly more susceptible to infection. A number of mechanisms therefore have evolved, both to protect the ocular surface from infection and to prevent an over exuberant immune response.

### ***Conjunctival-associated Lymphoid Tissue***

The conjunctiva contains local lymphoid tissue, similar to Mucosal Associated Lymphoid tissue found in other organs, e.g. Peyer's patches in the intestine.

The conjunctiva-associated lymphoid tissue (CALT) allows local processing of antigens and recruitment and activation of lymphoid cells. Steven et al<sup>95</sup> demonstrated in the mouse, that topical stimulation of the conjunctiva produced lymphoid aggregates consisting of CD4+ and CD8+ T-cells; B-cells, dendritic cells and macrophages.

### ***Lymphocytes***

Lymphocytes form a major part of the adaptive immune system. As with all leukocytes, lymphocytes are produced in the bone marrow from haemopoietic stem cells. Lymphocytes then mature in either the Bone Marrow, B-cells or the Thymus gland, T-cells. T-lymphocytes can be classified according to their function; cytotoxic T-cells destroy tumour cells or host cells that are infected with intracellular pathogens and express the surface marker CD8; helper T-cells assist other immune cells, for example, encouraging cytotoxic T-cells to destroy pathogens, or activating B-cells to produce antibodies. Lymphocytes recognise a specific epitope, naïve lymphocytes have not yet encountered their specific antigen. Once a naïve lymphocyte encounters its antigen, it undergoes massive clonal expansion and differentiation to combat an associated pathogen, the lymphocyte is now termed an effector lymphocyte and this change can be recognised with a switch in surface markers; in humans, naïve T-cells express

the isoform CD45RA, whereas mature T-cells express the isoform CD45RO. Once the infection has been dealt with, a number of the lymphocytes that recognise this antigen remain both in circulation and resident in tissues, ready to respond should the epitope be encountered again. This immunological 'memory' is a defining characteristic of the adaptive immune system. As mentioned above, following T-cell depletion and conditioning, there is destruction of this memory component of the immune system; with HSCT allowing the immune system to be reconstituted.<sup>20</sup>

Memory T-cells are epitope specific T-cells that persist in the circulation, tissues and secondary lymphoid organs following resolution of infection. They are identified as CD45RO<sup>+</sup><sup>96</sup> and can be further subdivided by into CD45RO<sup>+</sup>CCR7<sup>+</sup> Central Memory T-cells (T<sub>cm</sub>) and CD45RO<sup>+</sup>CCR7<sup>-</sup> Effector Memory T-cells (T<sub>EM</sub>).<sup>97</sup> Memory T-cells were originally thought to be limited to only the Secondary Lymphoid Organs and the circulation, but have been demonstrated in the peripheral tissues where they are more likely to take on a cytotoxic/effector role.<sup>98</sup> Cytotoxic T<sub>EM</sub> cells have been demonstrated in the healthy human conjunctiva where they may play a role in the recognition of viral epitopes.<sup>99</sup> A fourth subset of 'revertant' T-cells 'revert' back and lose CD45RO, and express CD45RA. This subset is termed T<sub>EMRA</sub> cells, they show a low rate of cell turnover and exert a cytotoxic effect<sup>100</sup> and have been demonstrated on the ocular surface.<sup>101</sup>

Intraepithelial lymphocytes (IEL) are found in all mucosal sites, including the gastrointestinal tract<sup>102</sup>, the respiratory tract<sup>103</sup> and vaginal tract,<sup>104</sup> and play a role in the early response to pathogens. Intraepithelial cells can be subdivided into two main groups<sup>105</sup>, Type a are 'conventional' T-cells TCR  $\alpha\beta$ /CD8 $\alpha\beta$ +. Type b cells comprise of three subsets, TCR $\alpha\beta$ /CD8 $\alpha\alpha$ +, TCR $\gamma\delta$ /CD8 $\alpha\alpha$ + and TCR $\gamma\delta$ DN (Double Negative). Type a cells are activated by antigen presented on MHC I or II through the TCR by professional antigen presenting cells. In contrast Type b IELs respond to antigen presented through alternative routes. Their roles are also distinct, Type a cells shuttle from systemic circulation into their specific mucosal site, this homing requires the integrin  $\alpha\epsilon\beta7$ . Type b cells are implicated in autoimmune disease;  $\gamma\delta$  cells have been shown to have a role in preventing autoimmunity in a number of conditions, such as colitis<sup>106</sup>, rheumatoid arthritis<sup>107</sup> and Grave's disease<sup>108</sup>.

In the conjunctival epithelium, the dominant T-cells are a resident population of CD8+ $\alpha\beta$ + T cells, whose numbers increase with age<sup>109</sup>, express mucosal homing signals  $\alpha\epsilon\beta7$  and are cytotoxic.<sup>99</sup> These CD8+ T-cells are predominantly effector memory cells, although there are detectable numbers of naïve cells.

Bose *et al*<sup>101</sup> found in healthy human conjunctiva, that the majority of T-Cells, both CD8+ and CD4+ cells are resident T cells and split into two distinct groups, the largest expressing CD69+CD103+. In addition, there is a smaller population of CD4+ CD25+ FoxP3+ cells which can be demonstrated in the conjunctiva and, in response to viral infections, these cell have been shown to suppress effector T-cells<sup>110</sup> acting as T-reg.

In the skin, two circulating subsets and two resident subsets of resident memory cells, with the effector functions of resident cells higher than recirculating cells.<sup>111</sup>

### ***Macrophages in the Ocular Surface***

Macrophages are phagocytic granular cells that are found throughout the tissues of the body. Their primary function is the clearance of pathogens, infected host cells and debris through phagocytosis. Macrophages are derived from circulating monocytes produced in by haemopoietic stem cells in the bone marrow, although in some circumstances it is possible for tissue macrophages to proliferate within tissues independent of recruitment from the circulation.<sup>112</sup> Different macrophage subsets have been identified; M1 macrophages are classically activated and encourage inflammation; M2 macrophages are alternatively activated and are involved in tissue repair. Regulatory macrophages which are able to suppress inflammation by secretion of the anti-inflammatory cytokine IL-10, this is especially important in the gastrointestinal tract, where there is constant exposure to microbial products.<sup>113</sup> Finally Tumour-associated Macrophages and myeloid-derived suppressor cells (MDSC) , are immune suppressive cells which may inhibit anti-tumour activity.<sup>114</sup> Debate exists as to the exact classification of monocyte derived cells and to whether antigen presentation is a function of dendritic cells or macrophages<sup>115</sup> but macrophages play in role in antigen presentation and T-cell activation<sup>116</sup>.

### ***The Lacrimal Gland***

The lacrimal glands are paired exocrine glands situated in the lateral aspect of the roof of the orbit sitting in a depression of the frontal bone, the lacrimal fossa. The lacrimal gland is a compound tubulo-acinar gland, histologically consisting of multiple lobuli draining into an intralobular duct. Multiple intralobular ducts then drain into interlobular ducts, which in turn, drain into 5-7 ducts, which then enter the ocular surface.

As early as 1976, plasma cells were demonstrated in the lacrimal gland.<sup>117</sup> In the ageing, healthy lacrimal gland, lymphocytosis is frequently seen and are more commonly found in the orbital portion of the gland.<sup>118</sup> Lacrimal gland enlargement is a common finding in patients with Primary Sjögren's Syndrome (pSS) and lacrimal gland lymphocytosis is a hallmark of pSS.<sup>119</sup> In the MRL/lpr mouse model of pSS resident epithelial cells have been shown to express ICAM-1, facilitating lymphocyte migration.<sup>120</sup>

### ***The Lids and Meibomian Glands***

#### ***The Lids***

The eyelids are highly specialised tissues that have evolved to protect and so maintain ocular surface integrity. The eyelids serve a number of functions, all of which support the ocular surface and tear film and hence vision. Firstly, the eyelids act as a physical barrier, protecting the eye not only from physical damage, but from excess light and heat. A row of eyelashes protect the ocular surface from debris, and initiate the blink reflex.

In order for the tear film to act as a reliable refractive surface, it is vital that the tear film is smooth and even; the eyelids play a pivotal role in maintaining a consistent tear film. Each blink helps to redistribute the tear film, in particular redistributing the lipid tear film (see below). In addition to constantly redistributing the tear film, the eyelids act as a lacrimal pump to help remove tears from the tear film. Through action of the orbicularis muscle on the lacrimal sac, each blink compresses the sac, creating a negative pressure and 'sucking' tears into the canaliculi and out of the ocular surface.

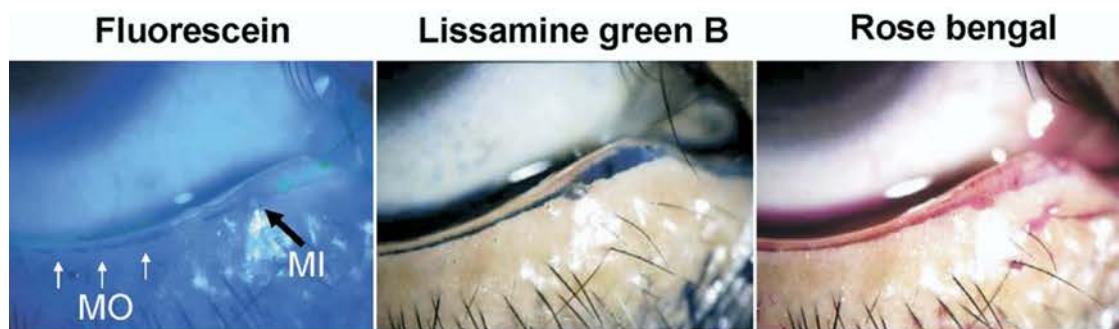Within the eyelid is a fibrous plate, the tarsal plate, which provides the lid with rigidity. These glands are responsible for producing meibum, a complex mixture of lipid species which form the lipid portion of the tear film. Spontaneous Blink Rate varies between individuals and increases with age<sup>121</sup> but is approximately 20 blinks/minute for an adult.

### ***The Meibomian Glands***

Within the tarsal plate is a row of modified sebaceous glands, first described by the German physician Heinrich Meibom in the 17<sup>th</sup> Century, and later named Meibomian Glands. They secrete a complex mixture of lipid species; these form the lipid layer of the tear film. Dysfunction of the glands, and subsequent alterations in the properties of lipid species causes an evaporative form of dry eye disease.

## **Marx Line**

Vital dyes are commonly used in clinical examination of the ocular surface; a number of vital dyes have been used clinically, including fluorescein and lissamine green. When such dyes are instilled, a clear, thin line becomes visible on the lid margin (Figure 6). This was first noted by Marx in 1924<sup>122</sup> and represents barrier line, delineating where the lipids forming the lipid tear film, meet the aqueous layer of the tear film. Marx's line is known to change with age, and with disease that affects Meibomian gland function. <sup>9</sup>



**Figure 6 The lower eyelid margin, stained with fluorescein, lissamine green and rose bengal to demonstrate Marx Line from Yamaguchi et al.<sup>9</sup> MO – Meibomian orifices, MI Marx line.**

## **Epidemiology of Ocular GvHD**

Exact figures on the incidence of ocular GvHD are complicated by changes in conditioning regimen, as total body irradiation may increase the risk of dry eye disease<sup>123</sup>, by treatments to prevent systemic GvHD<sup>124</sup>, and the indications for HSCT, as those with a diagnosis of a haematological malignancy are more at risk. <sup>124</sup>



The more recent figures suggest an incidence of ocular GvHD of between 33-50%.<sup>124-127</sup> with severe ocular disease in 13% and a severe reduction of vision to less than 20/200 in 2%.<sup>128</sup>

In the published literature, ocular GvHD is consistently more likely to be associated with systemic GvHD. Na *et al*<sup>124</sup> found that *all* of the patients in their cohort with ocular disease had evidence of systemic cGvHD, other authors find have found a different proportions of 14%<sup>125</sup>, 38%<sup>129</sup> and 50%<sup>128</sup>, 81%<sup>130</sup>. Furthermore, the likelihood of ocular GvHD may depend on the degree of systemic cGvHD; with ocular disease being more likely the more 'non-ocular' organs have cGvHD. <sup>124</sup>It is important to note that the earlier literature is complicated by the inclusion of patients who have undergone TBI and that this finding is universal with one author reporting no significant relationship between the presence of chronic systemic GvHD and ocular GvHD<sup>127</sup>.

Interestingly there appears to be a relationship of the ocular disease with preceding acute systemic disease. A number of authors have found that the development of acute systemic GvHD increases the chance of subsequently developing ocular disease. <sup>124,126,129</sup> and as mentioned above, aGvHD increases the risk of subsequently developing systemic cGvHD. <sup>49-55</sup>

Gender mismatch has long been identified as risk factor for aGvHD<sup>131</sup> and this has also been shown to be significant factor for the ocular disease, with ocular GvHD being more common in female to male transplants.<sup>126,132</sup> This occurs even in fully MHC matched transplants and is believed to be due to mismatches

in minor histocompatibility antigens. <sup>133</sup> In particular, female donors have not been exposed to epitopes originating on the Y chromosome and thymic deletion would not have removed cells that recognise the H-Y antigens, increasing the risk of GvHD, and the benefits of GVL.<sup>134</sup>

Most importantly, there is a significant impact in the quality of life in patients with ocular GvHD. Riemens *et al*<sup>135</sup> used the VFQ25 to assess 54 patients with post-HSCT and compared patients post-HSCT with ocular GvHD to patients post-HSCT without ocular GvHD. The study found patients with ocular GvHD had significantly worse ocular pain, they found it significantly difficult to maintain their roles in life and they had significant difficulties in social functioning.

#### Clinical Findings in Ocular GvHD

GvHD can affect the eye and ocular adnexae in a number of ways, but the ocular surface disease is by far the most common. Table 7 lists the ocular manifestations of ocular GvHD.

Anterior Segment	Chronic	Keratoconjunctivitis Sicca
	Chronic	Cicatrising Conjunctivitis
	Acute	Pseudomembranous Conjunctivitis
Inflammatory	Chronic	Anterior Uveitis <sup>136</sup>
	Chronic	Posterior Scleritis <sup>137</sup>
Posterior Segment	Chronic	GvHD Retinopathy <sup>138</sup>
	Chronic	Central Serous Retinopathy <sup>139</sup>

**Table 7 The different Ocular Manifestations of Acute and Chronic GvHD. Whilst ocular surface is the most common, less common manifestations have also been described in the literature.**

## **Pathogenesis of GvHD affecting the Ocular Surface and Lacrimal Apparatus**

### ***Ocular Surface GvHD***

In 1983, Jabs et al<sup>8</sup> described the histological features of conjunctival biopsies and ocular tissue obtained at autopsy from 19 post-HSCT patients, with seven samples from six patients with clinical evidence of ocular acute or chronic GvHD. The prominent feature on light microscopy was conjunctival keratinisation, which was present in five specimens, each in patients with either acute or chronic GvHD. A lymphocytic infiltrate was demonstrated (Figure 7), but only in two patients, both with acute GvHD and pseudomembranous conjunctivitis.



**Figure 7 Bullous Separation of conjunctival epithelium with migration of lymphocytes into basal layer from Jabs et al.<sup>8</sup>**

Rojas et al<sup>140</sup>, examined conjunctival biopsies with immunohistochemical techniques of patients before and after allogenic and autologous HSCT and in patients with and without GvHD related KCS. In all patients following HSCT, they found increased numbers of both CD4+ and CD8+ lymphocytes, and CD14+ cells. In both autologous and allogenic HSCT patients with dry eye, they found increased numbers of CD14+ cells. They were not able to further

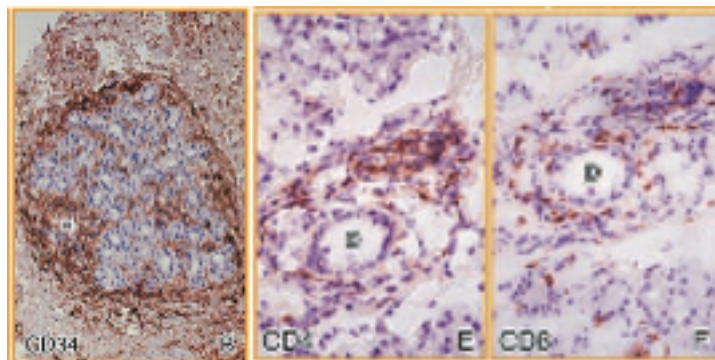
phenotype the CD14+ cells. Auw-Haedrich *et al*<sup>141</sup> also used immunohistochemistry to compare patients with ocular GvHD with healthy controls. They found an increased number of CD8+ cells in the conjunctiva, but did not provide a statistical analysis of the numbers. Tatematsu *et al*<sup>94</sup> also used immunohistochemistry, but using impression cytology and, in addition to squamous metaplasia of the mucosal microvilli, they demonstrated CD8+ cells in the basal epithelium of patients with ocular GvHD, but not in patients with SS or healthy volunteers. Eberwein *et al*<sup>142</sup> also demonstrated the presence of CD8+ in impression cytology samples, but when compared to the numbers in healthy volunteers, this failed to meet statistical significance.

Herretes *et al*<sup>5</sup> have shown in a mouse model of ocular GvHD found increased CD4+ and CD8+ cells in the conjunctiva. Furthermore, they used fluorescently labelled cells for the HSCT, and so were able to identify the CD4+ and CD8+ T-cells as originating from the donor. Interestingly the presence of infiltrating donor T-cells occurred *before* the onset of ocular disease. Furthermore, they were able to determine that these infiltrating T-cells originated predominantly from the transplanted donor T-cells rather than from reconstitution of transplanted haemopoietic cells. In addition to lymphocyte populations in the ocular surface of mice with ocular disease, Herretes *et al* also identified the presence of CD11b+ mononuclear cells and neutrophils.

### **Lacrimal Gland GvHD**

Jabs et al<sup>8</sup> also described the lacrimal gland features using tissue obtained at autopsy. They found accumulation of PAS-positive material and lacrimal stasis and occlusion and obliteration of the lumen of the acini. They do not report on any cellular infiltrate of the lacrimal glands.

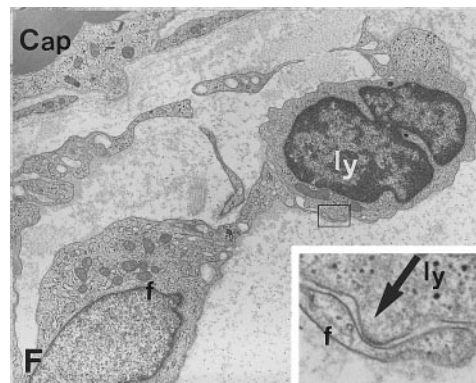
The lacrimal gland findings in ocular GvHD have been further described in both the human<sup>4</sup> and the mouse model<sup>5</sup>. The cellular infiltrate is composed of lymphocytes, macrophages and fibroblasts and is consistent in both the human (Figure 8 and Figure 9) and the mouse model (Figure 10).. These lymphocytes were subsequently further characterized as predominantly T-cells, both CD4+and CD8+cells with predominantly CD4+infiltrates and a smaller number of B-cells. <sup>3</sup> Furthermore, electron microscopy has demonstrated cellular



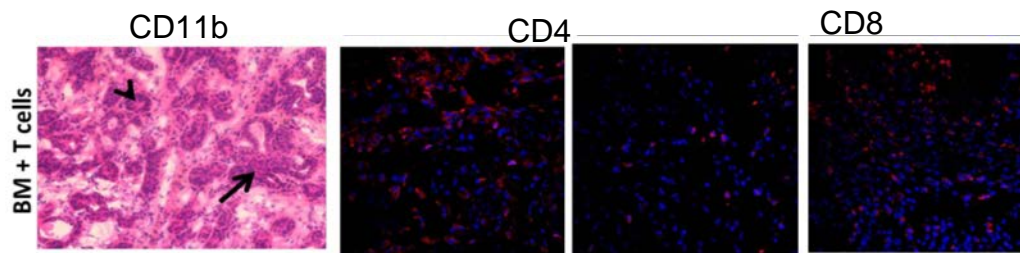
**Figure 8 Immunohistochemistry of lacrimal gland from patient with ocGVHD demonstrating periductal infiltrate of CD34+ fibroblasts, CD4+ and CD8+cells from Ogawa et al.<sup>3</sup>**

interaction between macrophages and fibroblasts (Figure 9). in the lacrimal gland of patients with ocular GvHD.<sup>4</sup>

This picture is remarkably similar to the lacrimal gland findings in Sjögren's syndrome, which is also characterised by CD4+ lymphocytes, CD8+ lymphocytes, macrophages and a smaller population of B-cells. Thus the lacrimal gland, in both diseases, contains the pre-requisite cells to initiate a B-cells response; antigen presentation, and T-cell activation. B-cells have been heavily implicated in GvHD with early reports of successful treatment with anti-B-cell therapies such as anti-CD20 antibody (rituximab) <sup>143</sup> being later confirmed in larger prospective trials. <sup>144,145</sup> These findings are similar to the findings in salivary gland cGvHD.



**Figure 9 Electron microscopy of human lacrimal gland in patient with ocular GVHD demonstrating lymphocyte and macrophages attached to fibroblasts in the perivascular area - Inset: Typical primitive contact (arrow). Ogawa et al 2001<sup>4</sup>**



**Figure 10** Histological and Immunohistochemical slide from lacrimal gland of mouse model of ocular GVHD demonstrating lacrimal gland stasis (arrowhead) and a dense cellular infiltrate composed of CD11b, CD4 and CD8 cells Herretes et al.<sup>5</sup>

### ***Tear Film Findings in Ocular GvHD***

Riemens et al<sup>146</sup> used multiplex cytokine bead array to examine the tears of patients with and without ocular GvHD and compared them to healthy volunteers. They looked at six cytokines; IL-2, IL-4, IL-6, IL17A, TNF- $\alpha$ , and INF- $\gamma$  and found increased levels of IL-6 and TNF- $\alpha$  in patients with ocular GvHD when compared with both post-HSCT patients without eye disease and healthy volunteers.

Jung et al<sup>147</sup> performed a similar study, also using multiplex cytokine bead array, looking for IL-2, IL-6, IL-10, IL-4, INF- $\gamma$  and TNF- $\alpha$ , in patients with cGvHD (as defined by NIH criteria<sup>2</sup>) which importantly includes ocular GvHD as part of the criteria. Ocular disease was assessed using a number of criteria including ocular surface staining, TBUT, Schirmer's score, conjunctival injection and OSDI. They found evidence of increased levels of all tear cytokine levels except IL-4 in patients with systemic GvHD. In patients with signs of ocular



GvHD, they again found increases in levels of all cytokines, except IL-4, with a stronger correlation for IL-6, IL-10 and TNF- $\alpha$  ( $r > 0.4$ ).

## **Dry Eye Disease**

### **Definition of Dry Eye Disease**

The DEWS II report defines dry eye disease as<sup>148</sup>

“Dry eye is a multifactorial disease of the ocular surface characterized by a loss of homeostasis of the tear film, and accompanied by ocular symptoms, in which tear film instability and hyperosmolarity, ocular surface inflammation and damage, and neurosensory abnormalities play etiological roles.”

This definition attempts to describe the complex nature of both the symptomatology and pathophysiology of dry eye disease. Multiple clinical entities with similar clinical features are encompassed in the dry eye syndrome.

### **Classification**

The 2007 DEWS report<sup>64</sup> classifies the causes of Dry Eye Disease into two main categories, aqueous deficient dry eye disease (ADDE) and evaporative dry eye disease (EDE). This was refined by the DEWS II report<sup>149</sup> which considers dry eye disease to exist on a spectrum with pure ADDE and pure

EDE on each end, with a continuum of mixed dry eye disease in between (Figure 11).

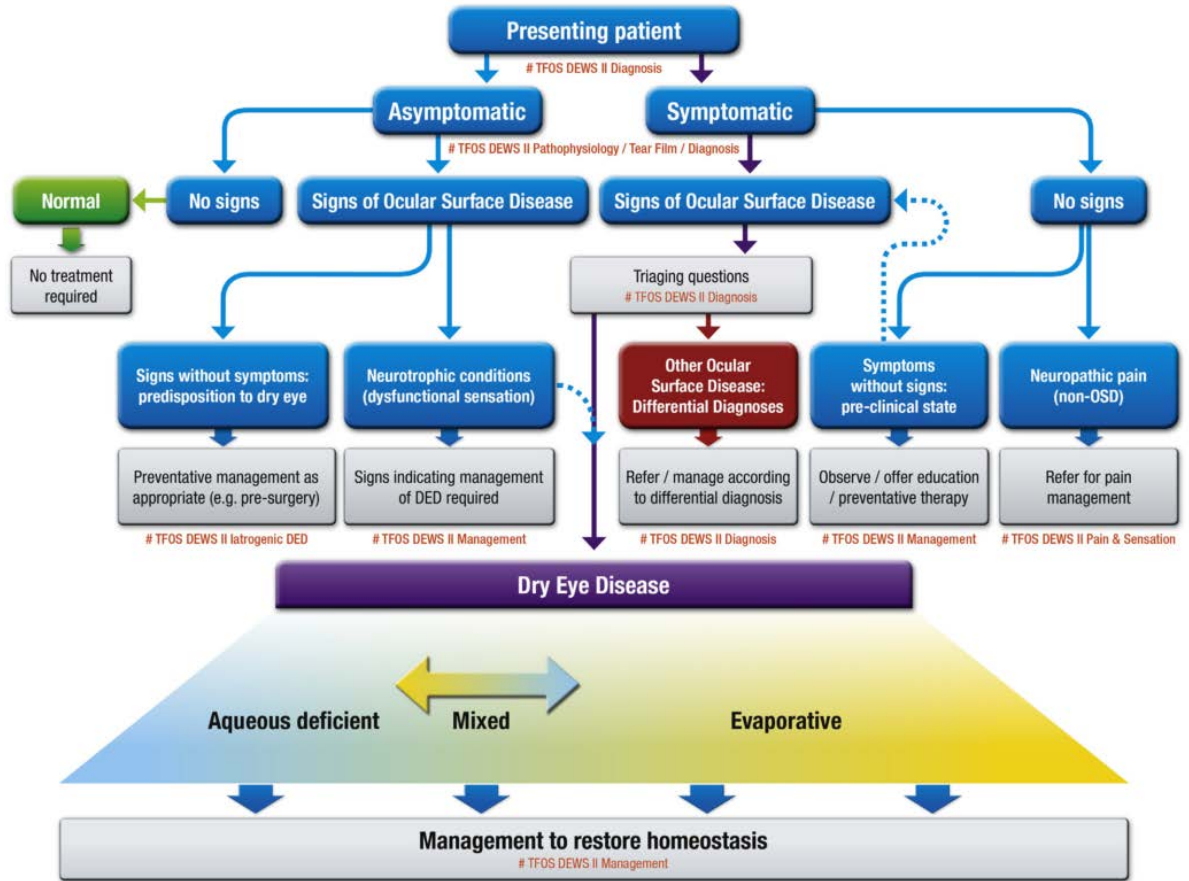


Figure 11 DEWS II Aetiological Classification of Dry Eye Disease from 2017 DEWS II report. Note how dry eye can manifest as a number of clinical entities, all requiring a tailored approach to treatment.

**Aqueous Deficient Dry Eye Disease (ADDE) and Sjögren's Syndrome**

In ADDE, there is insufficient production of the aqueous component of the tear film. The classical form of ADDE occurs in Primary Sjögren’s Syndrome (pSS); where autoimmune mediated inflammation causes fibrosis of the lacrimal gland and other exocrine glands, such as the salivary gland. Lacrimal gland biopsies

of patient with Sjögren's have demonstrated lymphocytosis with predominantly CD4+cells and B-cells<sup>150</sup>; although CD8+cells and antigen presenting cells have also been demonstrated. <sup>150</sup> The resultant fibrosis results in reduced tear production and subsequent ADDE. The lacrimal gland damage in ocular GvHD is very similar, albeit with a different cause: in ocular GvHD the immune mediated damage to the lacrimal gland is incited by donor alloreactive cells causing ADDE.

### ***Evaporative***

Deficits in the lipid tear film, also cause dry eye syndrome despite an adequate tear production. In EDE, abnormalities in the lipid tear film, allow rapid evaporation of the tear film and reduced tear stability. EDE can be intrinsic or extrinsic depending on the causes. Intrinsic dry eye disease includes Meibomian gland dysfunction, disorders of lid anatomy, low blink rate; extrinsic causes include vitamin A deficiency, topical drugs/preservatives, contact lens wear, or ocular surface disease.

### **The Tear Film**

Classically the tear film has been described as a tri-laminar structure<sup>151</sup> composed of three layers.

1. Lipid Layer
2. Aqueous Layer
3. Mucin Layer

The lipid layer, secreted by the Meibomian glands, 'floats' on the surface of the tear film, preventing tear evaporation. The aqueous layer, constitutes the majority of the tear film, and is secreted by the lacrimal glands, and accessory lacrimal glands. The mucin layer is secreted by the epithelium of the cornea and conjunctiva, and enables interaction between the cellular epithelium and the aqueous tear film. More recently, it has become apparent that this is an oversimplification. Rather than separate layers, the mucin layer represents a gradient of mucous components<sup>152</sup>, more concentrated at the epithelial surface, and diluting superficially. This had led to the concept of a single mucoaqueous layer. In-vitro studies have demonstrated that contrary to the classical model, the thickness of the lipid layer may *not* affect the evaporation rate of tears<sup>153</sup> leading some authors to suggest the role of the lipid tear film is to allow smooth distribution of the tear film, rather than to prevent evaporation.<sup>154</sup>

### **Pathophysiology of Dry Eye Disease**

Clarity of the ocular media is a pre-requisite for vision and maintenance of this clarity is a vital function of the ocular surface. Inflammation related damage to the ocular media risks this clarity and, even with successful clearance of the inciting agent, would lead to permanent scarring and loss of vision. A number of mechanisms have evolved within the eye to limit inflammation and so limit inflammation induced damage, and the ocular surface is no exception.

A number of anti-inflammatory cytokines are found in the tears of healthy volunteers. Including interleukin -1 receptor antagonist (IL-1-RA)<sup>155</sup>,

transforming growth factor beta (TGF-beta)<sup>156</sup>, IL-10<sup>155</sup>, IL-13<sup>155</sup>, Tissue Inhibitor of Metalloproteinase-1 (TIMP-1)<sup>157</sup>, programmed death-ligand 1 (PD-1-L1)<sup>158</sup>, decay accelerating factor (DAF)<sup>159</sup> and membrane inhibitor of reactive lysis (MIRL).<sup>160</sup> TGF- $\beta$  in both the tears and released by Goblet cells<sup>161</sup>, has been shown to suppress dendritic cell (DC) maturation on the ocular surface, reducing expression of co-stimulatory molecules, and reducing DC stimulation of T-cells.<sup>162</sup> DAF and MIRL are membrane bound proteins that protects from complement activation, and the presence of both have been demonstrated in both the lacrimal gland and the corneal epithelium. <sup>159,160</sup>

As mentioned above, the ocular surface contains a population of intraepithelial lymphocytes (IEL),<sup>163</sup> and amongst these cells exists a population of T-reg cells (CD4+ CD25+ FoxP3+) which can suppress effector T-cells.<sup>110</sup> NKT cells are also found on the ocular surface, and, through the release of IL-13, protect goblet cells<sup>164</sup> and hence maintain suppression of dendritic cells maturation.<sup>161</sup>

As discussed above a number of possible mechanisms exist to produce dry eye disease. In ocular GvHD, the mechanism behind the keratoconjunctivitis sicca, primarily involves aqueous deficiency from lacrimal gland involvement. A common point in the pathophysiology of all forms of dry eye, is hyperosmolarity which results in a number of changes in the ocular surface. Desiccating stress has been shown to affect a number of cell populations in the eye, including epithelial cells, Goblet cells and antigen presenting cells. Epithelial cells respond to desiccating stress by activation of the NF-kappa-beta and MAPK

pathways resulting in the release of inflammatory mediators including IL-1beta, TNF- $\alpha$  and MMP-9.<sup>165</sup> Furthermore, IL-6 and IL-8 are not only produced by human cultured epithelial cells, but also may be implicated in epithelial cell death. <sup>166</sup> Goblet cell death results in reduced production of TGF-beta, allowing DC maturation. Bone marrow derived cells upregulate chemokine receptors, in particular CCR5. <sup>167</sup>

Activation of Pattern Recognition receptors, such as TLR4, encourages CD11b+ monocyte infiltration.<sup>168</sup> Additionally, epithelial cell apoptosis releases DNA in of dry eye disease<sup>169</sup>, and TLR receptors have been shown to react to endogenous DNA in autoimmune disease, such as Sjogren's Syndrome.<sup>170</sup> Monocytes have been shown to play a role in dry eye disease<sup>171</sup> and are increased as disease severity increases<sup>172</sup>; bridging the innate and adaptive immune system, acting as APC and encouraging and maintaining T-cells infiltration at the ocular surface. <sup>173</sup> Although some authors have not found an increase in the number of macrophages, instead suggesting that a change in the relative subtypes of macrophages may be more important.<sup>174</sup> NK cells are seen early in the dry eye response and their depletion ameliorates desiccating stress damage in the animal model. <sup>175</sup>

As result of the innate response, the efferent arm of the response adaptive response is by T-cells, CD4+cells found in the conjunctiva of patients with dry eye, <sup>176</sup> and transfer of CD4+T-cells isolated from mice exposed to desiccating stress will cause dry eye in T-cell depleted mice. <sup>177</sup> Further work has heavily

implicated Th17 cells as drivers of dry eye disease. Th17 cells are activated in secondary lymphoid tissues which subsequently migrate to ocular surface and induce further immune responses.<sup>178</sup> Locally, Th17 differentiation may well be occurring on the ocular surface, as in vitro co-culture of naïve CD4+ cells can induce Th17 polarization.<sup>179</sup>

# Hypothesis and Aims

## Hypothesis

Firstly, we propose that there is cycling of immunocompetent cells in the conjunctiva and these cells will be reconstituted following bone marrow transplantation.

Secondly we propose that in ocular GvHD, there is Graft-vs-Host response, in the ocular surface that is *independent* of the aqueous deficient dry eye disease caused by lacrimal gland fibrosis and destruction.

## Aims

In this study, we aim to describe how the ocular surface leukocyte populations reconstitute following HSCT and how this differs from leukocyte reconstitution in the blood and from the conjunctival leukocyte populations in healthy volunteers.

Secondly, we aim to describe how the conjunctival leukocyte populations in patients with ocular GvHD differs from that in patients without ocular disease, healthy volunteers and in patients with pSS.



# Materials and Methods

## Clinical Studies

### Ethical Approval

Clinical data collection and patient sampling were undertaken following ethical approval and in accordance with the Declaration of Helsinki. Ethical approval for recruitment, examination and sampling from all patients was obtained through the West Midlands - Black Country research ethics committee (Reference 11/WM/0204).

### Clinical Examination

For each Cross-Sectional and Longitudinal Cohort patient, a standardised clinical assessment was performed.

Three questionnaires were given to the patient to self-complete; on the impact of the transplant on the patient (FACT-BMT v4), on the quality of the patients visual function (National Eye Institute Visual Function Questionnaire 25), and finally a questionnaire on the severity of the dry eye symptoms<sup>9</sup> (OSDI, Allergan).

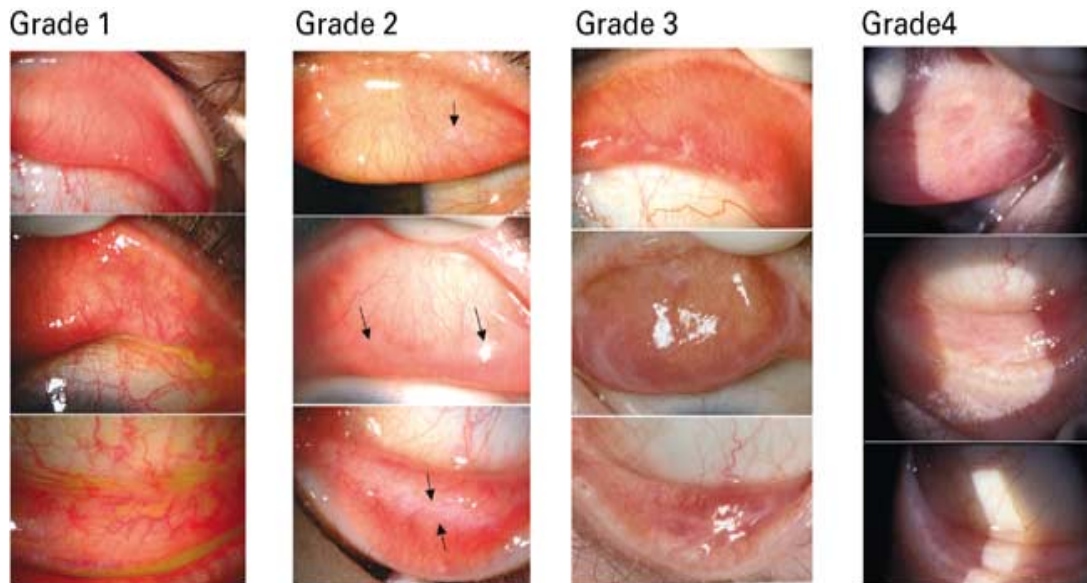The patient's visual acuity was measured using logMAR chart. Tear osmolarity was measured using a Tearlab (TearLab Corp., San Diego, CA). Local anaesthetic was instilled (Oxybuprocaine 0.4% minims, Bausch and Lomb) and Ocular Surface Impression Cytology (OSIC) was performed as per below.

Unanaesthetised Schirmer's testing was performed for five minutes. Slit lamp biomicroscopy was performed with a standardised protocol. Lid examination included assessment for Meibomian gland changes using a modified version of the schema set out by Bron et al<sup>180</sup> concentrating on those features that might alter in cicatrising disease (Table 8).

Anatomical Structure	Measure	Scoring
Eyelid Margin	Irregularity	0. No 1. Yes
	Vascularity	0. No 1. Yes
	Lash Loss	0. No 1. Yes
	Trichiasis or Dystichiasis	0. No 1. Yes
	Which?	<ul style="list-style-type: none"> <li>• Trichiasis</li> <li>• Dystichiasis</li> </ul>
	Malapposition	0. No 1. Yes
	Anterior Blepharitis	0. No 1. Yes
Mucocutaneous junction	Anteroplacement	0 - 3
	Retroplacement	0 - 3
	Ridging	0 - 3
	Mucosal Absorption	0. No 1. Yes
Orifices	Pouting or plugging	0. No 1. Yes
	Opaque/scarred	0. No 1. Yes
	Retroplacement	0 - 3
Main Duct	Cystoid Dilatation	0 - 3
Acini	Visibility	<ul style="list-style-type: none"> <li>• Clusters</li> <li>• Yellow stripes</li> <li>• Not Visible</li> </ul>
	Concretions	<ul style="list-style-type: none"> <li>• Deep</li> <li>• Subepithelial</li> <li>• Extruding</li> </ul>
	Chalazia	0 - 3
Secretions	Foam	0. No 1. Yes
	Quality	<ul style="list-style-type: none"> <li>• Clear</li> <li>• Cloudy</li> <li>• Granular</li> <li>• Toothpaste</li> </ul>
	Expressability	<ul style="list-style-type: none"> <li>• Light pressure</li> <li>• Moderate pressure</li> <li>• Heavy pressure</li> </ul>

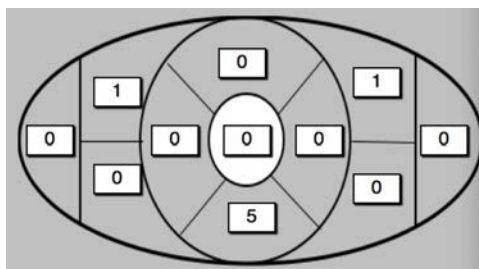
**Table 8 Modified Bron Schema for the Scoring of Meibomian Gland Changes**

Vital dye staining was performed using Lissamine Green and Fluorescein. Tear Break Up Time (TBUT) was measured at the slit lamp. An assessment of Marx's line was performed using the scoring system described Yamaguchi et al.<sup>9</sup> Briefly this score assesses posterior migration of the Meibomian gland orifices on a scale of 0-9 with higher scores indicating more marked posterior orifice migrations. Conjunctival and corneal staining was assessed using a modified Oxford Score.<sup>181</sup> Conjunctival fibrosis was assessed using the grading system described by Robinson et al<sup>1</sup> (Figure 12).




**Figure 12 From Robinson et al <sup>1</sup>. Representative grading photos for conjunctival Inflammation associated with chronic GVHD. Arrows illustrate the subtle cicatricial changes associated with Grade 2.**

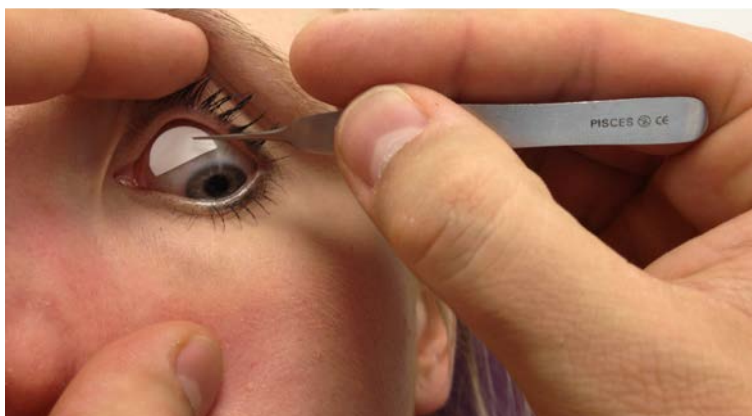Ocular Surface Staining was assessed using a modified version of the Oxford staining system by Bron et al<sup>181</sup>. This system separates the ocular surface into 5 corneal areas, and two pairs of 3 conjunctival areas, nasal and temporal (Figure 13). The degree of staining is compared to mathematically defined grading panels to describe the severity of staining, grading the staining from 0-8 (Figure 14).



**Figure 13** Diagram to show how the ocular surface is subdivided in the modified Oxford Schema. The cornea is divided into 5 sections, including the visual axis. The medial and lateral conjunctiva are each divided into 3 sections.



**Figure 14** Mathematically random dot patterns used to describe the severity of ocular surface staining in each area of the ocular surface. Each panel contains a randomly generated dot pattern with increasing density.



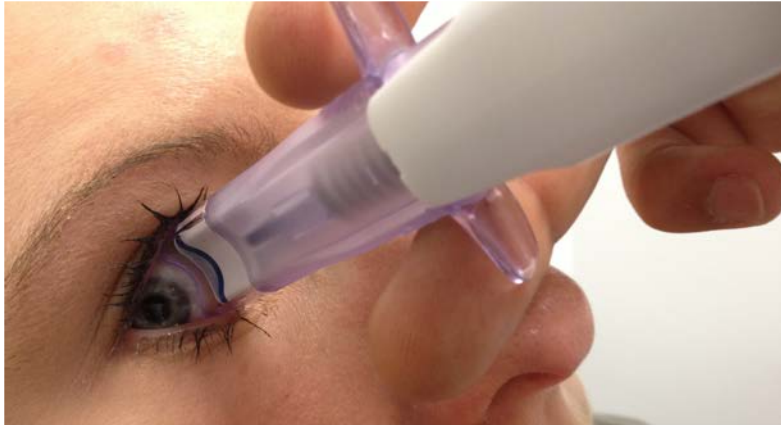**Figure 15 Ocular Surface Impression Cytology with Supor 200 filter**

### **OSIC Sampling Method**

Ocular Surface Impression Cytology (OSIC) was performed according to techniques first described by Baudoin et al<sup>182</sup>. Supor 200 polyethersulfone filters (Supor® 200 membrane, Pall Corporation, Ann Arbor, MI, USA) were bisected and autoclaved; four halves were used, resulting in a total sampling area of 264mm<sup>2</sup>.

Before patient sampling, experiments on healthy volunteers demonstrated that conjunctival impression sampling after the use of lissamine green, a vital dye used in clinical examination, can affect subsequent flow cytometry due to fluorescent interference from the lissamine green<sup>183</sup> (Appendix 1 Use of lissamine green before conjunctival impression cytology and flow cytometry in patients with Sjögren's syndrome). Sampling was therefore performed before clinical examination. Topical anaesthesia was instilled into the subject's fornix and two bisected halves were placed onto the superior bulbar conjunctiva and

two were placed on the inferior bulbar conjunctiva, each for 3-5 seconds (Figure 15). Care was taken to avoid the interpalpebral area, in order to avoid iatrogenic changes that might be confused with pathological conjunctival staining on subsequent slit lamp biomicroscopy examination.



**Figure 16 Ocular Surface Impression Cytology with the EyePRIM device**

During the study, a new purpose designed device was introduced for conjunctival impression cytology. The EyePRIM (Opia Technologies, Paris, France) contains a polyethersulphone (PES) supor filter with an area of 69mm<sup>2</sup> mounted in a single use device (Figure 16). Experimentation on healthy volunteers demonstrated that OSIC was quicker and less painful using the EyePRIM, with no difference in cellular yields when two EyePRIM devices were used (total area 138mm<sup>2</sup>) compared with four bisected halves of a supor 200 filter (total sampling area 264mm<sup>2</sup>).<sup>184</sup>



Immediately following sampling, the filter papers were placed directly into tissue culture medium (1.5ml of RPMI 1640 (Sigma-Aldrich, Dorset, UK) enriched with 10% Heat Inactivated Foetal Calf Serum (HIFCS) (Sigma-Aldrich) in a sterile 5ml bijou.

## **Ex vivo experimentation**

### **Conjunctival Cell Recovery**

Samples were processed within 5 hours of sampling. Conjunctival cells were removed from the Supor filter by gentle agitation with a sterile 1ml pipette tip for 1 minute whilst the filter paper was still suspended in RPMI/HIFCS.

The tissue culture medium, containing the suspended cells, was removed and centrifuged. The supernatant was discarded and the cell pellet resuspended in 90µl tissue culture medium to give a working volume of approximately 100µl and pipetted into 96 well plates in preparation for immunostaining.

### **Lysed Blood Preparation**

Venepuncture was performed, into K2 EDTA coated vacutainers (Becton Dickinson, Oxford, United Kingdom). 1ml of whole blood was centrifuged and the plasma removed and discarded. Red cell lysis was performed with 9ml (1:10 dilution) of ACK buffer (consisting of 8.29g NH<sub>4</sub>Cl, 1g KHCO<sub>3</sub> and 37.2 mg EDTA per litre) was added for 5 minutes. To stop continued lysis, 15ml of RPMI medium was added. Samples were then centrifuged, the supernatant discarded and the pellet resuspended with 10ml PBS. Samples were centrifuged for a

second time, again the supernatant discarded and the pellet resuspended in 1ml PBS.

### **Antibody Staining**

100 microl of cells were pipetted in to 96-well plates aiming for a cell count per well of  $2 \times 10^5$ — $1 \times 10^6$  for PBMCs). The plate was centrifuged (4 minutes at 400g at 4° C), the supernatant was removed and the 96-well plate gently vortexed. Antibodies specific for a number of surface markers (Table 9) were made up to 50µl appropriate dilutions (optimal antibody concentrations having been previously titrated) and incubated with the cells on ice in the dark for 20 minutes. Post-staining, 100µl of FACS buffer (PBS and 0.5% Bovine Serum Albumin (BSA; Sigma- Aldrich) was added to each well and the plate was centrifuged for a second time and the supernatant removed. The pellet was resuspended in 295µl of FACS buffer. To allow us to ascertain what proportion of the sample had been run through the flow cytometer, 5 µl of counting beads (CALTAG/Invitrogen, Paisley, UK) (1002 beads/ µl) were added.

Surface antibody		Fluorochrome	Manufacturer
CD11b	Macrophage/Monocyte cell marker	FITC	Ebioscience, Hatfield, UK
CD8a	CD8+ Cytotoxic Lymphocytes	VioGreen	Miltenyl Biotec
CD16	Macrophage/Monocyte cell marker	PE	Ebioscience, Hatfield, UK
CD45RO	Isotype of CD45 used to differentiate between naïve and mature T cells	PE-CF594	BD BioSciences, Oxford, UK
CD45	Pan-Leukocyte Marker	APC	Ebioscience, Hatfield, UK
CD4	CD4+ T-Helper Lymphocytes	PerCP-Cy5.5	Ebioscience, Hatfield, UK
CD14	Neutrophil Marker	APC-eFluor780	Ebioscience, Hatfield, UK
CD3	Lymphocyte Marker	APC-eFluor780	Ebioscience, Hatfield, UK
CD56	NK and NKT marker	PE-Cy7	Ebioscience, Hatfield, UK
Sytox Blue	Dead Cell Exclusion Dye		Invitrogen, Paisley, UK

**Table 9 Antibody-fluorochrome combinations used for immunostaining of lysed blood and conjunctival impression samples.**

In order to exclude any dead or dying cells, a nucleic acid stain, Sytox blue (Invitrogen, Paisley, UK), was used that only permeates dead cells. 30µl of Sytox blue as added at a dilution of 1/800 to the FACS tubes and incubated for 5 minutes at room temperature.

### Flow Cytometry

Flow cytometry was performed with a nine colour Dako Cyan ADP High Performance flow cytometer (Beckman Coulter, High Wycombe, UK).

## **Fluorescence Compensation**

One potential issue in multi-colour flow cytometry is overlapping fluorescent signals from fluorochromes emitting light in any adjacent spectra, which may be confused with another fluorochrome and hence cause falsely positive results. In order to avoid such fluorescence overlap, prior to each run of samples, a full electronic compensation panel was performed: consisting of a single fluorochrome incubated with positive and negative compensation beads (OneComp beads, EBioScience, Hatfield, UK). Any signal from a fluorochrome that overlaps into an adjacent spectrum is reduced. For example, if when the sample conjugated to PE is run through the flow cytometer, there is an overlapped fluorescence into the adjacent PE-Cy5 channel, then the PE-Cy5 channel is reduced down, or compensated, to zero by subtracting a percentage of the PE fluorescence value.

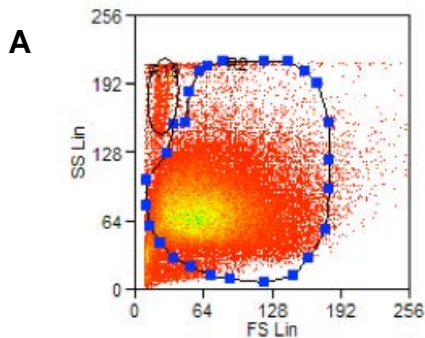
To allow compensation, each time a sample was run, 20 µl of positive and negative compensation beads were individually stained with each antibody-fluorochrome combination alongside the immunostaining of sample cells.

## **Gating Strategy**

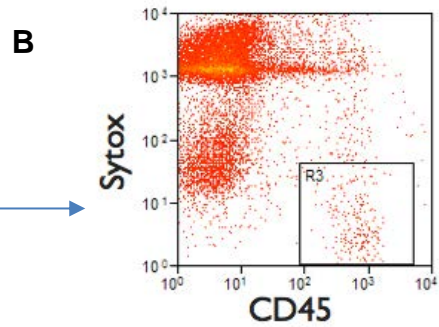
### ***Lymphocyte Gating Strategy***

The gating strategy to isolate different lymphocyte populations in the conjunctiva is shown in Figure 17. The first step was to remove the counting beads and cellular debris (Figure 17A). The majority of cells on the OSIC are epithelial cells; in order to identify viable leukocytes, a pan-leukocyte marker,

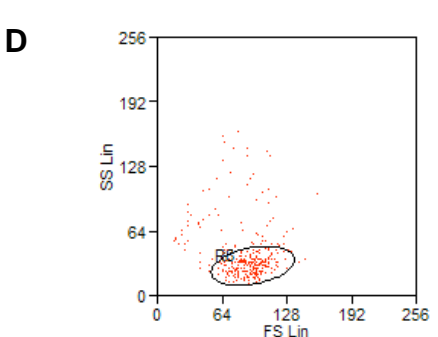
CD45, and the dead cell exclusion dye was used (Figure 17B). We needed to identify lymphocytes CD3+ cells; since CD14 and CD3 were both using the same fluorochrome, CD45 was used. Lymphocytes were CD45bright (Figure 17C) and to ensure only lymphocytes were included this population was back-gated onto the forward scatter and side scatter plot (Figure 17D) with lymphocytes defined as cells with low granularity. CD4+ and CD8+ cells were then isolated (Figure 17E) and then further subdivided into CD45RO+ and CD45RO- populations. Natural Killer T-cells were defined as those living leukocytes (exclusion dye negative CD45+) CD3+ cells that expressed CD56+.(Figure 17F)



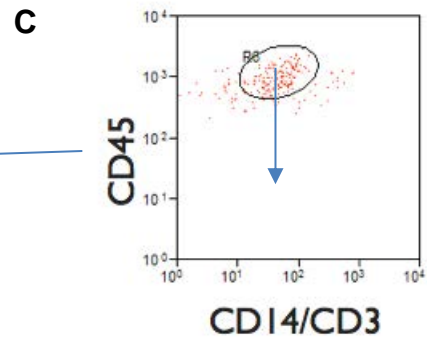
Forward Scatter and Side Scatter is used to identify the counting beads (area R19) and leukocytes selected in area R2.



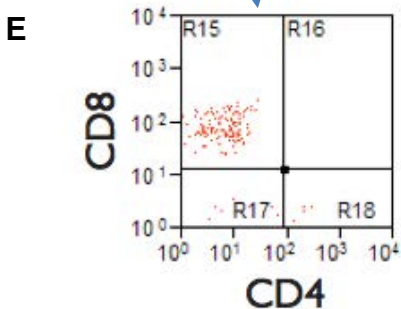
R2 is then gated to find the living (Sytox -ve) cells that are CD45+ (pan-leukocyte marker) in R3.



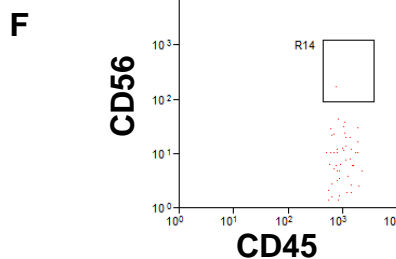
This is then backgated onto a Forward Scatter and Side Scatter Plot to ensure cells with a FS and SS typical of **lymphocytes** are counted (R8).



Since CD3 (lymphocytes) and CD14 (Monocytes) are on the same fluorochrome (APC-Cy7), lymphocytes are defined as CD45(high) and APC-CY7+ (R6).



Lymphocytes are then phenotyped into **CD4+** (R18) and **CD8+** (R15).

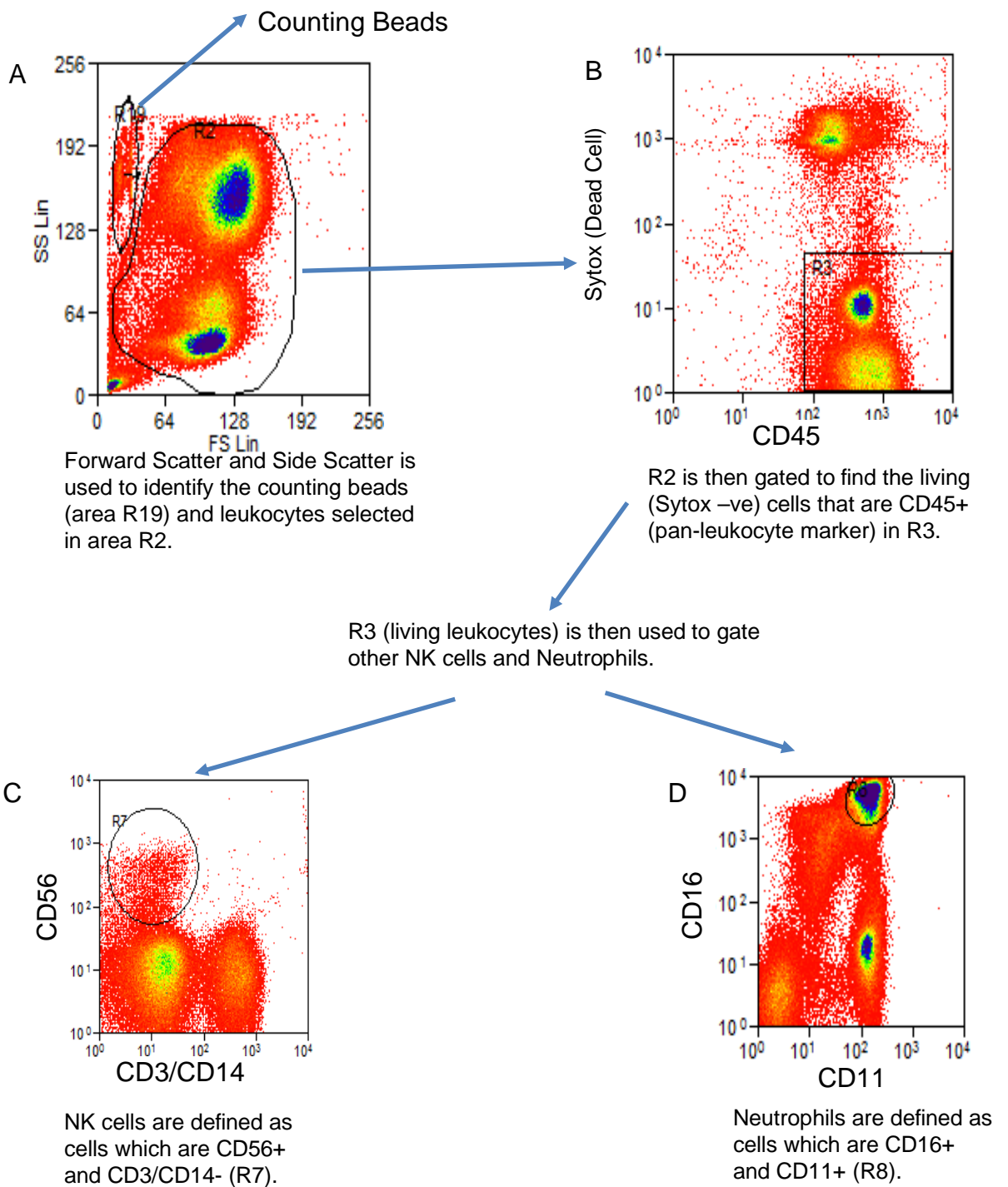


R8 (lymphocytes) are then gated to CD56, with **NKT cells** defined as CD56+ cells.

**Figure 17 Gating strategy to identify lymphocytes. A** Counting beads are counted and cells identified excluding debris. **B** Sytox and CD45 (panleukocyte marker) used to find living leukocytes. **C** CD45high (CD3+ lymphocytes) and CD45dim (CD14+ cells) on the same fluorochrome are defined. **D** This is then backgated onto FS and SS to ensure only lymphocyte shaped cells are included. **E** CD4 and CD8 lymphocytes are subdivided. **F** CD56 is used to describe NKT cells.

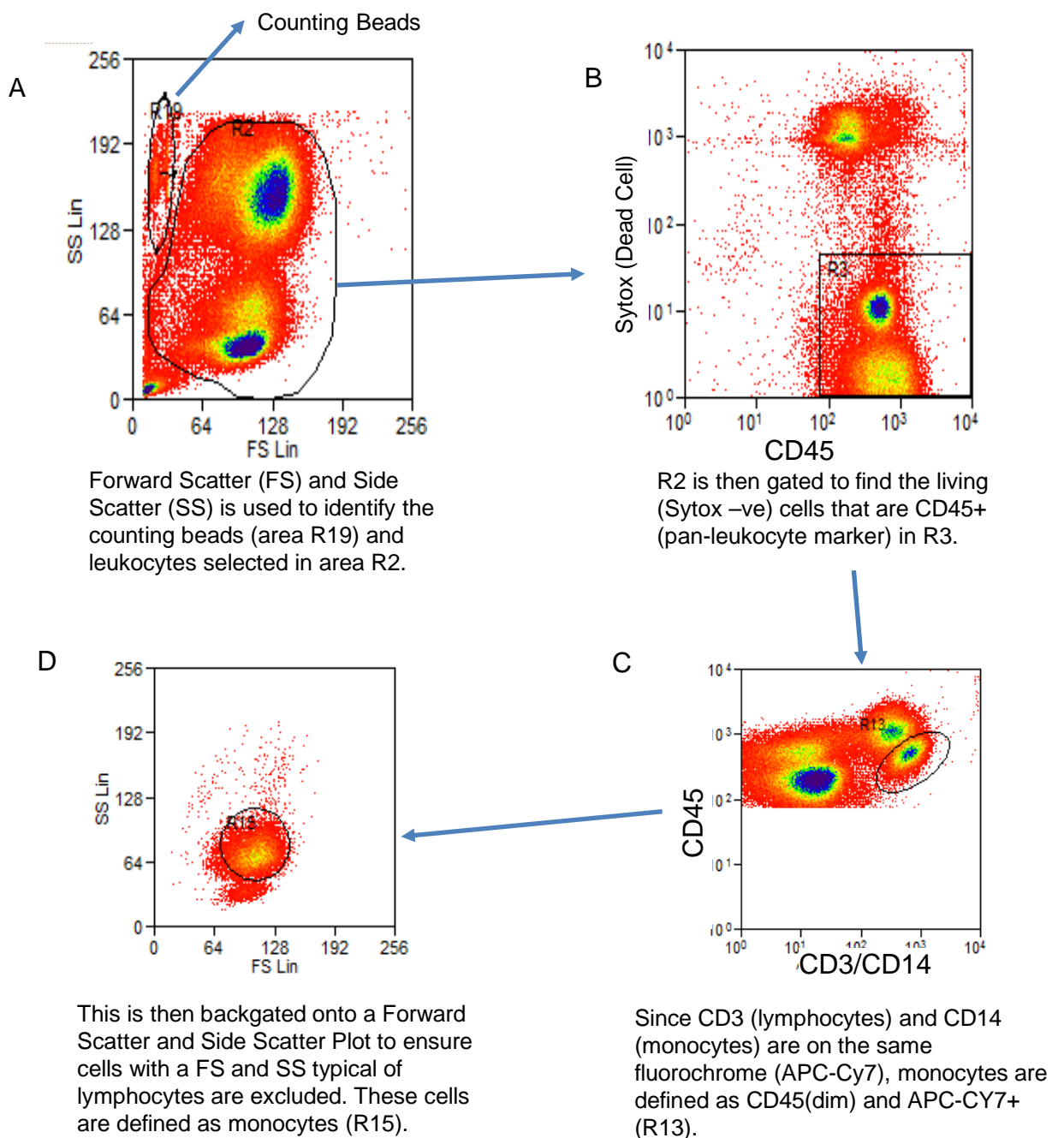
### ***Gating Strategy for monocytes, NK cells and neutrophils***

Since the numbers of conjunctival leukocytes were small, gating was first performed on lysed blood and then these gates used to help define the conjunctival cells. Figure 18 shows the gating strategy for both NK cells and neutrophils. As before, cells were initially isolated from debris (Figure 18A) and counting beads and living leukocytes isolated by using the pan-leukocyte marker CD45 and the dead cell exclusion dye (Figure 18B). These cells were then defined as NK cells if they were CD56+ (Figure 18C) or neutrophils if they were CD11b+ and CD16+ (Figure 18D). The gating strategy for monocytes is shown in Figure 19. Monocytes were defined as those cells that are living leukocytes (exclusion dye negative CD45+) and that were CD14+. Since CD14 and CD3 shared a fluorochrome, monocytes were defined as those cells that were less bright on CD45 and these cells were further backgated onto FS and SS to further differentiate these cells from lymphocytes. This was then performed on the OSIC samples .

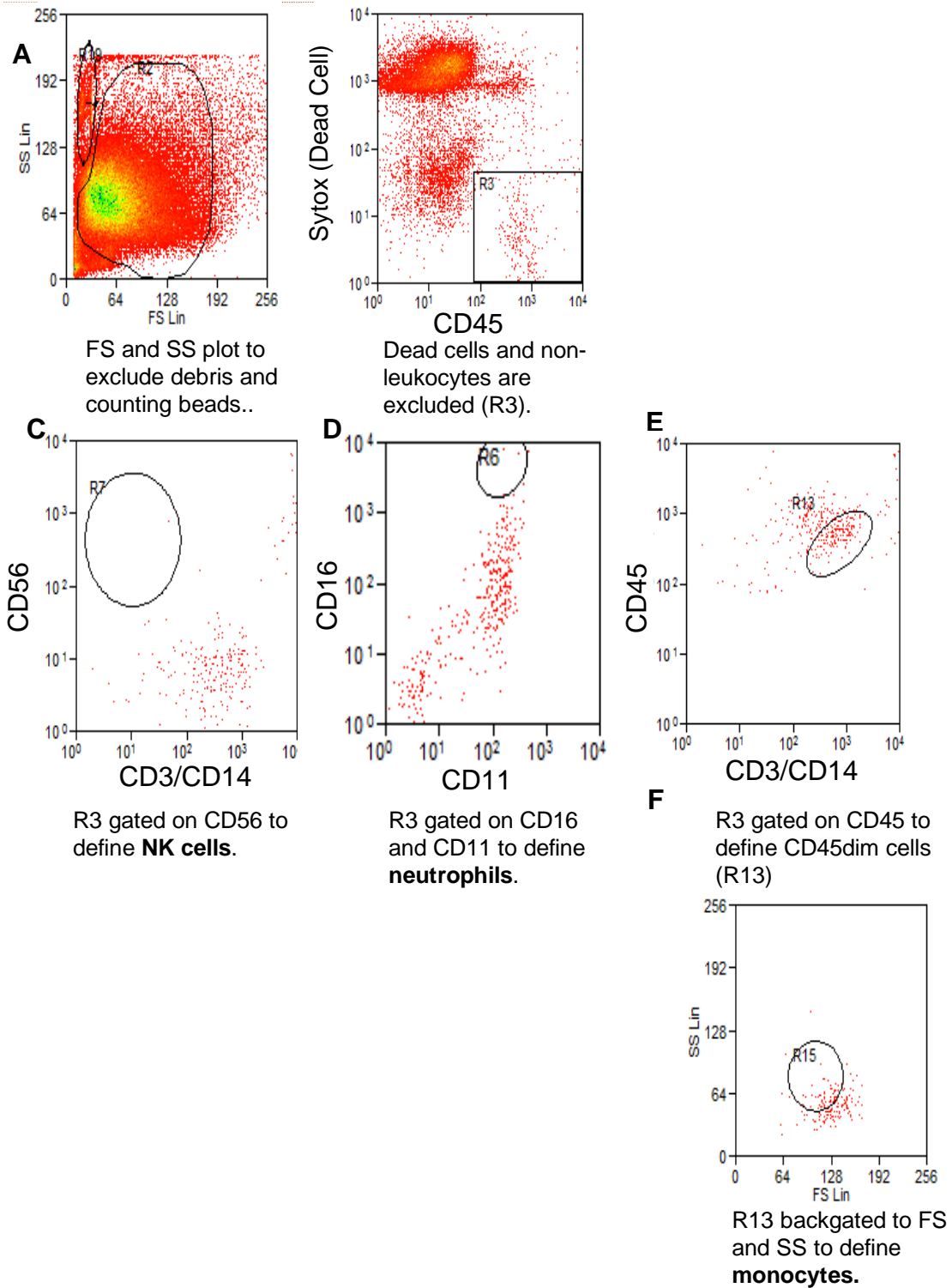


**Figure 18 Gating Strategy for NK Cells and Neutrophils in a lysed blood sample. A** Counting beads are counted and cells identified excluding debris. **B** Sytox and CD45 (panleukocyte marker) used to find living leukocytes. **C** NK cells are defined as CD56+ **D** Neutrophils are those cells that are both CD16+ and CD11+





**Figure 19 Gating Strategy for Monocytes in Lysed Blood** **A** Counting beads are counted and cells identified excluding debris. **B** Sytox and CD45 (panleukocyte marker) used to find living leukocytes. **C** Since CD3 (lymphocytes) and CD14 (monocytes) were on the same marker, CD45 was used to separate CD45dim cells and these were then backgated **D** to ensure cells with a FS and SS profile typical of monocytes were included.



**Figure 20** Gating strategy for NK cells, neutrophils and monocytes in a representative conjunctival sample. A shows FS and SS with R2 gating to include all cells, excluding counting beads and debris. B Cells from gate R2 that did not stain with the dead cell exclusion dye and were CD45 (pan-leukocyte marker) positive (R3). C is gated off R3 and shows NK cells (CD56 +h CD3/CD14-) D is also gated off R3 to show neutrophils (CD16+ /CD11+) high and CD11b high and are defined as neutrophils. E Shows a subset of CD3/CD14 high cells that are F back gated onto the FS and SS to define monocytes.

## **Statistical Analysis**

### **Longitudinal Cohort**

For the longitudinal analysis, two way repeated measures ANOVA using Graphpad Prism v6.0h for MacOSX, GraphPad Software, San Diego California USA, [www.graphpad.com](http://www.graphpad.com) were used.

### **Cross-Sectional Cohort**

Since the NIH classification uses the mean Schirmer's score of the two eyes, the mean number of cells in the patient's two eyes were used for statistical analysis of patients in the Cross-Sectional Cohort. Mann-Whitney non-parametric tests were then performed also using Graphpad Prism 6.0h.

Weighted Kappa analysis using the NIH severity scale was performed using graphpad's online Kappa calculator at

<http://www.graphpad.com/quickcalcs/kappa2/>. Since the severity scale is a symptomatic scale, the worst eye was considered for Schirmer's score. Since the Kappa score required equal sizes, when compared with Schirmer's score and with the International Consensus Group proposed diagnostic criteria, the last two NIH severity groups (2 and 3) were combined.

## Chapter 3 Longitudinal Cohort

### Patient Recruitment

Patients were recruited from the haematology clinics at the Centre for Clinical Haematology at University Hospital Birmingham. All patients who were listed for allogenic HSCT between May 2012 and July 2012 .

Patients were included if they were about to undergo allogenic HSCT; there were no restrictions on the indications or method of transplant. Patients were excluded if they had any history of pre-existing ocular inflammatory disease.

Patients were seen for a total of five visits; a baseline visit before HSCT and at 1 month, 3 months, 6 months and 12 months post-HSCT. At each visit a clinical assessment and ocular sampling (OSIC) and blood sampling was performed. Samples were stored on ice and flow cytometry was performed on the OSIC samples and lysed blood samples within 5 hours.

A total of five participants were recruited. One participant passed away due to recurrence of their original disease after the 3-month visit. One participant was seen at baseline, but failed the pre-assessment process, and their transplant was delayed, missing the 1 months and 3-month visit.

In order to compare leukocyte populations, five healthy volunteers were recruited; blood samples were taken and OSIC performed on nine eyes. There was no significant difference between the ages of the healthy volunteers and either the longitudinal cohort (Mann-Whitney  $p=0.3267$ ) or the cross-sectional

cohort (Mann-Whitney  $p=0.2967$ ). As a disease control, we recruited participants with Primary Sjögren's Syndrome. This group was chosen, as it represents a paradigm of aqueous deficient dry eye disease, in which there is fibrosis and destruction of the lacrimal gland. It is therefore similar to the dry eye disease associated with ocular GvHD, with the difference that in ocular GvHD, there is an underlying systemic T-cell mediated graft versus host response, thus potentially allowing a distinction between GVHD mediated ocular surface inflammation and aqueous deficiency ocular surface inflammation. Seven patients (10 eyes) with Sjögren's syndrome were recruited from the Sjögren's clinic at University Hospitals Birmingham NHS Trust. Six patients were female, this group was significantly older than the cross-sectional cohort (Mann-Whitney  $p=0.0002$ ) with a median age of 65.5 years (range 59-75 years).

## **Results**

### **Characteristics of Participants**

Of the five recruited participants, one participant was female and all participants were white. The mean age of the participants was 49 years old (range 34-68 years). The original indication for HSCT was leukaemia in all patients; acute myeloid leukaemia in two participants, chronic lymphoid leukaemia in two participants, and acute lymphoblastic leukaemia in one participant.

## **Clinical Features**

The vision was normal for all patients at baseline and remained better than 0.2 logMAR (6/9 Snellen equivalent) at all post-transplant visits.

All patients, were asymptomatic of ocular disease at baseline and follow up visits, with an OSDI score of < 12 for all patients at all visits.

## **Clinical Signs of dry eye**

The eyes of all participants were healthy at baseline, and none of the 5 patients developed significant signs or symptoms of ocular disease.

Details of the clinical features are shown in Table 10. At baseline, one patient had evidence of corneal staining with a modified Oxford score of 19 there was no corneal staining at baseline in the remaining patients and at subsequent visits, no patients developed significant ocular surface staining.

At baseline, 2 eyes of one patient had a Schirmer's score of  $\leq 10$ mm in 5 mins; at all subsequent visits all eyes of all patients had a normal Schirmer's score ( $\geq 10$ mm in 5 minutes).

	<b>Baseline</b>	<b>1 Month</b>	<b>3 Months</b>	<b>6 Months</b>	<b>12 Months</b>
<b>Normal Schirmer's' (<math>\geq</math> 10mm in 5 mins)</b>	8/10	8/8	3/3	4/4	4/4
<b>Median and range Oxford Staining Score (averaged between two eyes)</b>	0.25 (0-19.5)	1 (0-16.5)	0 (0-2)	1.25 (0-3)	3 (0-7.5)
<b>OSDI (number of eyes)</b>	3.6 (n=5)	4.9 (n=3)	N/A	6.25 (n=4)	6.8
<b>Average Osmolarity (mOsm/l)</b>	305.5	301.1	317.5	315.5	302.5 (n=4)
<b>Number &lt;316mOsm/l <sup>185</sup></b>	1/6	1/10	1/2	4/8	0/2
<b>Marx line (Yamaguchi score)</b>	3.7	2.75	2.5	1.75	2.375

**Table 10 Dry Eye Characteristics of the longitudinal cohort.**

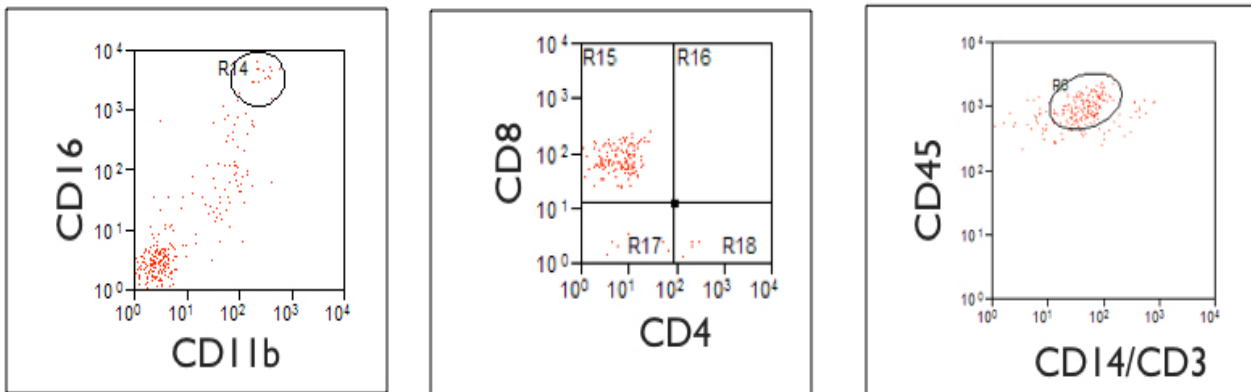
At baseline, unanaesthetised Schirmer's score was normal ( $\geq 10\text{mm}$  in 5 mins) in 8/10 eyes and was normal in all subsequent visits for all eyes.

There was no change in the position of Marx's Line over the one-year period.

The mean Yamaguchi score at baseline, 1 month, 3 months, 6 months, and 12 months were 3.7, 2.25, 1.75 and 2.375 respectively.

### Resident Conjunctival Leukocyte Population

In healthy volunteers, there were very few resident leukocytes in the conjunctiva (Figure 21), with the predominant cells being CD8+ lymphocytes as has been previously described.<sup>33,109</sup>



**Figure 21** Representative Flow Cytometry Data from the conjunctiva of a healthy volunteer after gating as previously described. A shows Neutrophils (CD16+/CD11b+). B shows CD8+ and CD4+ lymphocytes. C shows macrophages (CD45+ and CD14+) cells, note this is subsequently backgated onto FS and SS to exclude lymphocytes (CD3+) cells which shared the same fluorochromes as CD14.



## Reconstitution of Myeloid Derived Cells in the Blood and Conjunctiva

Reconstitution of myeloid derived cells, in both the blood and the conjunctiva is shown in Figure 22. Before HSCT, at baseline, the numbers of myeloid derived cells in the blood **and** conjunctiva were not significantly different to those in healthy volunteers, with no significant difference in the number of monocytes, NK cells or neutrophils when compared to healthy volunteers. Following HSCT, at one month post-transplant, the numbers of monocytes, neutrophils and NK cells fall, in the blood, with significantly lower number of monocytes ( $p=0.0159$ ), NK cells ( $p=0.0317$ ) and a trend to reduced neutrophils ( $p=0.11$ ) in the blood when compared to baseline. At 3 months, the numbers of these cells have returned to baseline, with no significant difference in the numbers of monocytes, neutrophils or NK cells; and there remains no significant difference in the numbers of myeloid derived cells at the 12-month time point. In the conjunctiva, however, there is *no significant change* in the numbers of macrophages, neutrophils or NK cells at one-month and there remains no difference at the 3-month and 12-month time points.

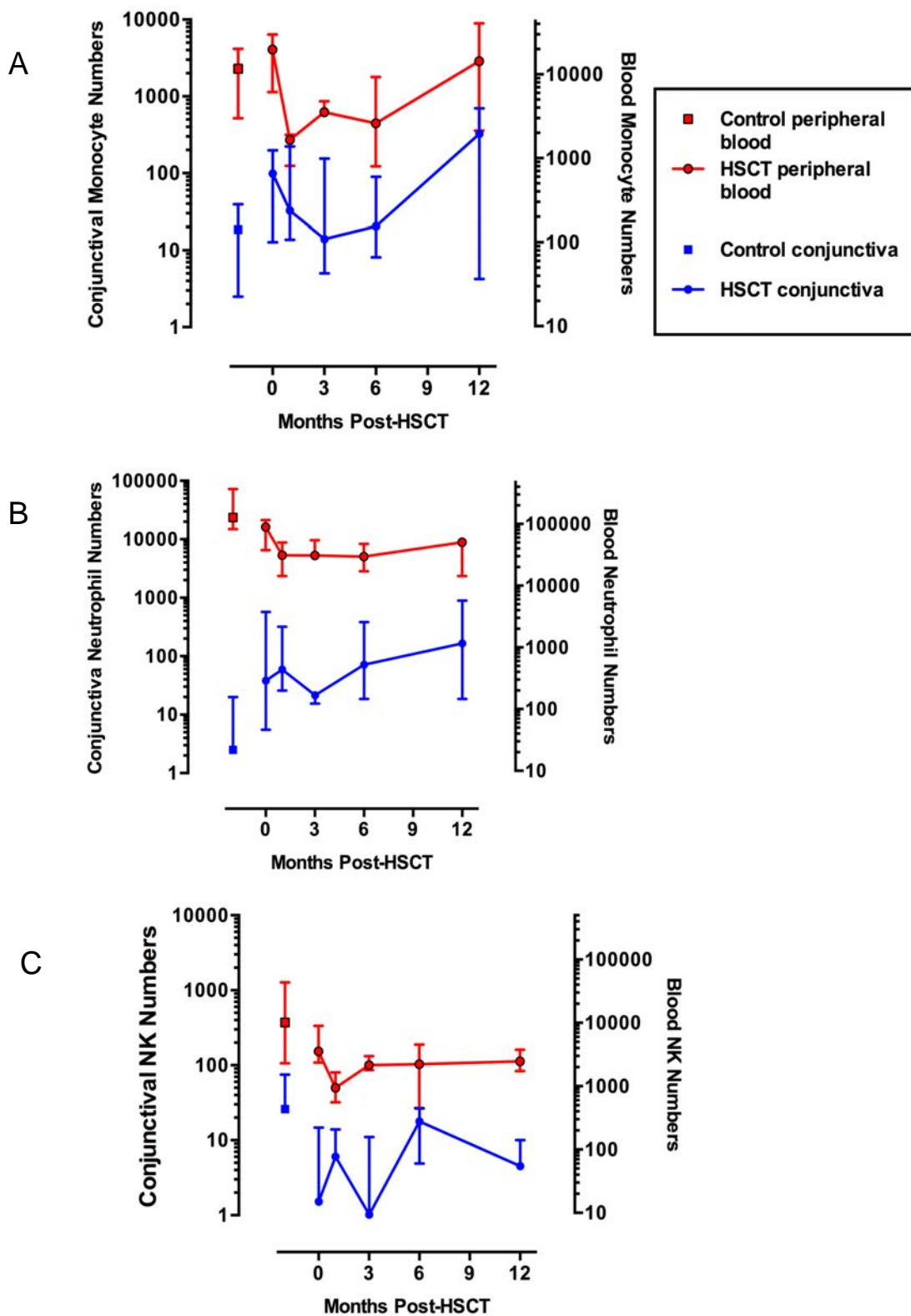
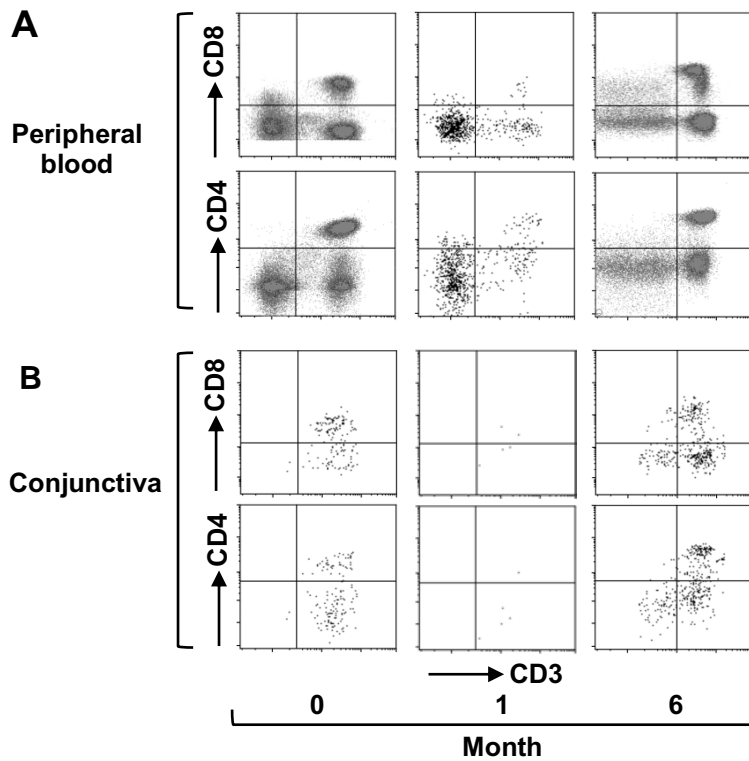


Figure 22 Reconstitution of Myeloid Derived Cells in lysed blood and conjunctiva showing the median and interquartile range of cell numbers. A. Monocytes B. Neutrophils, and C NK cells. Note significant fall in the number of Monocytes and NK cells and a trend to reduced neutrophils whilst there is no significant change in the

## Reconstitution of Lymphocytes in the Blood and Conjunctiva

When compared to healthy volunteers, there was no significant difference in the number of CD4+, CD8+ or NKT cells in the blood or conjunctiva at baseline.

Representative flow cytometry data of conjunctival lymphocytes at baseline, 1 month and 6 months is shown in Figure 23 .



**Figure 23** Representative Flow cytometry plot of a single patient. **A** Peripheral blood. Demonstrating high levels of CD4 and CD8 cells at baseline, with a marked reduction in cell numbers at one month post-transplant, with cell numbers returning to normal at 6 month post-transplant. This picture is mirrored in the conjunctiva in **B** with almost complete depletion of CD4 and CD8 lymphocytes in the conjunctiva at 3 months post-transplant, and cell numbers returning to normal at 6 months post-transplant.

The changes in the numbers of lymphoid cells in the both the blood and the conjunctiva following HSCT and in healthy volunteers is shown in Figure 24. Following conditioning and HSCT, there is a fall in the number of lymphocytes found in the blood, with significantly lower CD4+ cells ( $p=0.0195$ ), CD8+ cells ( $p=0.0159$ ) and NKT cells ( $p=0.0159$ ) at one month compared to baseline. The number of CD4+ and CD8+ cells remains low at 3 months when compared to baseline ( $p=0.0357$ ), but the number of NKT cells has returned to baseline. At six months, there is no significant difference in the number of CD4+ and CD8+ cells when compared to baseline, although there is a trend to reduced CD4+ cells ( $p=0.011$ ).

In contrast to conjunctival myeloid derived cells, there is a fall in the number of conjunctival lymphocytes after HSCT, with significantly fewer conjunctival CD4+ ( $p=0.0211$ ) at 1 month, but not CD8+ or NKT cells. At the 3-month time-point, the number of conjunctival CD4+, CD8+ and NKT cells are significantly lower than at baseline ( $p=0.0029$ ,  $p=0.0005$  and  $p=0.0398$  respectively).

When the 12-month conjunctival leukocyte numbers are compared with healthy volunteers, we found significantly higher numbers of CD4+ lymphocytes ( $p=0.0263$ ) but not CD8+ lymphocytes and this resulted in a significant change in the CD8+/CD4+ ratio ( $p=0.012$ ).

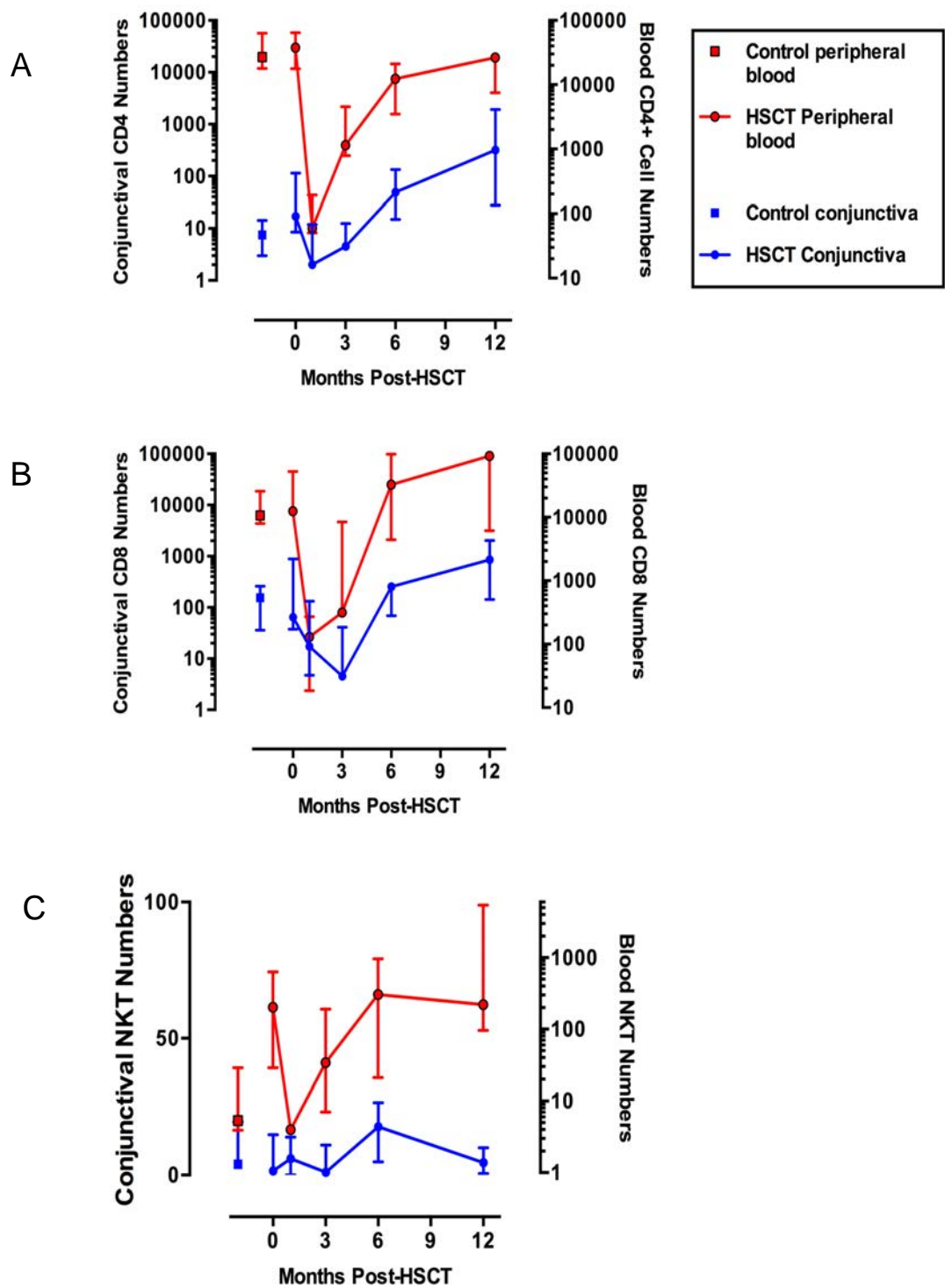
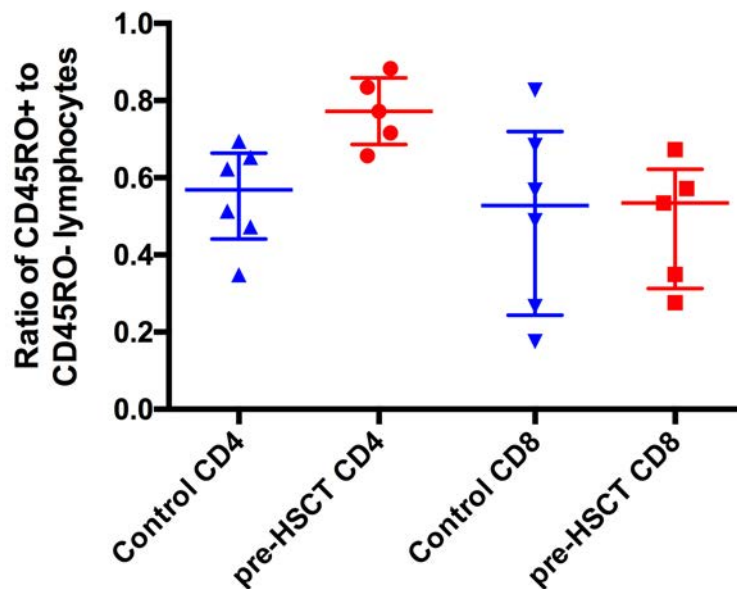


Figure 24 Reconstitution of Lymphoid Cells in lysed blood and conjunctiva showing the median and interquartile range of cell numbers. A. CD4+ Lymphocytes B. CD8+ lymphocytes, and C NKT cells. Note that there is a fall in the number of lymphocytes in the blood, but in contrast to the myeloid derived cells, there is a corresponding fall in the number of CD4+, CD8+ and NKT Lymphocytes.

In order to look at these lymphocyte populations in more detail, we then looked at the CD45RO marker, which is not expressed by naïve T-cells. Comparing the expression of CD45RO+ in CD4+ lymphocytes and CD8+ lymphocytes in patients undergoing HSCT and healthy volunteers. Figure 25 shows the median proportion of CD45RO+ CD4+ and CD45RO+CD8+ lymphocytes in the blood in patients before HSCT and in healthy volunteers. We found significantly higher percentage of CD4+CD45RO+ in pre-HSCT patients when compared to healthy volunteers.



**Figure 25 Comparison of the median and range of the ratio of blood CD4 and CD8 lymphocytes that express CD45RO in patients pre-HSCT and healthy volunteers. Note there are significantly more CD45RO+/CD4+ cells in the blood of patients before HSCT and healthy volunteers.**

Figure 26 shows the median numbers of CD4+/CD45RO+ and CD8+/CD45RO+ cells in the conjunctiva in both post-HSCT patients and healthy volunteers.

After HSCT, there is a significant increase in the percentage of CD4+/CD45RO+ cells ( $p=0.0095$ ) and CD8+/CD45RO+ cells ( $p=0.0190$ ). At 12 months, the number of both CD4+/CD45RO+ and CD8+/CD45RO+ cells were no different to baseline ( $p=0.931$  and  $0.792$  respectively).

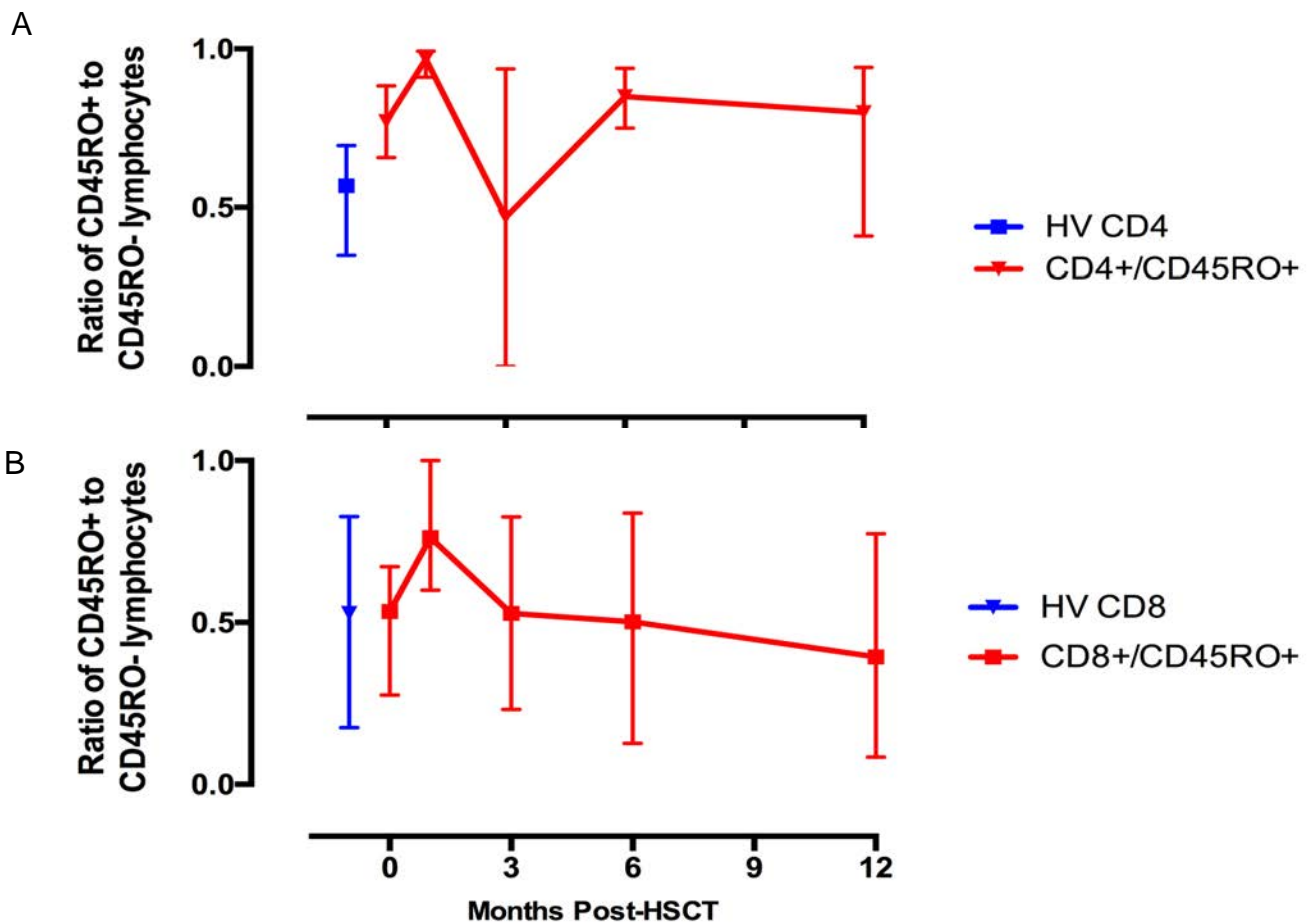


Figure 26 Median and range of the ratio of CD45RO+ and - lymphocytes in the conjunctiva A CD4+ cell and B CD8+ cells for healthy volunteers (blue) and post-HSCT patients (red) shown changing over time post-transplant.

At baseline, almost all the conjunctival CD4+ and CD8+ cells express CD45RO+. Immediately following the transplant, the CD45RO percentage of CD4+CD45RO+ cells remains high, but starts to fall, with a higher percentage of both CD4+ and CD8+ not expressing CD45RO. The number of CD4+CD45RO+ cells was significantly lower at 12 months than at baseline ( $p=0.0133$ ), there was a trend to a reduced number of CD8+CD45RO+ cells, but this did not reach statistical significance.

## **Discussion**

### ***Lymphocyte Reconstitution***

As would be expected, following myeloablation, there is a rapid reduction in the number of both blood lymphocytes and resident conjunctival lymphocytes. As previously discussed, the T-Cells in the blood take many months to return to the pre-transplant numbers, and this was indeed the case in our cohort, with both CD4+and CD8+lymphocyte numbers falling in both the blood and the conjunctiva. In the conjunctiva, there is a fall in the T-cell numbers, with CD4+cells low at 1 month, and both CD4+and CD8+cells significantly low at 3 months when compared to baseline. The reason that CD8+cells are not significantly lower at the 1-month time point in the conjunctiva could be that the alemtuzumab failed to deplete resident CD8+cells. In patients with Cutaneous T Cell Lymphomas, alemtuzumab is used to deplete the cancerous T-cells. It has been shown that resident T<sub>EM</sub> cells, both CD4+and CD8+(but not recirculating cells) can survive the alemtuzumab. <sup>186</sup> The majority of conjunctival CD8+cells



demonstrate mucosal homing markers and are likely to be tissue resident, until being lost from the conjunctival surface.<sup>99</sup>, however it is feasible that a smaller subset of conjunctival CD8+cells are able to survive alemtuzumab, and there is a marked trend for reduced CD8+cells post-transplant, suggesting that the majority of CD8+cells were depleted by the alemtuzumab.

As discussed above, the reconstitution of T-cells follows a biphasic pattern, with initial expansion of donor-derived mature T-cells and subsequent thymic maturation and expansion of transplanted naïve T-cells. Before and immediately after conditioning and HSCT, the majority of T-cells in the conjunctiva are experienced, memory T-cells. In the first month following transplant, the majority of both CD4+and CD8+cells are CD45RO+ suggesting an effector memory phenotype. These cells likely represent the first 'phase' of reconstitution, the expansion of transplanted mature T-cells. At later time points the proportion of conjunctival, but not blood, CD45RO-lymphocytes increases. We propose that these cells represent the second 'phase' of constitution, expansion of naïve T-cells. Even in the absence of clinical disease or signs of inflammation, there is a significantly increased number of CD4+cells in the conjunctiva when post-HSCT patients, at the 12-month point, are compared to healthy volunteers. At this timepoint, there is a significantly reduced number of CD4+CD45RO+ cells, conjunctiva and the numbers of CD45RO+ cells in the blood is not significantly different to baseline; suggesting the increase is due to migration of naïve CD4+T-cells into the conjunctiva. Naïve T-cells circulate through secondary lymphoid organs and so their presence in the peripheral

tissue is unexpected. There are three possible reasons for this. Firstly, although the majority of CD4<sup>+</sup> cells pre-HSCT were CD45RO<sup>+</sup>; following transplant and reconstitution a higher proportion of conjunctival CD4<sup>+</sup>T-cells are now 'revertant' (T<sub>EMRA</sub>) and fail to express CD45RO. Without knowing whether these cells express CCR7, it is not possible to say these cells are truly naïve.

Secondly, it could be possible that there is sub-clinical inflammation in the conjunctiva. although the numbers of innate immune cells in the conjunctiva at 12 months is no different in post-HSCT patients and healthy volunteers. Finally, it could be that there is recirculation or trafficking of naïve T-cells though the conjunctiva. The view that naïve T-cells are confined to secondary lymphoid tissues and do not enter peripheral tissue has been questioned<sup>187</sup> and it has been shown in mouse models, that there is a small but significant number of naïve T-cells can be found in non-lymphoid tissue <sup>188</sup> and it has been shown that there are small numbers of naïve T-cells in the human conjunctiva especially in the context of dry eye disease.<sup>101</sup>

### ***Myeloid Derived Cell Reconstitution***

Whilst numbers of monocytes fall rapidly after conditioning, the numbers in the blood return to normal within 3 months. In contrast, in the conjunctiva, there is no significant change in the number of macrophages before or after conditioning and HSCT. Using a mouse model of HSCT, Kennedy et al<sup>189</sup> found that macrophage reconstitution occurs at different rates in different tissues; splenic macrophages are 89% donor-derived at one month, whereas at two months, alveolar macrophages were only 61% donor derived. This is consistent

with our findings that post-transplant macrophage numbers are no different to baseline. Unfortunately, we were not able to differentiate between host and donor-derived cells. Haniffa et al<sup>190</sup> examined pre and post-conditioning skin shave biopsies and found skin resident macrophages survived conditioning, but the number of dendritic cells falls. This means that we are not able to determine whether there are any changes in the macrophage populations over time, as any reconstitution changes might be masked by survival of the host-derived resident macrophages.

Neutrophils also fall rapidly in the blood following conditioning, but the levels at 1 month are not significantly lower than at baseline. Neutrophils are the first leukocytes to reconstitute returning to normal levels after 11-14 days.<sup>22</sup> and so it is likely that the reason is that neutrophils are have reconstituted by the 1 month time-point. Similarly, there is no change in the numbers of neutrophils in the conjunctiva, again, this is likely because by the one month time point, they have already reconstituted.

NK cells also reconstitute in the blood early on after conditioning following transplantation, and normal NK cell levels can be expected in the first month.<sup>191</sup> Post-HSCT, donor NK cells play an important role in the GVT response and it has been demonstrated in vitro, that donor-derived NK cells can lyse tumour cells.<sup>192</sup> Furthermore, NK cells can inhibit T-cell activation and ameliorate GVHD.<sup>193</sup> In our patients, T-cell depletion was performed pre-HSCT, and different methods of T-cell depletion has been shown to affect the kinetics of NK

reconstitution.<sup>194</sup>, additionally systemic immunosuppression may affect NK reconstitution independently of T-cell depletion.<sup>195</sup> Nevertheless, it is not clear why the numbers of NK cells in the blood is low in our patients at the one month timepoint.

## Chapter 4 Cross-Sectional Cohort

### Patient Recruitment

A cross-sectional cohort of patients was also recruited from the haematology clinics at the Centre for Clinical Haematology at the Queen Elizabeth hospital. Patients who had undergone HSCT were recruited, including patients with and without systemic or ocular GvHD. Patients were excluded if they had any history of ocular disease pre-dating HSCT.

Patients were seen for a single visit, where clinical assessment and sampling were performed as previously discussed.

### Results

A total of 29 patients were recruited. 11/29 (40%) of patients were female, the average age was 50 years old (range 21-66 years). The majority of patients were White (26/29) with the remaining patients Asian (3/29). The average time patients were seen post-HSCT was 235 days (range 94-876 days). Patient demographics and transplant conditioning regimen are shown in Table 11 The original indications for HSCT are shown in Table 11.

<b>Age</b>	Average Age	50
	Range	21-66
<b>Gender</b>	Female	11
	Male	18
<b>Ethnicity</b>	White British	26
	Asian Pakistani	1
	Asian Bangladeshi	1
	Asian Other	1
<b>Indication for Transplant</b>	Acute Myeloid Leukemia	12 (41%)
	Acute Lymphoblastic Leukaemia	5 (17%)
	MDS	3 (10%)
	Chronic Lymphoid Leukaemia	2 (7%)
	Anaplastic Anaemia	2 (7%)
	Chronic Myeloid Leukaemia	1 (3%)
	Follicular Lymphoma	1 (3%)
	Hodgkin's Lymphoma	1 (3%)
	Non-Hodgkin's Lymphoma	1 (3%)
	Probable T-cell Prolymphocytic Leukaemia	1 (3%)
<b>Conditioning</b>	Fludarabine/Melphalan/Campath	19
	Cyclophosphamide/TBI	6
	Cyclophosphamide/TBI/Fludarabine	1
	BEAM/Campath	1
	Bisulphan/Cyclophosphamide	1
	FLAMSA/Bu	1
	Reduced Intensity	4
<b>Donor</b>	Sibling	15
	Unrelated	14
<b>Transplant Source</b>	Peripheral Stem Cell	21 (70%)
	Bone Marrow	7 (24%)
	Cord Blood	1 (3%)
<b>Chronic GvHD</b>	Nil	7
	Mild	10
	Moderate	10
	Severe	2

Table 11 Cross-sectional cohort patient demographics, conditioning, and HSCT details.

## Ocular GvHD and Dry Eye Disease

To assess the patient's symptoms of dry eye disease, the NIH ocular severity scale and the OSDI were used and the results are shown in Table 12. The weighted kappa when comparing the NIH severity scale and OSDI was 0.030 indicating a poor relationship.

NIH Severity Score	n=29
0	17
1	9
2	2
3	1
OSDI (0-100)	n=23
Average (range)	18 (0-66)
Nil (<12)	11
Mild (12-22)	6
Moderate (23-32)	3
Severe (33-100)	3

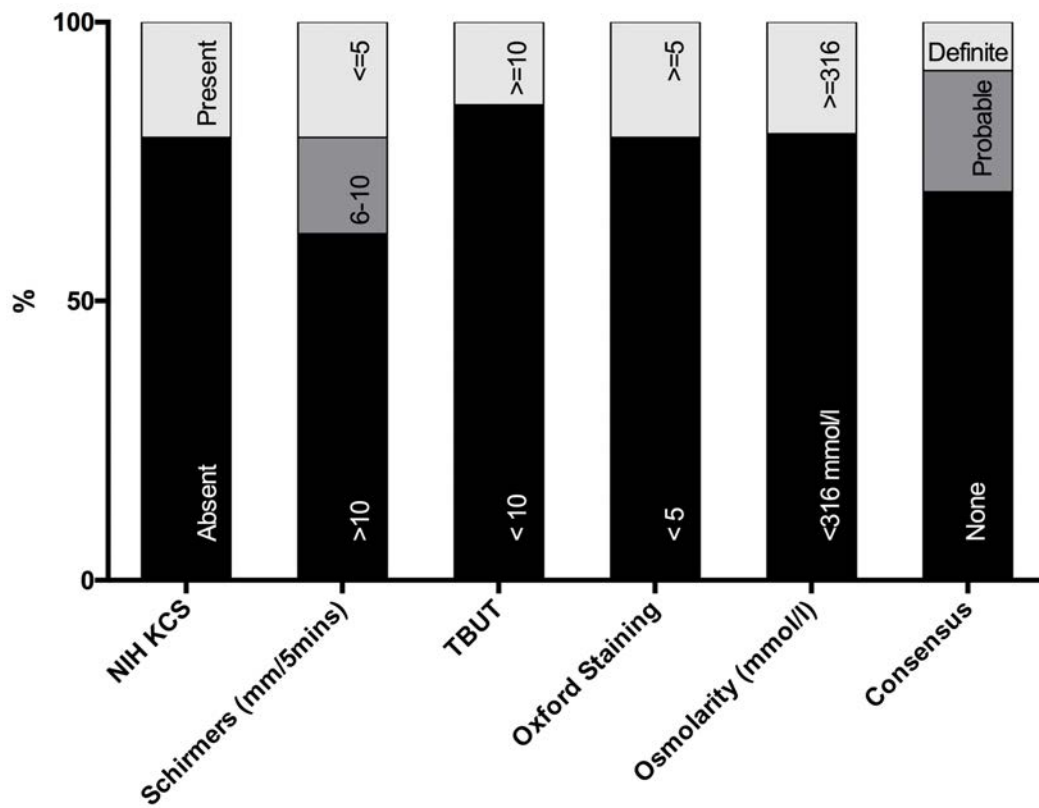
**Table 12 NIH Ocular GvHD Severity Score and Dry Eye Symptom Score (OSDI) in Cross-Sectional Cohort of post-HSCT patients. These two scores describe the symptoms of patients with dry eye related disease.**

<b>NIH New Onset KCS</b>	<b>n=29</b>
Present	6
Absent	23
<b>Unanaesthetised Schirmer's Score (Average of two eyes)</b>	<b>n=29</b>
Average (range)	15 (0-36)
Schirmer's ≤5mm/5mins	6
Schirmer's 6-10mm/5mins	5
Schirmer's >10mm/5mins	18
<b>Tear Break Up Time (TBUT) (Average of two eyes)</b>	<b>n=27</b>
Average (range)	6 seconds (0-20)
TBUT <10	23
TBUT ≥10	4
<b>Modified Oxford Corneal Grading Score (Average of two eyes)</b>	<b>n=29</b>
Average (range)	7 (0-80)
<5	23
≥5	6
<b>Osmolarity (Average of two eyes)</b>	<b>n=20</b>
Average (range)	303.5 (286-325)
Osmolarity >316	16
Osmolarity ≤316	4

**Table 13 Clinical signs of Ocular GvHD and Dry Eye Disease in Cross-Sectional Cohort of post-HSCT patients.**



The diagnosis and severity of ocular GvHD and /or dry eye disease were assessed with a number of methods; the NIH severity score, Schirmer's score, TBUT, Modified Oxford scale of corneal staining and the tear film osmolarity. The numbers of patients fulfilling each clinical parameter are shown in Table 13. The proportion of patients reported as having ocular GvHD or dry eye disease using each test or grading criteria are shown for comparison in Figure 27.



**Figure 27 Proportions of patients post-HSCT showing evidence of ocular GVHD/dry eye disease with each clinical test or scoring criteria.**

The International Consensus Group proposed diagnostic criteria for Ocular GvHD<sup>2</sup> combines different clinical signs seen in ocular GvHD as well as the presence of GvHD in other organs, the results are shown in Table 14. The

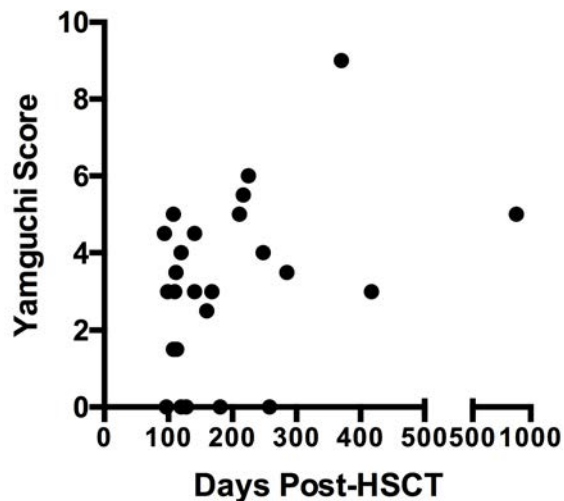
weighted Kappa comparing the NIH criteria and the proposed diagnostic criteria was 0.519 indicating the strength of agreement is 'fair'.

International Chronic (GvHD) Consensus Group Diagnostic Criteria n=23	
Definite [ocular GvHD]	2
Probable [ocular GvHD]	5
None [ocular GvHD]	16

**Table 14 International Consensus Group, proposed diagnostic criteria for ocular GvHD.**

### **Cicatricial Lid Features**

Cicatricial changes to the lid margin were assessed, in 25/29 patients, using Yamaguchi's scale to describe a posterior migration of Marx's line.<sup>9</sup> The average Yamaguchi score for right and left eyes was 3.2 (SD 2.4 right and 2.2 left). There was a positive correlation between the time post-HSCT and the Yamaguchi scale (Pearson  $p=0.0494$   $r=0.3376$ ) indicating that the further in time from transplant, the more posterior migration of the meibomian gland orifices (Figure 28).



**Figure 28 Scatter plot of time post-HSCT in days and Yamaguchi scale (averaged right and left eye)**

The majority of eyes (43/58) did not show evidence of subconjunctival fibrosis using Robinson’s grading system; 12/58 eyes had Grade 1 fibrosis and 3/58 eyes had Grade 2 fibrosis. There was a trend to increased Robinson’s Grade and the number of days post-transplant, but this did not reach statistical significance ( $p=0.0553$  Kruskal-Wallis).

### **Conjunctival Leukocyte Populations and Ocular GvHD**

Table 15 shows the median cell numbers and interquartile range for each cell type in all post-HSCT patients, post-HSCT patients with new onset KCS, post-HSCT patients without new onset KCS, healthy volunteers and patient with Sjögren’s Syndrome. These data are graphically displayed in Figure 29 and Figure 30. Post-HSCT patients with new onset KCS were found to have significantly higher number of CD8+ cells ( $p=0.04$ ), macrophages ( $p=0.0001$ ) and neutrophils ( $p=0.035$ ) when compared to post-HSCT patients without new onset KCS. The percentage of CD8+/CD45RO+ cells was not significantly

higher in patients with KCS and without KCS. There was no significant difference in the number of CD4+ cells, NKT cells or NK cells.

	All Post HSCT (n=58)	New Onset KC (n=12)	No KCS (n=26)	Healthy Volunteers (n=9)	Sjögren's Syndrome (n=10)
CD4	54 (106)	56 (91)	54 (115)	4 (20)	235 (431)
CD8	194 (488)	557 (214)	84 (350)	137 (367)	201 (431)
NKT	5 (7.5)	14 (30)	5 (8)	3(2)	11(16)
Macrophages	143 (350)	663 (360)	109 (188)	12 (75)	49 (111)
NK Cells	97 (108)	91 (96)	97 (97)	6 (20)	71 (295)
Neutrophils	78 (381)	190 (2420)	46 (245)	7(59)	174 (456)

**Table 15 Median cell numbers and interquartile range for each conjunctival leukocyte population in all post-HSCT patients, post-HSCT patients with and without new onset KCS, healthy volunteers and patients with Sjögren's syndrome.**

-

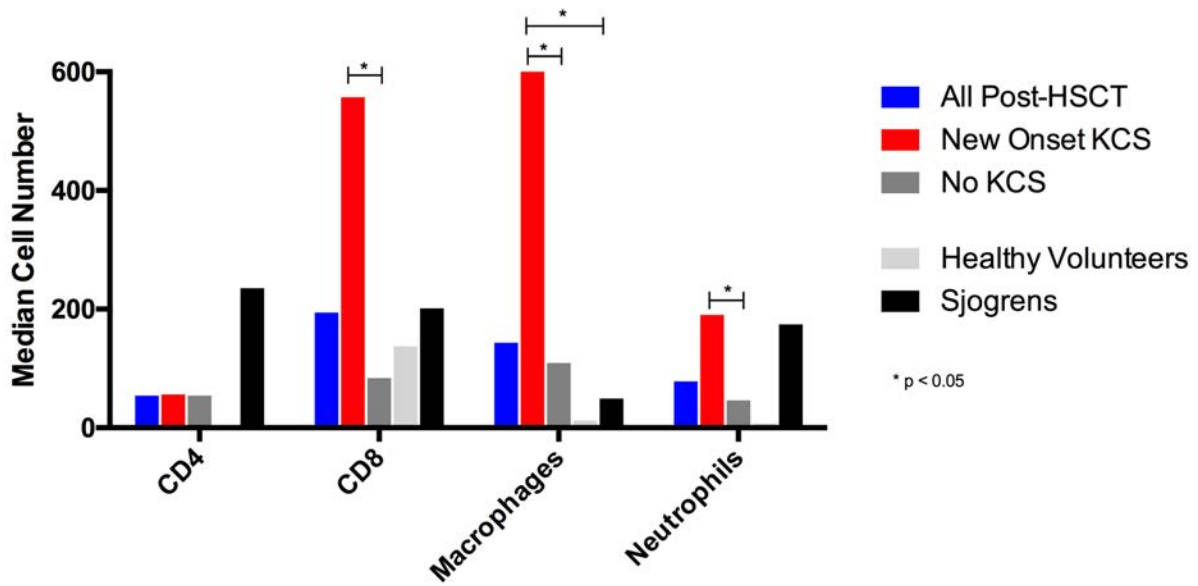


Figure 29 Conjunctival CD4+, CD8+, Macrophages, and Neutrophils in all patients post-HSCT, post-HSCT patients with new onset KCS, post-HSCT patients without new onset KCS, healthy volunteers and Sjögren’s patients. Note significantly increased CD8+, macrophages, and neutrophils in post-HSCT patients with new onset KCS, compared to those without; and increased numbers of macrophages in patients with post-HSCT new onset KCS when compared to patients with Sjögren’s syndrome.

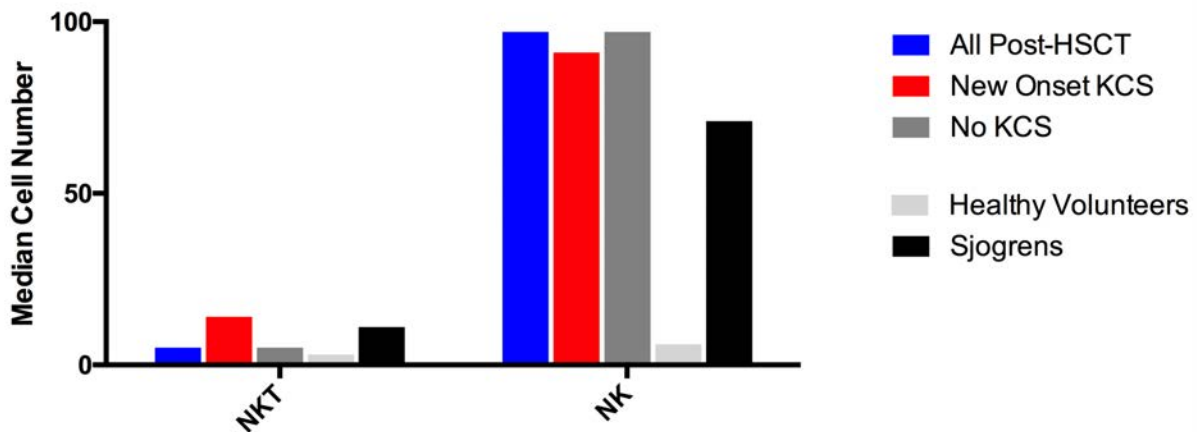


Figure 30 Conjunctival NK T-Cells and NK cells in all patients post-HSCT, post-HSCT patients with new onset KCS, post-HSCT patients without new onset KCS, healthy volunteers and Sjögren's patients.

#### Post-HSCT new onset KCS and comparison with healthy volunteers and patients with Sjögren's Syndrome

Table 16 shows Mann-Whitney results comparing the conjunctival leukocyte populations in all patients post-HSCT (with and without new onset KCS) compared with both healthy volunteers and patients with Sjögren's Syndrome. When compared to healthy volunteers, patients with post-HSCT new onset KCS have significantly *increased numbers of all leukocytes except for NKT cells*.

Despite, being a similar form of dry eyes disease, in Sjögren's syndrome there is increased numbers of macrophages in post-HSCT dry eye and the Aqueous Deficient Dry Eye Disease in Sjögren's Syndrome. Interestingly this difference was not limited to the post-HSCT patients with KCS; post-HSCT patients

*without* dry eye had increased number of macrophages, when compared to both healthy volunteers and patients with Sjögren's syndrome.

When the two control groups were compared; we found a trend to increased numbers of CD4+cells in the eyes with Sjogren's syndrome (p=0.06), and significantly increased neutrophils in the eyes with Sjogren's syndrome (p=0.02).

		Healthy Volunteers	Sjögren's Syndrome
All post-HSCT Patients	CD4+	NS (p=0.09)	NS
	CD8+	NS	NS
	NKT	NS	NS
	Macrophages	<b>p=0.047</b>	<b>p=0.0446</b>
	NK	<b>p=0.0038</b>	NS
	Neutrophils	<b>p=0.0079</b>	NS
Post-HSCT New Onset KCS (Dry Eyes)	CD4+	<b>p=0.0455</b>	NS (p=0.10)
	CD8+	<b>p=0.0260</b>	NS (p=0.10)
	NKT	NS	NS
	Macrophages	<b>p=0.0022</b>	<b>p=0.023</b>
	NK	<b>p=0.036</b>	NS
	Neutrophils	<b>p=0.0022</b>	NS
Post-HSCT No New Onset KCS (Wet Eyes)	CD4+	NS	NS
	CD8+	NS	NS
	NKT	NS	NS
	Macrophages	<b>p=0.0161</b>	<b>p=0.1471</b>
	NK	NS	NS
	Neutrophils	NS	NS

**Table 16 Comparison of conjunctival leukocyte populations in patients post-HSCT with healthy volunteers and Sjogren's Syndrome patients. Shaded cells demonstrate where the difference between the post-HSCT group and the control groups are significantly higher, or where there is a trend to higher numbers in the post-HSCT group.**

### **Lysed Blood Leukocyte populations and Ocular GvHD**

We found no significant differences in the numbers of leukocytes in patients with new-onset KCS and those without. (Appendix 3 Supplementary Data).

### **Source of Donor Cells, ocular GvHD and Conjunctival Leukocyte Populations**

A total of 15/29 HSCT were from siblings, and 14/29 HSCT were from unrelated donors. The number of patients with KCS was 3/15 in the sibling group and 3/14 in the unrelated group; chi-square testing did not show any significant difference between the two groups.

### **Systemic GvHD and Conjunctival Leukocyte Populations**

Table 17 shows the NIH classification of chronic GvHD in the cross-sectional cohort of patients. 21/29 patients had some form of GvHD; using the NIH classification, 1/29 patient had severe GvHD, 10/29 had moderate GvHD, 10/29 had mild GvHD and 8 patients had no evidence of GvHD. The breakdown of severity by system is shown in Table 18.



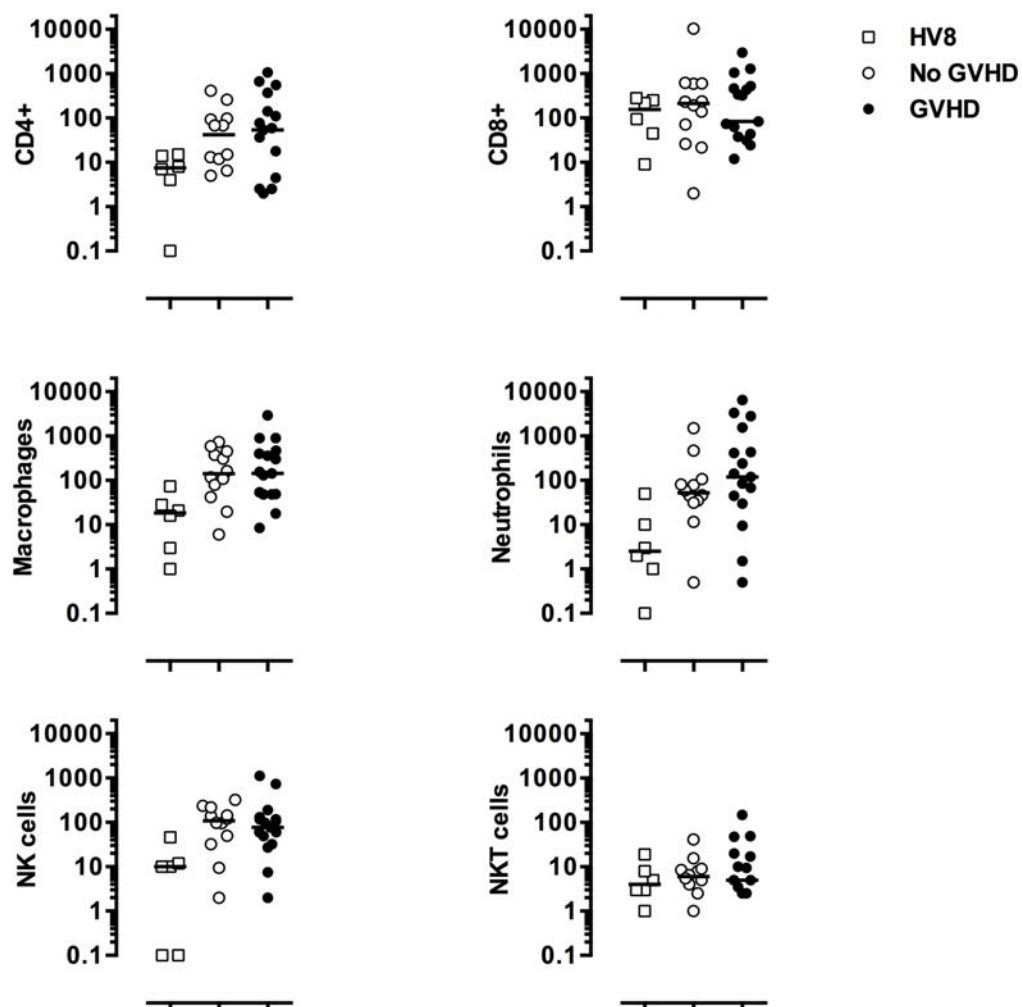
NIH GvHD Severity	Number of patients
None	8
Mild	10
Moderate	10
Severe	1

**Table 17** The severity of GvHD in the Cross-Sectional Cohort of patients using the NIH Classification of GvHD severity. The majority of patients had either mild or moderate GvHD.

Severity Score	0	1	2	3
<b>Performance Score</b>	24	5	0	0
<b>Skin</b>	19	6	3	1
<b>Mouth</b>	24	0	2	3
<b>Eyes</b>	17	9	2	1
<b>GI Tract</b>	28	0	1	0
<b>Liver</b>	28	0	1	0
<b>Lung</b>	25	4	0	0
<b>Joint/Fascia</b>	28	1	0	0
<b>Genital Tract</b>	29	0	0	0

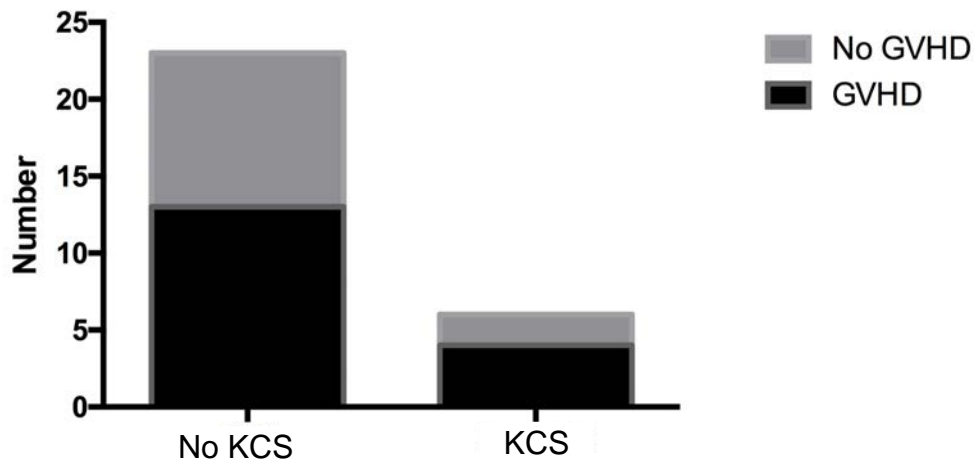
**Table 18** Further description of the NIH severity score for patients in the cross-sectional cohort (total n=29), describing the NIH GvHD severity score (0-3) for each affected system.

In order to look into whether conjunctival leukocyte numbers were altered in patients with systemic GvHD, we excluded the ocular component from the global score and then divided the cohort into patients with and without any evidence of systemic cGvHD. There was *no significant difference* in the conjunctival leukocyte numbers when patients with systemic GvHD were compared with patients without systemic GvHD. These data are shown in Figure 31.



**Figure 31 Conjunctival Leukocytes populations in Healthy Volunteers, and post-HSCT patients with and without systemic GVHD (excluding ocular GVHD). Note there is no significant difference in the number of any of the populations examined in patients with systemic GVHD and without systemic GVHD.**

Figure 32 shows the GvHD status of patients and whether they had evidence of GvHD in any other organ. Whilst a higher percentage of patients (4/6 67%) with new onset KCS had evidence of GvHD in other organs, when compared to patients without new onset KCS (13/23 57%); this did not reach statistical significance (using Fisher's Exact test).



**Figure 32 Graph to show the numbers of patients with and without KCS and evidence of GVHD in any other organ. There was no significant difference between the numbers of patients with KCS in patients with or without systemic GvHD.**

## Conclusions

### Scoring Scales and Diagnostic Criteria

The prevalence of ocular GvHD varied in our cohort depending on the diagnostic criteria used. With a prevalence varying from 6/29 (21%) using the NIH new-onset KCS criteria, to 12/29 (41%) using the NIH severity criteria and 7/23 (30%) using the International consensus proposed diagnostic criteria.

This variation in the number of patients highlights the difficulty in diagnosing ocular GvHD and the difficulty in grading the disease. The controversy

surrounding the different scoring systems for ocular GvHD are discussed in above. Despite being a very simple useable by any clinician, the NIH score has been shown to compare well with other dry eye scales. <sup>62,63</sup>. Despite this, in our cohort, the Kappa score did not show a strong relationship between OSDI and the NIH score. This is surprising as the OSDI depends on patient reported symptoms and the NIH grading is heavily based on patient symptoms but could be explained by small numbers of patients with severe disease. In our cohort, the relationship between Schirmer's score, a clinical sign, and the NIH grading score was 'fair'. Schirmer's score is an uncomfortable and time-consuming process; the NIH score, would therefore be a preferred option in haematology clinics to screen patients.

A clinical grading scheme can have a number of purposes, for example, as a screening tool, to identify those patients who may need referral to a specialist, or as a severity tool to identify those patients who may need a change to treatment. The setting is also important to consider. A very detailed tool may be appropriate when administered for research purpose, but may not be useful in a busy clinical situation. Finally, it is important to include the patient's own experience in assessing the severity of the condition, especially in a disease such as dry eye, where there is often a disparity between the severity of symptoms and signs. There is evidence that patients following HSCT are reticent to seek help for their eyes,<sup>127</sup> and may suffer a reduced quality of life as a result,<sup>135</sup> Use of the NIH severity scale allows the patient to express their symptoms, to allow the clinician to detect a change in the severity of the ocular

disease so as to direct ophthalmological referral, and finally use of the NIH ocular scale is an integral factor in assessing the overall effect of all GvHD status of the patient. Our data corroborates the published literature on the use of the NIH grading scheme in the haematology clinic.

Although our data was limited, we did find a 'moderate' strength relationship between the NIH criteria and the proposed criteria, supporting the use of the new criteria in the clinical setting. It must be pointed out that, as it is more detailed, the consensus criteria would require a suitably trained and experienced examiner, and specialist equipment, namely a slit-lamp biomicroscope. This would make routine use in non-ophthalmology clinics more difficult and possibly not feasible. Nevertheless, this scale uses predominantly clinical signs, being a more detailed scale, the proposed International criteria is also capable of providing a numerical value, and this might provide a degree of granularity that would be more useful in a research setting.

The proposed International consensus diagnostic criteria include whether there is evidence of systemic cGvHD (Table 4); two factors from our cohort would question this. Firstly, although more patients with new onset KCS had systemic cGvHD, this did not reach statistical significance. Secondly, we did not show any difference in the conjunctival leukocyte population in patients with and without systemic cGvHD. Finding a number of patients with dry eye disease without cGHVD is not inconsistent with the literature, as although the majority of published cohorts show ocular GvHD in patients is more with systemic

cGvHD, ocular GvHD without systemic GvHD is far from uncommon with number of studies report ocular GvHD in the absence of systemic cGvHD.

126,128-130,196 Use of this scale could potentially lead to underdiagnosis and the potential consequences of this to the patient should not be underestimated.

127,128,135 Whilst there is evidence to suggest patients with systemic cGvHD may have more severe disease<sup>196</sup>, due to the application to the proposed diagnostic criteria could lead to the situation whereby two patients with identical signs of ocular disease are classified differently, and treated differently.

### **Cicatrization and Ocular Surface Fibrosis following HSCT**

We found some evidence of increasing subconjunctival fibrosis in patients following HSCT, and this fibrosis was associated with time following transplantation. There was a trend to more subconjunctival fibrosis, using Robinson's classification, in patients who were further from their HSCT. Yamaguichi's score, describing the migration of Marx's line, a sign of cicatricial changes, was significantly higher in patients who were longer from their transplant. As described above, fibrosis is a feature of lacrimal gland GvHD, but cicatricial conjunctival changes are common to a number of ocular surface disease, including pSS.

### **Changes in the ocular surface leukocyte populations in patients with KCS post-HSCT.**

Which leukocyte populations were raised, depends very much on which population was used a control group. We have shown in Chapter 2 that the

resident conjunctival lymphocyte population of patients post-HSCT is not the same as that in healthy volunteers with increased CD4+ lymphocytes and an increase in the number of naïve T-cells, even in the absence of clinical disease. This highlights the importance of choosing an appropriate control group. When compared to post-HSCT patients without KCS, there are significantly higher numbers of CD8+ cells, macrophages and neutrophils. A limitation of our method was that we were unable to ascertain the origin of conjunctival leukocytes. As discussed above, in an animal model of ocular GvHD, Herretes *et al*<sup>197</sup> were able to demonstrate infiltrating T-cells were of donor origin.

### ***Lymphocytes***

#### **CD4+cells**

T-Cells have been heavily implicated in both animal models and human dry eye disease<sup>198</sup> and topical Ciclosporin, a T-cell suppressor, has been a mainstay of dry eye treatment for over a decade. In our cohort of patients with pSS, the majority of infiltrating lymphocytes are CD4+ cells and this is consistent with the published literature on Sjögren's syndrome.<sup>176</sup> Whilst the difference did not reach statistical significance, there was a trend to higher numbers of CD4+ cells in pSS when compared to both healthy volunteers (p=0,06) and post-HSCT with KCS (p=0.09). CD4+ cells have been heavily implicated in human dry eye disease<sup>176</sup> and the desiccating stress model of dry eye disease, with adoptive transfer of CD4+cells into T-cell depleted mice 'transferring' dry eye disease.<sup>177</sup> In our cohort of patients with GvHD related disease we found that



number of conjunctival CD<sup>+</sup> T-cells were similar to those in patients without dry eye disease and this suggests that the inflammatory process on the ocular surface of patient with dry eye disease related to GvHD is a **distinct process** to that occurring as a result of the aqueous deficiency state found in Sjögren's Syndrome.

### **CD8+Cells**

In the healthy human conjunctiva, the majority of CD8<sup>+</sup> cells are cytotoxic T<sub>EM</sub>.<sup>99</sup> CD8<sup>+</sup> T-cells have been shown in the conjunctiva of patients with ocular GvHD, by a number of authors<sup>94,140-142</sup> although using different methods, with some studies not employing double CD3<sup>+</sup> and CD8<sup>+</sup> staining and some using different control groups, such as healthy volunteers or autologous HSCT patients. In contrast, it has been shown in other ocular surface inflammatory conditions that CD8<sup>+</sup> T-cell numbers are *reduced*, for example ocular SJS<sup>199</sup> and ocular MMP<sup>200</sup>. It is important to note that CD8<sup>+</sup> cells may play a variety of roles in mucosal surfaces; with different populations of CD8<sup>+</sup> lymphocytes serving distinct functions. For example, regulatory CD8<sup>+</sup> cells have been demonstrated in a mouse model of pSS to mitigate the effects of Th17 cells in a mouse model of pSS<sup>201</sup> and a desiccating stress model of dry eye disease.<sup>198</sup> CD8<sup>+</sup> T-cells are also seen in oral cGvHD, where infiltrating CD8<sup>+</sup> lymphocytes have been demonstrated to be cytotoxic T<sub>EM</sub> and are closely associated with apoptotic keratinocytes.<sup>79</sup> In general, however, peripheral cGvHD is mediated by CD4<sup>+</sup> lymphocytes and other forms of GvHD are associated with a

predominant CD4+infiltrate; including intestinal GvHD<sup>91</sup>, pulmonary GvHD<sup>92</sup> and skin cGvHD. Nevertheless,  $\gamma\delta$  IEL CD8+cells have been shown in a mouse model of intestinal GvHD to be cytotoxic through a Fas-mediated pathway. It is likely that the CD8+cells we have demonstrated in the ocular surface may play a similar cytotoxic role.

### **Macrophages**

In a murine experimental model of dry eye disease, macrophage numbers were shown to be unchanged, but the phenotype was different, with a higher proportion of M1 macrophages to animals without dry eye. <sup>174</sup>. Nevertheless, a number of authors have demonstrated increased number of macrophages in dry eye disease.<sup>171 172 173</sup>

Macrophages have also been implicated in other conjunctival inflammatory diseases such as Mooren's ulcer<sup>202</sup>, vernal keratoconjunctivitis<sup>203,204</sup> and in the Chinese hamster model of acanthamoeba keratitis, activation of macrophages has been shown to improve the disease.<sup>205</sup>

We found significantly increased numbers of macrophages in the conjunctiva of patients with new onset KCS. Importantly, this was not only found when post-HSCT patients were compared with healthy controls, but also when compared to patient with pSS. It is important to note the varied possible function of monocytes; for example, Extracorporeal photophoresis, a treatment for GvHD, has been shown to increase the number of myeloid derived suppressor cells (MDSC) furthermore these MDSCs show the ability to suppress T-cells.<sup>206</sup> Little

is known about the possible roles of MDSC's in the eye, but they have been shown to suppress T-cells in murine models of corneal transplants.<sup>207</sup>

It has been shown in cutaneous GVHD that there are increased number of recipient derived macrophages in skin GvHD lesions.<sup>190</sup> In a mouse model of allergic conjunctivitis, it has been suggested, that conjunctival macrophages act as APCs.<sup>208</sup> Using a mouse model of ocular GvHD, Herretes et al reported increased macrophages in the conjunctiva<sup>5</sup> and speculated that macrophage T-cell interaction is critical to the process of ocular damage. Given our findings of increased macrophages, this would seem plausible, especially considering that in the pSS cohort, the macrophage numbers were significantly lower.

### ***Neutrophils***

An increased number of conjunctival neutrophils have been reported in a number of ocular surface inflammatory diseases, including dry eye disease<sup>209</sup>, infective conjunctivitis<sup>210</sup>, pseudomonas keratitis<sup>211</sup>, fungal keratitis<sup>212</sup>, Stevens-Johnson Syndrome<sup>199</sup>, ocular mucous membrane pemphigoid<sup>200</sup>, but also in animal models of corneal trauma<sup>213</sup> and systemic diseases including cystic fibrosis<sup>214</sup> and chronic smoking<sup>215</sup>. Neutrophils serve a number of immunological functions; in particular, as part of the innate immune system they play an important role the removal of pathogens through a number of mechanisms. One of these mechanisms, involves the secretion of extracellular DNA in the form of Neutrophil Extracellular Traps (NET).<sup>216</sup> Tibrewal et al<sup>217</sup> examined tear fluid from a mixed cohort of patient with dry eye disease,

including patients with ocular GvHD. They found increased levels of extracellular DNA in the tear film of patients with dry eye, and the highest levels found in the ocular GvHD cohort. Neutrophil function is not restricted to killing of pathogens however, (for a review see Scapini et al<sup>218</sup>) and there is significant cross-talk between neutrophils and other immune cells including lymphocytes. This relationship is predominantly a suppressive response<sup>219</sup>, but there is evidence that neutrophils can cross-present present antigens to CD8+ cells<sup>220</sup> and that through NETs, neutrophils can reduce the activation threshold of resting T-cells.<sup>221</sup>

Neutrophils are found in acute cutaneous GvHD<sup>69</sup> and liver GvHD<sup>222</sup> In a murine model of intestinal GvHD, Schwab et el reported on the role of neutrophils in intestinal GvHD.<sup>42</sup> They found that neutrophils did not accumulate in germ-free conditions, GvHD severity was reduced with depletion of neutrophils and in TLR deficient neutrophils. The ocular surface microbiome<sup>223</sup> may play a similar role in ocular GvHD.

In conclusion, in ocular GvHD, there is an inflammatory infiltrate composed of CD8, macrophages and neutrophils that is not present in patients post-HSCT who do not have ocular GvHD. Furthermore, this inflammation is distinct from the inflammation in aqueous deficient dry eye disease, suggesting that the inflammation is due to GvHD, rather than desiccating stress.

### ***Natural Killer Cells***

We found no significant difference in the number of NK cells in the conjunctiva of patients with new onset KCS, and those post-HSCT patients without KCS. When compared with healthy volunteers, however, there was an increased number of NK cells in post-HSCT KCS patients and all post-HSCT patients regardless of KCS. NK cells have a varied role in GvHD.<sup>224</sup>, with donor derived NK cells encourage engraftment and prevent GvHD through suppression of donor derived T-cells. <sup>193</sup>.

We also found an increased number of NK cells in the eyes of patient with pSS when compared to healthy volunteers, suggesting that the increased number of NK cells is due to aqueous deficiency rather than a GvHD response. Indeed NK cells have been implicated in the induction of dry eye disease, and the dry eye disease can be ameliorated in NK deficient mice. <sup>175</sup>

## Chapter 5 Summary of Thesis and Conclusions

### Clinical Grading of Ocular GVHD

Clinical scoring and diagnostic criteria of ocular GVHD is complicated by the fact there are a number of options. This complexity is bought about by the fact that different systems are needed in different situations for different purposes. A haematologist in clinic will need a quick, easy to use system that will allow the haematologist to determine whether the patient has symptoms that warrant referral to the ophthalmologist, as well as to allow them to fit the ocular symptoms into the context of the patient's overall clinical picture, and construct a global view of a patient's GvHD. To this end, in the most recent 2015 NIH Consensus guidelines for clinical trials<sup>60</sup>, the need for Schirmer's Score has been removed. For the ophthalmologist, more detailed systems may be use, so as to identify those patients in whom the disease is more aggressive and in whom, there is the risk of sight threatening disease. Finally any scoring system needs to be appropriate for the use of research, both clinical and basic science, to allow patients to be arranged into cohorts, but also to be stratified according to disease severity. Whilst we have demonstrated the pathophysiology is different to other autoimmune forms of dry eye disease, such as Sjögren's Syndrome, the clinical picture of ocular GVHD can be described with existing tools for dry eye disease, such as the DEWS II severity scale or the Ocular Staining Score<sup>225</sup>. Indeed, ophthalmologists may be familiar with their use in clinical practise and they have been validated in other ocular surface disease

such as Sjögren's syndrome<sup>226</sup>. In an effort to provide the ophthalmologist with a diagnostic tool, the International Consensus ocular GVHD diagnostic criteria were published. <sup>6</sup> and recently validated <sup>65</sup> against a Best Practise Score and, importantly, the 2015 NIH consensus for clinical trials, thus allowing comparison between the haematology and ophthalmology clinic. The relevance of diagnostic criteria to basic science research is questionable, as the likelihood of a diagnosis may not relate to the severity of a pathological process. Our data would support this, as we did not find the same increased numbers of CD8+and monocytes as we did find when using other methods, such as the Schirmer's score and the new onset KCS criteria. Since we have shown that the ocular surface lymphocyte populations are different in post-HSCT patients regardless of ocular disease, and that the presence of systemic GVHD does not influence the ocular surface leukocyte populations: it could be argued, that the presence or absence of systemic GVHD has little or no impact on the eyes. If this is indeed the case, I would question whether, for basic science trials, the 'second step' where the clinical score is converted into diagnostic score (nil, probable, possible) should be omitted and analysis using the composite score only.

### **Conjunctival Immune Populations Post-HSCT**

Peripheral tissue reconstitution has been poorly studied in the human, due to the difficulty in obtaining tissue biopsies which require invasive procedures. Most of the published literature comes from animal studies, with models of HSCT. We were able to study peripheral tissue reconstitution longitudinally in

representative human patients. After conditioning lymphocyte cell numbers fall, as they do in the blood. Some, possibly tissue resident, CD8+cells survive conditioning, but at the three-month time-point, CD8+cell numbers fall to become significantly lower than pre-transplant levels. This suggested that the lifespan of resident CD8+cells in the conjunctiva is less than 3 months.

Compared to healthy volunteers, there are significantly higher numbers of CD4+lymphocytes in the conjunctiva at 12 months. This is not accompanied by an increase in the number of innate cells, such as macrophages or neutrophils. This presence of increased lymphocytes in the conjunctiva *in the absence* of ocular disease has been described before<sup>140</sup> and in our cross-sectional cohort, we found increased CD4+in *all* patients post-HSCT when compared to healthy volunteers. The question remains, why these CD4+cells are entering the tissue from the circulation, even in the absence of clinical disease, indeed, we did not demonstrate an increased number of CD4+cells in the conjunctiva, when we compared post-HSCT patients with and without KCS. This CD4+may represent a subclinical inflammatory infiltrate, or that with an abnormally high proportion of naïve T-cells in the circulation, there is increased trafficking of naïve T-cells into the tissue.

Nevertheless, we have shown the resident ocular surface CD8+ population is resistant to conditioning and T-cell ablation, but these cells are not detected at the 3-month time point, suggesting their lifespan is less than 3 months. We



have also found that reconstitution of the ocular surface is abnormal, with an increase in conjunctival CD4+cells when compared to healthy volunteers.

### **Ocular GVHD Pathophysiology**

For ocular surface GVHD to be occurring, there needs to be immune mediated inflammation against the host, caused by transplanted donor cells or their progeny. GVHD has been shown to cause lacrimal gland inflammation, fibrosis and destruction.<sup>3,4</sup> This causes aqueous deficiency, dry eye disease and the subsequent immune mediated ocular surface damage. This immune process has been extensively studied.<sup>198,227</sup> The question remains as to whether the clinical picture of ocular surface inflammation we see in ocular GVHD is a result of the dry eye related inflammation caused by lacrimal gland destruction, or whether there is, superimposed on this inflammation, a true GVHD response.

It has been long established that there is a lymphocytic infiltrate in the conjunctiva of patients with ocular GVHD<sup>8</sup>; and we were able to demonstrate the presence of CD8+lymphocytes in the conjunctiva of patients as well as macrophages, and neutrophils. The literature, however, is unclear as to the phenotype of these lymphocytes; Rojas et al<sup>140</sup> did not find increased CD8+cells, but Tatematsu<sup>94</sup> and Auw-Haedrich<sup>141</sup> identified CD8+cells, but did not provide statistical analysis; whereas Eberwein et al<sup>142</sup> did analyse numbers, but these *failed* to reach significance. In contrast, in a mouse model of ocular GVHD, found *both donor derived* CD4+and CD8+cells in the ocular surface of mice with ocular GVHD. This situation is further complicated by the fact that

CD8+cells are commonly found in the ocular surface<sup>109</sup> and the control group chosen, with some authors using patients undergoing autologous HSCT, others using patients post-allogenic HSCT without ocular GVHD and others using healthy volunteers. In dry eye disease, the literature *does not* demonstrate a CD8+infiltrate, but CD4+(including Th17) cells are heavily implicated, both in animal models of dry eye disease, and Sjögren's syndrome<sup>171,176</sup> contrasting the immune process in GVHD and dry eye disease. CD8+cells are also found in other body sites with GVHD, notably the oral mucosa<sup>79</sup>, the minor salivary glands<sup>80</sup>, and in cutaneous GVHD<sup>71</sup>. In other sites, CD4+cells are more apparent such as the gastrointestinal tract,<sup>91</sup> and the lungs.<sup>92</sup> Whilst we were unable to further phenotype the CD8+cells; it has been demonstrated that conjunctival CD8+cells are cytotoxic.<sup>99</sup> and so seems most likely that we are observing effector cytotoxic CD8 cells.

The presence of macrophages in patients with KCS post-HSCT raises the question of whether there is antigen presentation on the ocular surface.

Macrophages have been demonstrated to activate naïve CD8+ cells in vitro <sup>228</sup>, furthermore in a humanised mice suffering from GvHD following immunisation with the pp65 viral antigen, it was found that there was interaction of naïve CD4+cells and surrounding clusters of macrophages in cutaneous GVHD-like lesions. <sup>229</sup>. We also found evidence of naïve T-cells (CD4+CD45RO-) cells in the conjunctiva of patients post-HSCT. We did not, however, demonstrate increased number of macrophages in those patients we demonstrated increased numbers of CD4+CD45RO- cells and so local antigen presentation

seems unlikely. T-helper cells have been shown to interact with macrophages to induce antimicrobial action<sup>114</sup>, but in the absence of increased CD4+ cells, it seems more likely that the macrophages are acting without assistance from T-helper cells through innate pathways. Increased macrophage numbers have been found in dry eye disease<sup>171 172 173</sup> although not all studies have found macrophages in the mouse model of dry eye disease<sup>174</sup> and we did not find them in our disease cohort of patients with pSS. Nevertheless, macrophages have also been identified in the mouse model of ocular GVHD<sup>5</sup> and T-cell macrophage interactions may well be very important in the disease.

The inflammatory infiltrate in ocular GVHD is distinct to that found in dry eye disease and primary Sjogren's syndrome, with a predominance of CD8+ cells and macrophage infiltration; indicating that there is a distinct inflammatory process occurring on the ocular surface in ocular GVHD.

### **Suggestions for Future Work**

We have shown that the ocular surface lymphocyte populations post-HSCT are significantly different to those in healthy volunteers. In addition, even in patients without KCS, there were increased macrophages when compared to healthy volunteers. This highlights the importance of choosing an appropriate control group and an appropriate the time-point at which patients are seen. We would also suggest that both healthy volunteers *and* post-HSCT without ocular disease are compared.

In our cross-sectional cohort, we found increased numbers of macrophages and CD8+ cells are found in the conjunctiva of patients with new onset KCS. As discussed above, there is considerable difficulty in determining the best system to assess the presence/absence of ocular GVHD, as well as the severity of the disease. We were unable to validate the International ocular GVHD Consensus diagnostic criteria on our cohort, as low numbers and unavailable data. Further larger studies may help to validate, or invalidate the International Consensus diagnostic criteria and whether or not further criteria could be added to improve this system.

One of the limitations of our current study, is that we were unable to detect the origin of the cells that we had found, and so we are unable to tell whether cells were donor or host derived. In most cases it would be difficult to assess the origin of cells, but for patients where there is a sex-mismatched transplant, it would be possible to identify the presence or absence of a Y chromosome using in-situ hybridisation. If, for instance, the raised CD8+ T-cells in the conjunctiva were donor derived, perhaps more intensive forms of pre-transplant T-cell depletion might help prevent the ocular disease. We were also limited by the number of surface markers we were able to investigate with flow cytometry. Further studies might be able to phenotype the appropriate cell populations in more detail. In the longitudinal cohort, the increased number of CD4+CD45RO+ cells would be interesting to further phenotype; CCR7 would help us to identify whether these were revertant T<sub>EMRA</sub> cells or naïve T-cells. Further phenotyping of these CD4+ cells could be performed using cell stimulation and cytokine

assays, or analysis of tear cytokine levels in post-HSCT patients with no ocular disease. Tetramer staining might also be used to identify whether these cells recognise viral epitopes, or are indeed specific for host tissue. Given the predominance of Th17 in the animal models of dry eye disease, it would help to further differentiate the ocular surface inflammation in ocular GvHD from dry eye disease by looking for markers for these cells.

### **Clinical Applications/Translation**

We have demonstrated that OSIC and flow cytometry is a practical, non-invasive investigation that enables us to observe reconstitution in a peripheral tissue. Monitoring peripheral tissues may help us to understand the kinetics of peripheral reconstitution, perhaps allowing modifications to transplant protocols to improve outcomes for patients. Furthermore, we have also demonstrated changes in a peripheral tissue that are specific to GvHD. This technique provides the opportunity to monitor GvHD in a peripheral tissue, as well as an opportunity to monitor the effects of systemic treatment for GVHD.

# Appendices

## Appendix 1 Use of lissamine green before conjunctival impression cytology and flow cytometry in patients with Sjögren's syndrome

Tomlins PJ, Bowman S, Bron A, Rauz S, Curnow SJ

Presented at the European Association for Vision and Eye Research  
Conference 2012



[Redacted text block containing seven lines of obscured content]

**Appendix 2 Assessment of the EyePRIM Device for Conjunctival  
Impression for Flow Cytometry**

Tomlins PJ, Roy P, Curnow SJ, Rauz S

Presented at Association for Research in Vision and Ophthalmology Meeting  
2013

Investigative Ophthalmology & Visual Science June 2013, Vol.54, 5430





[Redacted text block containing multiple lines of obscured content]

### Appendix 3 Supplementary Data

	All Post GvHD (n=58)	New Onset KC (n=12)	No KCS (n=26)	Healthy Volunteers (n=9)	Sjögren's Syndrome (n=10)
CD4	5557 (9663)	7329 (4863)	4969 (8517)	19752 (23539)	2872 (15528)
CD8	7349 (21868)	7659 (16133)	7349 (17961)	6249 (3709)	7211 (19056)
NKT	128 (305)	161 (212)	108 (385)	20 (13)	63 (337)
Monocytes	3660 (7719)	6170 (13078)	2989 (6767)	2284 (1937)	5215 (3513)
NK Cells	2020 (1894)	2007 (1081)	2020 (2421)	371 (203)	373 (641)
Neutrophils	36103 (60712)	58046 (32063)	28717 (65573)	23491 (39338)	77302 (6702)

**Table 19 Median cell numbers and interquartile range for each leukocyte population in lysed blood in all post-HSCT patients, post-HSCT patients with and without new onset KCS, healthy volunteers and patients with Sjögren's syndrome.**

## References

1. Robinson MR, Lee SS, Rubin BI, et al. Topical corticosteroid therapy for cicatricial conjunctivitis associated with chronic graft-versus-host disease. *Bone marrow transplantation*. 2004;33(10):1031-1035.
2. Filipovich AH, Weisdorf D, Pavletic S, et al. National Institutes of Health consensus development project on criteria for clinical trials in chronic graft-versus-host disease: I. Diagnosis and staging working group report. *Biology of blood and marrow transplantation : journal of the American Society for Blood and Marrow Transplantation*. 2005;11(12):945-956.
3. Ogawa Y, Kuwana M, Yamazaki K, et al. Periductal area as the primary site for T-cell activation in lacrimal gland chronic graft-versus-host disease. *Investigative ophthalmology & visual science*. 2003;44(5):1888-1896.
4. Ogawa Y, Yamazaki K, Kuwana M, et al. A significant role of stromal fibroblasts in rapidly progressive dry eye in patients with chronic GVHD. *Investigative ophthalmology & visual science*. 2001;42(1):111-119.
5. Herretes S, Ross DB, Duffort S, et al. Recruitment of Donor T Cells to the Eyes during Ocular GVHD in Recipients of MHC-Matched Allogeneic Hematopoietic Stem Cell Transplants. *Investigative ophthalmology & visual science*. 2015.
6. Ogawa Y, Kim SK, Dana R, et al. International Chronic Ocular Graft-vs-Host-Disease (GVHD) Consensus Group: proposed diagnostic criteria for chronic GVHD (Part I). *Scientific reports*. 2013;3:3419.
7. Gipson IK. The ocular surface: the challenge to enable and protect vision: the Friedenwald lecture. *Investigative ophthalmology & visual science*. 2007;48(10):4390; 4391-4398.
8. Jabs DA, Hirst LW, Green WR, Tutschka PJ, Santos GW, Beschoner WE. The eye in bone marrow transplantation. II. Histopathology. *Arch Ophthalmol*. 1983;101(4):585-590.
9. Yamaguchi M, Kutsuna M, Uno T, Zheng X, Kodama T, Ohashi Y. Marx line: fluorescein staining line on the inner lid as indicator of meibomian gland function. *Am J Ophthalmol*. 2006;141(4):669-675.
10. Ramalho-Santos M, Willenbring H. On the origin of the term "stem cell". *Cell Stem Cell*. 2007;1(1):35-38.

11. Farber S, Diamond LK. Temporary remissions in acute leukemia in children produced by folic acid antagonist, 4-aminopteroyl-glutamic acid. *The New England journal of medicine*. 1948;238(23):787-793.
12. Thomas ED, Lochte HL, Jr., Lu WC, Ferrebee JW. Intravenous infusion of bone marrow in patients receiving radiation and chemotherapy. *The New England journal of medicine*. 1957;257(11):491-496.
13. Thomas ED, Lochte HL, Jr., Cannon JH, Sahler OD, Ferrebee JW. Supralethal whole body irradiation and isologous marrow transplantation in man. *The Journal of clinical investigation*. 1959;38:1709-1716.
14. Ferrebee JW, Lochte HL, Jr., Jaretzki A, 3rd, Sahler OD, Thomas ED. Successful marrow homograft in the dog after radiation. *Surgery*. 1958;43(3):516-520.
15. Hong R, Cooper MD, Allan MJ, Kay HE, Meuwissen H, Good RA. Immunological restitution in lymphopenic immunological deficiency syndrome. *Lancet*. 1968;1(7541):503-506.
16. Passweg JR, Baldomero H, Bader P, et al. Use of haploidentical stem cell transplantation continues to increase: the 2015 European Society for Blood and Marrow Transplant activity survey report. *Bone marrow transplantation*. 2017.
17. Alchi B, Jayne D, Labopin M, et al. Autologous haematopoietic stem cell transplantation for systemic lupus erythematosus: data from the European Group for Blood and Marrow Transplantation registry. *Lupus*. 2013;22(3):245-253.
18. Muraro PA, Pasquini M, Atkins HL, et al. Long-term Outcomes After Autologous Hematopoietic Stem Cell Transplantation for Multiple Sclerosis. *JAMA Neurol*. 2017.
19. van Laar JM, Farge D, Sont JK, et al. Autologous hematopoietic stem cell transplantation vs intravenous pulse cyclophosphamide in diffuse cutaneous systemic sclerosis: a randomized clinical trial. *JAMA*. 2014;311(24):2490-2498.
20. Alexander T, Arnold R, Hiepe F, Radbruch A. Resetting the immune system with immunoablation and autologous haematopoietic stem cell transplantation in autoimmune diseases. *Clin Exp Rheumatol*. 2016;34(4 Suppl 98):53-57.
21. Bosch M, Khan FM, Storek J. Immune reconstitution after hematopoietic cell transplantation. *Curr Opin Hematol*. 2012;19(4):324-335.

22. Bensinger WI, Clift R, Martin P, et al. Allogeneic peripheral blood stem cell transplantation in patients with advanced hematologic malignancies: a retrospective comparison with marrow transplantation. *Blood*. 1996;88(7):2794-2800.
23. Storek J, Dawson MA, Storer B, et al. Immune reconstitution after allogeneic marrow transplantation compared with blood stem cell transplantation. *Blood*. 2001;97(11):3380-3389.
24. Klanginsirikul P, Carter GI, Byrne JL, Hale G, Russell NH. Campath-1G causes rapid depletion of circulating host dendritic cells (DCs) before allogeneic transplantation but does not delay donor DC reconstitution. *Blood*. 2002;99(7):2586-2591.
25. Auffermann-Gretzinger S, Eger L, Bornhauser M, et al. Fast appearance of donor dendritic cells in human skin: dynamics of skin and blood dendritic cells after allogeneic hematopoietic cell transplantation. *Transplantation*. 2006;81(6):866-873.
26. Storek J, Ferrara S, Ku N, Giorgi JV, Champlin RE, Saxon A. B cell reconstitution after human bone marrow transplantation: recapitulation of ontogeny? *Bone marrow transplantation*. 1993;12(4):387-398.
27. Storek J, Lalovic BB, Rupert K, Dawson MA, Shen DD, Maloney DG. Kinetics of B, CD4 T, and CD8 T cells infused into humans: estimates of intravascular:extravascular ratios and total body counts. *Clin Immunol*. 2002;102(3):249-257.
28. Miller JJ, Cole LJ. The radiation resistance of long-lived lymphocytes and plasma cells in mouse and rat lymph nodes. *Journal of immunology (Baltimore, Md : 1950)*. 1967;98(5):982-990.
29. Storek J, Witherspoon RP, Storb R. T cell reconstitution after bone marrow transplantation into adult patients does not resemble T cell development in early life. *Bone marrow transplantation*. 1995;16(3):413-425.
30. Takada K, Jameson SC. Naive T cell homeostasis: from awareness of space to a sense of place. *Nat Rev Immunol*. 2009;9(12):823-832.
31. Le RQ, Melenhorst JJ, Battiwalla M, et al. Evolution of the donor T-cell repertoire in recipients in the second decade after allogeneic stem cell transplantation. *Blood*. 2011;117(19):5250-5256.
32. Castermans E, Hannon M, Dutrieux J, et al. Thymic recovery after allogeneic hematopoietic cell transplantation with non-myeloablative conditioning is limited to patients younger than 60 years of age. *Haematologica*. 2011;96(2):298-306.

33. Grimaldi F, Potter V, Perez-Abellan P, et al. Mixed T Cell Chimerism After Allogeneic Hematopoietic Stem Cell Transplantation for Severe Aplastic Anemia Using an Alemtuzumab-Containing Regimen Is Shaped by Persistence of Recipient CD8 T Cells. *Biology of blood and marrow transplantation : journal of the American Society for Blood and Marrow Transplantation*. 2017;23(2):293-299.
34. van der Heiden PL, de Boer R, van der Steen DM, et al. Identification of varicella-zoster virus-specific CD8 T cells in patients after T-cell-depleted allogeneic stem cell transplantation. *J Virol*. 2009;83(14):7361-7364.
35. Kleemann P, Distler E, Wagner EM, et al. Varicella-zoster virus glycoproteins B and E are major targets of CD4+ and CD8+ T cells reconstituting during zoster after allogeneic transplantation. *Haematologica*. 2012;97(6):874-882.
36. Suessmuth Y, Mukherjee R, Watkins B, et al. CMV reactivation drives posttransplant T-cell reconstitution and results in defects in the underlying TCRbeta repertoire. *Blood*. 2015;125(25):3835-3850.
37. Link CS, Eugster A, Heidenreich F, et al. Abundant cytomegalovirus (CMV) reactive clonotypes in the CD8(+) T cell receptor alpha repertoire following allogeneic transplantation. *Clin Exp Immunol*. 2016;184(3):389-402.
38. Day EK, Carmichael AJ, ten Berge IJ, Waller EC, Sissons JG, Wills MR. Rapid CD8+ T cell repertoire focusing and selection of high-affinity clones into memory following primary infection with a persistent human virus: human cytomegalovirus. *Journal of immunology (Baltimore, Md : 1950)*. 2007;179(5):3203-3213.
39. Kim DH, Sohn SK, Won DI, Lee NY, Suh JS, Lee KB. Rapid helper T-cell recovery above  $200 \times 10^6/l$  at 3 months correlates to successful transplant outcomes after allogeneic stem cell transplantation. *Bone marrow transplantation*. 2006;37(12):1119-1128.
40. Alho AC, Kim HT, Chammas MJ, et al. Unbalanced recovery of regulatory and effector T cells after allogeneic stem cell transplantation contributes to chronic GVHD. *Blood*. 2016;127(5):646-657.
41. Zinocker S, Sviland L, Dressel R, Rolstad B. Kinetics of lymphocyte reconstitution after allogeneic bone marrow transplantation: markers of graft-versus-host disease. *Journal of Leukocyte Biology*. 2011;90(1):177-187.
42. Schwab L, Goroncy L, Palaniyandi S, et al. Neutrophil granulocytes recruited upon translocation of intestinal bacteria enhance graft-versus-host disease via tissue damage. *Nat Med*. 2014;20(6):648-654.

43. Moy RH, Huffman AP, Richman LP, et al. Clinical and immunologic impact of CCR5 blockade in graft-versus-host disease prophylaxis. *Blood*. 2017;129(7):906-916.
44. Barnes DW, Loutit JF, Micklem HS. "Secondary disease" of radiation chimeras: a syndrome due to lymphoid aplasia. *Annals of the New York Academy of Sciences*. 1962;99:374-385.
45. Martinez C, Smith JM, Good RA. Runt disease in adult tolerant mice induced by intravenous injection of immunologically competent cells. *Proc Soc Exp Biol Med*. 1961;106:572-576.
46. Billingham RE. Reactions of grafts against their hosts. *Science*. 1959;130(3381):947-953.
47. Deeg HJ, Storb R, Weiden PL, et al. Cyclosporin A and methotrexate in canine marrow transplantation: engraftment, graft-versus-host disease, and induction of intolerance. *Transplantation*. 1982;34(1):30-35.
48. Reisner Y, Kapoor N, Kirkpatrick D, et al. Transplantation for acute leukaemia with HLA-A and B nonidentical parental marrow cells fractionated with soybean agglutinin and sheep red blood cells. *Lancet*. 1981;2(8242):327-331.
49. Atsuta Y, Suzuki R, Yamamoto K, et al. Risk and prognostic factors for Japanese patients with chronic graft-versus-host disease after bone marrow transplantation. *Bone marrow transplantation*. 2006;37(3):289-296.
50. Atkinson K, Horowitz MM, Gale RP, et al. Risk factors for chronic graft-versus-host disease after HLA-identical sibling bone marrow transplantation. *Blood*. 1990;75(12):2459-2464.
51. Carlens S, Ringden O, Remberger M, et al. Risk factors for chronic graft-versus-host disease after bone marrow transplantation: a retrospective single centre analysis. *Bone marrow transplantation*. 1998;22(8):755-761.
52. Higman MA, Vogelsang GB. Chronic graft versus host disease. *Br J Haematol*. 2004;125(4):435-454.
53. Przepiorka D, Anderlini P, Saliba R, et al. Chronic graft-versus-host disease after allogeneic blood stem cell transplantation. *Blood*. 2001;98(6):1695-1700.
54. Wagner JL, Flowers ME, Longton G, Storb R, Schubert M, Sullivan KM. The development of chronic graft-versus-host disease: an analysis of

- screening studies and the impact of corticosteroid use at 100 days after transplantation. *Bone marrow transplantation*. 1998;22(2):139-146.
55. Ochs LA, Miller WJ, Filipovich AH, et al. Predictive factors for chronic graft-versus-host disease after histocompatible sibling donor bone marrow transplantation. *Bone marrow transplantation*. 1994;13(4):455-460.
  56. Weiden PL, Flournoy N, Thomas ED, et al. Antileukemic effect of graft-versus-host disease in human recipients of allogeneic-marrow grafts. *The New England journal of medicine*. 1979;300(19):1068-1073.
  57. Weiden PL, Sullivan KM, Flournoy N, Storb R, Thomas ED. Antileukemic effect of chronic graft-versus-host disease: contribution to improved survival after allogeneic marrow transplantation. *The New England journal of medicine*. 1981;304(25):1529-1533.
  58. Marmont AM, Horowitz MM, Gale RP, et al. T-cell depletion of HLA-identical transplants in leukemia. *Blood*. 1991;78(8):2120-2130.
  59. Marks DI, Lush R, Cavenagh J, et al. The toxicity and efficacy of donor lymphocyte infusions given after reduced-intensity conditioning allogeneic stem cell transplantation. *Blood*. 2002;100(9):3108-3114.
  60. Jagasia MH, Greinix HT, Arora M, et al. National Institutes of Health Consensus Development Project on Criteria for Clinical Trials in Chronic Graft-versus-Host Disease: I. The 2014 Diagnosis and Staging Working Group report. *Biology of blood and marrow transplantation : journal of the American Society for Blood and Marrow Transplantation*. 2015;21(3):389-401 e381.
  61. Wolffsohn JS, Arita R, Chalmers R, et al. TFOS DEWS II Diagnostic Methodology report. *The ocular surface*. 2017;15(3):539-574.
  62. Inamoto Y, Chai X, Kurland BF, et al. Validation of measurement scales in ocular graft-versus-host disease. *Ophthalmology*. 2012;119(3):487-493.
  63. Tatematsu Y, Ogawa Y, Abe T, et al. Grading criteria for chronic ocular graft-versus-host disease: comparing the NIH eye score, Japanese dry eye score, and DEWS 2007 score. *Scientific reports*. 2014;4:6680.
  64. The definition and classification of dry eye disease: report of the Definition and Classification Subcommittee of the International Dry Eye WorkShop (2007). *The ocular surface*. 2007;5(2):75-92.
  65. Rapoport Y, Freeman T, Koyama T, et al. Validation of International Chronic Ocular Graft-Versus-Host Disease (GVHD) Group Diagnostic



- Criteria as a Chronic Ocular GVHD-Specific Metric. *Cornea*. 2017;36(2):258-263.
66. Martin PJ, Schoch G, Fisher L, et al. A retrospective analysis of therapy for acute graft-versus-host disease: initial treatment. *Blood*. 1990;76(8):1464-1472.
  67. Friedman KJ, LeBoit PE, Farmer ER. Acute follicular graft-vs-host reaction. A distinct clinicopathologic presentation. *Arch Dermatol*. 1988;124(5):688-691.
  68. Przepiorka D, Weisdorf D, Martin P, et al. 1994 Consensus Conference on Acute GVHD Grading. *Bone marrow transplantation*. 1995;15(6):825-828.
  69. Fischer A, Jakubowski AA, Lacouture ME, et al. Histopathologic Features of Cutaneous Acute Graft-Versus-Host Disease in T-Cell-Depleted Peripheral Blood Stem Cell Transplant Recipients. *Am J Dermatopathol*. 2015;37(7):523-529.
  70. Terakura S, Martin PJ, Shulman HM, Storer BE. Cutaneous macrophage infiltration in acute GvHD. *Bone marrow transplantation*. 2015;50(8):1135-1137.
  71. Bruggen MC, Klein I, Greinix H, et al. Diverse T-cell responses characterize the different manifestations of cutaneous graft-versus-host disease. *Blood*. 2014;123(2):290-299.
  72. Shulman HM, Kleiner D, Lee SJ, et al. Histopathologic diagnosis of chronic graft-versus-host disease: National Institutes of Health Consensus Development Project on Criteria for Clinical Trials in Chronic Graft-versus-Host Disease: II. Pathology Working Group Report. *Biology of blood and marrow transplantation : journal of the American Society for Blood and Marrow Transplantation*. 2006;12(1):31-47.
  73. Johnson ML, Farmer ER. Graft-versus-host reactions in dermatology. *J Am Acad Dermatol*. 1998;38(3):369-392; quiz 393-366.
  74. Schaffer JV, McNiff JM, Seropian S, Cooper DL, Bologna JL. Lichen sclerosus and eosinophilic fasciitis as manifestations of chronic graft-versus-host disease: expanding the sclerodermoid spectrum. *J Am Acad Dermatol*. 2005;53(4):591-601.
  75. Wysocki CA, Panoskaltsis-Mortari A, Blazar BR, Serody JS. Leukocyte migration and graft-versus-host disease. *Blood*. 2005;105(11):4191-4199.

76. Faaij CMJM, Lankester AC, Spierings E, et al. A possible role for CCL27/CTACK-CCR10 interaction in recruiting CD4+ T cells to skin in human graft-versus-host disease. *British Journal of Haematology*. 2006;133(5):538-549.
77. Piper KP, Horlock C, Curnow SJ, et al. CXCL10-CXCR3 interactions play an important role in the pathogenesis of acute graft-versus-host disease in the skin following allogeneic stem-cell transplantation. *Blood*. 2007;110(12):3827-3832.
78. Fassil H, Bassim CW, Mays J, et al. Oral chronic graft-vs.-host disease characterization using the NIH scale. *J Dent Res*. 2012;91(7 Suppl):45S-51S.
79. Imanguli MM, Swaim WD, League SC, Gress RE, Pavletic SZ, Hakim FT. Increased T-bet+ cytotoxic effectors and type I interferon-mediated processes in chronic graft-versus-host disease of the oral mucosa. *Blood*. 2009;113(15):3620-3630.
80. Imanguli MM, Atkinson JC, Mitchell SA, et al. Salivary gland involvement in chronic graft-versus-host disease: prevalence, clinical significance, and recommendations for evaluation. *Biology of blood and marrow transplantation : journal of the American Society for Blood and Marrow Transplantation*. 2010;16(10):1362-1369.
81. Glucksberg H, Storb R, Fefer A, et al. Clinical manifestations of graft-versus-host disease in human recipients of marrow from HL-A-matched sibling donors. *Transplantation*. 1974;18(4):295-304.
82. Akpek G, Chinratanalab W, Lee LA, et al. Gastrointestinal involvement in chronic graft-versus-host disease: a clinicopathologic study. *Biology of blood and marrow transplantation : journal of the American Society for Blood and Marrow Transplantation*. 2003;9(1):46-51.
83. Salomao M, Dorritie K, Mapara MY, Sepulveda A. Histopathology of Graft-vs-Host Disease of Gastrointestinal Tract and Liver: An Update. *Am J Clin Pathol*. 2016;145(5):591-603.
84. Mapara MY, Leng C, Kim YM, et al. Expression of chemokines in GVHD target organs is influenced by conditioning and genetic factors and amplified by GVHR. *Biology of blood and marrow transplantation : journal of the American Society for Blood and Marrow Transplantation*. 2006;12(6):623-634.
85. Peled JU, Hanash AM, Jenq RR. Role of the intestinal mucosa in acute gastrointestinal GVHD. *Blood*. 2016;128(20):2395-2402.

86. van Bekkum Dw Fau - Knaan S, Knaan S. Role of bacterial microflora in development of intestinal lesions from graft-versus-host reaction. (0027-8874 (Print)).
87. Hanash AM, Dudakov JA, Hua G, et al. Interleukin-22 protects intestinal stem cells from immune-mediated tissue damage and regulates sensitivity to graft versus host disease. *Immunity*. 2012;37(2):339-350.
88. Schwab L, Goroncy L, Palaniyandi S, et al. Neutrophil granulocytes recruited upon translocation of intestinal bacteria enhance graft-versus-host disease via tissue damage. (1546-170X (Electronic)).
89. Koyama M, Cheong M, Markey KA, et al. Donor colonic CD103+ dendritic cells determine the severity of acute graft-versus-host disease. (1540-9538 (Electronic)).
90. Reinhardt K, Foell D, Vogl T, et al. Monocyte-induced development of Th17 cells and the release of S100 proteins are involved in the pathogenesis of graft-versus-host disease. (1550-6606 (Electronic)).
91. Zhou V, Agle K, Chen X, et al. A colitogenic memory CD4+ T cell population mediates gastrointestinal graft-versus-host disease. *The Journal of clinical investigation*. 2016;126(9):3541-3555.
92. Ohnuma K, Hatano R, Aune TM, et al. Regulation of pulmonary graft-versus-host disease by IL-26+CD26+CD4 T lymphocytes. *Journal of immunology (Baltimore, Md : 1950)*. 2015;194(8):3697-3712.
93. Reinstein DZ, Archer TJ, Gobbe M, Silverman RH, Coleman DJ. Epithelial thickness in the normal cornea: three-dimensional display with Artemis very high-frequency digital ultrasound. *J Refract Surg*. 2008;24(6):571-581.
94. Tatematsu Y, Ogawa Y, Shimmura S, et al. Mucosal microvilli in dry eye patients with chronic GVHD. *Bone marrow transplantation*. 2012;47(3):416-425.
95. Steven P, Rupp J, Huttmann G, et al. Experimental induction and three-dimensional two-photon imaging of conjunctiva-associated lymphoid tissue. *Investigative ophthalmology & visual science*. 2008;49(4):1512-1517.
96. Hamann D, Baars PA, Rep MH, et al. Phenotypic and functional separation of memory and effector human CD8+ T cells. *J Exp Med*. 1997;186(9):1407-1418.

97. Sallusto F, Lenig D, Forster R, Lipp M, Lanzavecchia A. Two subsets of memory T lymphocytes with distinct homing potentials and effector functions. *Nature*. 1999;401(6754):708-712.
98. Masopust D, Vezys V, Marzo AL, Lefrancois L. Preferential localization of effector memory cells in nonlymphoid tissue. *Science*. 2001;291(5512):2413-2417.
99. Williams GP, Pachnio A, Long HM, Rauz S, Curnow SJ. Cytokine production and antigen recognition by human mucosal homing conjunctival effector memory CD8+ T cells. *Investigative ophthalmology & visual science*. 2014;55(12):8523-8530.
100. Geginat J, Lanzavecchia A, Sallusto F. Proliferation and differentiation potential of human CD8+ memory T-cell subsets in response to antigen or homeostatic cytokines. *Blood*. 2003;101(11):4260-4266.
101. Bose T, Lee R, Hou A, Tong L, Chandy KG. Tissue resident memory T cells in the human conjunctiva and immune signatures in human dry eye disease. *Scientific reports*. 2017;7:45312.
102. Bonneville M, Janeway CA, Jr., Ito K, et al. Intestinal intraepithelial lymphocytes are a distinct set of gamma delta T cells. *Nature*. 1988;336(6198):479-481.
103. Leckie MJ, Jenkins GR, Khan J, et al. Sputum T lymphocytes in asthma, COPD and healthy subjects have the phenotype of activated intraepithelial T cells (CD69+ CD103+). *Thorax*. 2003;58(1):23-29.
104. Schon MP, Arya A, Murphy EA, et al. Mucosal T lymphocyte numbers are selectively reduced in integrin alpha E (CD103)-deficient mice. *Journal of immunology (Baltimore, Md : 1950)*. 1999;162(11):6641-6649.
105. Hayday A, Theodoridis E, Ramsburg E, Shires J. Intraepithelial lymphocytes: exploring the Third Way in immunology. *Nat Immunol*. 2001;2(11):997-1003.
106. Poussier P, Ning T, Banerjee D, Julius M. A Unique Subset of Self-specific Intraintestinal T Cells Maintains Gut Integrity. *The Journal of Experimental Medicine*. 2002;195(11):1491-1497.
107. Keystone EC, Rittershaus C, Wood N, et al. Elevation of a gamma delta T cell subset in peripheral blood and synovial fluid of patients with rheumatoid arthritis. *Clin Exp Immunol*. 1991;84(1):78-82.
108. Catalfamo M, Roura-Mir C, Sospedra M, et al. Self-reactive cytotoxic gamma delta T lymphocytes in Graves' disease specifically recognize

- thyroid epithelial cells. *Journal of immunology (Baltimore, Md : 1950)*. 1996;156(2):804-811.
109. Williams GP, Denniston AK, Oswal KS, et al. The dominant human conjunctival epithelial CD8 $\alpha$ beta<sup>+</sup> T cell population is maintained with age but the number of CD4<sup>+</sup> T cells increases. *Age*. 2012;34(6):1517-1528.
  110. Nesburn AB, Bettahi I, Dasgupta G, et al. Functional Foxp3<sup>+</sup> CD4<sup>+</sup> CD25(Bright<sup>+</sup>) "natural" regulatory T cells are abundant in rabbit conjunctiva and suppress virus-specific CD4<sup>+</sup> and CD8<sup>+</sup> effector T cells during ocular herpes infection. *J Virol*. 2007;81(14):7647-7661.
  111. Watanabe R, Gehad A, Yang C, et al. Human skin is protected by four functionally and phenotypically discrete populations of resident and recirculating memory T cells. *Sci Transl Med*. 2015;7(279):279ra239.
  112. Jenkins SJ, Ruckerl D, Cook PC, et al. Local macrophage proliferation, rather than recruitment from the blood, is a signature of TH2 inflammation. *Science*. 2011;332(6035):1284-1288.
  113. Varol C, Vallon-Eberhard A, Elinav E, et al. Intestinal lamina propria dendritic cell subsets have different origin and functions. *Immunity*. 2009;31(3):502-512.
  114. Murray PJ, Wynn TA. Protective and pathogenic functions of macrophage subsets. *Nat Rev Immunol*. 2011;11(11):723-737.
  115. Hume DA. Macrophages as APC and the Dendritic Cell Myth. *The Journal of Immunology*. 2008;181(9):5829-5835.
  116. Denning TL, Norris BA, Medina-Contreras O, et al. Functional specializations of intestinal dendritic cell and macrophage subsets that control Th17 and regulatory T cell responses are dependent on the T cell/APC ratio, source of mouse strain, and regional localization. *Journal of immunology (Baltimore, Md : 1950)*. 2011;187(2):733-747.
  117. Allansmith MR, Kajiyama G, Abelson MB, Simon MA. Plasma cell content of main and accessory lacrimal glands and conjunctiva. *Am J Ophthalmol*. 1976;82(6):819-826.
  118. Obata H, Yamamoto S, Horiuchi H, Machinami R. Histopathologic study of human lacrimal gland. Statistical analysis with special reference to aging. *Ophthalmology*. 1995;102(4):678-686.
  119. Xu KP, Katagiri S, Takeuchi T, Tsubota K. Biopsy of labial salivary glands and lacrimal glands in the diagnosis of Sjogren's syndrome. *J Rheumatol*. 1996;23(1):76-82.

120. Gao J, Morgan G, Tieu D, et al. ICAM-1 expression predisposes ocular tissues to immune-based inflammation in dry eye patients and Sjogrens syndrome-like MRL/lpr mice. *Experimental eye research*. 2004;78(4):823-835.
121. Cruz AA, Garcia DM, Pinto CT, Cechetti SP. Spontaneous eyeblink activity. *The ocular surface*. 2011;9(1):29-41.
122. Pult H, Korb DR, Blackie CA, Knop E, Marx E. About vital staining of the eye and eyelids. I. The anatomy, physiology, and pathology of the eyelid margins and the lacrimal puncta by E. Marx. 1924. *Optom Vis Sci*. 2010;87(10):718-724.
123. Bray LC, Carey PJ, Proctor SJ, Evans RG, Hamilton PJ. Ocular complications of bone marrow transplantation. *The British journal of ophthalmology*. 1991;75(10):611-614.
124. Na KS, Yoo YS, Mok JW, Lee JW, Joo CK. Incidence and risk factors for ocular GVHD after allogeneic hematopoietic stem cell transplantation. *Bone marrow transplantation*. 2015;50(11):1459-1464.
125. Ogawa Y, Okamoto S, Wakui M, et al. Dry eye after haematopoietic stem cell transplantation. *The British journal of ophthalmology*. 1999;83(10):1125-1130.
126. Jacobs R, Tran U, Chen H, et al. Prevalence and risk factors associated with development of ocular GVHD defined by NIH consensus criteria. *Bone marrow transplantation*. 2012;47(11):1470-1473.
127. Ivanir Y, Shimoni A, Ezra-Nimni O, Barequet IS. Prevalence of dry eye syndrome after allogeneic hematopoietic stem cell transplantation. *Cornea*. 2013;32(5):e97-101.
128. Tabbara KF, Al-Ghamdi A, Al-Mohareb F, et al. Ocular findings after allogeneic hematopoietic stem cell transplantation. *Ophthalmology*. 2009;116(9):1624-1629.
129. Calissendorff B, el Azazi M, Lonnqvist B. Dry eye syndrome in long-term follow-up of bone marrow transplanted patients. *Bone marrow transplantation*. 1989;4(6):675-678.
130. Livesey SJ, Holmes JA, Whittaker JA. Ocular complications of bone marrow transplantation. *Eye*. 1989;3 ( Pt 3):271-276.
131. Bross DS, Tutschka PJ, Farmer ER, et al. Predictive factors for acute graft-versus-host disease in patients transplanted with HLA-identical bone marrow. *Blood*. 1984;63(6):1265-1270.

132. Kamoi M, Ogawa Y, Uchino M, et al. Donor-recipient gender difference affects severity of dry eye after hematopoietic stem cell transplantation. *Eye*. 2011;25(7):860-865.
133. Stern M, Brand R, de Witte T, et al. Female-versus-male alloreactivity as a model for minor histocompatibility antigens in hematopoietic stem cell transplantation. *Am J Transplant*. 2008;8(10):2149-2157.
134. Miklos DB, Kim HT, Miller KH, et al. Antibody responses to H-Y minor histocompatibility antigens correlate with chronic graft-versus-host disease and disease remission. *Blood*. 2005;105(7):2973-2978.
135. Riemens A, Te Boome LC, Kalinina Ayuso V, et al. Impact of ocular graft-versus-host disease on visual quality of life in patients after allogeneic stem cell transplantation: questionnaire study. *Acta ophthalmologica*. 2014;92(1):82-87.
136. Hettinga YM, Verdonck LF, Fijnheer R, Rijkers GT, Rothova A. Anterior uveitis: a manifestation of graft-versus-host disease. *Ophthalmology*. 2007;114(4):794-797.
137. Strouthidis NG, Francis PJ, Stanford MR, Graham EM, Holder GE, Bird AC. Posterior segment complications of graft versus host disease after bone marrow transplantation. *The British journal of ophthalmology*. 2003;87(11):1421-1423.
138. Coskuncan NM, Jabs DA, Dunn JP, et al. The eye in bone marrow transplantation. VI. Retinal complications. *Arch Ophthalmol*. 1994;112(3):372-379.
139. Cheng LL, Kwok AK, Wat NM, Neoh EL, Jon HC, Lam DS. Graft-vs-host-disease-associated conjunctival chemosis and central serous chorioretinopathy after bone marrow transplant. *Am J Ophthalmol*. 2002;134(2):293-295.
140. Rojas B, Cuhna R, Zafirakis P, et al. Cell populations and adhesion molecules expression in conjunctiva before and after bone marrow transplantation. *Experimental eye research*. 2005;81(3):313-325.
141. Auw-Haedrich C, Potsch C, Bohringer D, et al. Histological and immunohistochemical characterisation of conjunctival graft vs host disease following haematopoietic stem cell transplantation. *Graefes Arch Clin Exp Ophthalmol*. 2007;245(7):1001-1007.
142. Eberwein P, Issleib S, Bohringer D, et al. Conjunctival HLA-DR and CD8 expression detected by impression cytology in ocular graft versus host disease. *Molecular vision*. 2013;19:1492-1501.

143. Ratanatharathorn V, Ayash L, Reynolds C, et al. Treatment of chronic graft-versus-host disease with anti-CD20 chimeric monoclonal antibody. *Biology of blood and marrow transplantation : journal of the American Society for Blood and Marrow Transplantation*. 2003;9(8):505-511.
144. Arai S, Pidala J, Pusic I, et al. A randomized phase II crossover study of imatinib or rituximab for cutaneous sclerosis after hematopoietic cell transplantation. *Clin Cancer Res*. 2015.
145. Cutler C, Kim HT, Bindra B, et al. Rituximab prophylaxis prevents corticosteroid-requiring chronic GVHD after allogeneic peripheral blood stem cell transplantation: results of a phase 2 trial. *Blood*. 2013;122(8):1510-1517.
146. Riemens A, Stoyanova E, Rothova A, Kuiper J. Cytokines in tear fluid of patients with ocular graft-versus-host disease after allogeneic stem cell transplantation. *Molecular vision*. 2012;18:797-802.
147. Jung JW, Han SJ, Song MK, et al. Tear Cytokines as Biomarkers for Chronic Graft-Versus-Host Disease. *Biology of blood and marrow transplantation : journal of the American Society for Blood and Marrow Transplantation*. 2015.
148. Nelson JD, Craig JP, Akpek EK, et al. TFOS DEWS II Introduction. *The ocular surface*. 2017;15(3):269-275.
149. Craig JP, Nichols KK, Akpek EK, et al. TFOS DEWS II Definition and Classification Report. *The ocular surface*. 2017;15(3):276-283.
150. Pepose JS, Akata RF, Pflugfelder SC, Voigt W. Mononuclear cell phenotypes and immunoglobulin gene rearrangements in lacrimal gland biopsies from patients with Sjogren's syndrome. *Ophthalmology*. 1990;97(12):1599-1605.
151. Wolff E. The muco-cutaneous junction of the lid margin and the distribution of the tear fluid. *Trans Ophthalmol Soc UK*. 1946;66:291-308.
152. Dilly PN. Structure and function of the tear film. *Adv Exp Med Biol*. 1994;350:239-247.
153. King-Smith PE, Reuter KS, Braun RJ, Nichols JJ, Nichols KK. Tear film breakup and structure studied by simultaneous video recording of fluorescence and tear film lipid layer images. *Investigative ophthalmology & visual science*. 2013;54(7):4900-4909.
154. Millar TJ, Schuett BS. The real reason for having a meibomian lipid layer covering the outer surface of the tear film - A review. *Experimental eye research*. 2015;137:125-138.



155. Carreno E, Enriquez-de-Salamanca A, Teson M, et al. Cytokine and chemokine levels in tears from healthy subjects. *Acta ophthalmologica*. 2010;88(7):e250-258.
156. Gupta A, Monroy D, Ji Z, Yoshino K, Huang A, Pflugfelder SC. Transforming growth factor beta-1 and beta-2 in human tear fluid. *Curr Eye Res*. 1996;15(6):605-614.
157. Markoulli M, Papas E, Cole N, Holden BA. The diurnal variation of matrix metalloproteinase-9 and its associated factors in human tears. *Investigative ophthalmology & visual science*. 2012;53(3):1479-1484.
158. El Annan J, Goyal S, Zhang Q, Freeman GJ, Sharpe AH, Dana R. Regulation of T-cell chemotaxis by programmed death-ligand 1 (PD-L1) in dry eye-associated corneal inflammation. *Investigative ophthalmology & visual science*. 2010;51(7):3418-3423.
159. Lass JH, Walter EI, Burris TE, et al. Expression of two molecular forms of the complement decay-accelerating factor in the eye and lacrimal gland. *Investigative ophthalmology & visual science*. 1990;31(6):1136-1148.
160. Bardenstein DS, Dietz Y, Lass JH, Medof ME. Localization of the complement membrane attack complex inhibitor (CD59) in human conjunctiva and lacrimal gland. *Curr Eye Res*. 1994;13(12):851-855.
161. Contreras-Ruiz L, Masli S. Immunomodulatory cross-talk between conjunctival goblet cells and dendritic cells. *PLoS One*. 2015;10(3):e0120284.
162. Shen L, Barabino S, Taylor AW, Dana MR. Effect of the ocular microenvironment in regulating corneal dendritic cell maturation. *Arch Ophthalmol*. 2007;125(7):908-915.
163. Sacks EH, Wieczorek R, Jakobiec FA, Knowles DM, 2nd. Lymphocytic subpopulations in the normal human conjunctiva. A monoclonal antibody study. *Ophthalmology*. 1986;93(10):1276-1283.
164. De Paiva CS, Raince JK, McClellan AJ, et al. Homeostatic control of conjunctival mucosal goblet cells by NKT-derived IL-13. *Mucosal Immunol*. 2011;4(4):397-408.
165. Luo L, Li DQ, Doshi A, Farley W, Corrales RM, Pflugfelder SC. Experimental dry eye stimulates production of inflammatory cytokines and MMP-9 and activates MAPK signaling pathways on the ocular surface. *Investigative ophthalmology & visual science*. 2004;45(12):4293-4301.

166. Higuchi A, Kawakita T, Tsubota K. IL-6 induction in desiccated corneal epithelium in vitro and in vivo. *Molecular vision*. 2011;17:2400-2406.
167. Gulati A, Sacchetti M, Bonini S, Dana R. Chemokine receptor CCR5 expression in conjunctival epithelium of patients with dry eye syndrome. *Arch Ophthalmol*. 2006;124(5):710-716.
168. Lee HS, Hattori T, Park EY, Stevenson W, Chauhan SK, Dana R. Expression of toll-like receptor 4 contributes to corneal inflammation in experimental dry eye disease. *Investigative ophthalmology & visual science*. 2012;53(9):5632-5640.
169. Reinoso R, Calonge M, Castellanos E, et al. Differential cell proliferation, apoptosis, and immune response in healthy and evaporative-type dry eye conjunctival epithelia. *Investigative ophthalmology & visual science*. 2011;52(7):4819-4828.
170. Theofilopoulos AN, Gonzalez-Quintal R, Lawson BR, et al. Sensors of the innate immune system: their link to rheumatic diseases. *Nat Rev Rheumatol*. 2010;6(3):146-156.
171. Barabino S, Montaldo E, Solignani F, Valente C, Mingari MC, Rolando M. Immune response in the conjunctival epithelium of patients with dry eye. *Experimental eye research*. 2010;91(4):524-529.
172. Goyal S, Chauhan SK, Zhang Q, Dana R. Amelioration of murine dry eye disease by topical antagonist to chemokine receptor 2. *Arch Ophthalmol*. 2009;127(7):882-887.
173. Schaumburg CS, Siemasko KF, De Paiva CS, et al. Ocular surface APCs are necessary for autoreactive T cell-mediated experimental autoimmune lacrimal keratoconjunctivitis. *Journal of immunology (Baltimore, Md : 1950)*. 2011;187(7):3653-3662.
174. You IC, Coursey TG, Bian F, Barbosa FL, de Paiva CS, Pflugfelder SC. Macrophage Phenotype in the Ocular Surface of Experimental Murine Dry Eye Disease. *Arch Immunol Ther Exp (Warsz)*. 2015;63(4):299-304.
175. Chen Y, Chauhan SK, Saban DR, Sadrai Z, Okanobo A, Dana R. Interferon-gamma-secreting NK cells promote induction of dry eye disease. *J Leukoc Biol*. 2011;89(6):965-972.
176. Stern ME, Gao J, Schwalb TA, et al. Conjunctival T-cell subpopulations in Sjogren's and non-Sjogren's patients with dry eye. *Investigative ophthalmology & visual science*. 2002;43(8):2609-2614.
177. Niederkorn JY, Stern ME, Pflugfelder SC, et al. Desiccating Stress Induces T Cell-Mediated Sjogren's Syndrome-Like Lacrimal

- Keratoconjunctivitis. *The Journal of Immunology*. 2006;176(7):3950-3957.
178. Dohlman TH, Chauhan SK, Kodati S, et al. The CCR6/CCL20 axis mediates Th17 cell migration to the ocular surface in dry eye disease. *Investigative ophthalmology & visual science*. 2013;54(6):4081-4091.
  179. Zheng X, Bian F, Ma P, et al. Induction of Th17 differentiation by corneal epithelial-derived cytokines. *J Cell Physiol*. 2010;222(1):95-102.
  180. Bron AJ, Benjamin L, Snibson GR. Meibomian gland disease. Classification and grading of lid changes. *Eye*. 1991;5 ( Pt 4):395-411.
  181. POSTERS. *Acta Ophthalmologica Scandinavica*. 2006;84:13-72.
  182. Baudouin C, Brignole F, Becquet F, Pisella PJ, Goguel A. Flow cytometry in impression cytology specimens. A new method for evaluation of conjunctival inflammation. *Investigative ophthalmology & visual science*. 1997;38(7):1458-1464.
  183. Tomlins PJ, Bowman S, Bron A, Rauz S, Curnow SJ. Use of lissamine green before conjunctival impression cytology and flow cytometry in patients with sjögren's syndrome. *Acta ophthalmologica*. 2012;90:0-0.
  184. Tomlins P, Roy P, Curnow J, Rauz S. Assessment of the EyePRIM Device for Conjunctival Impression for Flow Cytometry. *Invest Ophthalmol Vis Sci*. 2013;54(6):5430-.
  185. Tomlinson A, Khanal S, Ramaesh K, Diaper C, McFadyen A. Tear film osmolarity: determination of a referent for dry eye diagnosis. *Investigative ophthalmology & visual science*. 2006;47(10):4309-4315.
  186. Clark RA, Watanabe R, Teague JE, et al. Skin effector memory T cells do not recirculate and provide immune protection in alemtuzumab-treated CTCL patients. *Sci Transl Med*. 2012;4(117):117ra117.
  187. Cose S. T-cell migration: a naive paradigm? *Immunology*. 2007;120(1):1-7.
  188. Cose S, Brammer C, Khanna KM, Masopust D, Lefrancois L. Evidence that a significant number of naive T cells enter non-lymphoid organs as part of a normal migratory pathway. *Eur J Immunol*. 2006;36(6):1423-1433.
  189. Kennedy DW, Abkowitz JL. Kinetics of central nervous system microglial and macrophage engraftment: analysis using a transgenic bone marrow transplantation model. *Blood*. 1997;90(3):986-993.

190. Haniffa M, Ginhoux F, Wang XN, et al. Differential rates of replacement of human dermal dendritic cells and macrophages during hematopoietic stem cell transplantation. *J Exp Med*. 2009;206(2):371-385.
191. Ullah MA, Hill GR, Tey SK. Functional Reconstitution of Natural Killer Cells in Allogeneic Hematopoietic Stem Cell Transplantation. *Front Immunol*. 2016;7:144.
192. Ruggeri L, Capanni M, Casucci M, et al. Role of natural killer cell alloreactivity in HLA-mismatched hematopoietic stem cell transplantation. *Blood*. 1999;94(1):333-339.
193. Ruggeri L, Capanni M, Urbani E, et al. Effectiveness of donor natural killer cell alloreactivity in mismatched hematopoietic transplants. *Science*. 2002;295(5562):2097-2100.
194. Eissens DN, Schaap NP, Preijers FW, et al. CD3+/CD19+-depleted grafts in HLA-matched allogeneic peripheral blood stem cell transplantation lead to early NK cell cytolytic responses and reduced inhibitory activity of NKG2A. *Leukemia*. 2010;24(3):583-591.
195. Martinez C, Urbano-Ispizua A, Rozman C, et al. Immune reconstitution following allogeneic peripheral blood progenitor cell transplantation: comparison of recipients of positive CD34+ selected grafts with recipients of unmanipulated grafts. *Exp Hematol*. 1999;27(3):561-568.
196. Ogawa Y, Okamoto S, Wakui M, et al. Dry eye after haematopoietic stem cell transplantation. *The British journal of ophthalmology*. 1999;83(10):1125-1130.
197. Herretes S, Ross DB, Duffort S, et al. Recruitment of Donor T Cells to the Eyes During Ocular GVHD in Recipients of MHC-Matched Allogeneic Hematopoietic Stem Cell Transplants. *Investigative ophthalmology & visual science*. 2015;56(4):2348-2357.
198. Stern ME, Schaumburg CS, Pflugfelder SC. Dry eye as a mucosal autoimmune disease. *Int Rev Immunol*. 2013;32(1):19-41.
199. Williams GP, Tomlins PJ, Denniston AK, et al. Elevation of conjunctival epithelial CD45INTCD11b(+)CD16(+)CD14(-) neutrophils in ocular Stevens-Johnson syndrome and toxic epidermal necrolysis. *Investigative ophthalmology & visual science*. 2013;54(7):4578-4585.
200. Williams GP, Nightingale P, Southworth S, et al. Conjunctival Neutrophils Predict Progressive Scarring in Ocular Mucous Membrane Pemphigoid. *Investigative ophthalmology & visual science*. 2016;57(13):5457-5469.

201. Zhang X, Schaumburg CS, Coursey TG, et al. CD8(+) cells regulate the T helper-17 response in an experimental murine model of Sjogren syndrome. *Mucosal Immunol.* 2014;7(2):417-427.
202. Shinomiya K, Ueta M, Sotozono C, et al. Immunohistochemical analysis of inflammatory limbal conjunctiva adjacent to Mooren's ulcer. *The British journal of ophthalmology.* 2013;97(3):362-366.
203. Pong JC, Chu CY, Li WY, et al. Association of hemopexin in tear film and conjunctival macrophages with vernal keratoconjunctivitis. *Arch Ophthalmol.* 2011;129(4):453-461.
204. Fukushima A, Ishida W, Ojima A, et al. Participation of CD11b and F4/80 molecules in the conjunctival eosinophilia of experimental allergic conjunctivitis. *Int Arch Allergy Immunol.* 2010;151(2):129-136.
205. Alizadeh H, Neelam S, Niederkorn JY. Role of activated macrophages in Acanthamoeba keratitis. *J Parasitol.* 2007;93(5):1114-1120.
206. Rieber N, Wecker I, Neri D, et al. Extracorporeal photopheresis increases neutrophilic myeloid-derived suppressor cells in patients with GvHD. *Bone marrow transplantation.* 2014;49(4):545-552.
207. He Y, Wang B, Jia B, Guan J, Zeng H, Pan Z. Effects of Adoptive Transferring Different Sources of Myeloid-Derived Suppressor Cells in Mice Corneal Transplant Survival. *Transplantation.* 2015;99(10):2102-2108.
208. Ishida W, Fukuda K, Kajisako M, et al. Conjunctival macrophages act as antigen-presenting cells in the conjunctiva during the development of experimental allergic conjunctivitis. *Molecular vision.* 2010;16:1280-1285.
209. Sonawane S, Khanolkar V, Namavari A, et al. Ocular surface extracellular DNA and nuclease activity imbalance: a new paradigm for inflammation in dry eye disease. *Investigative ophthalmology & visual science.* 2012;53(13):8253-8263.
210. Cvenkel B, Globocnik M. Conjunctival scrapings and impression cytology in chronic conjunctivitis. Correlation with microbiology. *Eur J Ophthalmol.* 1997;7(1):19-23.
211. Zaidi TS, Zaidi T, Pier GB. Role of neutrophils, MyD88-mediated neutrophil recruitment, and complement in antibody-mediated defense against Pseudomonas aeruginosa keratitis. *Investigative ophthalmology & visual science.* 2010;51(4):2085-2093.
212. Taylor PR, Roy S, Meszaros EC, et al. JAK/STAT regulation of Aspergillus fumigatus corneal infections and IL-6/23-stimulated

- neutrophil, IL-17, elastase, and MMP9 activity. *J Leukoc Biol.* 2016;100(1):213-222.
213. Li Z, Burns AR, Smith CW. Two waves of neutrophil emigration in response to corneal epithelial abrasion: distinct adhesion molecule requirements. *Investigative ophthalmology & visual science.* 2006;47(5):1947-1955.
214. Mrugacz M, Kasacka I, Bakunowicz-Lazarczyk A, Kaczmarek M, Kulak W. Impression cytology of the conjunctival epithelial cells in patients with cystic fibrosis. *Eye.* 2008;22(9):1137-1140.
215. Matsumoto Y, Dogru M, Goto E, et al. Alterations of the tear film and ocular surface health in chronic smokers. *Eye.* 2008;22(7):961-968.
216. Brinkmann V, Reichard U, Goosmann C, et al. Neutrophil extracellular traps kill bacteria. *Science.* 2004;303(5663):1532-1535.
217. Tibrewal S, Sarkar J, Jassim SH, et al. Tear Fluid Extracellular DNA: Diagnostic and Therapeutic Implications in Dry Eye Disease. *Investigative ophthalmology & visual science.* 2013;54(13):8051-8061.
218. Scapini P, Cassatella MA. Social networking of human neutrophils within the immune system. *Blood.* 2014;124(5):710-719.
219. Pillay J, Tak T, Kamp VM, Koenderman L. Immune suppression by neutrophils and granulocytic myeloid-derived suppressor cells: similarities and differences. *Cell Mol Life Sci.* 2013;70(20):3813-3827.
220. Beauvillain C, Delneste Y, Scotet M, et al. Neutrophils efficiently cross-prime naive T cells in vivo. *Blood.* 2007;110(8):2965-2973.
221. Tillack K, Breiden P, Martin R, Sospedra M. T lymphocyte priming by neutrophil extracellular traps links innate and adaptive immune responses. *Journal of immunology (Baltimore, Md : 1950).* 2012;188(7):3150-3159.
222. Zhong X, Zhu F, Qiao J, et al. The impact of P2X7 receptor antagonist, brilliant blue G on graft-versus-host disease in mice after allogeneic hematopoietic stem cell transplantation. *Cell Immunol.* 2016;310:71-77.
223. Dong Q, Brulc JM, Iovieno A, et al. Diversity of bacteria at healthy human conjunctiva. *Investigative ophthalmology & visual science.* 2011;52(8):5408-5413.
224. Simonetta F, Alvarez M, Negrin RS. Natural Killer Cells in Graft-versus-Host-Disease after Allogeneic Hematopoietic Cell Transplantation. *Front Immunol.* 2017;8:465.

225. Witcher JP, Shiboski CH, Shiboski SC, et al. A simplified quantitative method for assessing keratoconjunctivitis sicca from the Sjogren's Syndrome International Registry. *Am J Ophthalmol.* 2010;149(3):405-415.
226. Shiboski CH, Shiboski SC, Seror R, et al. 2016 American College of Rheumatology/European League Against Rheumatism Classification Criteria for Primary Sjogren's Syndrome: A Consensus and Data-Driven Methodology Involving Three International Patient Cohorts. *Arthritis Rheumatol.* 2017;69(1):35-45.
227. Stevenson W, Chauhan SK, Dana R. Dry eye disease: an immune-mediated ocular surface disorder. *Arch Ophthalmol.* 2012;130(1):90-100.
228. Pozzi LA, Maciaszek JW, Rock KL. Both dendritic cells and macrophages can stimulate naive CD8 T cells in vivo to proliferate, develop effector function, and differentiate into memory cells. *Journal of immunology (Baltimore, Md : 1950).* 2005;175(4):2071-2081.
229. Sundarasetty B, Volk V, Theobald SJ, et al. Human Effector Memory T Helper Cells Engage with Mouse Macrophages and Cause Graft-versus-Host-Like Pathology in Skin of Humanized Mice Used in a Nonclinical Immunization Study. *Am J Pathol.* 2017;187(6):1380-1398.