



## Short Communication

## Open Access

## Two Cases of Hallermann-Streiff Syndrome with Retinal Abnormalities

Erika Maka<sup>\*</sup>, Olga Lukáts, Mária Bausz, Zoltán Zsolt Nagy and Miklos Dénes Resch

Semmelweis University, Department of Ophthalmology

<sup>\*</sup>Corresponding author: Erika Maka, Semmelweis University, Faculty of Medicine, Department of Ophthalmology, Maria str. 39, Budapest, Hungary 1085; Tel: +36208258481; Fax: +3612100309; E-mail: [maker@mailbox.hu](mailto:maker@mailbox.hu)

Received date: Feb 18, 2015, Accepted date: Apr 27, 2015, Published date: Apr 29, 2015

Copyright: © 2015 Maka E, et al. This is an open-access article distributed under the terms of the Creative Commons Attribution License, which permits unrestricted use, distribution, and reproduction in any medium, provided the original author and source are credited.

### Abstract

Hallermann-Streiff syndrome is a rare congenital disorder that is characterized by malformations of the craniofacial region with ocular abnormalities. Some ophthalmic signs can be observed in early age and some in adulthood. The visual functions are determined by a lot of factors including microphthalmos, cataract and fundus abnormalities. We report two cases of Hallermann-Streiff syndrome identified in our department in the last decade.

**Keywords:** Hallermann-Streiff syndrome; Microphthalmia; Congenital cataract; Retinal pigment epithelium

### Case 1

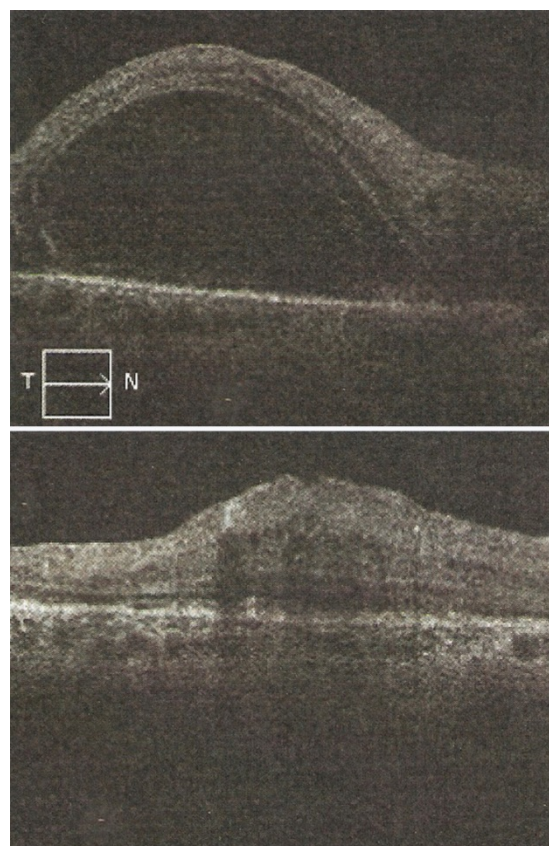
A 42-year-old woman was referred to our Department with secondary glaucoma 9 years ago. She had typical signs of the Hallermann-Streiff syndrome (dyscephalia with bird-like face, dental anomalies, proportionate nanism, hypotrichosis, atrophy of skin on the nose, bilateral congenital cataract and microphthalmos). Cataract surgeries were performed at some months of age and vitrectomy on the right side because of an epiretinal membrane at 11 years of age. She wore contact lenses and sometimes glasses. Axial length was below average on both sides (Table 1).

Parameters	Patient 1		Patient 2	
	Right eye	Left eye	Right eye	Left eye
Axial length (mm)	17.2	18.1	17.31	16.81
Mean corneal refractive power (D)	57.88	58.75	54.87	57.12
Refraction – SE (D)	+15.0	+16.0	+17.75	+15.25
Corneal diameter (mm)	10	10	11.0	11.0
Mean central corneal thickness (µm)	538	521	529	566
Intraocular pressure (mm Hg)	12	8	7	11
Best corrected visual acuity	0.06	LP	Fixate and follow	

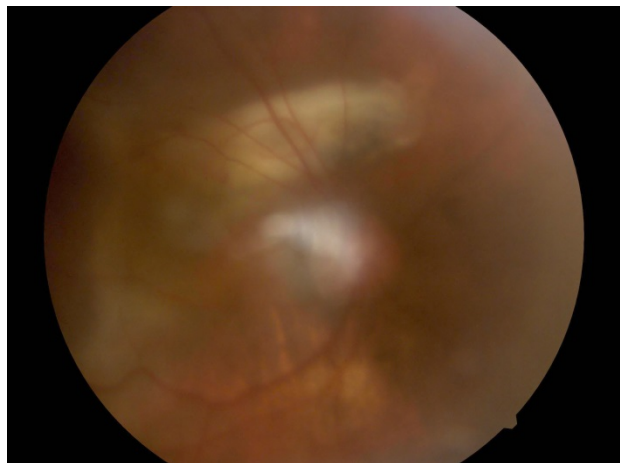
**Table 1:** Ocular findings (LP: Light Perception).

Signs of chronic anterior uveitis with insufficient pupil dilation were found. Lid surgeries were made due to trichiasis and entropion 8 years ago. The intraocular pressure was under control with local combined treatment in the right eye (timolol, brinzolamide, bimatoprost). Trabeculectomy was performed on the left eye 5 years ago. From July of 2013 she noticed visual disturbance on the right eye,

the BSCVA decreased from 0.15 to 0.04. Serous retinal detachment developed in both maculas. The visual acuity was very poor (light perception) on the left side because of the glaucoma. We applied intravitreal anti-VEGF (0.5 mg ranimzumab) injection twice into the right eye.

**Figure 1:** Optical coherence tomography of macula about the right eye of patient 1 before and after the intravitreal anti VEGF injection.

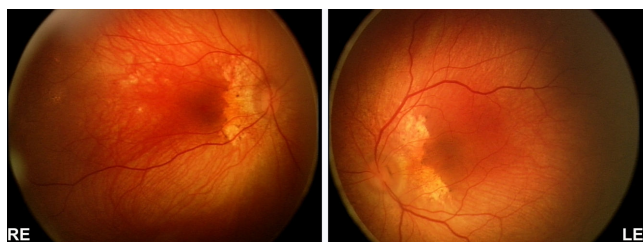
The central retinal thickness decreased, subretinal fluid disappeared (Figure 1), however only limited BSCVA improvement occurred (to 0.06 on the right eye). The limited visual outcome was probably caused by residual intraretinal fluid and structural damage of the photoreceptors due to the exudative process (Figure 2).



**Figure 2:** Fundus photograph about the right eye of Patient 1 (quality due to chronic uveitis) shows subretinal fibrosis.

## Case 2

A three weeks old boy was referred to us with bilateral congenital cataract and microphthalmos. We observed the signs of the Hallermann-Streiff syndrome with bird-like face, the presence of natal teeth, and skin atrophy on the nose. After cataract surgery (aspiration with bimanual technique) we prescribed spectacles. On the fundus we found pigment abnormalities (Figure 3) around the small optic nerve head and on the posterior pole. We did not find retinal detachment. We examined the boy regularly and found further RPE changes with time.



**Figure 3:** Fundus photograph about Patient 2 (RE: Right Eye, LE: Left Eye) shows smaller crowded optic nerve heads and irregular pigmentation.

Ocular findings of Patient 1 and 2 are summarized in Table 1.

## Discussion

Hallermann-Streiff syndrome is a rare congenital disorder that is characterized by malformations of the craniofacial region, proportionate short stature and in most cases with normal intelligence.

It was first described in 1893 by Aubry. In 1948 Hallermann, then in 1950 Streiff, and in 1958 Francois reported the clinical appearances of this syndrome: dyscephaly and bird-like face with hypoplastic mandible, dental anomalies (neonatal teeth, hypodontia or partial adontia), proportionate nanism, hypotrichosis, atrophy of the skin (particularly in the scalp and nasal region), bilateral microphthalmia, and congenital cataract. Francois reviewed the literature, and described the ocular anomalies in this syndrome (microphthalmia, congenital cataract, blue sclera, distichiasis, ptosis, anti-mongoloid palpebral fissure, indentation in the external part of the lower palpebral margin, atrophy of the iris, corneal bulging, amorphous retrolenticular membrane, posterior synechiae, vitreous floaters, elevated intraocular pressure, changes in the fundus: small disseminated pigmentations, foci of chorioretinal atrophy, peripapillary choroid atrophy, cherry-red macula surrounded by a grayish zone, pale disc, coloboma at the entrance of the optic nerve). Francois found bilateral microphthalmia in 17 of 22 cases, and bilateral congenital cataract in all cases [1]. In 1960 Falls and Schull named it Hallermann-Streiff syndrome [2]. Dallapiccola et al. found decreased level of serum Insulin-like Growth Factor 1 (IGF-1) [3]. Sometimes spontaneous cataract absorption can be observed [4]. The eye position in the orbit can be enophthalmic [5]. Entropion and trichiasis can lead to corneal complications. Glaucoma is described only in a few cases. The glaucoma can be observed in microphthalmic eyes. The other cause of higher intraocular pressure (as in the case of our first patient) can be the chronic anterior uveitis [6]. Only some articles published fundus photographs. Blair et al. published a case showing multiple areas of choroidal leakage on fluorescein angiogram of an 11 years old girl [7]. Serous retinal detachment is reported in some cases with this syndrome following cataract surgery [8-10]. Stewart et al. found abnormal scleral collagen in this syndrome like in other nanophthalmic cases [11]. Spontaneous or postoperative uveal effusion can occur in nanophthalmos. Barrier- and out flow abnormalities can lead to serous retinal detachment. The retinal pigment epithelium increases by proliferation and expansion between the third week and the fifth month of the development. The decrease of the average number of RPE per unit area follows between the fourth and ninth month of gestation. After the birth the RPE cell number remains at around 400,000 because of their mitotic weakness. The enlargement of RPE cells can be observed with the growth of the eye [12].

Almost all published cases of the disorder appear to have occurred randomly for unknown reasons. Approximately 200 cases have been reported in the literature. The target of therapy can be the prevention or treatment of the complications. The cause of the visual impairment can be microphthalmos, cataract, glaucoma or retinal abnormalities. Early treatment of the congenital cataract is important to ensure proper visual development. The long-term follow-up is crucial to recognize and treat the other ocular findings.

## Acknowledgements

The authors thank Peter Cerny Foundation for Curing Sick Babies for their help in documentation of fundus (RetCam Shuttle Version/ Clarity Medical System, USA). The authors are thankful to Huba JM Kiss MD for language check of the manuscript.

---

## References

1. Francois J (1958) A new syndrome; dyscephalia with bird face and dental anomalies, nanism, hypotrichosis, cutaneous atrophy, microphthalmia, and congenital cataract. *AMA Arch Ophthalmol* 60: 842-862.
2. Falls HF, Schull WJ (1960) Hallermann-Streiff syndrome, a dyscephaly with congenital cataracts and hypotrichosis. *Arch Ophthalmol* 63: 409-420.
3. Damiano Salpietro C, Briuglia S, Valeria Merlino M, Piraino B, Valenzise M, et al. (2004) Hallerman-Streiff syndrome: patient with decreased GH and insulin-like growth factor-1. *Am J Med Genet A* 125A: 216-218.
4. Lee MC, Choi IJ, Jung JW (2008) A case of Hallermann-Streiff syndrome with aphakia. *Korean Journal of Pediatrics* 51: 646-649.
5. Nucci P, de Conciliis C, Sacchi M, Serafino M (2011) Hallermann-Streiff syndrome with severe bilateral enophthalmos and radiological evidence of silent brain syndrome: a new congenital silent brain syndrome? *Clin Ophthalmol* 5: 907-911.
6. Hopkins DJ, Horan EC (1970) Glaucoma in the Hallermann-Streiff syndrome. *Br J Ophthalmol* 54: 416-422.
7. Blair NP, Brockhurst RJ, Lee W (1981) Central serous choroidopathy in the Hallermann-Streiff Syndrome. *Ann Ophthalmol* 13: 987-990.
8. Adyanthaya RS, Ying HS, Handa JT, Repka MX (2008) Macular retinal detachment in Hallermann-Streiff syndrome. *Arch Ophthalmol* 126: 271-273.
9. Nishina S, Suzuki Y, Azuma N (2008) Exudative retinal detachment following cataract surgery in Hallermann-Streiff syndrome. *Graefes Arch Clin Exp Ophthalmol* 246: 453-455.
10. Muthugaduru DJ, Sahu C, Ali MJ, Dalal A, Jalali S (2013) Report on ocular biometry of microphthalmos, retinal dystrophy, flash electroretinography, ocular coherence tomography, genetic analysis and the surgical challenge of Hallermann-Streiff syndrome. *Doc Ophthalmol* 127: 147-153.
11. Stewart DH 3rd, Streeten BW, Brockhurst RJ, Anderson DR, Hirose T, et al. (1991) Abnormal scleral collagen in nanophthalmos. An ultrastructural study. *Arch Ophthalmol* 109: 1017-1025.
12. Grierson I, Hiscott P, Hogg P, Robey H, Mazure A, et al. (1994) Development, repair and regeneration of the retinal pigment epithelium. *Eye (Lond)* 8 : 255-262.