

## UV-B impacts on morphology and retina of *Oncorhynchus mykiss* larvae

Dargaei, Z.<sup>1</sup>; Sharifpour, I.<sup>2\*</sup>; Zorriehzahra, J.<sup>2</sup>

Received: August 2012

Accepted: December 2013

### Abstract

The harmful effects of ultraviolet radiation on aquatic animals, due to ozone layer reduction, have been long studied in recent years. Exposure of Rainbow Trout larvae (*Oncorhynchus mykiss*) to Ultraviolet-B radiation (UV-B) at different doses (68.75  $\mu\text{w}/\text{cm}^2$  and 94.83  $\mu\text{w}/\text{cm}^2$  as the minimum and maximum dose of UV-B in natural environment respectively) for 15 minutes once a day in dark condition in comparison to control group (without any solar or UV) showed a wide variety of body abnormalities and eye damages. Body curvature, yolk sac edema, fin blistering, dwarfism, eye and head abnormalities as morphological malformations were revealed during the experiment, none of the malformations were observed in control group. Histopathological changes in retina such as irregular and discontinues pigmented epithelium, necrosis of photoreceptors and degeneration of nucleus layers confirmed the destructive effects of UV-B radiation in the eyes of Rainbow Trout. Such changes in larvae can be valid as bio-indicator for pollution and UV radiation and also introduce fishes as model for toxicological studies.

**Keywords:** Ultraviolet-B, Larvae, *Oncorhynchus mykiss*, Morphological malformatoion, Hitsopathological changes

---

1-Department of Marine Sciences, Tarbiat Modares University, P.O.Box: 46414-356, Noor, Iran

2-Iranian Fisheries Research Organization, P.O.Box: 13185-116, Tehran, Iran

\*Corresponding author's email: isharifpour@yahoo.com

## Introduction

Ultraviolet radiation (UV) according to wavelength can be subdivided into three types: UV-A (315-400 nm), UV-B (280-315 nm), and UV-C (100-280 nm) Arrigo (1995). Ozone layer protects the earth from penetrating of UV radiation. Over the last decades, due to stratospheric ozone depletion and global climate changes, the amount of UV with short wavelength reaching the earth's surface has increased (Meyer-Rochow, 2000; Palancar and Toselli, 2004). Because of high speed penetrating of UV in aquatic environments, these ecosystems are significantly vulnerable (Häkkinen and Oikari, 2004; Osman et al., 2010). Extensive research has shown that UV-B radiation has variety adverse effects on aquatic animals (Zagarese and Williamson, 2001; Sharma et al., 2005; Grad et al., 2003; Alemanni et al., 2003) ranging from molecular and tissue damages to population levels Armstrong et al. (2002). This dangerous radiation is able to contribute in a wide variety of malformations in aquatic animals (Alemanni et al., 2003; Grad et al., 2003; Sharma et al., 2005; Romansic et al., 2009; Mahmoud et al., 2009; Zagarese and Williamson, 2001). Previous studies have shown that light intensity induces severe damages in those organs, which are more exposed to UV radiation including eye Ham et al. (1976). Eye is an important organ in fish and plays a crucial role in many guiding behaviors such as foraging, mating and navigation. The vertebrate retina as a part of the central nervous system serves an effective function in vision by converting captured light rays to electrical impulses Ham et al. (1976). It seems

that exposure to UV-B radiation can cause irreparable damages in retina layers Lanum (1978).

Rainbow Trout (*Oncorhynchus mykiss*) is largely used in aquaculture in many countries. Rainbow Trout farming is an important contributor to the aquaculture industry in Iran. The economic importance of this species has tremendously increased in recent years as a result of its extensive use in aquaculture. Moreover, Rainbow Trout has been used in fundamental researches because it has a documented biology, short period of development and easy to reproduce all year round. Thus, it is a suitable model for study the embryonic stages of aquatic animals.

Due to less protection mechanisms at early larval stage, sensitivity of aquatic animals to all kind of environmental stressors is higher in this period than other growing stages Häkkinen et al. (2002).

The purpose of the present study is to focus on the adverse effects of UV-B on early developmental stages of *Oncorhynchus mykiss* in laboratory condition. We investigate morphological changes and retina structure before and after UV-B exposure.

## Materials and methods

New hatching larvae of *Oncorhynchus mykiss* were transferred from Sardar Jangal Aquaculture Center located in 3000 road to Iranian Coldwater Fishes Research Center (CFRC) at Tonekabon in Mazandaran Province in Iran. Fishes were maintained in tanks continually supplied with fresh water (9°C). After 24 hours acclimation to laboratory

condition, they were randomly divided into 3 groups (1000 larvae in each group) and transferred to three experiment tanks. Each unit was divided to three subunits (350 larvae in each subunit) as well. Aquaria were covered with black plastic sheets to prevent any effects resulting from exposing solar light. All fish specimens were kept in similar laboratory condition (temperature: 9-11°C, dissolved oxygen: 7.7 mg/L, pH: 8.4, conductivity: 51  $\mu\text{s}/\text{cm}$ ).

To attain a suitable level of UV-B radiation for the following laboratory study, the strength of UV-B in normal sunlight was calculated in the natural environment. Maximum intensity of UV-B in sunlight found in the natural environment was 94.83  $\text{uw}/\text{cm}^2$  and this dose of UV-B was used as the high dose of UV-B during the experiment Ghanizadeh Kazerouni and Khodabandeh (2010). The second group of specimens was exposed to the lowest level of UV-B intensity measured in the natural environment, which was 68.75  $\text{uw}/\text{cm}^2$  Ghanizadeh Kazerouni and Khodabandeh (2010). Larvae without any UV-B exposure served as the control group. The duration of exposure was 15 minutes. The fish were exposed to UV-B using a lamp (TUV/8W/G8T5/PHILIPS). Randomly

sampling was done 2 hours after UV-B exposure every day separately for both morphological and histological studies during 9 days experiment.


Malformations were recorded every day after exposure using a dissecting microscope (Motic DS-2).

Fixed specimens were dehydrated and subsequently embedded in paraffin. Sagittal and transverse serial sections were cut by rotary microtome (MICRODS 4055) at 4-7 $\mu\text{m}$  thicknesses. Hematoxylin and Eosin (H&E) stained sections were then studied using light microscope (Nikon, Japan) (Martoja and Martoja-Pierson, 1967; Ghanizadeh Kazerouni and Khodabandeh, 2010).

The data was analyzed by image tool, excel, one-way ANOVA and Tukey's test at 0.05 level of significance.

## Results


In the UV-B treatments five categories of deformities such as; body curvature, yolk sac edema, fin blistering, dwarfism, eye and head abnormalities in comparison with control group were observed (Fig. 1 a-f). Some of the affected larvae had combination of abnormalities.



**Figure 1: Developmental stage of *Oncorhynchus mykiss* showing (a) 1<sup>st</sup> day APFS (b) 4<sup>th</sup> day APFS (c) 6<sup>th</sup> day APFS (d) 8<sup>th</sup> APFS (e), (f) 9<sup>th</sup> APFS. YS = Yolk Sac, DF = Dorsal Fin, CD = Caudal Fin, VF = Ventral Fin, EY = Eye, APFS = After Post-Fertilization Stage**

Body curvature: The most frequently morphological malformation was notochord curvature. Different types of body curvature

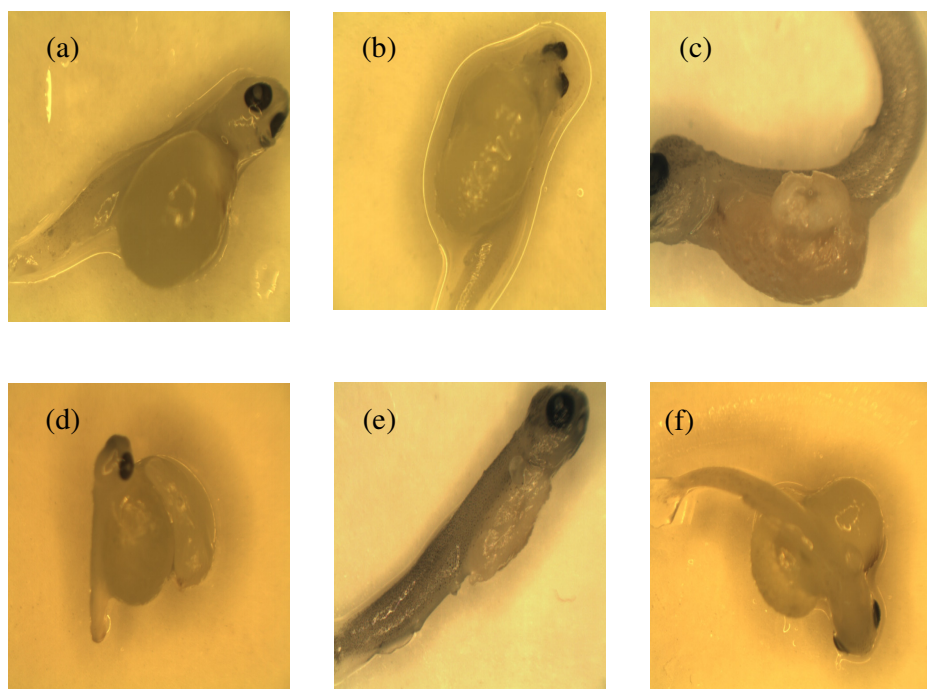
were observed such as; Lordosis (Fig. 2a), Kyphosis (Fig. 2b), Lateral flexion (Fig. 2c) and body curling (Fig. 2d).



**Figure 2: Notochord malformations (body curvature) of *Oncorhynchus mykiss* larvae after exposure to UV-B showing (a) lordosis (2<sup>nd</sup> day APFS exposed to lower dose of UV-B radiation 68.75  $\mu\text{w}/\text{cm}^2$ ), (b) kyphosis (2<sup>nd</sup> day AFPS exposed to lower dose of UV-B radiation 68.75  $\text{uw}/\text{cm}^2$ ), (c) lateral flexion (7<sup>th</sup> day APFS exposed to higher dose of UV-B radiation 94.83  $\text{uw}/\text{cm}^2$ ), (d) body curling (3<sup>rd</sup> day APFS exposed to higher dose of UV-B radiation 94.83  $\text{uw}/\text{cm}^2$ ). APFS= After Post Fertilization Stage, UV-B= ultraviolet-B**

*Yolk sac edema:* As can be seen in Figure 3, the fish larvae exposed to UV-B radiation showed different kinds of yolk sac deformities during the experiment. Balloon-shaped edema

(Fig. 3a), oval-shaped edema (Fig. 3b) and irregular-shaped yolk sac (Figs. 3c-f) were observed.



**Figure 3: Yolk sac edema in the *Oncorhynchus mykiss* larvae after exposure to UV-B showing (a) Balloon- shaped edema (2<sup>nd</sup> day APFS exposed to lower dose of UV-B radiation 68.75 uw/cm<sup>2</sup>), (b) Oval- shaped edema (3<sup>rd</sup> day APFS exposed to lower dose of UV-B radiation 68.75 uw/cm<sup>2</sup>), (c,d,e,f) Irregular-shaped edema (9<sup>th</sup>, 2<sup>nd</sup>, 8<sup>th</sup> and 2<sup>nd</sup> day APFS to higher dose of UV-B 94.83 uw/cm<sup>2</sup> respectively). APFS= After Post-Fertilization Stage, UV-B= Ultraviolet-B**

*Fin blistering:* Compared with control group, the fins were degenerated and blistered in UV-B treatments (Figs. 4a-c).


*Eye and head abnormalities:* The fish larvae affected by UV-B radiation showed wide variety of abnormalities on head and eye (Fig. 5). In some cases in higher dose of UV-B 94.83 uw/cm<sup>2</sup>, head was divided in two parts (Fig. 5a). The lack in properly growth of eye and head (Figs. 5b-d) were recorded.

*Dwarfism:* Dwarfism was observed in UV-B treatments. The fish larvae in two UV exposed groups did not grow very well and compared with unexposed group were much shorter in the same development stages (Figs. 6a-c).

In control group, histological micrographs of the eye in larvae of *Oncorhynchus mykiss* showed five distinct layers (Figs. 7a,b). In this group, larvae had healthy eyes with well-

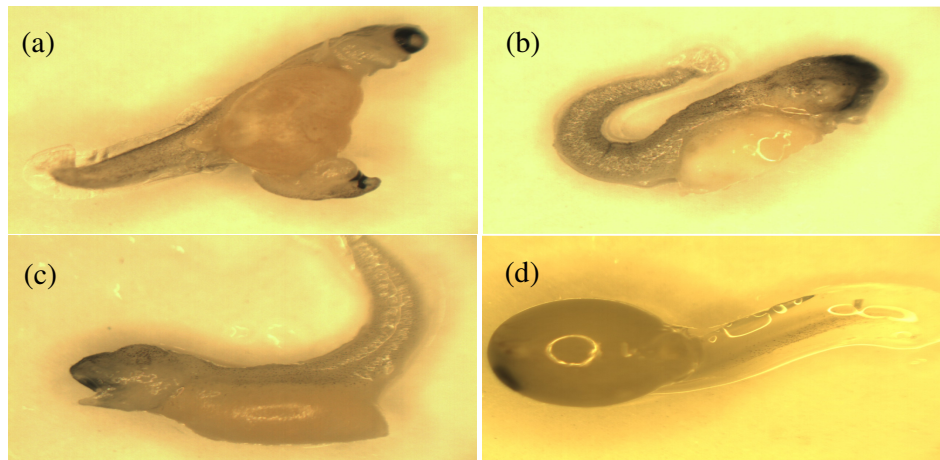
differentiated layers, uniform pigment epithelium (Fig. 7 c,d). In contrast, the exposed larvae showed the different degree of damages correlated with UV-B doses. The intensity of damages in higher dose of UV-B was more than lower dose. The irregular and discontinues pigmented epithelium was recorded in UV-B treatments (Fig. 8 a,b). The

photoreceptors layers showed a high degree of necrosis (Fig. 8 a) and also the length of these cells decreased during the experiment. In the larvae affected by UV-B radiation, the inner and outer nucleus layer and ganglion cells exhibited degeneration as well as necrosis (Fig. 8 c-f).




**Figure 4: Fin blistering in the *Oncorhynchus mykiss* larvae exposed to UV-B showing (a) fin blistering (5<sup>th</sup> day APFS exposed to higher dose of UV-B radiation 94.83 uw/cm<sup>2</sup>), (b) fin blistering (7<sup>th</sup> day APFS exposed to lower dose of UV-B radiation 68.75 uw/cm<sup>2</sup>), (c) fin blistering (9<sup>th</sup> day APFS exposed to higher dose of UV-B radiation 94.83 uw/cm<sup>2</sup>), APFS= After Post-Fertilization Stage, UV-B= Ultraviolet-B**

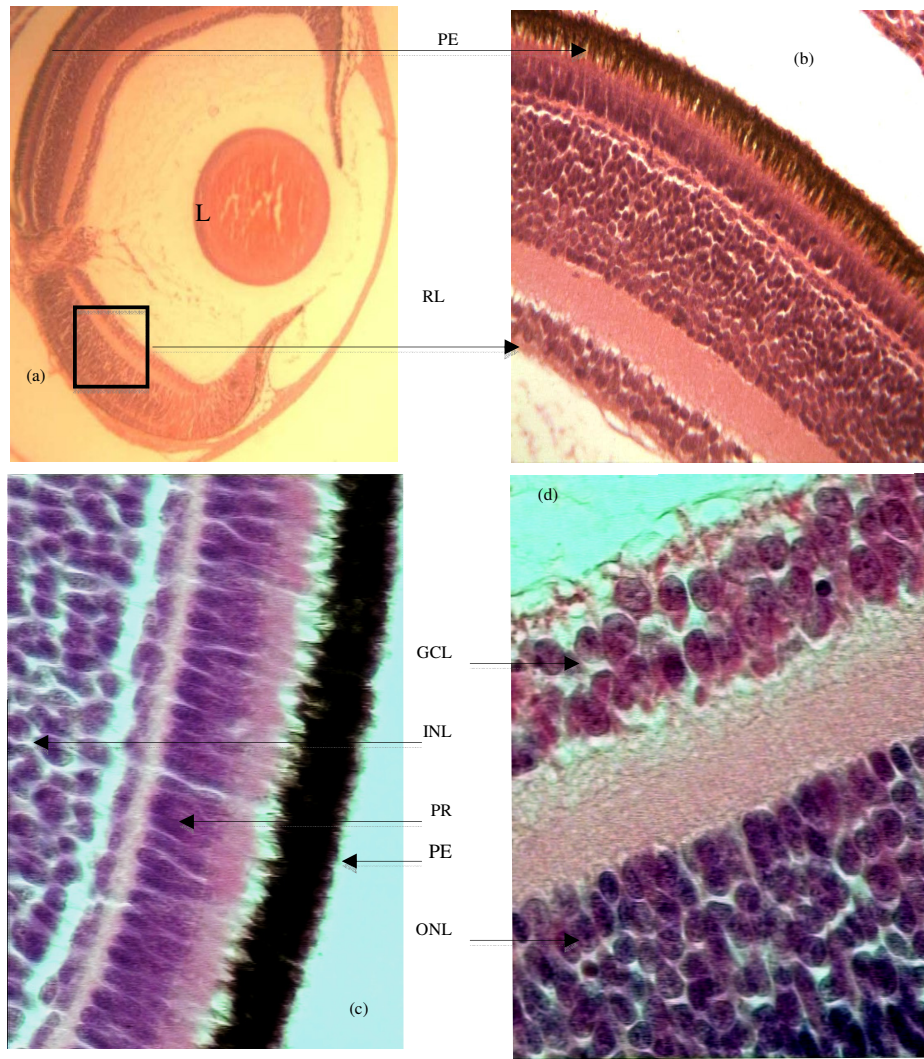




**Figure 5:** Head and eye abnormalities in the *Oncorhynchus mykiss* larvae exposed to UV-B showing, (a) eye deformities (5th day APFS exposed to higher dose of UV-B radiation 94.83 uw/cm<sup>2</sup>), (b) eye damage (7th day APFS exposed to higher dose of UV-B radiation 94.83 uw/cm<sup>2</sup>), (c) eye damage (4th day APFS exposed to higher dose of UV-B radiation 94.83 uw/cm<sup>2</sup>), (d) head and eye deformities (2nd day APFS exposed to lower dose of UV-B radiation 68.75 uw/cm<sup>2</sup>), APFS= After Post-Fertilization Stage, UV-B= Ultraviolet-B

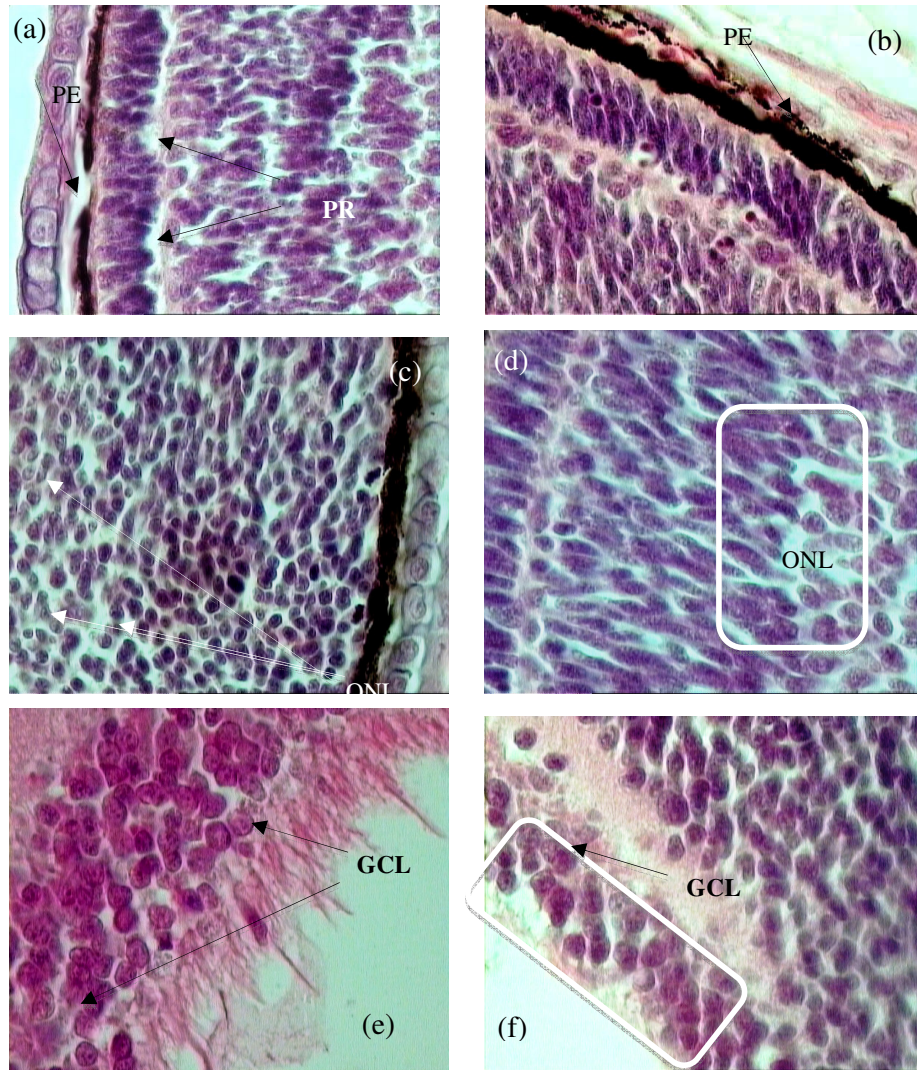


**Figure 6.** Dwarfism in the *Oncorhynchus mykiss* larvae after exposure to UV-B showing (a) dwarfism (2nd day APFS exposed to lower dose of UV-B radiation 68.75uw/cm<sup>2</sup>), (b) dwarfism (5th day APFS exposed to lower dose of UV-B radiation 68.75uw/cm<sup>2</sup>), (c) Dwarfism (5th day APFS exposed to higher dose of UV-B radiation 94.83uw/cm<sup>2</sup>), APSF= After Post-Fertilization Stage, UV-B= Ultraviolet-B



**Figure 7:** Histology of eye in the *Oncorhynchus mykiss* larvae in control group showing (a) sagittal section through the eye, (b,c,d) sagittal section through retinal layers, PE= pigment epithelium, L= lens, RL= retina layers, GCL= ganglion cell layer, INL= inner nucleus layer, PR= photoreceptor, ONL= outer nucleus layer





**Figure 8: Histological lesion of the eye in *Oncorhynchus mykiss* larvae after exposure to UV-B showing, (a) sagittal section through retinal layers exposed to lower dose of UV-B radiation  $68.75 \text{ uw/cm}^2$ , (b) sagittal section through retinal layers exposed to higher dose of UV-B radiation  $94.83 \text{ uw/cm}^2$ , (c) sagittal section through retinal layers exposed to lower dose of UV-B radiation  $68.75 \text{ uw/cm}^2$ , (d) sagittal section through retinal layers exposed to higher dose of UV-B radiation  $94.83 \text{ uw/cm}^2$ , (e) sagittal section through retinal layers exposed to lower dose of UV-B radiation  $68.75 \text{ uw/cm}^2$ , (f) sagittal section through retinal layers exposed to higher dose of UV-B radiation  $94.83 \text{ uw/cm}^2$ , PE= pigment epithelium, L= lens, RL= retina layers, GCL= ganglion cell layer, INL= inner nucleus layer, PR= photoreceptor, ONL= outer nucleus layer**

## Discussion

The negative effects of UV-B exposure are well-documented phenomena, and aquatic environments and species are important targets for this radiation (Alemanni et al., 2003; Grad et al., 2003; Häder et al., 2007; Häder et al., 1998; Krapp et al., 2009; Sinha and Häder, 2002; Zepp et al., 2007).

The embryos and larvae of many aquatic species are more sensitive to environmental stressors, like increased UV-B incidence, than are individuals in late life stages (Bancroft et al., 2007; Charron et al., 2000). The present results indicate the severe UV-B effects in morphology and histology of *O. mykiss*. Our data shows that UV-B dose employed in this study has very severe harmful effects during embryos stages, which is similar to other studies (Bonaventura et al., 2006; Nahon et al., 2010). It was reported in Bonaventura et al. (2006) study that after exposing embryos of the sea urchin (*Paracentrotus lividus*) to UV-B radiation, the developmental stages delays and severe morphogenetic abnormalities are observed. Nahon et al. (2009) also demonstrated that embryos of the Sea urchin (*Sphaerechinus granularis*) developed more slowly after UV-B irradiation.

UV radiation of solar or artificial origin carries potential risks to morphology and histology of different fish organs (Setlow and Woodhead, 1994; Setlow et al., 1993; Mahmoud et al., 2009). Our results also show that UV-B increases the prevalence of deformities in Rainbow Trout larvae including eye and head damages, yolk sac edema, body curvature of larvae, larval dwarfism, notochord collapse, histopathological changes in retina.

Many deformities involved with notochord produced during the exposure to UV-B, which is similar to the results of Blaustein et al. (1995) on long Toed salamander (*Ambystoma macrodactylum*) embryos exposed to ambient UV-B. Romansic et al. (2009) also suggested that UV-B radiation causes many body abnormalities in Cascades frog (*Rana cascadae*) larvae involved with tail such as lateral flexure and body curling. Considerable amount of research has been conducted addressing similar observational damages by different toxicants in many aquatic species (Weis and Weis, 1977; Marty et al., 1990; McFadzen et al., 2000; Miner et al., 2000; Chan et al., 2001; Nguyen and Janssen, 2002; Browman et al., 2003; Hallare et al., 2005; Osman et al., 2010). The stress-induced changes were more pronounced in the early embryonic stages of fishes (Hallare et al., 2005; Osman et al., 2010; Mekki et al., 2010). These damages could be due to the absorption of UV-B by biomacromolecules like proteins and nucleic acids (internal UV-photon absorber) Obermüller et al. (2007) and indirect genotoxic and cytotoxic effects of UV via sensitizers Yu et al. (2006). These photobiological activities reflected by morphological and histological changes are mediated by reactive oxygen species in addition to mutagenic oxidative DNA damage Tarozzi et al. (2005). The UV-B induced morphological and pathological changes recorded in the present work confirm the photo inhibition of the antioxidant defense system of UV-B-induced Rainbow Trout larvae.

This study focuses mostly on the effects

of Ultraviolet radiation on Rainbow Trout as an economic species, specifically on eye as an important organ in fish. Because Rainbow Trout is a cosmopolitan fish and the effects of UV-B radiation on this species have not been studied so far. This research can be used as a model to evaluate the effects of UV radiation on aquatic environments.

### Acknowledgments

The research was funded by Tarbiat Modares University and Ministry of Science, Research and Technology of I.R.IRAN. We thank the Iranian Coldwater Fishes Research Center (CFRC) for providing aquaculture facilities and field measurements. We also thank Dr. Saber Khodabandeh for his helpful advices in conducting histological experiments.

### References

- Alemanni, M. E., Lozada, M. and Zagarese, H. E., 2003.** Assessing sublethal effects of ultraviolet radiation in juvenile rainbow trout (*Oncorhynchus mykiss*), *Photochem Photobiol Sciences*, 2(8), 867-870.
- Armstrong, T. N., Reimschuessel, R. and Bradley, B. P., 2002.** DNA damage, histological changes and DNA repair in larval Japanese medaka (*Oryzias latipes*) exposed to ultraviolet-B radiation. *Aquatic Toxicology*, 58(1), 1-14.
- Arrigo, K. R., 1995.** Impact of ozone depletion on phytoplankton growth in the Southern Ocean: large-scale spatial and temporal variability. *Mar. Ecol. Prog. Ser.*, 42(5).
- Bancroft, B. A., Baker, N. J. and Blaustein, A. R. 2007.** Effects of UVB radiation on marine and freshwater organisms: a synthesis through meta-analysis. *Ecology Letters*, 10(4), 332-345.
- Blaustein, A. R., Edmond, B., Kiesecker, J. M., Beatty, J. J. and Hokit D. G., 1995.** Ambient ultraviolet radiation causes mortality in salamander eggs. *Journal of Applied Ecology*, 5(3), 740-743.
- Bonaventura, R., Poma, V., Russo, R., Zito, F. and Matranga V., 2006.** Effects of UV-B radiation on development and hsp70 expression in sea urchin cleavage embryos. *Marine Biology*, 149(1), 79-86.
- Browman, H. I., Vetter, R. D., Rodriguez, C. A., Cullen, J. J., Davis, R. F., Lynn, E. and St Pierre, J., 2003.** Ultraviolet (280–400 nm)–induced DNA Damage in the Eggs and Larvae of *Calanus finmarchicus* G.(Copepoda) and Atlantic Cod (*Gadus morhua*). *Photochem Photobiol*, 77(4), 397-404.
- Chan, J., Robinson, E. S., Atencio, J., Wang, Z., Kazianis, S., Coletta, L. D., Nairn, R. S, and McCarrey, J. R., 2001.** Characterization of the CDKN2A and ARF genes in UV-induced melanocytic hyperplasias and melanomas of an opossum (*Monodelphis domestica*). *Molecular Carcinogenesis*, 31(1), 16-26.
- Charron, R. A., Fenwick, J. C., Lean, D. R. and Moon, T. W., 2000.** Ultraviolet-B Radiation Effects on Antioxidant Status and Survival in the Zebrafish, *Brachydanio rerio*. *Photochem Photobiol, Photochem Photobio*, 72(3), 327-333.
- Ghanizadeh Kazerouni, E. and Khodabandeh, S., 2010.** Effects of ultraviolet radiation on skin structure and ultrastructure in Caspian Sea Salmon, *Salmo trutta caspius*, during alevin

- stage. *Toxicological and Environmental Chemistry*, 92(5), 903-914.
- Grad, G., Burnett, B. J. and Williamson, C. E., 2003.** UV Damage and Photoreactivation: Timing and Age are Everything. *Journal of Photochemistry and Photobiology*, 78(3), 225-227.
- Häder, D., Kumar, H., Smith, R. and Worrest, R., 2007.** Effects of solar UV radiation on aquatic ecosystems and interactions with climate change. *Journal of Photochemistry and Photobiology*, 6(3), 267-285.
- Häder, D., Kumar, H., Smith, R. and Worrest, R., 1998.** Effects on aquatic ecosystems In: Environmental Effects of Ozone Depletion. United Nations Environment Programme. *Journal of Photochemistry and Photobiology*, 46(1), 53-68.
- Häkkinen, J. and Oikari, A., 2004.** A field methodology to study effects of UV radiation on fish larvae. *Water Research*, 38(12), 2891-2897.
- Häkkinen, J., Vehniäinen, E., Ylönen, O., Heikkilä, J., Soimasuo, M., Kaurola, J., Oikari, A. and Karjalainen, J., 2002.** The effects of increasing UV-B radiation on pigmentation, growth and survival of coregonid embryos and larvae. *Environmental Biology of Fishes*, 64(4), 451-459.
- Hallare, A., Schirling, M., Luckenbach, T., Köhler, H. and Triebkorn, R., 2005.** Combined effects of temperature and cadmium on developmental parameters and biomarker responses in zebrafish (*Danio rerio*) embryos. *Journal of Thermal Biology*, 30(1), 7-17.
- Ham, W. T., Mueller, H. A. and SLINEY, D. H., 1976.** Retinal sensitivity to damage from short wavelength light. *Letter to nature*, 260, 153-155.
- Krapp, R. H., Bassinet, T., Berge, J., Pampanin, DM. and Camus, L., 2009.** Antioxidant responses in the polar marine sea-ice amphipod *Gammarus wilkitzkii* to natural and experimentally increased UV levels. *Aquatic Toxicology*, 94(1), 1-7.
- Lanum, J., 1978.** The damaging effects of light on the retina. Empirical findings, theoretical and practical implications. *Survey of Ophthalmology*, 22(4), 221-249.
- Mahmoud, U. M., Mekkawy, I. A. and Sayed, A. E. H., 2009.** Ultraviolet radiation-A (366nm) induced morphological and histological malformations during embryogenesis of *Clarias gariepinus* (Burchell, 1822). *Journal of Photochemistry and Photobiology B*, 95(2), 117-128.
- Martoja, R. and Martoja-Pierson, M., 1967.** Initiation aux techniques de l'histologie animale.
- Marty, G. D., Hinton, D. E. and Cech, J. J., 1990.** Effect of incubation temperature on oxygen consumption and ammonia production by Japanese medaka, *Oryzias latipes*, eggs and newly hatched larvae. *Environmental Toxicology and Chemistry*, 9(11), 1397-1403.
- McFadzen, I., Baynes, S., Hallam, J., Beesley, A. and Lowe, D., 2000.** Histopathology of the skin of UV-B irradiated sole (*Solea solea*) and turbot (*Scophthalmus maximus*) larvae. *Marine Environmental Research*, 50(1), 273-277.
- Mekkawy, I. A., Mahmoud, U. M., Osman, A. G. and Sayed, AEH., 2010.** Effects of ultraviolet A on the activity of two metabolic enzymes, DNA damage and lipid peroxidation during early developmental stages of the African catfish, *Clarias gariepinus* (Burchell, 1822). *Fish Physiology and Biochemistry*, 36(3), 605-626.

- Meyer-Rochow, V. B., 2000.** Risks, especially for the eye, emanating from the rise of solar UV-radiation in the Arctic and Antarctic regions. *International Journal of Circumpolar Health*, 59(1), 38-51.
- Miner, B. G., Morgan, S. G. and Hoffman, J. R., 2000.** Postlarval chromatophores as an adaptation to ultraviolet radiation. *Journal of Experimental Marine Biology and Ecology*, 249(2), 235-248.
- Nahon, S., Charles, F., Lantoine, F., Vétion, G., Escoubeyrou, K., Desmalades, M. and Pruski, A. M., 2010.** Ultraviolet radiation negatively affects growth and food quality of the pelagic diatom *Skeletonema costatum*. *Journal of Experimental Marine Biology and Ecology*, 383(b), 164-170.
- Nguyen, L. and Janssen, C., 2002.** Embryo-larval toxicity tests with the African catfish (*Clarias gariepinus*): comparative sensitivity of endpoints. *Archives of Environmental Contamination and Toxicology*, 42(2) 256-262.
- Obermüller, B., Puntarulo, S. and Abele, D., 2007.** UV-tolerance and instantaneous physiological stress responses of two Antarctic amphipod species *Gondogeneia antarctica* and *Djerboa furcipes* during exposure to UV radiation. *Marine Environmental Research*, 64(3), 267-285.
- Osman, A. G., Kouth, M. and Sayed, A. E. H., 2010.** Use of hematological parameters to assess the efficiency of quince (*Cydonia oblonga* Miller) leaf extract in alleviation of the effect of ultraviolet-A radiation on African catfish *Clarias gariepinus* (Burchell, 1822). *Journal of Photochemistry and Photobiology*, 99(1), 1-8.
- Palancar, G. G. and Toselli, B. M., 2004.** Effects of meteorology and tropospheric aerosols on UV-B radiation: a 4-year study. *Atmospheric Environment*, 38(17), 2749-2757.
- Romansic, J. M., Waggener, A. A., Bancroft, B. A. and Blaustein, A. R., 2009.** Influence of ultraviolet-B radiation on growth, prevalence of deformities, and susceptibility to predation in Cascades frog (*Rana cascadae*) larvae. *Hydrobiologia*, 624(1) 219-233.
- Setlow, R. B. and Woodhead, A. D., 1994.** Temporal changes in the incidence of malignant melanoma: explanation from action spectra. *Mutation Research*, 307(1), 365-374.
- Setlow, R. B., Grist, E., Thompson, K. and Woodhead, A. D., 1993.** Wavelengths effective in induction of malignant melanoma. *Proceedings of the National Academy of Sciences*, 90(14), 6666-6670.
- Sharma, J., Masuda, R. and Tanaka, M., 2005.** Ultrastructural study of skin and eye of UV-B irradiated ayu *Plecoglossus altivelis*. *Journal of Fish Biology*, 67(6), 1646-1652.
- Sinha, R. P. and Häder, D., 2002.** UV-induced DNA damage and repair: a review. *Journal of Photochemistry and Photobiology*, 1(4), 225-236.
- Tarozzi, A., Marchesi, A., Hrelia, S., Angeloni, C., Andrisano, V., Fiori, J., Cantelli-Forti, G. and Hrella, P., 2005.** Protective Effects of Cyanidin-3-O- $\beta$ -glucopyranoside Against UVA-induced Oxidative Stress in Human Keratinocytes. *Photochem Photobiol*, 81(3) 623-629.
- Weis, P. and Weis, J. S., 1977.** Methylmercury teratogenesis in the killifish, *Fundulus heteroclitus*. *Teratology*, 16 (3), 317-325.



- Yu, H., Kaufman, Y., Chin, M., Feingold, G., Remer, L., Anderson, T., Balkanski, Y., Bellouin, N., Boucher, O. and Christopher, S., 2006.** A review of measurement-based assessments of the aerosol direct radiative effect and forcing. *Atmospheric Chemistry and Physics*, 6(3), 613-666.
- Zagarese, H. E. and Williamson, C. E., 2001.** The implications of solar UV radiation exposure for fish and fisheries. *Fish Fish*, 2(3), 250-260.
- Zepp, R., Erickson, Iii. D., Paul, N. and Sulzberger, B., 2007.** Interactive effects of solar UV radiation and climate change on biogeochemical cycling. *Journal of Photochemistry and Photobiology*, 6(3), 286-300.