

## Study of pathological effects of an organic germicide bathing on rainbow trout

Afzali F.<sup>1</sup>; Sharifpour I.<sup>2,\*</sup>; Soltani M.<sup>3</sup>

Received: July 2011      Accepted: August 2012

### Abstract

The aim of this study was evaluation an organic germicide (Aquagerm) histological affects on Rainbow trout (*Oncorhynchus mykiss*) vital tissues. This new disinfectant is an aquatic antiseptic and mixed-oxidant disinfectant which is produced for the first time in Iran. This new product mechanism is based on oxidant properties of pro-sulphate which attack crucial structures of pathogens. In this study, forty healthy fish were selected and divided in to two groups as control and treatment. The treatment group was treated with 1/2000 concentration of organic germicide for 45 min (according to the manufacturing protocols). At 4, 8, 12, 24, 48 and 96 h after bath challenge, 5 specimens were collected from treatment and one from control group. Gill, brain, kidney, and liver of all fish were sampled. Some histological damages such as edema and detachment of basic layer in secondary gill filaments were observed in gill microscopy results. The most important histological changes observed in the brain were congestion of some blood vessels. Furthermore, some evidences of increased melano-macrophage, glomerular shrinkage, and dilatation in Bowman capsules were recorded whereas no any damages were observed in liver. All histological changes removed after 48-96 h. It could be concluded that, all pathological observations in this study were just a natural response of fish body after exposing to the new disinfectant, and they were not recorded any damages like those which happen against hazardous chemicals. It seems that there is no risk associated with the consumption of this disinfectant for the fish tissues.

**Keywords:** Rainbow trout, Organic germicide, Kidney, Liver, Gill, Brain, Histopathology

---

1- Islamic Azad University, Science And Research Branch, Tehran,Iran

2- Iranian Fisheries Research Organization, Tehran, Iran

3- Department of Aquatic Animal Health, Faculty of Veterinary Medicine University of Tehran,P.O.Box:14155-6453 , Tehran, Iran

\*Corresponding author's email: isharifpour@yahoo.com

## **Introduction**

Artificial reproduction of aquatic food specially fish and shrimp, seems to be strongly needed these days due to the rapid growth of world population and reducing in aquatic resources.

There is a need to apply severe management to control aquaculture diseases, improving sea food industries and increasing aquatic production in the country. On the other hand, due to a variety of reasons, like water restrictions and intensive fish culture with the poor quality in farm managements, it is predicted to have irretrievable losses in the future. For this aim, there is a vast range of disinfectants widely used in the control and reduction of pathogens Alborali et al. (1997).

Healthy fish usually are exposed to potentially pathogenic factors that cause bacterial, viral, fungal and parasitic diseases in different stages of aquatic animal life Fatemi and Mirzargar (2007). The basis of competent management is proper use of chemical substances to reduce or eliminate pathogenic factors Cawley (1999).

Given that Malachite Green (MG) is used for disinfection of eggs in fish farms, researchers believe that this material accumulates in fish muscle Cha et al. (2001). Therefore, the application of MG is banned by the Food and Drug Organization of America Schreier et al. (1996). It is clear that, the consumption of this substance must be stopped gradually

and it is needed to establish sufficient studies and field experiment plan to replace other materials which have preventive effect on the fungus growth and also not having the negative effects of Malachite Green like organic germicide.

The organic acid tested in this study (Aquagerm) is an antiseptic compound containing sulfate and organic acids which is produced for the first time in Iran. This solvent material is prescribed for cleaning and disinfecting of pool and transferring equipment of the fish. This is a multi-purpose disinfectant and antiseptic and little research has been done on the properties of this material Saeedi et al. (2008).

Considering the non-toxic and non-carcinogenic effects of this new product and the necessity for applying new disinfectants in the country that can replace existing toxic and carcinogenic ones such as Malachite Green, this research is focused on the pathological effects of organic germicide on some vital organs of Rainbow trout to determine the probable influences of its concentration. In this study the pathologic effects of organic germicide on important organs of fish is investigated by bath challenge to complete our findings and knowledge of this product and also provide a suitable and reliable reference for assessment and compare it with other disinfectants.

## **Materials and methods**

This study was done on rainbow trout fish, French race, in a fish farm located in

Moojen village, Shahrood, Iran. Fish were kept in a healthy condition with no previous record of disease. The farm water source was a flume with a flow rate of 38 lit/sec. Farm facilities were included 5

rectangular pools 2.5×28 m with a height of 2 m and water level of 90-120cm. Fish weights were 200±100 which were cultured for 8 to 9 months.

**Table 1 : Physical and Chemical Characteristics of Water**

| Oxygen Inlet<br>(mg/lit) | Oxygen Outlet<br>(mg/lit) | pH  | Nitrite<br>(ppm) | Nitrate<br>(ppm) | Ammonium<br>(ppm) | Water Temp.<br>(°C) |
|--------------------------|---------------------------|-----|------------------|------------------|-------------------|---------------------|
| 8                        | 6                         | 8.1 | ≥0.2             | 5-9              | ≥0.1              | 12                  |

Forty rainbow trout fish with an average weight of 115 g were sampled from under study farm. 20 fish were transferred to the control pond and the other 20 fish kept in the treatment pond. Dehydration and sustenance conditions were similar in two groups of ponds during 7 day period, with proper nutrition, aeration and filtration. Feeding was stopped 24 h before sampling. Treatment group fish were treated with organic germicide 1/2000 concentration for 45 min (according to the manufacturing protocol). For each sampling, 5 fish from treatment pond and one from control pond were anaesthetized with clove essence 100-150 ppm and gill, brain, liver and kidney were sampled and fixed in 10% formalin. The sampled tissues were kept for at least 24 hours in the formalin solution to complete fixation process. Sampling was done in 4, 8, 12, 24, 48 and 96 h after bath challenge and fixed specimens were transferred to the laboratory immediately after experiment. Two slides from each organ were prepared for pathological studies. Microscopic section preparation was done according to standard methods (Poosti and Adibmoradi, 2001).

Briefly, fixed tissues were first decalcified, dehydrated then embedded in paraffin wax. Paraffin blocks were sectioned at 5 µm with a rotary microtome. Then slides were stained with haematoxylin and eosin (H & E). All the prepared slides were examined under optical microscope and photography was performed in two vertical and horizontal sections.

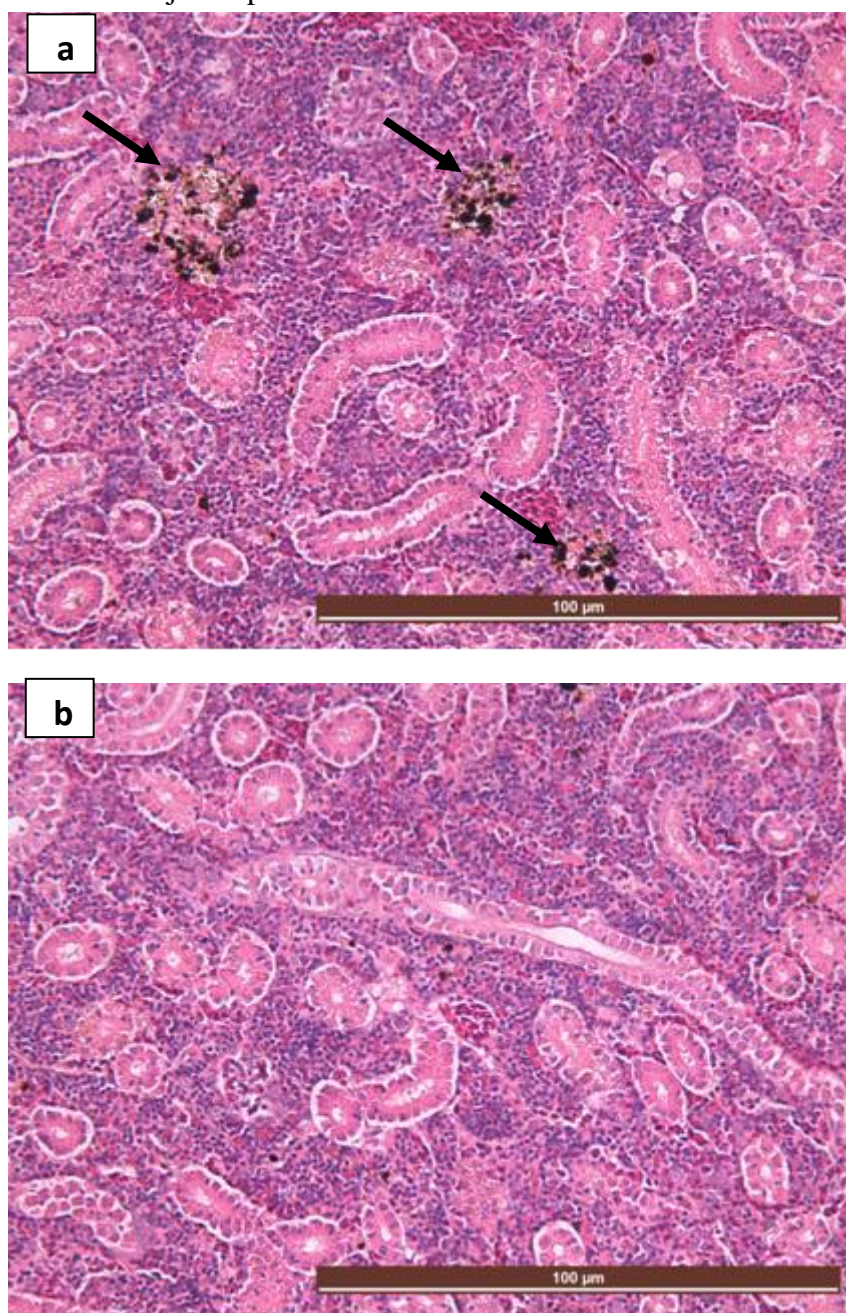
## Results

### *Clinical signs*

All fish were monitored for 96 h after bathing with disinfectant. There were no changes in swimming behaviour in fish nor in experimental group neither in control group and no mortality observed. The histopathological results show some changes in some organs as follow:

*Kidney:* generally, it was not observed any serious tissue damages in interstitial tissue, glomerules and renal tubules of kidney nor in treatment group neither in control groups at 4, 8, 12, 24, 48 and 96 h after bath challenge study with Organic germicide. However, in a few specimens of treatment group, increasing in melano-macrophage centers, glomerule

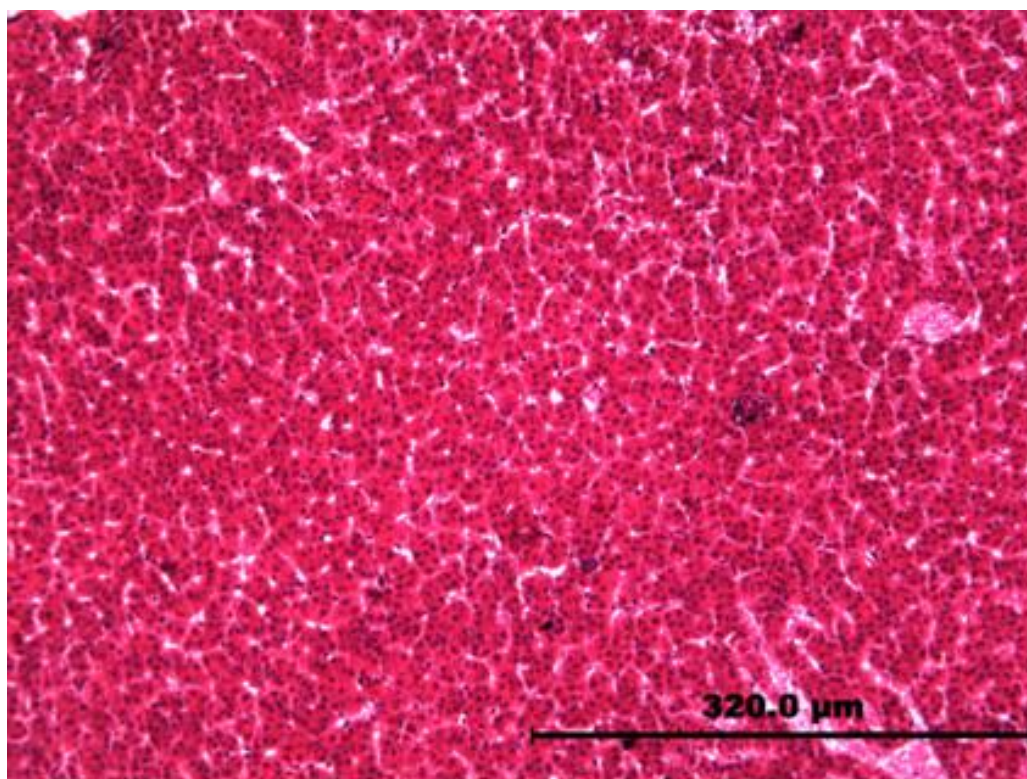
shrinkage and dilation of Bowman capsules were observed just up to 24 h after bath challenge (Fig. 1).



**Figure 1: Kidney histological sections of rainbow trout. (a) Showing increasing in melano-macrophage centers at 24 h after bath challenge with organic germicide (arrows) (b) Fish kidney with no damages after 96 h (H&E, X20).**

*Liver:* liver in both treatment and control groups did not show any tissue damages at 4, 8, 12, 24, 48 and 96 h after bath challenge with Organic germicide. It was

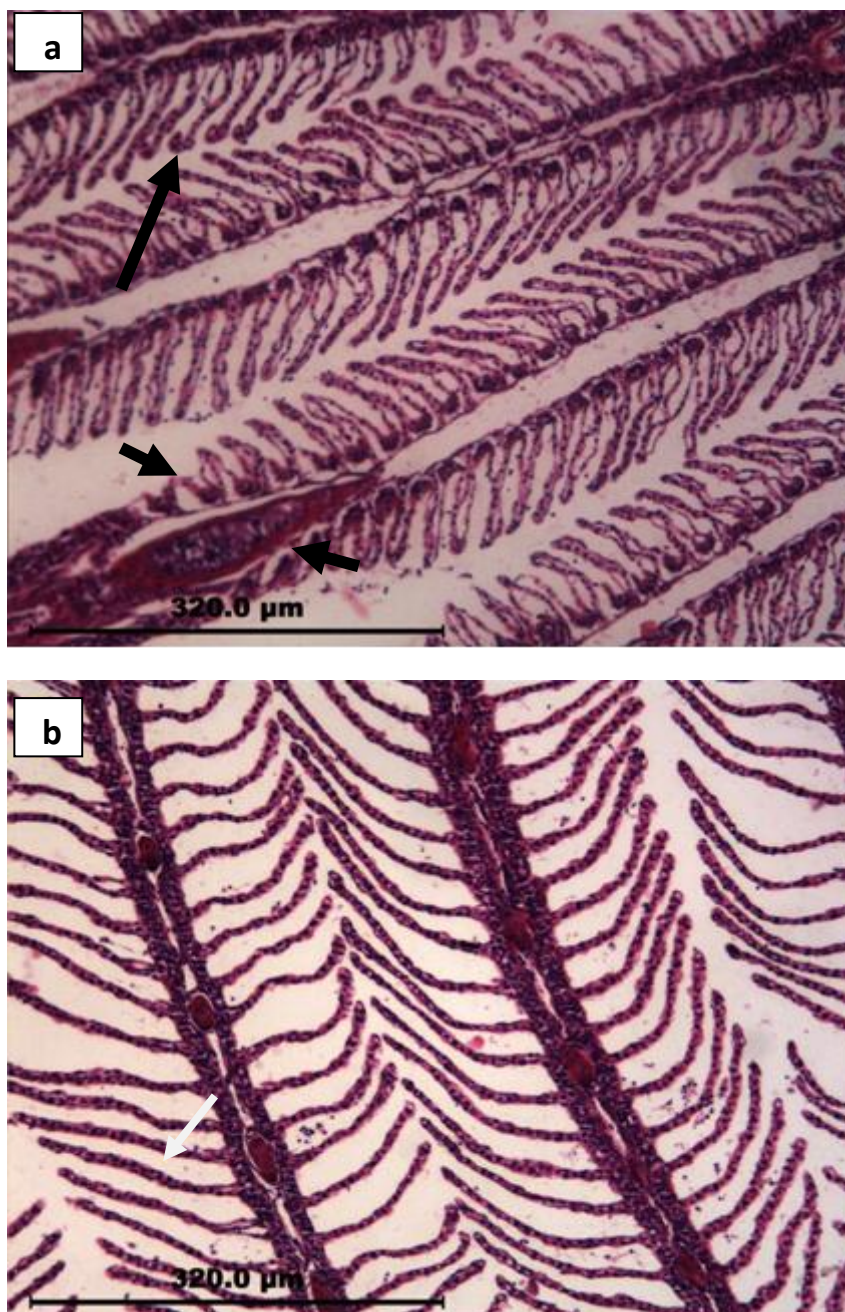
not observed any histological changes in the hepatocyte, bile ducts, blood and lymph vessels (Fig. 2).



**Figure 2: Liver histological sections of rainbow trout showing no damages at 24 h after bath challenge with organic germicide (H&E, X10).**

*Gill:* Gill samples from treatment group at 4, 8, 12, 24 and 48 h after bath challenge with Organic germicide were showed some lesions, swelling and detachment of the basic layers in secondary lamellae, aneurysm or telangiectasia, appearance of clavate filaments in secondary lamellae, hyperemia and shortening in secondary

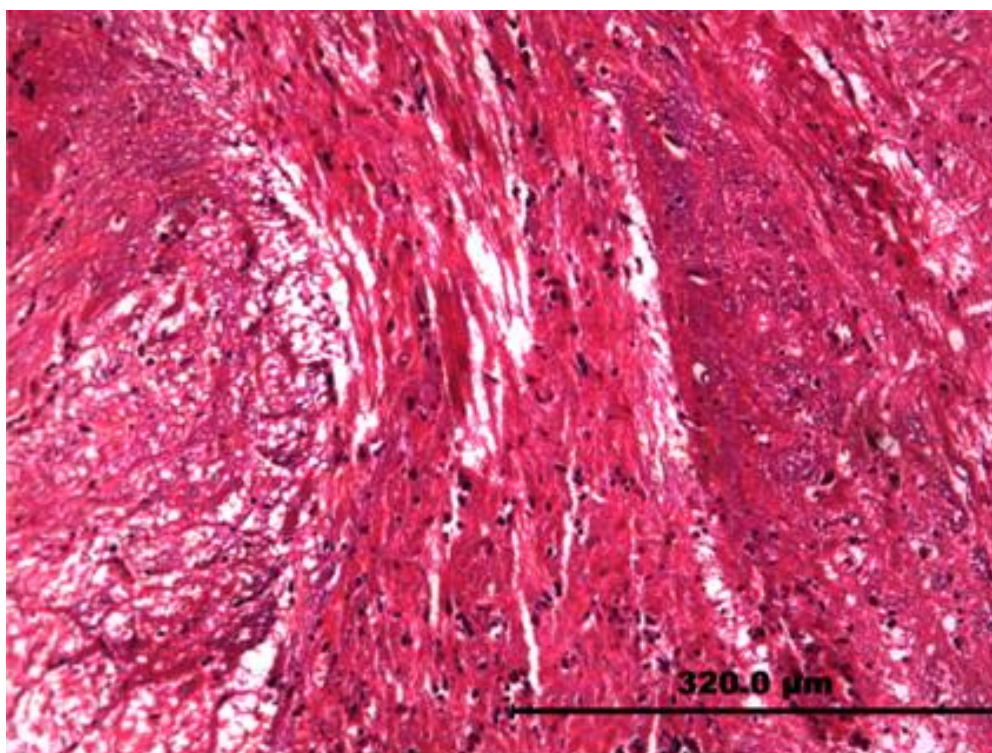
lamellae, swelling and detaching of covering layers (Epithelial lifting), inflation and disorder in the structure of gill lamellae. All fish were recovered after 96 h and fish in control group appeared normal and no abnormality were observed (Fig. 3).



**Figure 3:**Gill histological sections of rainbow trout. (a) Showing Hyperemia and Shortening in secondary lamellae (shorter arrows), Aneurysm and telangiectasia in secondary lamellae (longer arrow) at 24 h after bath challenge with organic germicide. (b) Gill with no damages after 96 h (H&E, X10).

*Brain:* brain samples from both treatment and control groups at 4, 8, 12, 24, 48 and 96 h after bath challenge with Organic germicide were not showed serious tissue

damages. Slight hyperemia in some vessels of molecular and granular layers was observed in brain of few fish in treatment group (Fig. 4).



**Figure 4:** Brain histological sections of rainbow trout showing slight hyperemia in some vessels at 24 h after bath challenge with organic germicide (H&E, X10).

## Discussion

Gills have important role in respiration, osmotic adjustment, equivalency between acid and base, disposal of excessive nitrogen from the body in the fishes. Since the wide surface of this organ is in direct contact with the external environment, so its morphology is the most useful medium to study the stimulator factor effects on fishes. The present study showed that the Organic germicide causes no losses

and abnormal behavior in fish during the period of this study. The most recorded damages in this experiment are related to the gill. The gill is the first organ that stimulates in encountering with any foreign substance and shows defensive reactions. Observed lesions in gills, such as hyperplasia, clavate appearance and basic layer swelling are natural reaction of this organ in encountering with foreign substances. Lamella

capillaries are supported by a large number of pillar cells and primary and secondary lamellae have been covered by epithelial cells, so observed damages in some samples are insignificant and not considered as a serious pathological damage. Kidney is one of the vital organs and its proper working is important to water equivalency and electrolyte balance in the body. In this study, evaluation of kidney's specimens has indicated some abnormality in glomerules and Bowman capsules. Formation of melano-macrophage centers is the immune response of this organ against stimulator foreign substance. During of this reaction, pigments release from pigment cells and defense against the disturbing agent, and then they have been swallowed by macrophages, accumulate in these centers and are excreted from the body (Shahsavani and Movaseghi, 2002). Observation of black spots in some samples are the same melano-macrophage centers that contain melanin and shows defense mechanism in kidney, therefore, it is not important and could not be considered as a serious pathological effect.

Liver is known as an organ that has many acts in order to the metabolism and also it is very important in fish life. Since this study findings showed no pathologic damages in fish liver, it could be concluded that the Organic germicide cannot cause toxicity problems in fish.

Brain Pathologic lesions due to external stimulator substances, cause disorders such as imbalance, early sexual being in young fish, prevention of gonad development in adult fish, decreasing in spawning and eggs growth, effect on the transmission mechanism of nervous messages and vital hormone secretion of the body (Sharifpour, et al., 2011). This study finding about the treated fish brain showed no serious pathological effects and slight hyperemia observed in capillaries is the natural reaction of this organ against the antiseptic substances.

In former studies, pathological effects of disinfectant substance - Malachite Green - has been evaluated after bath challenge studies with the carps and proved it's certain losses. Malachite Green is a color with organic origin which is known since 100 years ago. The use of this material due to having high risks is prohibited in the United States and limited in other regions afterward (Amerian, 1996). Other studies revealed histopathology effects of malachite green like detrimental effects in liver, gill, kidney, intestine, gonads and pituitary gonadotropic cells which causes sinusoidal congestion and focal necrosis in liver, damages mitochondria and also causes nuclear alterations (Gerundo et al., 1991). Also Hypertrophy and vacuolization followed by necrosis and cirrhosis have been observed in hepatocytes of *Heteropneustes fossilis* following treatment with malachite



green SJ (Srivastava et al., 1998a). Exposure to this dye also causes severe damages to gills resulting in necrosis of lamellar cells and gill epithelium, as well as leucocyte infiltration in rainbow trout (Svobodova et al., 1997) and *Heteropneustes fossilis* (Srivastava et al., 1998b). In another study, the wide range of toxicological effects of malachite green (MG) were investigated on various fish species and certain mammals and concluded that the potential of alternative parasiticides like humic acid, chlorine dioxide and Pyceze, should be explored to replace MG. But it should be used with extreme care at suitable concentrations and at times when the temperature is low and also Removal of residual MG in treatment ponds should also be considered (Srivastava et al., 2004). Gregori et al. (2007) studied the effect of acute exposure of 4 disinfectants commonly used in aquacultural practice including formalin, potassium permanganate, benzalkonium chloride and malachite green on the histological structure of adult zebrafish (*Danio rerio*) gills. The results of their study indicated that gills of all exposed zebrafish showed a higher occurrence of histopathological changes. These alterations included a slightly focal proliferation of interlamellar cells with obliteration of interlamellar spaces, mild inflammatory reaction with leucocyte infiltration and lifting of the epithelial layer from gill lamellae. Fish exposed to potassium permanganate

showed more severe histopathological changes consisting of necrotic change of lamellar cells, distortion and apical necrosis of secondary lamellae. Since the findings of this study showed that specified dose of Organic germicide has no certain pathological influences on the vital organs of the fish, it could be suitable replacement instead of other disinfectants such as Malachite Green which has carcinogenic property. However further investigations are needed to understand the exact role of this organic disinfectant in controlling fungal infections in fish and fish eggs.

### Acknowledgments

We wish to thank Faculty of Veterinary Medicine, University of Tehran for supporting this study.

### References

- Alborali, L., Sangiorgi, E., Leali, M., Guadagnini, P. and Sicura, S., 1997. The persistence of malachite green in the edible tissue of rainbow trout (*Oncorhynchus mykiss*). *Rivista italiana di acquacoltura. Verona*, 32(2), 45-60.
- Āmerian, M. A., 1996. Evaluation of Pathological Effects of Carp Bathing with Malachite Green. Chamran University, Ahwaz, Iran. 79.

- Cawley, G., 1999.** Bronopol: an alternative fungicide to malachite green. *Fish Veterinary Journal*, 3, 79-81.
- Cha, C. J., Doerge, D. R. and Cerniglia, C. E., 2001.** Biotransformation of Malachite Green by the Fungus *Cunninghamella elegans*. *Applied and environmental microbiology*, 67(9), 4358-4360.
- Fatemi, S. A. and Mirzargar, S. S., 2007.** Applied Pharmacology of the Fishes. Iran: Tehran University Publishment. 624.
- Gerundo, N., Alderman, D., Hadley, R. and Feist, S., 1991.** Pathological effects of repeated doses of malachite green: a preliminary study. *Journal of Fish Diseases*, 14(5), 521-532.
- Gregori, M., Pretti, C., Intorre, L., Braca, G. and Abramo, F., 2007.** Gill histopathology in zebrafish model following exposure to aquacultural disinfectants. *Bulletin-European Association of Fish Pathologists* , 27 (5), 185.
- Poosti, I. and Adibmoradi, M., 2001.** Comparative Histology and Histotechnique. Iran: Tehran University Publishment. 531p.
- Saeedi, A., Ghiasi, M., Pourgholam, R., Zahedi, A., Vahedi, F., Binaee, M. and Behroozi, S., 2008.** The study of complex chemical effects of Aquagerm (Germicide) on pH of water, saprolegnia fungus, streptococcus bacteria and behavioral change of Rainbow trout. *Iranian Journal of Veterinary Medicine*(1-).
- Schreier, T. M., Rach, J. J. and Howe, G. E., 1996.** Efficacy of formalin, hydrogen peroxide, and sodium chloride on fungal-infected rainbow trout eggs. *Aquaculture*, 140(4), 323-331.
- Shahsavani, D. and Movaseghi, A. R., 2002.** Systemic Pathology of the Fish. Mashhad, Iran: Ferdowsi University. 400p.
- Sharifpour, I., Rezvani Gilkolaei, S. Kazemi, R., 2011.** Histopathology of some important organ of perch (*Sander lucioperca*) and salmon (*Salmo Trutta caspius*) in the southern Caspian Sea with emphasis on pollutants. *Iranian Scientific Fisheries Research Journal*. Vol.19(4), 77-86. (In Persian)
- Srivastava, S., Singh, N., Sinha, R. and Srivastava, A., 1998a.**

---

Malachite green induced histopathological lesions in the liver of a freshwater catfish, *Heteropneustes fossilis* (Bloch). *Journal of Advanced Zoology*, 19, 46-49.

**Srivastava, A., Sinha, R., Singh, N. and Srivastava, S., 1998b.** Histopathological changes in a freshwater catfish, *Heteropneustes fossilis* following exposure to malachite green. *Proceedings-national*

*Academy of Sciences India Section b*, 68, 23-28.

**Srivastava, S., Sinha, R. and Roy, D., 2004.** Toxicological effects of malachite green. *Aquatic Toxicology*, 66(3), 319-329.

**Svobodova, Z., Flajshans, M., Vykusova, B., Machova, J. and Groch, L., 1997.** The effect of long-term therapeutic bath of malachite green on common carp (*Cyprinus carpio*). *Acta Veterinaria. Brno*, 66.