

ORIGINAL INVESTIGATIONS

# Myocardial Edema After Ischemia/Reperfusion Is Not Stable and Follows a Bimodal Pattern

## Imaging and Histological Tissue Characterization



Rodrigo Fernández-Jiménez, MD,\*† Javier Sánchez-González, PhD,\*‡ Jaume Agüero, MD,\* Jaime García-Prieto, BSc,\* Gonzalo J. López-Martín, Tech,\* José M. García-Ruiz, MD,\* Antonio Molina-Iracheta, DVM,\* Xavier Rosselló, MD,\* Leticia Fernández-Friera, MD, PhD,\*§ Gonzalo Pizarro, MD,\*|| Ana García-Álvarez, MD, PhD,\* Erica Dall'Armellina, MD, DPhil,\*¶ Carlos Macaya, MD, PhD,\*‡ Robin P. Choudhury, DM,\*¶ Valentin Fuster, MD, PhD,\*# Borja Ibáñez, MD, PhD\*†

### ABSTRACT

**BACKGROUND** It is widely accepted that edema occurs early in the ischemic zone and persists in stable form for at least 1 week after myocardial ischemia/reperfusion. However, there are no longitudinal studies covering from very early (minutes) to late (1 week) reperfusion stages confirming this phenomenon.

**OBJECTIVES** This study sought to perform a comprehensive longitudinal imaging and histological characterization of the edematous reaction after experimental myocardial ischemia/reperfusion.

**METHODS** The study population consisted of 25 instrumented Large-White pigs (30 kg to 40 kg). Closed-chest 40-min ischemia/reperfusion was performed in 20 pigs, which were sacrificed at 120 min (n = 5), 24 h (n = 5), 4 days (n = 5), and 7 days (n = 5) after reperfusion and processed for histological quantification of myocardial water content. Cardiac magnetic resonance (CMR) scans with T2-weighted short-tau inversion recovery and T2-mapping sequences were performed at every follow-up stage until sacrifice. Five additional pigs sacrificed after baseline CMR served as controls.

**RESULTS** In all pigs, reperfusion was associated with a significant increase in T2 relaxation times in the ischemic region. On 24-h CMR, ischemic myocardium T2 times returned to normal values (similar to those seen pre-infarction). Thereafter, ischemic myocardium-T2 times in CMR performed on days 4 and 7 after reperfusion progressively and systematically increased. On day 7 CMR, T2 relaxation times were as high as those observed at reperfusion. Myocardial water content analysis in the ischemic region showed a parallel bimodal pattern: 2 high water content peaks at reperfusion and at day 7, and a significant decrease at 24 h.

**CONCLUSIONS** Contrary to the accepted view, myocardial edema during the first week after ischemia/reperfusion follows a bimodal pattern. The initial wave appears abruptly upon reperfusion and dissipates at 24 h. Conversely, the deferred wave of edema appears progressively days after ischemia/reperfusion and is maximal around day 7 after reperfusion. (J Am Coll Cardiol 2015;65:315–23) © 2015 by the American College of Cardiology Foundation.

Open access under [CC BY-NC-ND license](#)

From the \*Centro Nacional de Investigaciones Cardiovasculares Carlos III (CNIC), Madrid, Spain; †Hospital Universitario Clínico San Carlos, Madrid, Spain; ‡Philips Healthcare, Madrid, Spain; §Hospital Universitario Montepíncipe, Madrid, Spain; ||Hospital Universitario Quirón Universidad Europea de Madrid, Madrid, Spain; ¶Oxford Acute Vascular Imaging Centre, Division of Cardiovascular Medicine, Radcliffe Department of Medicine, University of Oxford, Oxford, United Kingdom; and #The Zena and Michael A. Wiener Cardiovascular Institute, Icahn School of Medicine at Mount Sinai, New York, New York. This work was supported by a competitive grant from the Ministry of Economy and Competitiveness (MINECO), Fondo Europeo de Desarrollo Regional (FEDER) Carlos III Institute of Health-Fondo de Investigación Sanitaria (PI13/01979), and in part by FP7-PEOPLE-2013-ITN



## ABBREVIATIONS AND ACRONYMS

**CMR** = cardiac  
magnetic resonance

**FOV** = field of view

**I/R** = ischemia/reperfusion

**NEX** = number of excitations

**ROI** = region of interest

**STIR** = short-tau  
inversion recovery

**TE** = echo time

**TR** = repetition time

**T2W** = T2 weighted

**T**issue characterization after myocardial ischemia/reperfusion (I/R) is of great scientific and clinical value. After myocardial I/R, there is an intense edematous reaction (due to abnormal fluid accumulation in the interstitial and/or cardiomyocyte compartments) in the post-ischemic myocardium (1-5). Cardiac magnetic resonance (CMR) is a noninvasive technique that allows accurate tissue characterization of the myocardium (6). In particular, T2-weighted (T2W) and T2-mapping CMR sequences have the potential to identify tissues with high water content (7). Few experimental studies

have correlated post-I/R T2-CMR data with myocardial water content (2,8), and these validations were undertaken at different times after reperfusion. Many recent experimental and clinical studies have used these CMR sequences to retrospectively evaluate post-myocardial infarction edema on the basis of the assumptions that myocardial edema appears early after I/R, persists in a stable form for at least 1 week (9,10), and is accurately visualized by CMR.

SEE PAGE 324

However, the time chosen for the CMR examination varies significantly among studies, from 1 day (9,10) up to several weeks (9-16) after reperfusion. In addition, post-I/R T2W signal intensity and T2 relaxation time are affected by other factors besides water content: T2-CMR results can be modulated independently by hemorrhage (17,18), microvascular obstruction (19), and even cardioprotective therapies (20-22). There is, therefore, intense debate about the accuracy of CMR-based methods for detecting, quantifying, and tracking the post-infarction edematous reaction (7,23). Given the growing use of CMR technology to quantify post-I/R edema in clinical trials (24,25), a comprehensive characterization of the time course of post-I/R myocardial edema, including evaluation of both CMR and histological reference standards, is needed (22-24,26-28).

The present study aimed to comprehensively characterize myocardial edema and reperfusion-related tissue changes after I/R, covering from early to late reperfusion stages. For this, we performed a full CMR and histopathological study in a large animal (pig) model of I/R.

## METHODS

**STUDY DESIGN.** Experiments were performed in castrated male Large-White pigs weighing 30 kg to 40 kg. A total of 25 pigs completed the full protocol and comprised the study population. The study was approved by the Institutional Animal Research Committee and conducted in accordance with the recommendations of the Guide for the Care and Use of Laboratory Animals. The study design is summarized in **Figure 1**. Five pigs (Group 1) served as controls and were sacrificed with no intervention other than baseline CMR. In 20 pigs, reperfused acute myocardial infarction (I/R) was induced experimentally by closed-chest 40-min left anterior descending coronary artery occlusion. These pigs were sacrificed at 120 min (n = 5, Group 2), 24 h (n = 5, Group 3), 4 days (n = 5, Group 4), and 7 days (n = 5, Group 5) after reperfusion. CMR scans, including T2W short-tau inversion recovery (STIR), T2-mapping, and delayed enhancement sequences, were performed at every follow-up stage until sacrifice (i.e., animals sacrificed on day 7 underwent CMR examinations at baseline, 120 min, 24 h, day 4, and day 7). After the last follow-up CMR scan, animals were immediately euthanized, and myocardial tissue samples from ischemic and remote areas were rapidly collected for evaluation of water content by histology.

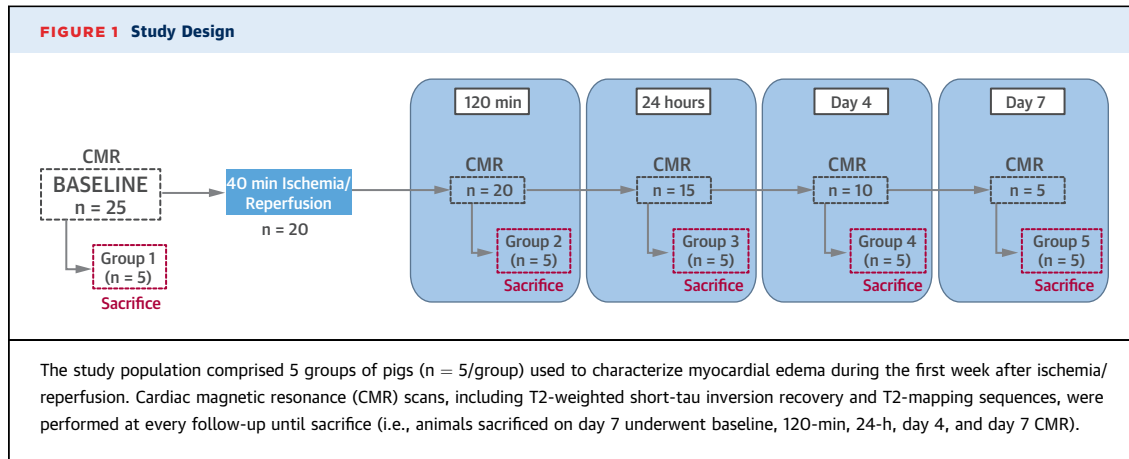
**MYOCARDIAL INFARCTION PROCEDURE.** The I/R protocol has been detailed elsewhere (29). Anesthesia was induced by intramuscular injection of ketamine (20 mg/kg), xylazine (2 mg/kg), and midazolam (0.5 mg/kg), and maintained by continuous intravenous infusion of ketamine (2 mg/kg/h), xylazine (0.2 mg/kg/h), and midazolam (0.2 mg/kg/h). Animals

Next Generation Training in Cardiovascular Research and Innovation-Cardionext. This study forms part of a Master Research Agreement between CNIC and Philips Healthcare. QMass software use was partially supported by a scientific collaboration with Medis Medical Imaging Systems BV. The Spanish Ministry of Economy and Competitiveness and the Pro-CNIC Foundation support the CNIC. Dr. Fernández-Jiménez is a recipient of a Rio Hortega fellowship from the Ministry of Economy and Competitiveness through the Instituto de Salud Carlos III; and has received an FICNIC fellowship from the Fundació Jesús Serra, the Fundación Interhospitalaria de Investigación Cardiovascular, and the CNIC. Dr. Sánchez-González is an employee of Philips Healthcare. Dr. Agüero is an FP7-PEOPLE-2013-ITN-Cardionext fellow. All other authors have reported that they have no relationships relevant to the contents of this paper to disclose. Derek Yellon, PhD, DSc, served as Guest Editor for this paper.

[Listen to this manuscript's audio summary by JACC Editor-in-Chief Dr. Valentin Fuster.](#)

[You can also listen to this issue's audio summary by JACC Editor-in-Chief Dr. Valentin Fuster.](#)

Manuscript received October 19, 2014; revised manuscript received November 5, 2014, accepted November 6, 2014.

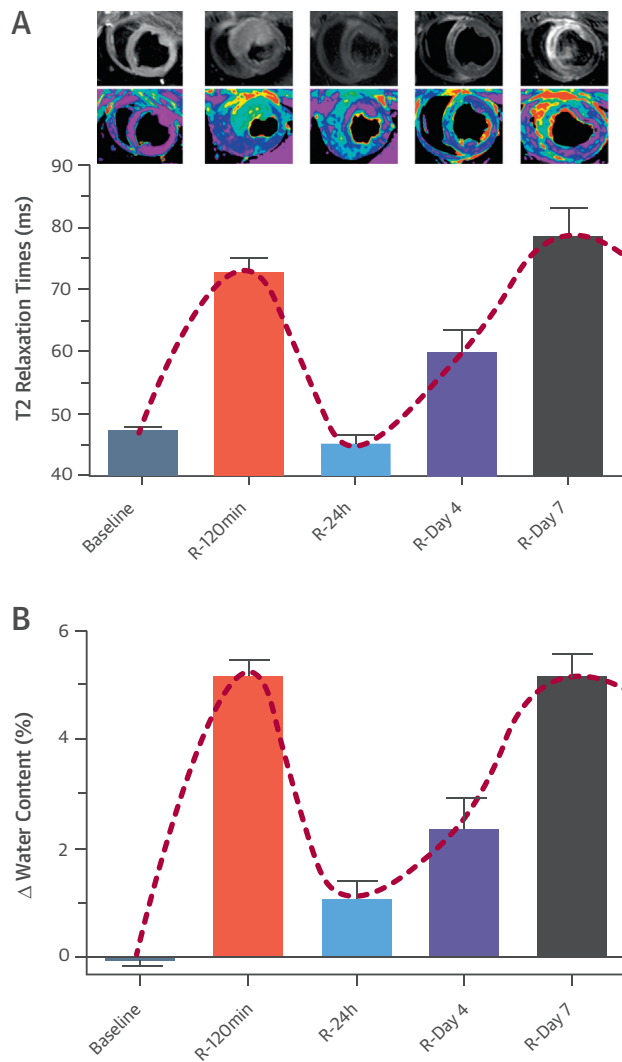


were intubated and mechanically ventilated with oxygen (fraction of inspired O<sub>2</sub>: 28%). Central venous and arterial lines were inserted, and a single bolus of unfractionated heparin (300 IU/kg) was administered at the onset of instrumentation. The left anterior descending coronary artery, immediately distal to the origin of the first diagonal branch, was occluded for 40 min with an angioplasty balloon introduced via the percutaneous femoral route using the Seldinger technique. Balloon location and maintenance of inflation were monitored angiographically. After balloon deflation, a coronary angiogram was recorded to confirm patency of the coronary artery. A continuous infusion of amiodarone (300 mg/h) was maintained during the procedure in all pigs to prevent malignant ventricular arrhythmias. In cases of ventricular fibrillation, a biphasic defibrillator was used to deliver nonsynchronized shocks.

**CMR PROTOCOL.** A baseline CMR scan was performed immediately before myocardial infarction and subsequent CMR scans were performed at post-infarction follow-up time points until sacrifice. All studies were performed in a Philips 3-T Achieva Tx whole-body scanner (Philips Healthcare, Best, the Netherlands) equipped with a 32-element phased-array cardiac coil. The imaging protocol included a standard segmented cine steady-state free-precession (SSFP) sequence to provide high-quality anatomical references, a T2-weighted triple inversion-recovery (T2W-STIR) sequence, a T2-turbo spin echo (TSE) mapping sequence, and a late gadolinium enhancement sequence. The imaging parameters for the SSFP sequence were field of view (FOV) of 280 × 280 mm, slice thickness 6 mm with no gaps, repetition time (TR) 2.8 ms, echo time (TE) 1.4 ms, flip angle 45°, cardiac phases 30, voxel size 1.8 × 1.8 mm, and 3 number of excitations (NEX). Imaging parameters for the T2W-STIR sequence were FOV 280 × 280 mm, slice

thickness 6 mm, TR 2 heartbeats, TE 80 ms, voxel size 1.4 × 1.95 mm, delay 210 ms, end-diastolic acquisition, echo-train length 16, and 2 NEX. The imaging parameters for the T2-TSE mapping were FOV 300 × 300 mm, slice thickness 8 mm, TR 2 heartbeats, and 10 echo times ranging from 4.9 to 49.0 ms. Delayed enhancement imaging was performed 10 to 15 min after intravenous administration of 0.20 mmol of gadopentetate dimeglumine contrast agent per kg of body weight (30) using an inversion-recovery spoiled turbo field echo (IR-T1TFE) sequence with the following parameters: FOV of 280 × 280 mm, voxel size 1.6 × 1.6 mm, end-diastolic acquisition, thickness 6 mm with no gap, TR 5.6 ms, TE 2.8 ms, inversion delay time optimized to null normal myocardium, and 2 NEX. SSFP, T2W-STIR, and IR-T1TFE sequences were performed to acquire 13 to 15 contiguous short-axis slices covering the heart from the base to the apex. To track T2 relaxation time changes across time, T2 maps in all studies were acquired in midapical ventricular short-axis slices corresponding to the same anatomical level.

**CMR DATA ANALYSIS.** CMR images were analyzed using dedicated software (MR Extended Work Space 2.6, Philips Healthcare, and QMass MR 7.5, Medis, Leiden, the Netherlands) by 2 observers experienced in CMR analysis. T2 maps were automatically generated on the acquisition scanner by fitting the signal intensity of all echo times to a monoexponential decay curve at each pixel with a maximum likelihood expectation maximization algorithm. T2 relaxation maps were quantitatively analyzed by placing a wide transmural region of interest (ROI) at the ischemic and remote areas of the corresponding slice in all studies. Hypointense areas suggestive of microvascular obstruction or hemorrhage were included in the ROI for T2 quantification purposes. Delayed gadolinium-enhanced regions were defined as >50% of maximum myocardial signal intensity (full width at

**FIGURE 2** Time Course of CMR T2 Relaxation Time and Corresponding Myocardial Water Content During the First Week After I/R

Note the parallel courses of cardiac magnetic resonance (CMR) fluctuations and histologically determined edema (**dashed red lines**). **(A)** Time course of absolute T2 relaxation time values (ms) in the ischemic myocardium during the first week after ischemia/reperfusion (I/R). **Bars** represent means and standard errors of the means. The **top of the panel** shows representative images from 1 animal that underwent 40-min/7-day I/R and CMR T2-weighted short-tau inversion recovery and T2-mapping examinations at all time points. All T2 maps were scaled between 30 and 120 ms. **(B)** Time course of absolute differences (%) in water content between ischemic (midapical anteroseptal left ventricular wall) and remote (posterolateral left ventricular wall) zones during the first week after I/R. **Bars** represent means and standard errors of the means. Absolute differences were  $0.0 \pm 0.2\%$  for group 1 (sacrificed at baseline with no other intervention than CMR),  $5.2 \pm 0.6\%$  for group 2 (I/R 120 min),  $1.1 \pm 0.7\%$  for group 3 (I/R 24 h),  $2.4 \pm 1.3\%$  for Group 4 (I/R 4 days), and  $5.1 \pm 1.0\%$  for group 5 (I/R 7 days). All pairwise comparisons for the absolute differences in myocardial water content were explored, adjusting the *p* values for multiple comparisons using the Holm-Bonferroni correction. Comparisons between different groups remained statistically significant with the exception of the following: group 1 (control) vs. group 3 (I/R 24 h), group 3 (I/R 24 h) vs. group 4 (I/R 4 days), and group 2 (I/R 120 min) vs. group 5 (I/R 7 days).

half maximum) with manual adjustment when needed. If present, a central core of hypointense signal within the area of increased signal was included as late gadolinium-enhanced myocardium. Regional transmural contrast enhancement was evaluated in the same segments where ROIs for T2 quantification were placed with a scheme on the basis of the spatial extent of delayed enhancement tissue within each segment (31). Segments with more than 75% hyperenhancement were considered segments with transmural enhancement.

**QUANTIFICATION OF MYOCARDIAL WATER CONTENT BY HISTOLOGY.** Paired myocardial samples were collected within minutes of euthanasia from the infarcted and remote myocardia of all pigs. Tissue samples were immediately blotted to remove surface moisture and introduced into laboratory crystal containers previously weighed on a high-precision scale. The containers were weighed before and after drying for 48 h at 100°C in a desiccating oven. Tissue water content was calculated as follows: water content (%) =  $([\text{wet weight} - \text{dry weight}]/\text{wet weight}) \times 100$ . An empty container was weighed before and after desiccation as an additional calibration control.

**STATISTICAL ANALYSIS.** Normal distribution of each data subset was checked using graphical methods and a Shapiro-Wilk test. For quantitative variables showing a normal distribution, data are expressed as mean  $\pm$  SD. Leven's test was performed to check the homogeneity of variances. A 1-way analysis of variance was conducted for comparison of myocardial water content among groups (from animals sacrificed at different time points). To take repeated measures into account, a generalized mixed model was conducted for comparison of T2 relaxation times among different time points. As this study was exploratory, all pairwise comparisons were explored, adjusting *p* values for multiple comparisons using the Holm-Bonferroni method. In all cases, data from the ischemic and remote myocardium (i.e., myocardial water content and T2 relaxation time values) were separately analyzed. All statistical analyses were performed using commercially available software (Stata version 12.0, StataCorp, College Station, Texas).

## RESULTS

### NATURAL EVOLUTION OF MYOCARDIAL EDEMA DURING THE FIRST WEEK AFTER I/R. CMR imaging.

Baseline (i.e., before ischemia) mean T2 relaxation times were  $47.2 \pm 2.6$  ms and  $46.3 \pm 1.7$  ms for the midapical anteroseptal and posterolateral left ventricular walls, respectively. In all pigs, early

reperfusion (120-min CMR) was associated with a sharp and significant increase in T2 relaxation time above baseline, in the former ischemic area (mid-apical anteroseptal ventricular wall). T2 relaxation times returned to baseline values at 24 h post-I/R in all animals, but subsequently increased progressively, reaching post-I/R values on day 7 similar to those observed during early reperfusion. Albeit slight, a linear trend for a progressive increase in T2 relaxation times across different time points was observed in the remote myocardium. **Figure 2A** shows mean changes in T2 relaxation time in the ischemic myocardium as well as a representative example of 1 animal serially scanned at all time points. Measurements of T2 relaxation time in the ischemic and remote myocardium at different time points after I/R are summarized in **Table 1**. Changes observed in T2W-STIR and T2-TSE mapping were consistent in all animals, as seen in **Figure 3**, which shows images from 8 pigs scanned at the different time points. The transmural extent of infarction was >80% in all evaluated segments containing the ROIs for T2 relaxation time quantification.

**Myocardial water content.** Myocardial water content in noninfarcted myocardium (from animals in group 1) was  $79.4 \pm 0.6\%$  and  $79.4 \pm 0.7\%$  for the midapical anteroseptal and posterolateral left ventricular walls, respectively. In the ischemic myocardium, an abrupt increase in water content was detected at early reperfusion. Consistent with the CMR data, there was a systematic and significant decrease in tissue water content in the formerly ischemic region at 24 h, followed by a subsequent increase over the following days to reach values on day 7 similar to those observed at early reperfusion. A linear trend for a slight, but progressive increase in water content across different time points was observed in the remote myocardium. Time courses for absolute differences in water content between ischemic and remote myocardium are shown in **Figure 2B**. **Table 2** summarizes measurements of water content in the ischemic and remote myocardium at different time points after I/R.

**DISCUSSION**

The present experimental study challenges the accepted view of the development of post-ischemia/reperfusion myocardial edema. Through state-of-the-art CMR analysis and histological validation in a pig model of I/R, we show that the edematous reaction during the first week after reperfusion is not stable, instead following a bimodal pattern (**Central Illustration**). The first wave appears abruptly upon reperfusion and dissipates at 24 h. Conversely,

**TABLE 1 Measurements of T2 Relaxation Time in the Ischemic and Remote Myocardium at Different Time Points During the First Week After Ischemia/Reperfusion**

		T2 Relaxation Times (ms)				
		Baseline	R-120 min	R-24 h	R-Day 4	R-Day 7
Group 1 (Control)	IM	47.7 ± 4.0				
	Rem	46.1 ± 1.5				
Group 2 (I/R-120 min)	IM	48.7 ± 0.6	73.3 ± 10.0			
	Rem	46.8 ± 1.8	47.0 ± 1.0			
Group 3 (I/R-24 h)	IM	46.5 ± 1.9	72.4 ± 12.3	45.9 ± 5.3		
	Rem	46.2 ± 2.6	48.6 ± 3.0	45.2 ± 0.6		
Group 4 (I/R-4 days)	IM	45.9 ± 1.6	73.5 ± 4.2	42.7 ± 9.3	55.1 ± 13.2	
	Rem	45.5 ± 0.8	48.3 ± 4.0	47.5 ± 3.1	48.2 ± 2.9	
Group 5 (I/R-7 days)	IM	47.2 ± 3.5	72.6 ± 14.2	47.0 ± 2.9	64.9 ± 7.9	78.4 ± 10.6
	Rem	46.7 ± 1.5	48.5 ± 3.7	51.4 ± 5.0	50.1 ± 1.8	50.0 ± 3.3
Pooled	IM	<b>47.2 ± 2.6</b>	<b>72.9 ± 9.9</b>	<b>45.2 ± 6.2</b>	<b>60.0 ± 11.5</b>	<b>78.4 ± 10.6</b>
	Rem	<b>46.3 ± 1.7</b>	<b>48.1 ± 3.0</b>	<b>48.0 ± 4.1</b>	<b>49.1 ± 2.5</b>	<b>50.0 ± 3.3</b>

Values are mean ± SD. All pairwise comparisons for pooled serial T2 relaxation times were explored, adjusting p values for multiple comparisons using the Holm-Bonferroni correction. Comparisons between different time points in the ischemic myocardium remained statistically significant with the exception of the following: baseline vs. R-24 h, and R-120 min vs. R-day 7. **Bold** values are those that were compared and are also represented in **Figure 2A**.  
 IM = ischemic myocardium; Rem = remote myocardium.

the second wave of edema appears progressively days after I/R and increases to a maximum on post-reperfusion day 7. To the best of our knowledge, this is the first study to comprehensively characterize the time course of myocardial edema during the first week after I/R, covering from very early to late reperfusion stages. Because edema has been perceived as both stable and persistent during at least 1 week after myocardial I/R, it has been used increasingly both clinically and in the setting of clinical trials as a marker of “ischemic memory.” Therefore, our findings that neither of these assumptions is accurate will have important translational implications.

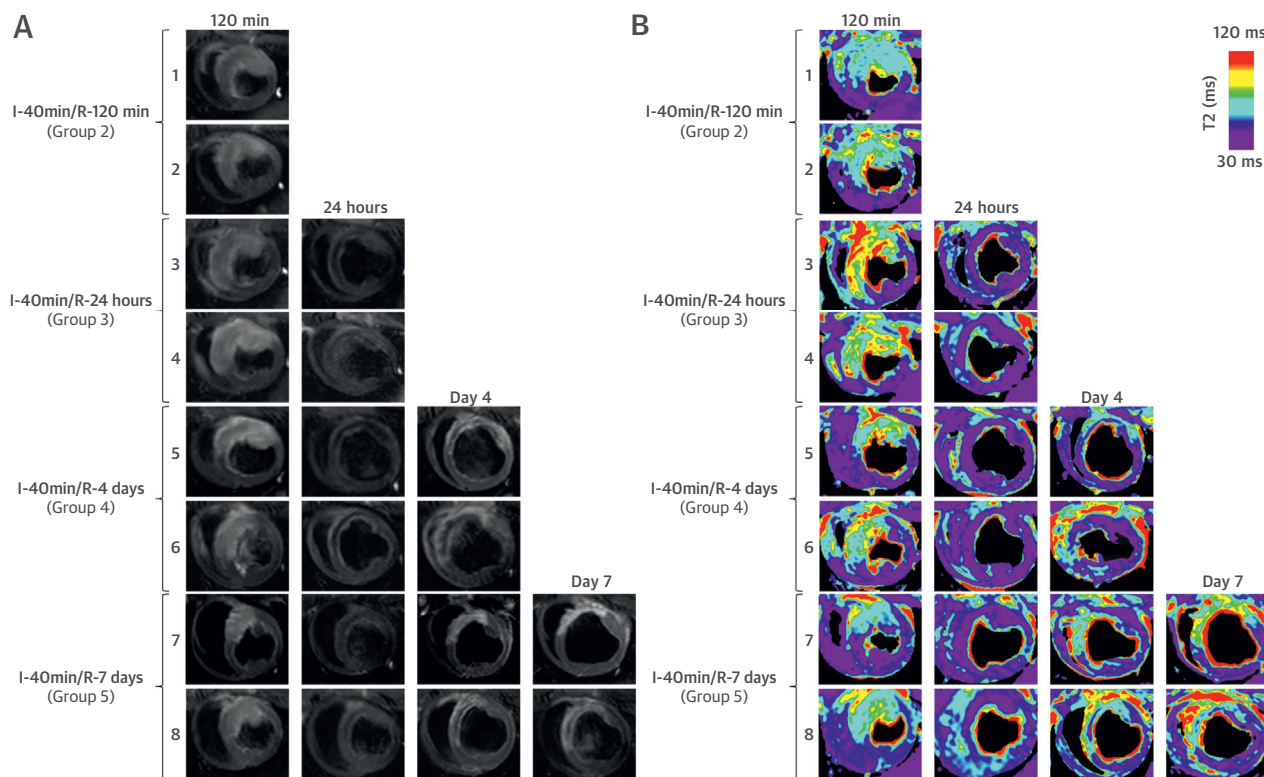
As with most organs, water is a major component of healthy cardiac tissue. In steady-state conditions, myocardial water content is stable and mostly intracellular, with only a very small interstitial component contained within the extracellular matrix. Cardiac

**TABLE 2 Measurements of Myocardial Water Content in the Ischemic and Remote Myocardium at Different Time Points During the First Week After I/R**

	Water Content (%)				
	Group 1 (Control)	Group 2 (I/R-120 min)	Group 3 (I/R-24 h)	Group 4 (I/R-4 days)	Group 5 (I/R-7 days)
IM	79.4 ± 0.6	84.5 ± 0.5	81.2 ± 0.5	82.5 ± 1.4	85.2 ± 0.9
Rem	79.4 ± 0.7	79.4 ± 0.4	80.0 ± 0.4	80.1 ± 0.4	80.1 ± 0.3

Values are mean ± SD. All pairwise comparisons for myocardial water content were explored, adjusting p values for multiple comparisons using the Holm-Bonferroni correction. Comparisons between different groups in the ischemic myocardium remained statistically significant with the exception of the following: group 2 (I/R-120 min) vs. group 5 (I/R-7 days).  
 Abbreviations as in **Table 1**.

**FIGURE 3** CMR T2W-STIR and T2 Mapping Images From Different Animals During the 1-Week Time Course After I/R



Serial CMR scans reveal highly consistent bimodal changes in image-determined myocardial edema during the first week after I/R, both in T2-weighted short-tau inversion recovery (T2W-STIR) imaging (A) and T2 mapping (B). Images from 8 pigs at different time points are shown. All T2 maps were scaled between 30 and 120 ms. Abbreviations as in Figure 2.

edema occurs in numerous pathological conditions in which this homeostasis is disrupted, and affects both fluid accumulation outside cells (interstitial edema) and within cardiomyocytes (cellular edema). In the context of myocardial infarction, edema appears initially in the form of cardiomyocyte swelling during the early stages of ischemia (5). Myocardial edema is then significantly exacerbated upon restoration of blood flow to the ischemic region. This increase is due to increased cell swelling (3) and, more importantly, to interstitial edema secondary to reactive hyperemia and leakage from damaged capillaries when the hydrostatic pressure is restored upon reperfusion (1,4).

CMR has emerged as a noninvasive technology that allows characterization of cardiac tissue after I/R (6), with T2-weighted (T2W) CMR sequences especially suited to detecting high water content in post-ischemic edematous cardiac muscle (7). Under the accepted dogma that myocardial edema appears early after I/R and is present for at least 1 week (9,10,24), numerous experimental and clinical studies have

used T2W-CMR to retrospectively evaluate the edematous reaction associated with myocardial infarction. Although visually attractive, T2W imaging is subject to several technical limitations and does not offer quantitative T2 measurements that would allow for comparisons between different studies (32,33). Recently developed quantitative T2 relaxation maps (T2 mapping) have been proposed to overcome at least some of the limitations for the detection and quantification of myocardial edema (34,35). However, T2-mapping sequences have inherent limitations, are time-consuming, and are thus mostly used as a research tool and require further validation. Large animal models of I/R offer an ideal platform for such a validation (36), and, due to its anatomical and physiological similarities to the human heart, the pig is one of the most reliable models for studying I/R-related processes.

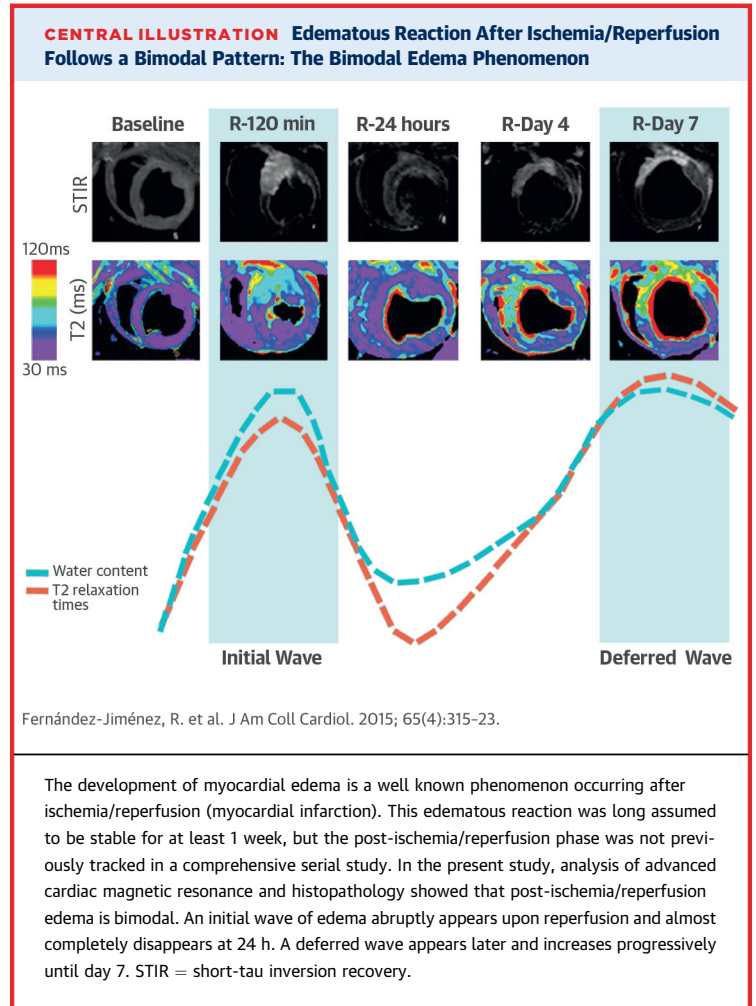
The disparate time points examined in different experimental and clinical studies are an important source of confusion in CMR evaluation of post-I/R

edema. As demonstrated in the present study, because T2 values in the ischemic myocardium fluctuate significantly during the first week after reperfusion, the timing of post-infarction imaging is critically important for noninvasive assessment of myocardial edema. In a previous study, Foltz et al. (37,38) suggested a similar myocardial T2 relaxation time course in a pig model of I/R, with CMR scans at days 0, 2, and 7 after reperfusion. However, this study lacked histological validation of myocardial water content, and the observed T2 value fluctuations were interpreted as reflecting the oxidative denaturation of hemoglobin to methemoglobin (17,39) rather than fluctuations in myocardial water content. The histological validation in the present study demonstrates the consistent appearance of 2 consecutive waves of edema during the first week after I/R, a groundbreaking concept in the field.

The first wave of edema appears soon after reperfusion and dissipates at 24 h. Interestingly, water content within the ischemic myocardium did not return to normal values, whereas T2 relaxation time in the ischemic ventricular wall dropped to baseline values. It is plausible that the decrease in T2 relaxation time observed at 24 h is due to at least 2 components: the classically described paramagnetic effect of hemoglobin denaturation products and the sharp decrease in myocardial water content at 24 h post-reperfusion reported here.

The second wave of edema appeared progressively in the days after I/R and was maximal at day 7. Interestingly, T2 abnormalities and increased water content in the ischemic region were ultimately as impressive as those observed at early reperfusion. Further studies are needed to elucidate the pathophysiology underlying this bimodal edematous reaction after I/R. It is intuitive to argue that the first and second waves of post-I/R edema are related to different pathological phenomena, although this has not been demonstrated in the present work. Whereas the first wave seems to be directly related to reperfusion, the pathophysiology underlying the second wave is more challenging to decipher. We speculate that tissue changes during the first week of infarction (removal of cardiomyocyte debris from the extracellular compartment and its replacement by water, collagen homeostasis, and healing of tissue/inflammation, among others) could play a role in this second edematous reaction.

The data presented here might have implications for understanding the role of CMR in retrospective quantification of the post-infarction area at risk. Given that this study was not designed to correlate the actual anatomical area at risk (perfusion



defect during ischemia) with the extension of CMR-visualized edema, any conclusions in this regard are speculative and distract from this study's main objective. Future studies should specifically evaluate the impact of the dual edema phenomenon on the role of CMR to accurately quantify area at risk.

The identification of the time course of post-I/R myocardial edema has important biological, diagnostic, prognostic, and therapeutic implications, and opens a route to further exploration of factors influencing this phenomenon.

**STUDY LIMITATIONS.** Extrapolation of the results of this experimental study to the clinic should be done with caution. The intensity and time course of bimodal post-I/R edema may be modified by several factors, such as the duration of ischemia, pre-existence of collateral flow, and even the application of peri-reperfusion therapies to attenuate I/R damage. Nonetheless, the use of a large animal model is of

great translational value, especially considering the difficulty of performing such a comprehensive serial CMR study (including 1 examination immediately upon reperfusion) in patients. The data presented in this study are robust and consistent, and the pig is one of the most clinically translatable large animal models for the study of I/R issues, because (unlike other mammals) its coronary artery anatomy and distribution are similar to those of humans (40) and it has minimal pre-existing coronary collateral flow (41). In addition, as shown here with the direct quantification of myocardial water content, experimental studies offer the possibility of histological validation.

In this study, the ROIs for quantification of T2 relaxation time were placed in the entire wall thickness, then were carefully and individually adjusted by hand to avoid the right and left ventricular cavities. Therefore, ROIs might include different myocardial states (i.e., hemorrhage, microvascular obstruction). We took this approach to mimic the histological water content evaluation, which was performed in the entire wall thickness. Given the parallel courses of T2 relaxation times and water content, we believe that the possible inclusion of different myocardial states had little effect on the results, although it might have had some influence on the differences in absolute T2 relaxation times between our study and others that used a different methodological approach to select ROIs.

## CONCLUSIONS

Contrary to the accepted view, the present work consistently shows that edematous reaction during

the first week after ischemia/reperfusion is not stable, but follows a bimodal pattern. The first wave of edema appears abruptly upon reperfusion and dissipates at 24 h. Conversely, the second wave appears progressively days after ischemia/reperfusion and is maximal around day 7 after reperfusion.

**ACKNOWLEDGMENTS** The authors are indebted to the contributions of Maria Del Trigo, Carlos Galán-Arriola, and David Sanz-Rosa. The authors also thank Tamara Córdoba, Oscar Sanz, Eugenio Fernández, and other members of the CNIC animal facility and farm for outstanding animal care and support, and Simon Bartlett (from the CNIC) for providing English editing.

**REPRINT REQUESTS AND CORRESPONDENCE:** Dr. Borja Ibáñez, Centro Nacional de Investigaciones Cardiovasculares Carlos III (CNIC), Melchor Fernández Almagro 3, 28029 Madrid, Spain. E-mail: [bibanez@cnic.es](mailto:bibanez@cnic.es).

## PERSPECTIVES

### COMPETENCY IN MEDICAL KNOWLEDGE:

Myocardial edema that develops after acute infarction is a bimodal phenomenon with diagnostic, prognostic, and therapeutic implications.

**TRANSLATIONAL OUTLOOK:** Temporal variation in post-ischemic reperfusion edema should be considered in studies of cardiac magnetic resonance imaging for quantification of jeopardized myocardium.

## REFERENCES

1. Bragadeesh T, Jayaweera AR, Pascotto M, et al. Post-ischaemic myocardial dysfunction (stunning) results from myofibrillar oedema. *Heart* 2008;94:166-71.
2. Garcia-Dorado D, Oliveras J, Gili J, et al. Analysis of myocardial oedema by magnetic resonance imaging early after coronary artery occlusion with or without reperfusion. *Cardiovasc Res* 1993;27:1462-9.
3. Kloner RA, Ganote CE, Whalen DA Jr., Jennings RB. Effect of a transient period of ischemia on myocardial cells. II. Fine structure during the first few minutes of reflow. *Am J Pathol* 1974;74:399-422.
4. Turschner O, D'Hooge J, Dommke C, et al. The sequential changes in myocardial thickness and thickening which occur during acute transmural infarction, infarct reperfusion and the resultant expression of reperfusion injury. *Eur Heart J* 2004;25:794-803.
5. Whalen DA Jr., Hamilton DG, Ganote CE, Jennings RB. Effect of a transient period of ischemia on myocardial cells. I. Effects on cell volume regulation. *Am J Pathol* 1974;74:381-97.
6. Friedrich MG. Tissue characterization of acute myocardial infarction and myocarditis by cardiac magnetic resonance. *J Am Coll Cardiol Img* 2008;1:652-62.
7. Arai AE, Leung S, Kellman P. Controversies in cardiovascular MR imaging: reasons why imaging myocardial T2 has clinical and pathophysiologic value in acute myocardial infarction. *Radiology* 2012;265:23-32.
8. Wisenberg G, Prato FS, Carroll SE, Turner KL, Marshall T. Serial nuclear magnetic resonance imaging of acute myocardial infarction with and without reperfusion. *Am Heart J* 1988;115:510-8.
9. Carlsson M, Ubachs JF, Hedstrom E, et al. Myocardium at risk after acute infarction in humans on cardiac magnetic resonance: quantitative assessment during follow-up and validation with single-photon emission computed tomography. *J Am Coll Cardiol Img* 2009;2:569-76.
10. Dall'Armellina E, Karia N, Lindsay AC, et al. Dynamic changes of edema and late gadolinium enhancement after acute myocardial infarction and their relationship to functional recovery and salvage index. *Circ Cardiovasc Imaging* 2011;4:228-36.
11. Aletras AH, Tilak GS, Natanzon A, et al. Retrospective determination of the area at risk for reperfused acute myocardial infarction with T2-weighted cardiac magnetic resonance imaging: Histopathological and displacement encoding with stimulated echoes (dense) functional validations. *Circulation* 2006;113:1865-70.
12. Berry C, Kellman P, Mancini C, et al. Magnetic resonance imaging delineates the ischemic area at risk and myocardial salvage in patients with acute



- myocardial infarction. *Circ Cardiovasc Imaging* 2010;3:527-35.
13. Friedrich MG, Abdel-Aty H, Taylor A, et al. The salvaged area at risk in reperfused acute myocardial infarction as visualized by cardiovascular magnetic resonance. *J Am Coll Cardiol* 2008;51:1581-7.
14. Ibanez B, Macaya C, Sanchez-Brunete V, et al. Effect of early metoprolol on infarct size in ST-segment-elevation myocardial infarction patients undergoing primary percutaneous coronary intervention: the effect of metoprolol in cardioprotection during an acute myocardial infarction (METOCARD-CNIC) trial. *Circulation* 2013;128:1495-503.
15. Thiele H, Hildebrand L, Schirdehahn C, et al. Impact of high-dose N-acetylcysteine versus placebo on contrast-induced nephropathy and myocardial reperfusion injury in unselected patients with ST-segment elevation myocardial infarction undergoing primary percutaneous coronary intervention: the LIPSIA-N-ACC (Prospective, Single-Blind, Placebo-Controlled, Randomized Leipzig Immediate Percutaneous Coronary Intervention Acute Myocardial Infarction N-ACC) trial. *J Am Coll Cardiol* 2010;55:2201-9.
16. Wright J, Adriaenssens T, Dymarkowski S, Desmet W, Bogaert J. Quantification of myocardial area at risk with T2-weighted CMR: comparison with contrast-enhanced CMR and coronary angiography. *J Am Coll Cardiol Img* 2009;2:825-31.
17. Lotan CS, Miller SK, Cranney GB, Pohost GM, Elgavish GA. The effect of postinfarction intramyocardial hemorrhage on transverse relaxation time. *Magn Reson Med* 1992;23:346-55.
18. O'Regan DP, Ahmed R, Karunanithy N, et al. Reperfusion hemorrhage following acute myocardial infarction: assessment with T2\* mapping and effect on measuring the area at risk. *Radiology* 2009;250:916-22.
19. Mikami Y, Sakuma H, Nagata M, et al. Relation between signal intensity on t2-weighted MR images and presence of microvascular obstruction in patients with acute myocardial infarction. *AJR Am J Roentgenol* 2009;193:W321-6.
20. Hausenloy DJ, Baxter G, Bell R, et al. Translating novel strategies for cardioprotection: the hatter workshop recommendations. *Basic Res Cardiol* 2010;105:677-86.
21. Thuny F, Lairez O, Roubille F, et al. Post-conditioning reduces infarct size and edema in patients with ST-segment elevation myocardial infarction. *J Am Coll Cardiol* 2012;59:2175-81.
22. White SK, Frohlich GM, Sado DM, et al. Remote ischemic conditioning reduces myocardial infarct size and edema in patients with ST-segment elevation myocardial infarction. *J Am Coll Cardiol Intv* 2015;8:177-87.
23. Croisille P, Kim HW, Kim RJ. Controversies in cardiovascular MR imaging: T2-weighted imaging should not be used to delineate the area at risk in ischemic myocardial injury. *Radiology* 2012;265:12-22.
24. Eitel I, Friedrich MG. T2-weighted cardiovascular magnetic resonance in acute cardiac disease. *J Cardiovasc Magn Reson* 2011;13:13.
25. Schwitler J, Arai AE. Assessment of cardiac ischaemia and viability: role of cardiovascular magnetic resonance. *Eur Heart J* 2011;32:799-809.
26. Garcia-Dorado D, Andres-Villarreal M, Ruiz-Meana M, Inserte J, Barba I. Myocardial edema: a translational view. *J Mol Cell Cardiol* 2012;52:931-9.
27. Ghugre NR, Pop M, Barry J, Connelly KA, Wright GA. Quantitative magnetic resonance imaging can distinguish remodeling mechanisms after acute myocardial infarction based on the severity of ischemic insult. *Magn Reson Med* 2013;70:1095-105.
28. Klocke FJ. Cardiac magnetic resonance measurements of area at risk and infarct size in ischemic syndromes. *J Am Coll Cardiol* 2010;55:2489-90.
29. Garcia-Prieto J, Garcia-Ruiz JM, Sanz-Rosa D, et al. Beta3 adrenergic receptor selective stimulation during ischemia/reperfusion improves cardiac function in translational models through inhibition of MPTP opening in cardiomyocytes. *Basic Res Cardiol* 2014;109:422.
30. Kim RJ, Albert TS, Wible JH, et al. Performance of delayed-enhancement magnetic resonance imaging with gadoversetamide contrast for the detection and assessment of myocardial infarction: An international, multicenter, double-blinded, randomized trial. *Circulation* 2008;117:629-37.
31. Wu E, Judd RM, Vargas JD, et al. Visualisation of presence, location, and transmural extent of healed Q-wave and non-Q-wave myocardial infarction. *Lancet* 2001;357:21-8.
32. Pennell D. Myocardial salvage: retrospection, resolution, and radio waves. *Circulation* 2006;113:1821-3.
33. Arai AE. Using magnetic resonance imaging to characterize recent myocardial injury: utility in acute coronary syndrome and other clinical scenarios. *Circulation* 2008;118:795-6.
34. Ugander M, Bagi PS, Oki AJ, et al. Myocardial edema as detected by pre-contrast T1 and T2 CMR delineates area at risk associated with acute myocardial infarction. *J Am Coll Cardiol Img* 2012;5:596-603.
35. Verhaert D, Thavendiranathan P, Giri S, et al. Direct T2 quantification of myocardial edema in acute ischemic injury. *J Am Coll Cardiol Img* 2011;4:269-78.
36. Fernandez-Jimenez R, Fernández-Friera L, Sanchez-Gonzalez J, Ibanez B. Animal models of tissue characterization of area at risk, edema and fibrosis. *Curr Cardiovasc Imaging Rep* 2014;7:1-10.
37. Foltz WD, Yang Y, Graham JJ, et al. MRI relaxation fluctuations in acute reperfused hemorrhagic infarction. *Magn Reson Med* 2006;56:1311-9.
38. Foltz WD, Yang Y, Graham JJ, et al. T2 fluctuations in ischemic and post-ischemic viable porcine myocardium in vivo. *J Cardiovasc Magn Reson* 2006;8:469-74.
39. Lotan CS, Bouchard A, Cranney GB, Bishop SP, Pohost GM. Assessment of postreperfusion myocardial hemorrhage using proton NMR imaging at 1.5 T. *Circulation* 1992;86:1018-25.
40. Weaver ME, Pantely GA, Bristow JD, Ladley HD. A quantitative study of the anatomy and distribution of coronary arteries in swine in comparison with other animals and man. *Cardiovasc Res* 1986;20:907-17.
41. Maxwell MP, Hearse DJ, Yellon DM. Species variation in the coronary collateral circulation during regional myocardial ischaemia: a critical determinant of the rate of evolution and extent of myocardial infarction. *Cardiovasc Res* 1987;21:737-46.

---

**KEY WORDS** CMR, MRI, myocardial infarction, pig, T2, water content