



Title	Evaluation of grid performance for thoracic radiography in calves using a portable x-ray unit
Author(s)	Shimbo, Genya; Tagawa, Michihito; Matsumoto, Kotaro; Tomihari, Mizuki; Miyahara, Kazuro
Citation	Japanese Journal of Veterinary Research, 66(1), 13-19
Issue Date	2018-02
DOI	10.14943/jjvr.66.1.13
Doc URL	http://hdl.handle.net/2115/68709
Type	bulletin (article)
File Information	Genya Shimbo.pdf



[Instructions for use](#)

Evaluation of grid performance for thoracic radiography in calves using a portable x-ray unit

Genya Shimbo¹⁾, Michihito Tagawa¹⁾, Kotaro Matsumoto²⁾,
Mizuki Tomihari²⁾ and Kazuro Miyahara^{1,*})

¹⁾ Veterinary Medical Center, Obihiro University of Agriculture and Veterinary Medicine, Inada, Obihiro, Hokkaido 080-8555, Japan

²⁾ Department of Veterinary Medicine, Division of Clinical Veterinary Medicine, Obihiro University of Agriculture and Veterinary Medicine, Inada, Obihiro, Hokkaido 080-8555, Japan

Received for publication, October 5, 2017; accepted, November 17, 2017

Abstract

Thoracic radiography provides diagnostic assistance in assessing the severity of lung lesions in bovine respiratory diseases. We investigated the effects of grid use on overall image quality for portable thoracic radiography in calves. Thoracic radiographs of the dorsocaudal region were made for 30 calves of various sizes, using three acquisition techniques (digital radiography with no grid, with a 3 : 1 grid, and with an 8 : 1 grid). Overall image quality was graded independently by five veterinarians using a 5-point scale based on the visibility of the thoracic vertebral bodies, thoracic spinous processes, scapulae, proximal third of the ribs, caudal lobar pulmonary vessels, and aortic arch; and on the level of image noise. The results were evaluated using Visual Grading Characteristics analysis. The 3 : 1 grid significantly improved overall image quality, regardless of body size. The 8 : 1 grid improved image quality only for calves smaller than 30 cm in thickness. The results of this study support the value of a 3 : 1 grid for portable thoracic radiography in calves.

Key Words: calf, image quality, low ratio grid, portable radiography

Introduction

Bovine respiratory disease (BRD) is one of the most common causes of morbidity and mortality in both pre-weaned and weaned calves, and has many negative long-term consequences including decreased milk production, poor reproductive performance, and poor growth, resulting in considerable economic loss (11, 20). The clinical diagnosis of BRD usually is based on clinical signs, increased rectal temperature, and

abnormal lung sounds (5, 8).

Thoracic radiography and ultrasonography can provide considerable assistance in diagnosing the severity of a lesion (7). Recently, thoracic ultrasonography has been recognized as a useful diagnostic aid in calves with anaerobic bacterial pneumonia, because it can be performed rapidly calf-side in a field setting by using a portable unit, and can accurately predict the presence of lung lesions (19, 21, 22). However, lung lesions are ultrasonographically apparent only when

*Corresponding author: Kazuro Miyahara, Veterinary Medical Center, Obihiro University of Agriculture and Veterinary Medicine, Inada, Obihiro, Hokkaido 080-8555, Japan
E-mail: miyahara@obihiro.ac.jp
doi: 10.14943/jjvr.66.1.13

they extend to the lung periphery. Indeed, ultrasonography in calves has failed to detect consolidation surrounded by aerated lung and a 10-cm abscess (19, 21). Thoracic radiography can be performed in calves using portable x-ray units capable of generating 80 to 100 kilovolts (kV) and 15 to 20 mA, such as many large animal veterinarians commonly use (4, 7). The typical findings in thoracic radiography and ultrasonography scans for calves with various thoracic conditions have been documented (12).

One of the challenges of portable thoracic radiography is the difficulty of using anti-scatter grids. Because the focal spot and the grid are manually positioned, grid misalignment often occurs. In addition, when a grid is used, the tube current (milliamperere second: mAs) must be increased to compensate for the attenuation of scattered as well as some primary radiation by the grid. However, because portable units have low output, this means the exposure time must be increased, which increases the likelihood of motion artifacts. These challenges in using grids also appear in mobile bedside chest radiography in human medicine, for which reason grids are not often used, even though the resulting image quality is often poor because of scattered radiation (10, 23). To overcome the problem of misalignment, a low ratio (3 : 1) grid has been developed, and its effectiveness has been reported (6). Additionally, unlike in an analog system, precise exposure control is not required for obtaining the optimal film density and brightness in digital system, because the detected signal can be adjusted independently of the incident detector dose. Indeed, in adult chest radiography, the use of grids has been found to improve image quality without the need to increase tube current (17).

The purpose of this study was to evaluate the effect of anti-scatter grids on the image quality of portable thoracic radiography in calves. We hypothesized that image quality could be improved to some extent without increasing the patient exposure.

Materials and Methods

This study was approved by the Institutional Animal Care and Use Committee at the Obihiro University of Agriculture and Veterinary Medicine. Thirty healthy calves (29 females and 1 male) without clinical signs of respiratory disease were studied. The median age (range), body weight, and body thickness at the level of the last rib were 118.5 days (25–246), 124 kg (50.6–216), and 36.5 cm (20–44), respectively. The calves were classified into three categories based on body thickness; ≤ 30 cm ($n = 10$), 31–40 cm ($n = 11$), and > 40 cm ($n = 9$). During examination, the calves were restrained with a head halter in a chute, to which a flat-panel detector (FPD) system (CALNEO C 1417s and CONSOLE ADVANCE, Fuji Film Co., Ltd., Tokyo, Japan) was attached. Radiographic exposures were made using a portable x-ray unit (PORTA 380HF, JOB, Hyogo, Japan). The exposure factors and source-to-image-receptor distance were set to 80 kV, 2.0 mAs, and 100 cm, respectively, in all experiments. The x-ray beam was collimated to cover the entire FPD (14×17 inch). Image processing parameters were used as recommended by the manufacturer, with density and contrast adjustments applied automatically. Portable thoracic radiographs of the dorsocaudal region were obtained from each calf using three techniques. In technique 1, images were acquired without the grid; in technique 2 a 3 : 1 focused grid (Mitaya Manufacturing, Co., Ltd., Saitama, Japan) was used; and in technique 3 an 8 : 1 focused grid (Mitaya Manufacturing) was used (Fig. 1). The specifications for the grids were as follows: the strip density, 40 lines/cm; interspace material, aluminum; focusing distance, 100 cm. Each technique was repeated several times, to compensate for respiratory or other motion artifacts, and one image was selected for each technique, with the goal of making the three images as comparable as possible. A total of 90 images were obtained, and the Fuji sensitivity number (S-value) for each image was recorded.

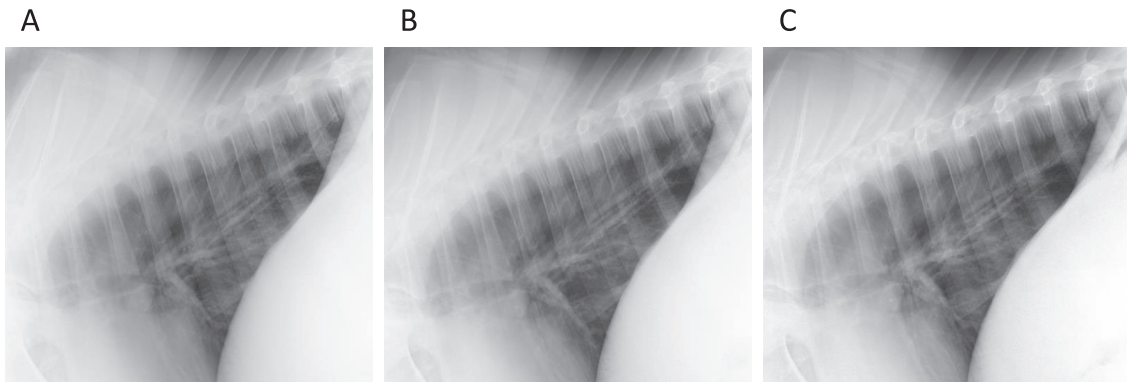


Fig. 1. Portable thoracic radiographs of a calf 34 cm in thickness. (A) Technique 1 (without any grid). (B) Technique 2 (using a 3 : 1 grid). (C) Technique 3 (using an 8 : 1 grid).

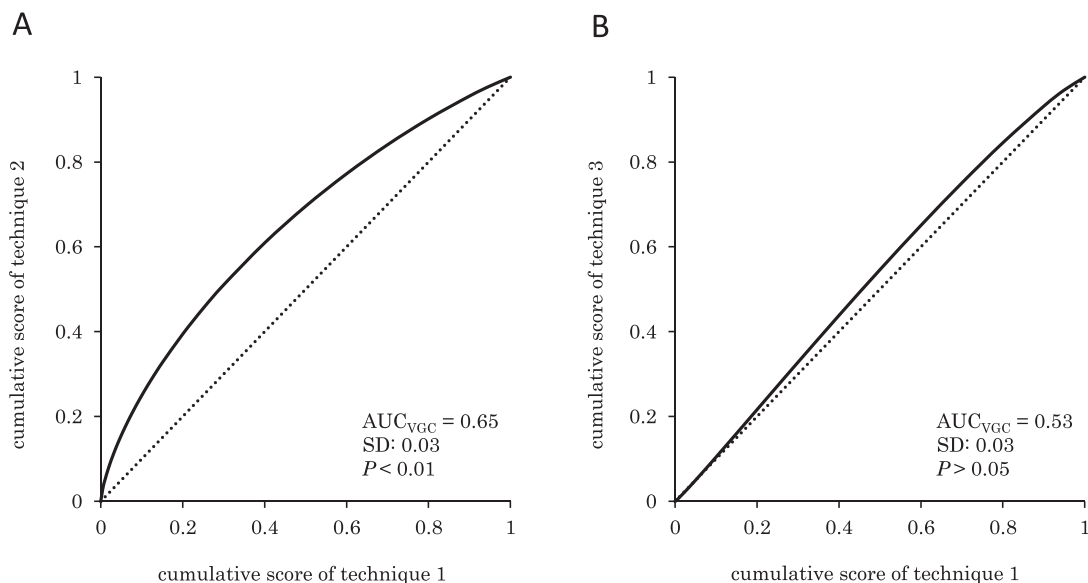
S-value, which is an exposure indicator provided automatically for each image, has a linear inverse relationship to exposure, therefore low incident dose results in a high S-value and vice versa (2).

The images (DICOM format) were interpreted using OsiriX (Pixmeo, Gengeva, Switzerland), by five veterinarians who were blinded to the study aim and design. All three images of each calf were displayed simultaneously on two high-resolution (2 megapixel) liquid crystal 10-bit display monitors (RadiForce MX215, EIZO Corporation, Ishikawa, Japan) in randomized order. One image was displayed on the left monitor and the other two on the right, at the same size. The evaluators were allowed to use processing tools, such as the window and level settings or magnification, as in standard clinical procedures. For image quality evaluation, visual grading analysis (VGA) was used in an absolute manner. VGA is a technique to assess the image quality based on the visualization of clinically relevant normal structures (14). Briefly, the images were graded for overall diagnostic quality using a 5-point scale (1 = unacceptable, 2 = barely acceptable, 3 = acceptable, 4 = good, 5 = excellent). The image quality was assessed on the basis of ability to resolve thoracic vertebral bodies, thoracic spinous processes, scapulae, proximal third of ribs, caudal lobar pulmonary vessels, and aortic arch, and also on the basis of image noise.

The difference in image quality between technique 1 and 2, or technique 1 and 3 were analyzed using visual grading characteristics (VGC), which was introduced by Bath and Mansson, because the analysis of rating data from ordinal scales requires non-parametric rank-invariant statistical analysis, and VGC fulfills this requirement (3). VGC handles visual grading data in similar fashion to receiver operating characteristic (ROC) analysis, and the variation in the visual grading of the evaluators of two imaging techniques can be used to describe the variation between the two techniques in the same way as in an ROC study. VGC analysis was performed in three steps. First, the number of images that scored each of 1 to 5 was computed in 2×5 frequency tables for technique 1 and 2, or technique 1 and 3. Second, the VGC data points were arranged according to the cumulative frequencies of images with score = 5, score ≥ 4 , score ≥ 3 , score ≥ 2 , and score ≥ 1 , respectively. Finally, the VGC points including the origin were plotted to produce VGC curves using the same software for obtaining ROC curves (ROCFIT: a web-based calculator for ROC curves; Baltimore: Johns Hopkins University [updated 2014 March 19; cited]. Available from: <http://www.rad.jhmi.edu/jeng/javarad/roc/JROCFITi.html>). As in a ROC curve the origin of a VGC curve per definition is "0". The area under the curve (AUC_{VGC}), as well as the estimated standard deviation (SD) of AUC_{VGC} , were computed to

Table 1. Median S-value (interquartile range) for each technique and body thickness

Technique	Grid	Body thickness (cm)	S-value
Technique 1	-	≤30	287 (245–346)
		31–40	373 (325–579)
		>40	540 (459–836)
Technique 2	3 : 1	≤30	546 (490–679)
		31–40	817 (673–1008)
		>40	1077 (855–1127)
Technique 3	8 : 1	≤30	972 (836–1280)
		31–40	1592 (1167–2294)
		>40	1828 (1486–1871)

**Fig. 2. Visual Grading Characteristics (VGC) curves obtained using the aggregated scores from all calves.** (A) Technique 2 (using a 3 : 1 grid). (B) Technique 3 (using an 8 : 1 grid). The dotted line indicates the diagonal with equal performance.

qualify the difference in image quality between technique 1 and 2, or technique 1 and 3. A curve equal to the diagonal, equivalent to an AUC_{VGC} of 0.5, indicates equality between the two techniques investigated. The greater the AUC_{VGC} (>0.5) indicates better image quality for the exposure technique on the vertical axis of the plot. If $|AUC_{VGC} - 0.5| > 1.96 SD$ then the difference in image quality was considered significant ($P < 0.05$) (14). If $|AUC_{VGC} - 0.5| > 2.58 SD$ then the significance level was assigned as $P < 0.01$.

Results

The S-values for each technique and body size are summarized in Table 1. The S-values increased as the grid ratio or body size increased. The VGC curves obtained from the aggregated scores of all calves in technique 1 and 2, or technique 1 and 3, are shown in Fig. 2. The results of VGC analysis showed that image quality was graded significantly higher for technique 2 than technique 1, whereas there were no differences in image quality between techniques 1 and 3. The AUC_{VGC} s for technique 2

Table 2. AUC_{VGC} (SD) for each technique and body thickness

	AUC _{VGC}		
	≤30 cm	31-40 cm	>40 cm
Technique 2	0.77 (0.052)*	0.75 (0.050)*	0.67 (0.061)*
Technique 3	0.66 (0.059)*	0.40 (0.056)	0.60 (0.064)

* $P < 0.01$ (vs Technique 1)

decreased as the size of the calves increased, but there were statistically significant differences in image quality between techniques 1 and 2 for all categories (body size ≤ 30 cm, $P < 0.01$; 31-40 cm, $P < 0.01$; > 40 cm, $P < 0.01$) (Table 2). However, there were no significant differences in image quality between techniques 1 and 3 for calves larger than 30 cm in thickness (body size < 30 cm, $P < 0.01$; 31-40 cm, $P > 0.05$; > 40 cm, $P > 0.05$).

Discussion

The most common type of radiographic study of the bovine thorax is a single lateral view of the dorsocaudal lung field using a large (14 × 17 inch) film, with the animal standing (18). This includes only a portion of the thorax in large calves, but the entire thorax in small calves. In our study, the entire thorax could be scanned in a single lateral view in five calves. Although these calves were small and the tube voltage used in this study was relatively low, the effects of scatter radiation cannot be disregarded. The scatter-to-primary ratio has been reported to be strongly dependent on the field of view, but weakly on the tube voltage (9). In addition, image quality was superior with the use of anti-scatter grids, even when using the same tube current as in a non-gridded technique, and even for a low tube voltage (60 kV) (17). In digital systems, anti-scatter grids improve contrast but increase the amount of noise (24); therefore, using anti-scatter grids can be beneficial as long as the image noise is kept at an acceptable level. Indeed, in spite of the fact that the S-values of 3 : 1 grid images in this study were far above

those of non-gridded images, the use of a 3 : 1 grid improved the image quality. The S-values of the 3 : 1 grid images in this study were quite high in comparison with the typically accepted range of 100-400 for portable chest radiography in humans (15). A phantom study has shown that grid images, with S-values equivalent to those of the 3 : 1 grid images in our study, had higher contrast-to-noise ratio than non-gridded images (23).

The image quality was improved by using a 3 : 1 grid for calves in all size categories. On the other hand, the image quality of radiographs using an 8 : 1 grid was superior to that of non-gridded images only for calves ≤ 30 cm in thickness. It was considered that the increase in visibility of structures outweighed the deterioration in radiographic noise in the images for smaller calves, but did not for larger calves, because of insufficient incident dose to the image receptor. There would be two major causes for insufficient incident dose, one the low output of the portable x-ray unit used in this study, the other the effects of grid misalignment. The x-ray unit had a maximum available tube setting of 80 kV and 15 mA, and exposure times longer than 0.13 sec resulted in susceptibility to respiratory motion artifact. Therefore, the radiation dose used in this study could not be increased. A previous study reported that image quality is superior with an anti-scatter grid even when using the same exposure factors as the non-gridded technique, but deteriorates when the exposure is too low (detector air kerma of 1 μ Gy) (17). It is possible that the use of an 8 : 1 grid would improve image quality even for calves thicker than 30 cm, if a more powerful portable x-ray

unit was used. When a higher tube voltage would be used, care must be taken to minimize personnel exposure, because a higher tube voltage generates more scatter radiation. Grid misalignment is almost inevitable in portable radiography (16). Although the 3 : 1 grid has lower contrast improvement factor than the 8 : 1 grid, the 3 : 1 grid has a wider angle tolerance (6). In this study, grid misalignment must have occurred to a certain extent and affected the image quality. This might be one of the reasons that the use of the 8 : 1 grid did not improve the image quality for calves thicker than 30 cm.

This study has several limitations. First, despite the fact that the images for each technique were taken consecutively in each calf, and an effort made to match the calf's position and respiratory motion for the images for each technique, it was impossible to take multiple radiographs in precisely the same manner when working with standing calves. Variability in calf positioning might have affected the S-values as well as the evaluation of image quality. However, each technique is expected to be affected by this variability to approximately the same degree. The study design is comparable to previous reports in humans that investigated the feasibility of using anti-scatter grids for mobile chest radiography (1, 13). Second, this study could not be performed in a completely blinded fashion, because the gridded images were distinguishable from the non-gridded images on the basis of image noise. The images were displayed in random order in an effort to minimize this issue. Third, the results of the grid performance for portable thoracic radiography in calves are applicable only to dairy calves ≤ 44 cm in body thickness, which was the largest calf included in this study. As calves mature, the body thickness increases, limiting penetration of x-ray. Therefore, the grid performance for larger calves would be deteriorated because of lower incident dose to the detector. Finally, the evaluation of image quality was performed using VGC, which is based on the visibility of normal structures and does not

assess diagnostic efficacy (3, 14). Therefore, one must be cautious in applying the results to clinical settings.

In conclusion, introduction of a 3 : 1 grid to portable thoracic radiography of the dorsocaudal region in calves improved overall image quality, at least for calves ≤ 44 cm in body thickness. A 3 : 1 grid appears to be more suitable than an 8 : 1 grid, considering the wider tolerance of the 3 : 1 grid to orientation errors and the low output of a portable x-ray unit. Further studies are needed to clarify whether a 3 : 1 grid can actually improve diagnostic efficacy in patients with thoracic diseases.

References

- 1) Anderson DW. Introduction of grids to mobile ICU radiography in a teaching hospital. *Br J Radiol* 79, 315-318, 2006
- 2) Baker M. Investigation into factors influencing Fuji S-value using an extremity phantom. *J Med Imaging Radiat Sci* 43, 34-37, 2012
- 3) Båth M, Månsson LG. Visual grading characteristics (VGC) analysis: a non-parametric rank-invariant statistical method for image quality evaluation. *Br J Radiol* 80, 169-176, 2007
- 4) Brown M, Brownrigg S. Equine and Large Animal Radiography. In: Lavin's Radiography for Veterinary Technicians, 5th ed. Brown M, Brown L. eds. Saunders, St. Louis. pp. 400-463, 2013.
- 5) Buczinski S, Forté G, Francoz D, Bélanger AM. Comparison of thoracic auscultation, clinical score, and ultrasonography as indicators of bovine respiratory disease in preweaned dairy calves. *J Vet Intern Med* 28, 234-242, 2014
- 6) Carlin MD, Nishikawa RM, MacMahon H, Doi K. The effect of x-ray beam alignment on the performance of antiscatter grids. *Med Phys* 23, 1347-1350, 1996
- 7) Constable PD, Hinchcliff KW, Done SH, Gruenberg W. *Veterinary Medicine: A textbook of the diseases of cattle, horses, sheep, pigs and goats*, 11th ed. Saunders, St. Louis. pp. 845-1094, 2017
- 8) Divers TJ. Respiratory diseases. In: *Rebhun's Diseases of Dairy Cattle*, 2nd ed. Divers TJ,

- Peek SF. eds. Saunders, St. Louis. pp. 79-129, 2007.
- 9) Fritz S, Jones AK. Guidelines for anti-scatter grid use in pediatric digital radiography. *Pediatr Radiol* 44, 313-321, 2014
 - 10) Gauntt DM, Barnes GT. An automatic and accurate x-ray tube focal spot/grid alignment system for mobile radiography: system description and alignment accuracy. *Med Phys* 37, 6402-6410, 2010
 - 11) Gorden PJ, Plummer P. Control, management, and prevention of bovine respiratory disease in dairy calves and cows. *Vet Clin North Am Food Anim Pract* 26, 243-259, 2010
 - 12) Jung C, Bostedt H. Thoracic ultrasonography technique in newborn calves and description of normal and pathological findings. *Vet Radiol Ultrasound* 45, 331-335, 2004
 - 13) Lehnert T, Naguib NN, Wutzler S, Bauer RW, Kerl JM, Burkhard T, Schulz B, Larson MC, Ackermann H, Vogl TJ, Balzer JO. Comparative study between mobile computed radiography and mobile flat-panel radiography for bedside chest radiography: impact of an antiscatter grid on the visibility of selected diagnostically relevant structures. *Invest Radiol* 49, 1-6, 2014
 - 14) Ludewig E, Richter A, Frame M. Diagnostic imaging-evaluating image quality using visual grading characteristic (VGC) analysis. *Vet Res Commun* 34, 473-479, 2010
 - 15) MacCutcheon DW. Management of pediatric radiation dose using Fuji computed radiography. *Pediatr Radiol* 34 (Suppl 3), S201-206, 2004
 - 16) MacMahon H, Yasillo NJ, Carlin M. Laser alignment system for high-quality portable radiography. *Radiographics* 12, 111-120, 1992
 - 17) Moore CS, Wood TJ, Avery G, Balcam S, Needler L, Smith A, Saunderson JR, Beavis AW. Investigating the use of an antiscatter grid in chest radiography for average adults with a computed radiography imaging system. *Br J Radiol*, 88, 20140613, 2015
 - 18) Morgan JP. *Techniques of Veterinary Radiography*, 5th ed. pp. 383-432, Wiley-Blackwell, Oxford, 1993.
 - 19) Ollivett TL, Caswell JL, Nydam DV, Duffield T, Leslie KE, Hewson J, Kelton D. Thoracic Ultrasonography and Bronchoalveolar Lavage Fluid Analysis in Holstein Calves with Subclinical Lung Lesions. *J Vet Intern Med* 29, 1728-1734, 2015
 - 20) Poulsen KP, McGuirk SM. Respiratory disease of the bovine neonate. *Vet Clin North Am Food Anim Pract* 25, 121-137, 2009
 - 21) Rabeling B, Rehage J, Döpfer D, Scholz H. Ultrasonographic findings in calves with respiratory disease. *Vet Rec* 143, 468-471, 1998
 - 22) Reinhold P, Rabeling B, Günther H, Schimmel D. Comparative evaluation of ultrasonography and lung function testing with the clinical signs and pathology of calves inoculated experimentally with *Pasteurella multocida*. *Vet Rec* 150, 109-114, 2002
 - 23) Scott AW, Gauntt DM, Yester MV, Barnes GT. High-ratio grid considerations in mobile chest radiography. *Med Phys* 39, 3142-3153, 2012
 - 24) Tanaka N, Naka K, Saito A, Morishita J, Toyofuku F, Ohki M, Higashida Y. Investigation of optimum anti-scatter grid selection for digital radiography: physical imaging properties and detectability of low-contrast signals. *Radiol Phys Technol* 6, 54-60, 2013