

# Doppler ultrasound – a valid and reliable tool to assess spondyloarthritis

Sandra Falcão<sup>1</sup>, Eugenio De Miguel<sup>2</sup>, Concepción Castillo<sup>2</sup>, Jaime C Branco<sup>1</sup>, Emilio Martín-Mola<sup>2</sup>

ACTA REUMATOL PORT. 2012;37:212-217

## ABSTRACT

Enthesitis is the hallmark of spondyloarthritis and is observed in all subtypes. Namely, a wide information on spondyloarthritis abnormalities, including synovitis, bursitis, tendinitis, enthesitis and cortical bone abnormalities (erosions and enthesophytes), can be efficiently perceived by ultrasound power Doppler. Furthermore, several studies on imaging of entheses showed that imaging techniques are better than clinical examination to detect pathology at asymptomatic entheses. Vascularized enthesitis detected by ultrasound power Doppler appears to be a valuable diagnostic tool to confirm spondyloarthritis diagnosis. This article focuses on the validity and reliability of ultrasound enthesitis assessment in the management of spondyloarthritis patients.

**Keywords:** Ultrasound; Power Doppler; Enthesitis; Spondyloarthritis

## BACKGROUND

There is an increasing interest among rheumatologists for using ultrasonography (US) as an investigation and management tool for musculoskeletal disorders<sup>1</sup>. This imaging modality has not only a number of advantages, such as low cost, good accessibility, and ability to dynamic real-time assessment of multiple joints in relatively short period of time, but also the ability to detect and monitor bone and joint soft tissue inflammation and its structural sequelae<sup>2</sup>. A growing body of evidence in many rheumatic conditions, such as rheumatoid arthritis (RA) and ankylosing spondylitis (AS), suggests that US is a high sensitive and non-invasive tool in the

detection and monitoring of early synovitis, bone erosions, tenosynovitis and enthesitis<sup>3,4</sup>. The early detection of inflammatory joint pathologies would ideally allow clinicians to initiate relevant therapies in order to prevent destruction of bone and joint soft tissue, and, subsequently, improve morbidity and long-term outcome.

Spondyloarthritis (SpA) is a group of disorders that are characterized by inflammatory involvement of the entheses and the adjacent bone<sup>5</sup>. Enthesitis is regarded as the primary lesion and is observed in all SpA subtypes, and may sometimes be present several years as an isolated clinical manifestation<sup>6-8</sup>. Encouraging data suggest that US enthesitis scores could be used as a valid tool for SpA assessment<sup>9,10</sup>.

Chronic inflammatory low back pain and radiographic changes involving the sacroiliac joints are key diagnostic features for AS according to the modified New York (MNY) criteria established in 1984<sup>11</sup>. Although the MNY criteria have been widely used in both clinical and research settings the absence of both radiographic sacroiliitis and impaired spinal mobility at early stages of the disease have contributed to a long delay (5-10 years) in AS diagnosis in many patients<sup>12</sup>. Recently the Assessment of SpondyloArthritis International Society (ASAS) developed new classification criteria for axial SpA that demonstrated much better specificity compared to the European Spondylarthropathy Study Group (ESSG) criteria modified for Magnetic Resonance Image (MRI) (sensitivity 85.1%, specificity 65.1%) and slightly superior to the modified Amor criteria (sensitivity 82.9%, specificity 77.5%)<sup>13</sup>. Nevertheless the sensitivity of ASAS classification criteria for peripheral SpA was slightly worse compared to the registered for axial SpA ASAS criteria (77.8% versus 82.9%)<sup>14</sup>. Despite these encouraging data, several studies on imaging of entheses showed that imaging techniques, such as MRI or US are superior to clinical examination, and frequently pathology at asymptomatic entheses might only be detected by imaging te-

\*Rheumatology, Faculdade de Ciências Médicas da Universidade Nova de Lisboa. Lisbon, Portugal

\*\*La Paz University Hospital, Rheumatology Unit. Madrid, Spain

chniques<sup>8,15</sup>. Furthermore, it has been suggested that US might be superior to MRI for detecting early signs of enthesopathy<sup>16,17</sup>.

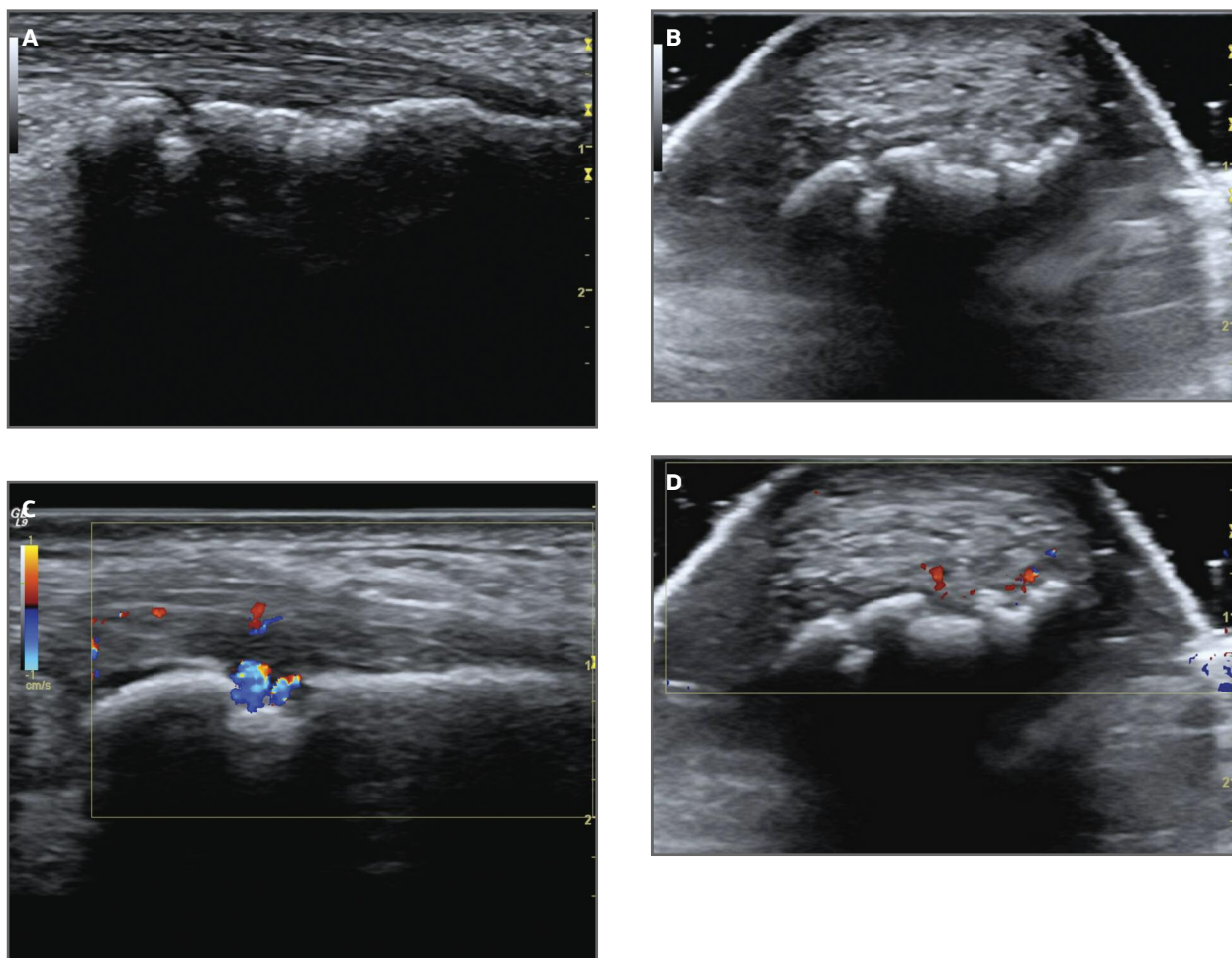
Despite the promising results about US examination of the enthesis in SpA, further research should be prompt to assess its specific role in diagnosis and follow up of disease course. This article focuses on the validity and reliability of US enthesitis assessment in the management of SpA patients.

### VALIDITY OF ULTRASOUND ENTHESITIS ASSESSMENT IN SPONDYLOARTHRITIS

US provide a widely information on SpA abnormalities, including synovitis, bursitis, tendinosis, enthesi-

tis and cortical bone abnormalities (erosions and enthesophytes).

The Outcome Measures in Rheumatology Clinical Trials (OMERACT) defines enthesopathy as an “abnormally hypoechoic (loss of normal fibrillar architecture) and/or thickened tendon or ligament at its bony attachment (may occasionally contain hyperechoic foci consistent with calcification), seen in 2 perpendicular planes that may exhibit Doppler signal and/or bony changes including enthesophytes, erosions, or irregularity” (Figure 1)<sup>18</sup>. Although grey-scale US depict enthesis structural damage, it seems that the combination with power Doppler increases diagnostic accuracy for SpA. The first description was made by D’Agostino and colleagues who demonstrated that US, in grey-scale combined with power Doppler, allowed



**FIGURE 1.** Ultrasonographic images of Achilles enthesopathy: (A) Longitudinal view: thickening, loss of fibrillar pattern, bone proliferation and erosions. (B) Transversal view: loss of fibrillar pattern and erosions. (C) Longitudinal view: thickening, loss of fibrillar pattern, bursa, erosions and Doppler signal. (D) Transversal view: loss of fibrillar pattern, erosions and Doppler signal

the detection of abnormal vascularization at enthesis insertion into cortical bone profile in the majority of SpA patients, but not in mechanical back pain or RA patients. This study included 164 SpA patients and 64 controls (thirty four with mechanical back pain and thirty with RA). Abnormal US findings consistent with at least one enthesitis were observed in 98% and 52% of SpA and control patients, respectively. US enthesitis was most commonly distributed in the distal portion of the lower limbs, irrespective of SpA subtype and of skeletal distribution of clinical symptoms, and none of abnormal enthesitis in control patients showed vascularization, compared with 81% of enthesitis in SpA patients<sup>8</sup>. More recently, the same author reported in a prospective single-center cohort study with 118 patients that power Doppler US detection of at least one vascularized enthesitis provided good predictive value for diagnosing SpA (sensitivity 76.5%, specificity 81.3%, positive likelihood ratio 4.1, OR 14.1,  $p < 0.0001$ )<sup>19</sup>.

In recent years, several US scores for enthesitis SpA structural damage assessment have been developed. Balint and colleagues developed the GUESS (Glasgow Ultrasound Enthesitis Scoring System). In this index an enthesitis score is formulated from the detection of bursitis, structure thickness, bony erosion, and enthesophyte (bony spur) on US examination of both lower limbs at five enthesial sites (superior pole and inferior pole of patella, tibial tuberosity, Achilles tendon, and plantar aponeurosis). The authors concluded that US is better than clinical examination in the detection of enthesitis in patients with SpA<sup>20</sup>. Alcalde and colleagues have tested an index (Sonographic Enthesial Index - SEI) that evaluates five enthesial regions from both lower limbs. Hypoechoogenicity, increased tendon thickness, peritendinous oedema and bursitis were considered as signs of acute injury (SEI-A); and insertional bone erosions, intratendinous calcifications, decreased thickness and tears as chronic lesions (SEI-C). Each variable was scored in absent (0) or present (1) and total SEI was the sum of SEI-A and SEI-C (maximum 76 points). SEI correlated with lower Shober's test, but not with other SpA activity or severity parameters<sup>10</sup>. These studies represent the landmark of US enthesitis attempt for structural damage assessment, but they did not include power Doppler signal on US lesion evaluation. Based on previous data, power Doppler signal is highly sensitive for detection of small vessels<sup>21</sup>, is significantly correlated with clinical examination<sup>22</sup>, and enables the distinction between inflam-

matory enthesitis and enthesial lesions of purely mechanical origin<sup>8</sup>. In this regard, de Miguel and colleagues elaborated a 136-point US-based scoring, examining elemental structural damage, including power Doppler signal, in twelve enthesial areas: proximal plantar fascia, distal Achilles tendon, distal and proximal patellar ligament, distal quadriceps and brachial triceps tendon. Enthesis thickness, structure, calcifications/cortical bone proliferation, erosions, bursa, and power Doppler were scored in cortical bone profile, tendon, and bursa of 25 SpA patients and 29 healthy controls. After logistic regression analysis of the core of three of the elementary lesions were overestimated: calcifications (0-3), Doppler (0 or 3) and erosion (0 or 3); while scoring tendon thickness, structure and bursa were classified as 0 or 1 (absence/presence). The established US score of  $\geq 18$  was the best cut-off point for differentiation between cases and controls; and demonstrated a sensitivity, specificity, positive and negative likelihood ratios of 83.3%, 82.8%, 4.8%, and 0.2%, respectively, for the diagnosis of SpA regardless of the presence of other clinical manifestations<sup>9</sup>. Kiris and colleagues evaluated the relationship between power Doppler US SpA enthesitis assessment and the Maastricht Ankylosing Spondylitis Enthesis Index. This study illustrated some important points that should be considered. Firstly, clinical examination of enthesitis seemed to be sensitive, except for Achilles tendon assessment where the US power Doppler was significantly more accurate. Secondly, clinical and sonographic results were discordant for three regions of the thirteen explored enthesitis (first costochondral joint, seventh costochondral joint and iliac crest) where tenderness of enthesitis occurred without ultrasonographically proven enthesitis. Results were probably related with the chosen US acoustic window. Thirdly, in agreement with other data, pain or tenderness of enthesitis is related to local increased vascularity easily detected by power Doppler, and thus the value of a uniform system for grading enthesitis should be properly adapted to assess its role in diagnosis and follow up of disease course<sup>22</sup>.

Recent data suggest that power Doppler US can also be efficiently used in diagnosis of early SpA<sup>19,23</sup>. Using the Madrid sonography enthesitis index (MASEI) as a model de Miguel and colleagues developed a cross-sectional, blinded and controlled study including 113 early SpA patients. A cut-off point of MASEI  $\geq 18$  achieved a positive likelihood ratio of 4.26, sensitivity and specificity of 87.26% and 84.21%, respective-

ly, for SpA diagnosis. Furthermore, it seems that entheses are early affected in SpA, and the incidence of involvement is higher in men and independent of SpA subtypes, HLA-B27 status or presentation pattern (axial, peripheral or mixed forms)<sup>23</sup>.

The therapeutic follow up of structural damage represents another potential goal for power Doppler US use in SpA. The introduction of targeting therapies, in particular tumor necrosis factor (TNF)-alpha blocking drugs, has seen unprecedented success in the treatment of signs and symptoms of SpA<sup>24</sup>, but current radiographic follow up data suggest that these drugs do not affect the bone proliferation process<sup>25</sup>. This apparent lack of structural stopping effect is in sharp contrast to what is seen for the erosive joint destruction in RA and represents a differential finding in SpA<sup>26</sup>. Although evidence supports the apparent inefficacy of anti-TNF drugs on bone formation in SpA pathophysiologic process, it seems that other enthesal abnormalities detected by US, such as morphologic abnormalities (tendon hypoechogenicity and/or thickening), power Doppler signal, and bursitis are responsive to these drugs<sup>27</sup>. Underlying the relevance of knowledge on enthesal pathophysiologic events in SpA; and supporting the challenge of introduce the US entheses study in SpA to improve the objective knowledge about disease activity, structural permanent damage, and its relation with present and future disease assessment tools.

#### **RELIABILITY OF ULTRASOUND ENTHESITIS ASSESSMENT IN SPONDYLOARTHRITIS**

It is a consensual fact that one of the major disadvantages of musculoskeletal US is operator dependency. The images generated are mainly qualitative and agreement as to be reached by different observers as to the presence or absence of pathological signs of disease. If quantitative measurements are required, then intra- and inter-observer errors become more important. Few studies have evaluated the overall reliability of US in rheumatology, most of them have been accomplished in RA patients or regarded joint examination<sup>28-31</sup>. Despite promising results, prior to the implementation of US as a valid method for detecting and monitoring the disease process in SpA patients, reliability assessment is crucial.

Previous reports have already studied the intra and inter-observer reliability in US enthesal study, using

a pragmatic methodology concerning the interpretation of static images<sup>8,9,20,22</sup>. More recent data have been published, with valid results on acquisition and interpretation of images using patients<sup>9,10,32</sup>.

Furthermore, moderate to excellent intra and inter-observer agreements were found, not only for most of the US elementary lesions indicative of enthesopathy<sup>32,34</sup>, but also for the conventional two-dimensional and three-dimensional assessments of enthesal sonographic lesions<sup>35</sup>. Filippucci and colleagues obtained weighted kappa values estimating the inter and intra-observer agreements for soft tissue inflammation of 0.696 and 0.816, respectively and for tissue damage of 0.711 and 0.901, respectively. The levels of agreement were estimated using a dichotomous (presence/absence) and a semi-quantitative score system for assessment of Achilles tendon enthesopathy. The elementary Achilles enthesal US findings that characterized soft tissue inflammation were tendon hypoechogenicity, tendon thickening, enthesal hypoechogenicity, bursal effusion and power Doppler signal at tendon, enthesal or bursal level. Therefore lesions such as intra-tendineous or enthesal calcifications, enthesophytes, bone erosions or bone irregularities were considered as tissue damage. This study revealed a relatively poor agreement concerning two elementary lesions: bone irregularity and enthesal hypoechogenicity, with inter-observer unweight kappa values of 0.2 and 0.49, respectively. Reasons such as the affection of tendon hypoechogenicity by anisotropy or the difficulty to reach a consensus about which bone irregularities represent a pathologic state were pointed by the authors for the relatively low Kappa values obtained<sup>33</sup>. This study illustrated an important point: lower levels of agreement generally are in the context of inter-observer image acquisition rather than intra-reader agreement level, which is generally more demanding and examiner-dependent.

Moreover, when evaluated the level of agreement between 2D and 3D of Achilles entheses erosions two different authors achieved excellent kappa values of 0.85 and 0.86<sup>34,35</sup>.

However, to improve the reliability of US to assess enthesitis in SpA more data are needed concerning evaluation of inter-machine reliability<sup>18</sup>. In this regard we studied prospectively one hundred and ninety-two entheses of nine SpA patients with two US equipments: Acuson-Antares Siemens (Medical Systems equipment) with a lineal 5-13 MHz probe (equipment 1; 9 patients 108 entheses) and LOGIQ9 (GE Healthcare)

**TABLE I. AGREEMENT BETWEEN READER 1 AND 2 MASEI SCORING USING A LOGIC9 AND AN ACUSON-ANTARES SIEMENS**

	Interpretation of Static Images	
	(ICC)	(95%CI; p)
Inter-reader / US equipment 1 (n=9)	0.97	0.90-0.99; p<0.0001
Inter-reader / US equipment 2 (n=7)	0.93	0.67-0.98; p<0.0001

with a lineal 9-14 MHz probe (equipment 2; 7 patients 84 entheses). The following enthesal sites were examined bilaterally in longitudinal and transversal plane: proximal plantar fascia, distal Achilles tendon, distal and proximal patellar ligament, distal quadriceps, and brachial triceps tendons. The obtained images were punctuated according MASEI score by two sonographers with different levels of experience in US (an expert US rheumatologist familiarized with MASEI score and a rheumatologist with training on US). Prior to the study consensus rules about entheses scanning, the definition about abnormal findings, and the MASEI score system were achieved. The lectures were blinded to clinical data and carried out independently. Inter-reader, and inter-US equipment reliability were assessed according to the two-way, mixed-effect model (absolute agreement) and single-measure intraclass correlation coefficients (ICCs). A Kappa value less than 0.20 was considered poor, between 0.41 and 0.60 moderate, between 0.61 and 0.80 good, and between 0.81 and 1 excellent<sup>36</sup>. They were determined by SPSS (version 10.5), and values of  $p < 0.05$  were considered significant. The inter-reader and inter-equipment agreements are reported in Table I and Table II, respectively. With regard to the inter-equipment reliability good to excellent results were achieved.

To the best of our knowledge, this was the first study to investigate the inter-equipment reliability for assessing enthesitis in SpA. The low variability achieved could reflect the importance of specific training, and consensus rules that took place prior the study. The two sonographers had different levels of experience in performing MASEI scoring system, but they routinely search for morphologic and elementary lesions used in this score system in their daily practice. Such aspect would possibly make easier the improvement of skills that they

**TABLE II. AGREEMENT BETWEEN EQUIPMENT 1 AND 2 OF MASEI SCORING PERFORMED BY READER 1 AND 2**

	Interpretation of Static Images	
	(ICC)	(95%CI; p)
Inter-equipment - reader 1 (n=7)	0.77	0.20-0.95; p<0.01
Inter-equipment - reader 2 (n=7)	0.87	0.33- 0.97; p<0.0001

were already very familiar with, and lowered the variability of a technique that includes several possible sources of discrepancy between sonographers, such as definition, detection, and scoring of lesions, and data acquisition. In this sense a standardized model for teaching sonographers with different levels of experience achieves an effective learning on entheses US<sup>37</sup>.

In summary, US seem to be a valid and reliable tool, even inter-equipment, to assess enthesitis in SpA. Nevertheless, its ultimate utility in the core set of SpA diagnostic criteria and disease monitoring remains to be determined, and prior clinical application, learning and strict consensus guidelines are highly warranted.

#### CORRESPONDENCE TO

Sandra Falcão  
Hospital Egas Moniz, Centro Hospitalar de Lisboa Ocidental.E.PE.  
Rheumatology Department  
Rua da Junqueira n°126  
1200 Lisbon, Portugal  
E-mail: sfalcao76@gmail.com

#### REFERENCES

- Grassi W, Salaffi F, Filippucci E. Ultrasound in rheumatology. *Best Pract Res Clin Rheumatol* 2005;19:467-485.
- Wakefield RJ, D'Agostino MA, Iagnocco A et al. The OMERACT Ultrasound Group: Status of Current Activities and Research Directions. *J Rheumatol* 2007;34:848-851.
- Bresnihan B, Kane D: Sonography and subclinical synovitis. *Ann Rheum Dis* 2004;63:333-334.
- Kane D, Grassi W, Sturrock R, Balint PV. Musculoskeletal ultrasound –a state of the art review in rheumatology. Part 2: Clinical indications for musculoskeletal ultrasound in rheumatology. *Rheumatology* 2004;43:829-838.
- D'Agostino MA, Olivieri I. Enthesitis. *Best Pract Res Clin Rheumatol* 2006;20:473-86.
- McGonagle D, Khan MA, Marzo-Ortega H, O'Connor P, Gibbon W, Emery P. Enthesitis in spondyloarthropathy. *Curr Opin Rheumatol* 1999;11:244-250.

7. McGonagle D, Khan MA, Marzo-Ortega H et al. Histological assessment of the early enthesitis lesion in spondyloarthropathy. *Ann Rheum Dis* 2002;61:534-537.
8. D'Agostino MA, Said-Nahal R, Hacquard-Bouder C, Brassier JL, Dougados M, Breban M. Assessment of Peripheral Enthesitis in the Spondylarthropathies by Ultrasonography Combined with Power Doppler. A Cross-Sectional Study. *Arthritis Rheum* 2003;48:523-533
9. E de Miguel, Cobo T, Muñoz-Fernández S et al. Validity of enthesitis ultrasound assessment in spondylarthropathy. *Ann Rheum Dis* 2009;68:169-174.
10. Alcalde M, Acebes JC, Cruz M, Gonzáles-Hombrado L, Herro-Beaumont G, Sánchez-Pernaute O. A Sonographic Enthesitic Index of lower limbs is a valuable tool in assessment of ankylosing spondylitis. *Ann Rheum Dis* 2007;66:1015-1019.
11. van der Linden S, Valkenburg HA, Cats A. Evaluation of diagnostic criteria for ankylosing spondylitis. A proposal for modification of the New York criteria. *Arthritis Rheum* 1984; 27:361-368.
12. Feldtkeller E, Khan MA, van der Heijde D, van der Linden S, Braun J. Age at disease onset and diagnosis delay in HLA-B27 negative vs. positive patients with ankylosing spondylitis. *Rheumatol Int* 2003;23:61-66.
13. Rudwaleit M, van der Heijde D, Landewé R et al. The development of Assessment of SpondyloArthritis international Society classification criteria for axial spondyloarthritis (part II): validation and final selection. *Ann Rheum Dis* 2009;68:777-783.
14. Rudwaleit M, van der Heijde D, Landewé R et al. The Assessment of SpondyloArthritis International Society classification criteria for peripheral spondyloarthritis and for spondyloarthritis in general. *Ann Rheum Dis* 2011;70:25-31.
15. McGonagle D, Gibbon W, O'Connor P, Green M, Pease C, Emery P. Characteristic magnetic resonance imaging enthesial changes of knee synovitis in spondylarthropathy. *Arthritis Rheum* 1998;41:694-700.
16. Kamel M, Eid H, Mansour R. Ultrasound detection of heel enthesitis: a comparison with magnetic resonance imaging. *J Rheumatol* 2003;30:774-778.
17. Kamel M, Eid H, Mansour R. Ultrasound detection of knee patellar enthesitis: a comparison with magnetic resonance imaging. *Ann Rheum Dis* 2004;63:213-214.
18. Wakefield RJ, Balint PV, Szkuclarek M et al. Musculoskeletal Ultrasound Including Definitions for Ultrasonographic Pathology. *J Rheumatol* 2005;32:2485-2487.
19. D'Agostino MA, Aegerter P, Bechara K et al. How to diagnose spondyloarthritis early? Accuracy of peripheral enthesitis detection by power Doppler ultrasonography. *Ann Rheum Dis* 2011;70:1433-1440
20. Balint PV, Kane D, Wilson H, McInnes, Sturrock RD. Ultrasonography of enthesial insertions in lower limb in spondylarthropathy. *Ann Rheum Dis* 2002;61: 905-910.
21. Koski JM, Saarakkala S, Helle M, Hakulinen U, Heikkinen JO, Hermunen H. Power Doppler ultrasonography and synovitis: correlating ultrasound imaging with histopathological findings and evaluating the performance of ultrasound equipments. *Ann Rheum Dis* 2006;65:1590-1595.
22. Kiris A, Kaya A, Ozgocmen S, KocaKoc E. Assessment of enthesitis in ankylosing spondylitis by power Doppler ultrasonography. *Skeletal Radiol* 2006;35:522-528.
23. de Miguel E, Muñoz-Fernández S, Castillo C, Cobo-Ibáñez T, Martín-Mola E. Diagnostic accuracy of enthesitis ultrasound in the diagnosis of early spondyloarthritis. *Ann Rheum Dis* 2011;70:434-439.
24. Braun J, Sieper J. Ankylosing spondylitis. *Lancet* 2007;369: 1379-1390.
25. Braun J, Baraliakos X. Treatment of ankylosing spondylitis and other spondyloarthritides. *Curr Opin Rheumatol.* 2009;21: 324-334.
26. van der Heijde D, Klareskog L, Rodriguez-Valverde V et al. Comparison of etanercept and methotrexate, alone and combined, in the treatment of rheumatoid arthritis: two-year clinical and radiographic results from the TEMPO study, a double-blind, randomized trial. *Arthritis Rheum* 2006;54:1063-1074.
27. Naredo E, Batlle-Gualda E, García-Vivar ML et al. Power Doppler ultrasonography assessment of entheses in spondyloarthropathies: response to therapy of enthesial abnormalities. *J Rheumatol* 2010;37:2110-2117.
28. Balint PV, Sturrock RD. Intraobserver repeatability and interobserver reproducibility in musculoskeletal ultrasound imaging measurements. *Clin Exp Rheumatol* 2001;19:89-92.
29. Szkudlarek M, Court-Payen M, Jacobsen S, Klarlund M, Thomsen HS, Ostergaard M. Interobserver agreement in ultrasonography of the finger and toe joints in rheumatoid arthritis. *Arthritis Rheum* 2003;48:955-962.
30. Scheel AK, Schmidt WA, Hermann KG et al. Interobserver reliability of rheumatologists performing musculoskeletal ultrasonography : results from a EULAR "Train the trainers" course. *Ann Rheum Dis* 2005;64:1043-1049.
31. Bruyn GA, Naredo E, Moller I et al. Reliability of ultrasonography in detecting shoulder disease in patients with rheumatoid arthritis. *Ann Rheum Dis* 2008; E-pub ahead of print.
32. D'Agostino MA, Aegerter P, Jousse-Joulin S et al. How to Evaluate and Improve the Reliability of Power Doppler Ultrasonography for Assessing Enthesitis in Spondylarthritis. *Arthritis Rheum* 2009;61:61-69.
33. Filippucci E, Aydin S, Karadag O et al. Reliability of high-resolution ultrasonography in the assessment of Achilles tendon enthesopathy in seronegative spondyloarthropathies. *Ann Rheum Dis* 2009;68:1850-1855.
34. de Miguel E, Falcao S, Castillo C et al. Enthesitis erosion in spondyloarthritis is not a persistent structural lesion. *Ann Rheum Dis* 2011. [Epub ahead of print].
35. Iagnocco A, Riente L, Delle Sedie A et al. Ultrasound imaging for the rheumatologist. XXII. Achilles tendon involvement in spondyloarthritis. A multi-centre study using high frequency volumetric probe. *Clin Exp Rheumatol* 2009;27:547-551.
36. Landis JR, Koch GG. The measurement of observer agreement for categorical data. *Biometrics* 1977;33:159-174.
37. Miguel C, De Miguel E, Batlle-Gualda E, Rejón E, Lojo L, Entheses ultrasound workshop group. Teaching Enthesitis Ultrasound: Experience of an Ultrasound Training Workshop. *Rheumatol Int* 2011. [Epub ahead of print].