



Mucosal Injury Following Short-Term Tracheal Intubation: A Novel Animal Model and Composite Tracheal Injury Score

Rishie Sinha, FRCA ; Ricardo Correia, PhD; David Gardner, PhD, DSc ; Llorenç Grau-Roma, PhD; Simone de Brot, DVM; Jonathan Hardman, PhD; Steve Morgan, PhD; Andrew Norris, FRCA

Objectives: Postintubation laryngotracheal injury is common. Assessment of histopathological changes currently requires animal models. We set about developing a viable, resource effective animal model to study these effects and to develop a detailed tissue injury score.

Methods: Six pigs were anesthetized using a standard regimen. We intubated the tracheas using a standard endotracheal tube modified to include optical sensors. Animals were anesthetized for a duration of two to four hours, and their lungs were ventilated using a normoxic gas mixture. Following euthanasia, the tracheas were removed and underwent histological assessment by two independent veterinary pathologists. The histological lesions, including controls, were described and quantified, and two pathologists classified tissues according to a novel injury score.

Results: Mean duration of tracheal intubation was 191 minutes (SD \pm 41.6). In all except one animal, cuff pressures were maintained in the range of 25–45 cmH₂O. Histopathological findings in all study animals showed more extensive changes than previously described with short-term intubation. Changes were seen in all mucosal layers consistent with acute, suppurative, and ulcerative tracheitis. The range of scores of the developed composite scoring system among the animals was wider than in earlier descriptions. There was a high percentage of agreement between both pathologists.

Conclusions: We have described a novel tracheal injury score to assess pathological changes following short term intubation in a viable animal model. The scoring system distinguished between the test animals as well as controls and may be appropriate for continuing study of intubation injury.

Key Words: Animals, constriction, pathologic, intratracheal, intubation, laryngostenosis, trachea, tracheal stenosis.

Level of Evidence: 3

INTRODUCTION

Endotracheal intubation can cause severe ischemic injury and permanent tracheal stenosis.^{1–5} Postintubation tracheal stenosis (PITS) being the most common cause of acquired tracheal stenosis.^{6,7} PITS is associated with

significant impact on quality of life and healthcare costs.⁵ The reported incidence ranges from 1% to 33% of all intubated patients.^{8–11} Injury is affected by duration of intubation, cuff properties, and inflation pressures.^{12–14} It is difficult to investigate these and similar effects in humans.

Animal models have been used to examine histopathological changes, but have been hindered by the perception that long periods of intubation, or excessive cuff pressures were required to induce measurable injury.^{15–19} In order to address this, Gordin et al. described a piglet model in which hypoxic gas mixtures were used to accelerate ischemic injury.²⁰ Although this model proved successful in inducing significant injury, the results may have been confounded by use of hypoxic conditions.

We have developed a novel endotracheal tube that incorporates optical sensors in the cuff.^{21–23} We needed to demonstrate functionality of sensors, and absence of obvious injury in a viable and translational animal model. Previous animal models were considered unsuitable for a variety of reasons including use of ambulatory animals, size of the animal, use of hypoxic gas mixtures to accelerate damage, or prolonged periods of ventilation.^{19,20} In this study, we describe an animal model suitable to assess the efficacy of sensors and influence of endotracheal cuff design, material, and cuff pressure management. We further describe the effect of short-term intubation, at conventional cuff pressures, on histopathology of the tracheal

This is an open access article under the terms of the Creative Commons Attribution-NonCommercial-NoDerivs License, which permits use and distribution in any medium, provided the original work is properly cited, the use is non-commercial and no modifications or adaptations are made.

From the Department of Anaesthesia (R.S., J.H.), Division of Clinical Neurosciences; and the Applied Optics Group (R.C., S.M.), Faculty of Engineering, University of Nottingham, Nottingham, UK; the School of Veterinary Medicine and Science (D.G., L.G.-R., S.dB.), University of Nottingham, Sutton Bonington Campus, Leicestershire, UK; and the Department of Anaesthetics (A.N.), Nottingham University Hospitals NHS Trust, Nottingham, UK.

Editor's Note: This Manuscript was accepted for publication 16 April 2018.

Funding and conflicts of interest: This work was supported by internal funding from The University of Nottingham.

RS, DG, LGR, SdB – no interests declared
 RC, JG, SM, AM – named inventors of sensorised endotracheal tube

JG – associate editor-in-chief of *British Journal of Anaesthesia* (BJA) and member of BJA editorial board

Acknowledgements: Members of staff, animal operating theatres, Sutton Bonington campus, University of Nottingham, UK.

Send correspondence to Dr. Rishie Sinha, University Department of Anaesthesia, C Floor, East Block, Queen's Medical Centre, Derby Road, Nottingham, NG7 2UH, UK. Email: rishie.sinha@nottingham.ac.uk

DOI: 10.1002/liv2.168

TABLE I.
Basic Parameters of Study Animals.

Pig	Weight (kg)	Core temperature range (degrees C) (mean and SD)	End-tidal carbon dioxide (kPa) (mean and SD)	Mean arterial pressure (kPa) (mean and SD)	Duration of tracheal intubation (minutes)
1	55	38.9 (0.98)	7.6 (0.47)	10.1 (0.91)	202
2	60	40.2 (2.68)	8.9 (0.47)	10.2 (1.63)	183
3	57			8.0 (1.06)	254
4	57	38.8 (0.21)	9.6 (0.47)	8.9 (2.77)	216
5	72	38.8 (1.20)	8.9 (0.47)	11.0 (3.78)	155
6	63	38.15 (0.07)	7.9 (0.94)	10.7 (1.80)	140
Control	50				140
Unintubated	58				None

epithelium and report a novel histopathological scoring system. Our primary objective was to develop a viable animal model to investigate tissue damage secondary to endotracheal tube cuff–pressure related injuries. Our secondary objective was to develop and validate an in-depth histopathological scoring system which would enable us to describe the injury noted in detail and that could be used in future studies of newer airway devices.

MATERIALS AND METHODS

Ethical approval was obtained and the work was performed under Home Office licence (PPL 40-3410).

We anesthetized six study pigs (Canberra 12) at 10 to 12 weeks of age, mean weight 60.6 kg. Pigs were fasted and sedated with intramuscular buprenorphine (0.05 mg/kg), ketamine (5 mg/kg) and detomidine (0.1 mg/kg). After 15 to 20 minutes, we intubated the tracheas with our novel endotracheal tubes (size 8.0 Mallinckrodt cuffed ET tube, Covidien UK) modified to include optical sensors in the cuffs. The optical fiber sensors (OFS) were placed outside the original tube cuff and a second cuff from a size 9.0 Mallinckrodt endotracheal tube was overlaid to create a double cuff. A detailed description of the OFS have been presented elsewhere.^{22,23}

General anaesthesia was induced using intravenous alfaxolone (0.7–2.4 mg/kg) and maintained with isoflurane (1–2%), in a mixture of oxygen and air to maintain oxygen saturations over 94%. The lungs were ventilated with a tidal volume of 10 to 12 ml/kg and alveolar ventilation adjusted to an ET CO₂ of 6 to 8 kPa. Core temperature was monitored using a rectal probe. Intravenous Hartmann's fluids were infused at the rate of 5 ml/kg/hr. Cardiovascular data (blood pressure and heart rate) were recorded using radiotelemetry probes (Telemetry Research, distributed by Millar Ltd, Oxon, UK) implanted into the carotid artery. Data are minute means ± standard error of the mean.

We initially used 5 mL of air to inflate the cuff as per routine veterinary practice in our unit. However, this led to intracuff pressures over 50 cm H₂O. In subsequent animals, the cuff was inflated in 1-mL increments to the point of adequate ventilation as guided by David Gardner. Contact pressure was recorded using a SmartScan Interrogator (Smart Fibres Ltd., Bracknell, UK). The pressures in subsequent animals were noted to be in the range of 23 to 45 cm H₂O. The mucosal flow sensor recorded data using a software programme developed in-house based on Labview (National Instruments Corporation, Newbury, UK).

Following the procedure, the pigs were humanely killed using sodium pentobarbitone (200 mg/kg). The larynx and

trachea were removed as a single unit. The exact position of the inflated endotracheal tube cuff was recorded in situ. Tissue samples proximal, at the point of cuff pressure, and distal to the cuff were taken and preserved in 10% formal saline for 24 h at 4°C, washed in 0.1 M Phosphate–buffered saline (PBS) for 24 h and stored in 70% ethyl alcohol prior to trimming and embedding in paraffin wax blocks. In addition, two control specimens were prepared one from an un-intubated trachea and one intubated using a conventional endotracheal tube.

Evaluation of Laryngotracheal Samples

Several consecutive and parallel cross-sections were performed in a cranio-caudal fashion separated by 1 ± 0.3 cm. Each section was divided into two cassettes, labelled, and routinely processed for histology using hematoxylin and eosin staining. The pathologists worked separately at first using the scoring system by Gordin et al.²⁰ but this did not provide us adequate detail. As a result, a new scale was devised in order to provide more information about the extent of tissue damage. Having agreed on a scoring system, tissue samples were analyzed using this scoring system by one of the pathologists who had been blinded to study protocol. In order to assess inter-rater reliability, a random selection of 30 slides were scored independently by two pathologists. These scores were inspected and analyzed using split-half reliability with Spearman-Brown adjustment. Retrospectively, all scores were examined. One hundred fifty scores were assigned in total by each pathologist. In only five cases did scores differ by 2 or more (Table II).

The following parameters were assessed: loss of cilia; epithelial flattening; epithelial ulceration; inflammatory changes; and presence of hemorrhages. Changes in the first four parameters were semi-quantified as absent (0), mild (1), moderate (2), or severe (3). In the case of cilia loss, epithelial flattening and epithelial ulceration, mild equated to <50% of cilia loss, moderate equated to <90%, and severe equated to diffuse damage. Ulcerated areas by definition included areas with cilia loss and epithelial flattening. Inflammatory changes were assessed in the first inner three layers of tissue (mucosa, submucosa and perichondrium) and a summative score allocated as absent (0), affecting only the mucosa (1), affecting mucosa and submucosa (2), and affecting all tissue layers (3). Hemorrhages were graded as absent (0) or present (1).

We combined the scores to create the Nottingham Composite Tracheal Injury (NCTI) score encompassing injury to all tissue layers, the summative inflammatory score, and the presence of hemorrhages.

We present our scores alongside the grading systems previously described, where 0 = no damage, 1 = compression of

TABLE II.
Comparison of Raw Scores Between Reviewer 1 (R1) and Reviewer 2 (R2) Prior to Validation.

	Cilia loss		Epithelial flattening		Ulceration		Inflammation		Haemorrhage		Total	
	R1	R2	R1	R2	R1	R2	R1	R2	R1	R2	R1	R2
1	3	3	1	1	1	0	2	2	0	0	7	6
2	2	2	2	2	1	1	3	3	1	1	9	9
3	3	3	2	2	1	1	3	2	0	0	9	8
4	2	0	0	0	0	0	2	2	0	0	4	2
5	3	1	1	0	2	0	2	2	0	0	8	3
6	3	3	1	1	1	0	3	2	0	0	8	6
7	1	1	1	1	1	1	3	3	0	0	6	6
8	1	1	1	1	1	0	2	2	0	0	5	4
9	3	3	1	1	1	1	2	2	0	0	7	7
10	3	3	1	1	1	0	2	2	0	0	7	6
11	3	3	2	2	2	2	3	2	0	0	10	9
12	3	3	3	3	3	3	2	2	0	0	11	11
13	3	3	1	1	1	1	3	2	0	0	8	7
14	2	1	0	0	0	0	2	2	1	0	5	3
15	3	2	2	2	2	2	3	3	0	1	10	10
16	3	3	0	0	0	0	2	2	0	0	5	5
17	3	3	2	2	1	0	3	2	0	0	9	7
18	3	3	1	1	0	0	2	2	0	0	6	6
19	2	2	1	1	0	0	2	2	0	0	5	5
20	3	3	1	1	1	1	3	2	0	0	8	7
21	3	3	1	1	1	1	3	2	0	0	8	7
22	3	3	2	2	0	0	2	2	1	0	8	7
23	0	0	0	0	0	0	2	2	0	0	2	2
24	2	1	0	0	0	0	2	2	0	0	4	3
25	3	3	2	2	1	1	2	2	0	0	8	8
26	2	2	1	1	1	1	3	2	1	0	8	6
27	1	0	1	1	0	0	3	2	0	0	5	3
28	2	2	2	2	1	1	3	3	0	0	8	8
29	3	3	1	1	1	1	2	2	0	0	7	7
30	1	1	0	0	0	0	2	2	0	0	3	3

Tissue changes: 0 = absent; 1 = mild; 2 = moderate; 3 = severe. Inflammation: 0 = absent; 1 = affecting only the mucosa; 2 = affecting the mucosa and submucosa; 3 = affecting all tissue layers. Hemorrhages: 0 = absent; 1 = present.

epithelial layer, 2 = epithelial loss, 3 = sub-epithelial and glandular inflammation or necrosis, and 4 = Perichondrium inflammation.^{20,24}

RESULTS

Animal 2 developed early signs of malignant hyperthermia, a known complication of general anaesthesia within pigs,^{25,26} and the procedure was terminated at two hours. In one pig, the core temperature and end-tidal carbon dioxide data were not correctly recorded, so these data have been omitted, however, this data would not have impacted tissue changes described. The basic parameters of all the studied animals including the unintubated and one intubated with a conventional red rubber tube are listed below (Table I).

The animals were ventilated for a mean time of 191 minutes (SD ± 41.6). Cuff pressures were maintained in

the range of 23 to 45 cm H₂O (25–55 cm H₂O for animal 1). Histological findings from the test animals were consistent with an acute, suppurative, and ulcerative tracheitis, (Figs. 1 and 2).^{8,27} All lesions were scored using our composite tracheal injury score. Loss of cilia in epithelial cells was extensive in most sections. There were multifocal areas of epithelial flattening and ulceration within the trachea. Inflammation was predominantly neutrophilic within the tracheal epithelium and a mixture of neutrophils and lymphocytes with edema in the lamina propria and submucosal layers. In two sections from two different animals the inflammation extended to the perichondrium. In addition, two of the animals (4 and 6) showed lesions of squamous metaplasia in the tracheal epithelium. These lesions are chronic and are therefore presumed to be pre-existing to the current procedure.

The sample of trachea intubated using a conventional ET tube demonstrated similar lesions to the study

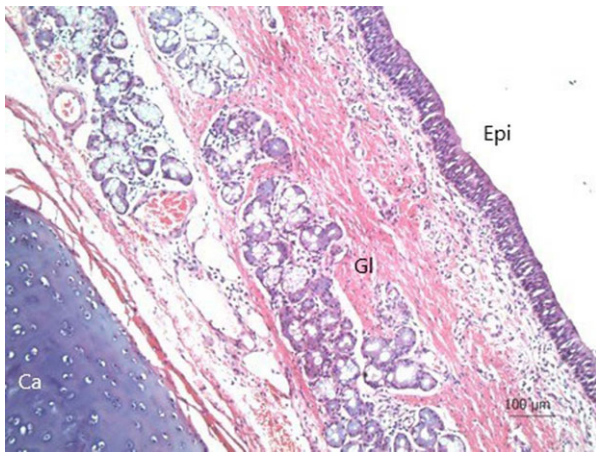


Fig. 1. Tracheal section from an unintubated animal. Minimal numbers of lymphocytes are present within the lamina propria and submucosa. 10x. Hematoxylin & Eosin. Ca = cartilage; Ep = epithelium; Gl = submucosal glands.

animals, ranging from a subacute non-suppurative tracheitis to that of an acute, suppurative, and ulcerative tracheitis. Unintubated tracheas had none of the above indications of damage to the tracheal epithelium, with only low numbers of inflammatory cells within the epithelium, lamina propria, and submucosa. The raw scores are presented in Table II. As can be seen there was a high degree of agreement between the reviewers for the raw data (Cronbach's alpha: 0.93; split-half reliability with Spearman-Brown adjustment: 0.93).

Inflation pressures and contact pressure from a recording are shown in Figure 3. This is from animal 1, which was subjected to relatively high cuff pressures early on. Overall, contact pressures and inflation pressures are similar as we would expect from a large volume PVC cuff. It can be seen that the deflated cuff in this case was already in tracheal contact from the point

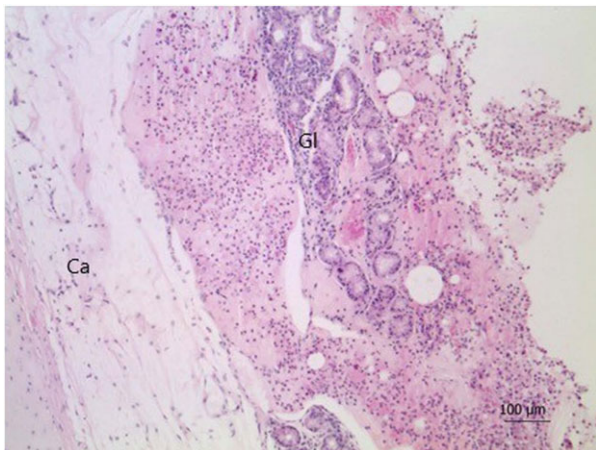


Fig. 2. Tracheal section from an intubated animal. There is diffuse ulceration of the tracheal mucosa and abundant neutrophils admixed with pale extracellular eosinophilic material (edema) within the lamina propria and submucosa. 10x. Hematoxylin & Eosin. Ca = cartilage; Gl = submucosal glands.

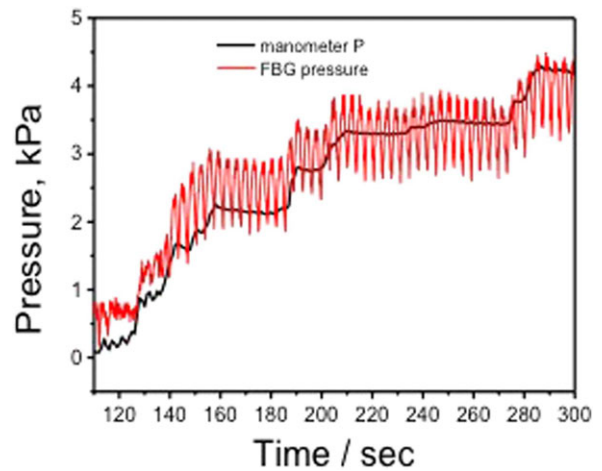


Fig. 3. Mean contact pressure (red line) and intra-cuff pressure (black line) during cuff inflation. This graph is from animal 1 which was subjected to higher than expected endotracheal tube cuff pressures.

of insertion, with pressure of around 1kPa (~10 cmH₂O). Subsequent stepwise inflation can be seen. The variation in the contact pressure is due to ventilator cycling. The point at which the inflated cuff makes contact is at around 130 mS. The mean contact pressure is around 0.5 kPa higher than the inflation pressure for lower pressures in the normally recommended range of 2 to 3 kPa, but this pattern reverses at higher pressures of 3 to 3.5 kPa.

The range of scores of the developed NCTI scoring system among the animals was wider than in earlier descriptions (Table III). We compare the NCTI alongside the grading system described above by Gordin and Bassi (Fig. 4).^{20,24}

DISCUSSION

This study demonstrated significant mucosal injury following short-term tracheal intubation at near recommended cuff inflation pressures. We assessed mucosal injury using a novel composite injury score derived from that described by Gordin et al.²⁰

The strengths of the current study are that a translationally relevant animal model for adult anesthetic and intensive care practice has been used (animal size, equipment, cuff pressures, and period of ventilation). Histopathology was assessed independently, with strong agreement between pathologists, and with pathologists unaware of ET tube characteristics (novel, conventional, or unintubated). The extent of pathological changes were greater than previous literature led us to expect given the short duration and near recommended pressures used.

The study has some limitations. Sample size was small, however, the pathological changes in all pigs were obvious and consistent. The severity of changes displayed some variation, and a larger study may have allowed some insight into what constituted a typical injury score. Potentially, the injuries could have been

TABLE III.
Nottingham Composite Tissue Tracheal Injury Score as a Summation of Damage in the Various Layers of Tissue.

Animal no.	Cilia loss	Epithelial flattening	Epithelial ulceration	Inflammation	Haemorrhages	Nottingham composite tracheal injury score
1	2	2	2	2	-	8
2	1	1	2	2	-	6
3	2	2	2	2	1	7
4	2	1	1	2	-	6
5	1	2	2	2	-	7
6	3	1	1	2	-	7
Control (away from cuff site)	0	0	0	2	-	2
Control (cuff site)	3	2	2	2	-	9
Unintubated	0	0	0	1	-	1

Tissue changes: 0 = absent; 1 = mild; 2 = moderate; 3 = severe. Inflammation: 0 = absent. 1 = affecting only themucosa; 2 = affecting mucosa and submucosa; 3 = affecting all tissue layers. Hemorrhages: 0 = absent; 1 = present.

affected by the modifications to the endotracheal tubes, ie, the addition of a second cuff and the presence of the OFS. Histological sections however showed no evidence of focused area of injury. In addition, we also examined the trachea of an animal that was intubated using a conventional endotracheal tube and a nonintubated trachea. The trachea from the animal intubated with a conventional red rubber tube showed similar changes to our experimental animals and no injury was seen in the unintubated trachea.

We maintained cuff pressures close to what is accepted as a conventional range. Higher pressures were sometimes needed in order to achieve mechanical ventilation.

The pathological features of ischemic tracheal injury secondary to tracheal intubation are well-documented.^{2,9,11,27-29} However, our understanding of the relative contributions of contact pressures, tube materials, cuff shape, and contour would be helped by having an accurate, reliable, and sensitive injury score as well as an animal model that does not require extended periods

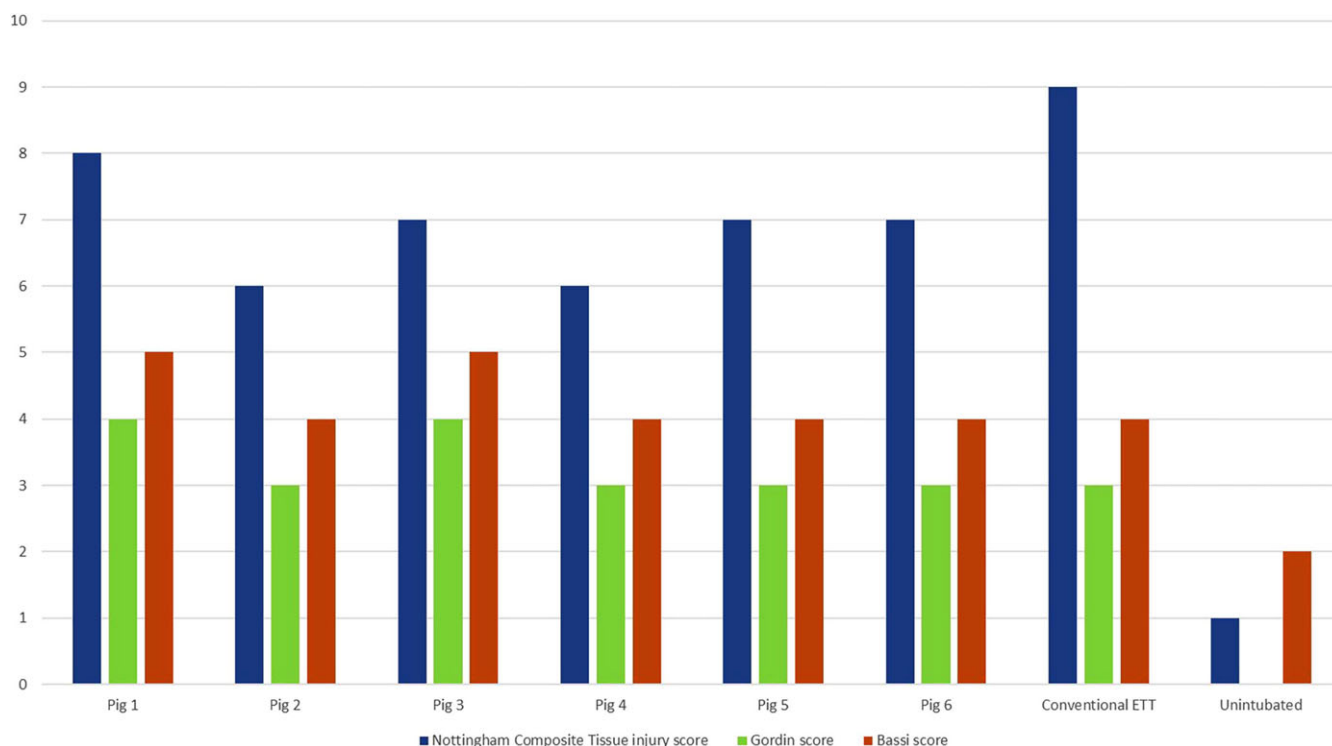


Fig. 4. Nottingham Composite Tracheal Injury scoring system compared with Gordin and Bassi scores.

of mechanical ventilation or artificial conditions to accelerate tissue injury.^{18,20}

Gordin et al.'s model generated rapid histopathological change, but only under hypoxic conditions in relatively small piglets (15–18 kg).²⁰ It has been noted that local hypoxia is one of the important contributory factors in the development of laryngotracheal injury.^{11,30} Additive systemic hypoxia has the benefit of accelerating tissue changes, but may also alter the nature and extent of injury. The results from ambulatory nonanesthetized or mechanically ventilated animal models of laryngotracheal damage may lack transferability to clinical practice.¹⁶

Changes noted in previous studies which differed by whether the animals were anesthetized, duration of intubation, and the age and weight characteristics of the population studied were also demonstrable in this study but after only two to four hours of ventilation at near normal pressures.^{16,27,31–33} In an age where carrying out animal studies is becoming increasingly difficult, our model allows for multiple utility of each animal utilized for study purposes.

Histopathological changes in previous studies have been largely restricted to measurement of depth of injury.^{8,20,24} We argue there is need for a more detailed and sensitive analytical tool. Previous scoring systems have examined samples histologically and graded them (0–4) based purely on the presence of injury in the various layers of tissue. Our scoring system provides for the identification of injury in the various layers but also quantifies this in significant detail thereby providing a nuanced, in-depth score of tracheal injury. We believe this model and scoring system will aid in study of the efficacy of future airway devices with differing characteristics (materials, cuff design, pressure managements systems) in minimizing the occurrence of endotracheal cuff pressure mediated injury. We are ourselves in the process of developing a new multiple sensor equipped endotracheal tube and an effective model with a detailed injury scoring system will enable us to examine comparative performance.

CONCLUSION

In summary, we describe a model for the study of laryngotracheal injury secondary to tracheal intubation in a relevant timescale that does not require hypoxic ventilation to accelerate changes. The model is consistent with simultaneously performing other investigations making it cost-effective, as well as minimizing the use of animals. Our NCTI Score provides a more detailed description of injury than existing scales. In addition, we are currently investigating the possibility of mucosal injury assessment in vivo using optical coherence tomography which could reduce or avoid the need for animal studies.³⁴

BIBLIOGRAPHY

1. El-Boghdady K, Bailey CR, Wiles MD. Postoperative sore throat: A systematic review. *Anaesthesia* 2016;71(6):706–717.
2. Whited RE. A prospective study of laryngotracheal sequelae in long-term intubation. *Laryngoscope* 1984;94(3):367–377.
3. Weymuller EA. Laryngeal injury from prolonged endotracheal intubation. *Laryngoscope* 1988;98(S45):1–15.
4. Zias N, Chroneou A, Tabba MK, et al. Post tracheostomy and post intubation tracheal stenosis: report of 31 cases and review of the literature. *BMC Pulm Med* 2008;8(1):18.
5. Lahav Y, Shoffel-Havakuk H, Halperin D. *Acquired Glottic Stenosis-The Ongoing Challenge: A Review of Etiology, Pathogenesis, and Surgical Management*. Elsevier, Vol 29; 2015:646.
6. Lorenz RR. Adult laryngotracheal stenosis: etiology and surgical management. *Curr Opin Otolaryngol Head Neck Surg* 2003;11(6):467–472.
7. Colton House J, Noordzij JP, Murgia B, Langmore S. Laryngeal injury from prolonged intubation: a prospective analysis of contributing factors. *Laryngoscope* 2011;121(3):596–600.
8. Lindholm CE. Prolonged Endotracheal Intubation. *Acta Anaesthesiol Scand Suppl* 1969;13:1–80.
9. Stauffer JL, Olson DE, Petty TL. Complications and consequences of endotracheal intubation and tracheotomy: a prospective study of 150 critically ill adult patients. *Am J Med* 1981;70(1):65–76.
10. Pearson F, Goldberg M. Tracheal stenosis complicating tracheostomy with cuffed tubes: clinical experience and observations from a prospective study. *Arch Surg* 1960;97(3):380–394.
11. Kastanos N, Miro RE, Perez AM, Mir AX, Agusti-Vidal A. Laryngotracheal injury due to endotracheal intubation. *Crit Care Med* 1983;11(5):362–367.
12. Peppard S, Dickens J. Laryngeal injury following short-term intubation. *Ann Otol Rhinol Laryngol* 1983;92:327–330.
13. Hedden M, Ersoz CJ, Donnelly WH, Safar P. Laryngotracheal damage after prolonged use of orotracheal tubes in adults. *JAMA* 1969;207(4):703–708.
14. Mehta S, Mickiewicz M. Pressure in large volume, low pressure cuffs: its significance, measurement and regulation. *Intensive Care Med* 1985;11(5):267–272.
15. Nordin U, Lindholm CE, Wolgast M. Blood flow in the rabbit tracheal mucosa under normal conditions and under the influence of tracheal intubation. *Acta Anaesthesiol Scand* 1977;21(2):81–94.
16. Bishop MJ, Hibbard AJ, Fink BR, Vogel AM, Weymuller EA. Laryngeal injury in a dog model of prolonged endotracheal intubation. *Anesthesiology* 1985;62(6):770–773.
17. Bunegin L, Albin MS, Smith RB. Canine tracheal blood flow after endotracheal tube cuff inflation during normotension and hypotension. *Anesth Analg* 1993;76(5):1083–1090.
18. Shah MD, Nguyen LHP, Campisi P, James A, Taylor GP, Forte V. Piloting a novel porcine model for endolaryngeal injury following prolonged intubation. *Int J Pediatr Otorhinolaryngol* 2007;71(9):1399–1406.
19. Su Z, Li S, Zhou Z, Chen X, Gu Y, Chen Y. A canine model of tracheal stenosis induced by cuffed endotracheal intubation. *Sci Rep* 2017;7:45357.
20. Gordin A, Chadha NK, Campisi P, Luginbuehl I, Taylor G, Forte V. An animal model for endotracheal tube-related laryngeal injury using hypoxic ventilation. *Otolaryngol Neck Surg* 2011;144(2):247–251.
21. Morgan SP, Hayes-Gill BR, Korposh S, Correia R, Hardman J, Norris A. Airway maintenance device. 2016:Google Patents.
22. Hernandez FU, Correia R, Korposh S, et al. Measurements of endotracheal tube cuff contact pressure using fibre Bragg gratings. *Proceedings of the SPIE* 2015:963435.
23. Correia R, Blackman O, Hernandez F, Korposh S. Highly sensitive contact pressure measurements using FBG patch in endotracheal tube cuff. *Sixth Eur Work Opt Fibre Sensors* 2016:99161F-F-4.
24. Bassi GL, Luque N, Marti JD, et al. Endotracheal tubes for critically ill patients: An in vivo analysis of associated tracheal injury, mucociliary clearance, and sealing efficiency. *Chest* 2015;147(5):1327–1335.
25. Lucre JN, Hall GM, Lister D. Porcine malignant hyperthermia. I: Metabolic and physiological changes. *Br J Anaesth* 1976;48(4):297–304.
26. Hall GM, Bendall JR, Lucre JN, Lister D. Porcine malignant hyperthermia. II: Heat production. *Br J Anaesth* 1976;48(4):305–308.
27. Cooper JD, Grillo HC. The evolution of tracheal injury due to ventilatory assistance through cuffed tubes: a pathologic study. *Ann Surg* 1969;169(3):334–348.
28. Goldberg M, Pearson FG. Pathogenesis of tracheal stenosis following tracheostomy with a cuffed tube. An experimental study in dogs. *Thorax* 1972;27(6):678–691.
29. Grillo HC, Donahue DM. Postintubation tracheal stenosis. *Chest Surg Clin N Am* 1996;6(4):725–731.
30. Andrews MJ, Pearson FG. Incidence and pathogenesis of tracheal injury following cuffed tube tracheostomy with assisted ventilation: analysis of a two-year prospective study. *Ann Surg* 1971;173(2):249.
31. Gould SJ, Howard S. The histopathology of the larynx in the neonate following endotracheal intubation. *J Pathol* 1985;146(4):301–311.
32. Rasche R, Kuhns L. Histopathologic changes in airway mucosa of infants after endotracheal intubation. *Pediatrics* 1972;50(4):632–637.
33. Sato K, Nakashima T. Histopathologic changes in laryngeal mucosa of extremely low-birth weight infants after endotracheal intubation. *Ann Otol Rhinol Laryngol* 2006;115(11):816–823.
34. Michel RG. Optical Coherence Tomography. In: Ernst A, Herth F, eds. *Principles and Practice of Interventional Pulmonology* New York: Springer; 2013:237–245.