

Myositis ossificans – Another condition with *USP6* rearrangement, providing evidence of a relationship with nodular fasciitis and aneurysmal bone cyst[☆]

Elise M. Bekers^{a,b}, Astrid Eijkelenboom^a, Katrien Grünberg^a, Rona C. Roverts^a,
Jacky W.J. de Rooy^c, Ingrid C.M. van der Geest^d, Joost M. van Gorp^e, David Creyten^f,
Uta Flucke^{a,*}

^a Department of Pathology, Radboud University Medical Center, Nijmegen, The Netherlands

^b Department of Pathologie (Pathologie-DNA), Jeroen Bosch Hospital, Den Bosch, The Netherlands

^c Department of Radiology and Nuclear Medicine, Radboud University Medical Center, Nijmegen, The Netherlands

^d Department of Orthopedics, Radboud University Medical Center, Nijmegen, The Netherlands

^e Department of Pathology (Pathologie-DNA), Diaconessenhuis Utrecht, Utrecht, The Netherlands

^f Department of Pathology, Ghent University Hospital, Ghent, Belgium

ARTICLE INFO

Keywords:

USP6 rearrangement
Myositis ossificans
Soft tissue tumors

ABSTRACT

Myositis ossificans is defined as a self-limiting pseudotumor composed of reactive hypercellular fibrous tissue and bone.

USP6 rearrangements have been identified as a consistent genetic driving event in aneurysmal bone cyst and nodular fasciitis. It is therefore an integral part of the diagnostic workup when dealing with (myo)fibroblastic lesions of soft tissue and bone. Two cases of myositis ossificans with *USP6* rearrangement were published so far.

We determine herein the incidence of *USP6* rearrangement in myositis ossificans using *USP6* fluorescence in situ hybridization analysis (FISH). Of the 11 cases included, seven patients were female and four were male. Age ranged from 6 to 56 years (mean 27 years). Lesions were located in the thigh (n = 5), knee (n = 1), lower leg (n = 1), lower arm (n = 1), perineum (n = 1), gluteal (n = 1) and thoracic wall (n = 1).

All assessable cases except one (8/9) showed rearrangement of *USP6* providing evidence that myositis ossificans is genetically related to nodular fasciitis and aneurysmal bone cyst.

1. Introduction

Myositis ossificans is defined as a self-limiting pseudotumor composed of reactive hypercellular fibrous tissue and bone. This rapid growing and involuting lesion is mostly located in the skeletal muscle of the extremities or limb girdles of young patients and is usually interpreted as a posttraumatic lesion [1,2]. However, its cause is debated since its early description in 1892 [3].

The clinical characteristics depend on the developmental stage; the early phase is characterized by a painful swelling and within 6 weeks after onset it becomes more circumscribed and firm. Eventually, it evolves into a painless, well-demarcated hard lump with a diameter of ca. 3 to 6 cm [1].

Radiographically, soft tissue fullness is observed in the early stage. Subsequently, calcification becomes apparent with patchy and irregular densities maturing after approximately 6 weeks into a bony periphery with a radiolucent center [1].

The histological findings reflect those of the clinical symptoms and radiology. The early stage is characterized by nodular fasciitis-like features and additional development of woven bone terminally showing a prominent zonation with cancellous bone at the periphery [1,2]. In addition, entrapment of muscle fibers is often observed.

Since *USP6* rearrangement was identified as a consistent genetic driving event, initially in aneurysmal bone cyst (ABC) and later in nodular fasciitis as well, it is an integral part of diagnostic workup when dealing with (myo)fibroblastic lesions of soft tissue and bone [4–9].

Interestingly, two cases of myositis ossificans containing *USP6* rearrangements were published by Sukov et al. and classified as being aneurysmal bone cysts of soft tissue [10].

We therefore set out to determine the incidence of *USP6* rearrangement in myositis ossificans using *USP6* fluorescence in situ hybridization analysis (FISH).

[☆] This research did not receive any specific grant from funding agencies in the public, commercial, or not-for-profit sectors.

* Corresponding author at: Radboud University Medical Center, Department of Pathology, P.O. Box 9101, 6500 HB Nijmegen, The Netherlands
E-mail address: uta.flucke@radboudumc.nl (U. Flucke).

2. Material and methods

The cases were retrieved from the authors' (referral) files. Clinical details were obtained from the referring physicians. The study was conducted in accordance with the Code of Conduct of the Federation of Medical Scientific Societies.

In all cases the tissue was fixed in 4% buffered formalin, routinely processed including decalcification, if needed, and embedded in paraffin; 2–4 μm thick sections were stained with hematoxylin and eosin.

USP6 FISH detection was performed on paraffin sections of 4 μm . Slides were mounted and dried for 45 min at 55 °C. They were deparaffinized in xylene for 5 min, rehydrated in ethanol (99,5%) and demineralized water. Pretreatment with 10 mM Sodiumcitrate (pH = 6.0) at 96 °C for 10 min followed and after cooling down, rinsing in demineralized water. Slides were rinsed with 0,01 M HCL for 5 min and cells were digested by 200 U/ml pepsin (0,01 M HCL) for 15 min at 37 °C. To remove pepsin, slides were rinsed 3 \times shortly with 0,01 M HCl and rinsed with PBS. Slides were fixated in 1% formaldehyde/PBS for 5 min. After that, slides were rinsed shortly with PBS and demineralized water and finally dehydrated in increasing ethanol series and are dried.

For the ISH staining, 10 μl USP6 (Kreatech, KBI-00094 split probe, Leica, Rijswijk, The Netherlands) was applied per pre-treated slide. The probe incubated area were covered with a cover glass and sealed with photo glue. The slides were denaturated at 80 °C for 10 min and hybridization overnight at 37 °C. After hybridization the slides were washed in 2xSSC at 42 °C for 5 min to remove the cover glass, washed for 1 \times 1 min and 1 \times 2 min in 2xSSC-NP40 3% washbuffer at 73 °C and rinsed with 2xSSC for 5 min (covered). Slides were dehydrated again in increasing ethanol series to demineralized water and were dried. Slides were covered with Vectashield mounting medium with DAPI (Vector, Brunswick, Amsterdam, The Netherlands) and stored at 4 °C.

USP6 signals were scored by two independent experienced technicians and considered positive if at least 20% of the 50 counted cells showed split signals. Slides were scored using a Leica DM4000 (Leitz) fluorescence microscope with a Leica DFC310 FX camera and LAS AF software.

As positive control, we included 10 samples of nodular fasciitis and 10 aneurysmal bone cysts.

3. Results

Clinical and FISH results are summarized in Table 1. Of the 11 patients included, seven were female and four were male. The age ranged from 6 to 56 years (mean 27 years). Lesions were located in the thigh (n = 5), knee (n = 1), lower leg (n = 1), lower arm (n = 1), perineum (n = 1), gluteal (n = 1) and thoracic wall (n = 1).

By computed tomography, coronal reconstruction, bone window, a diffuse swelling of the proximal rectus femoris muscle with faint peripheral calcifications was seen (Case 8) (Fig. 1). On MRI, TSE T2-

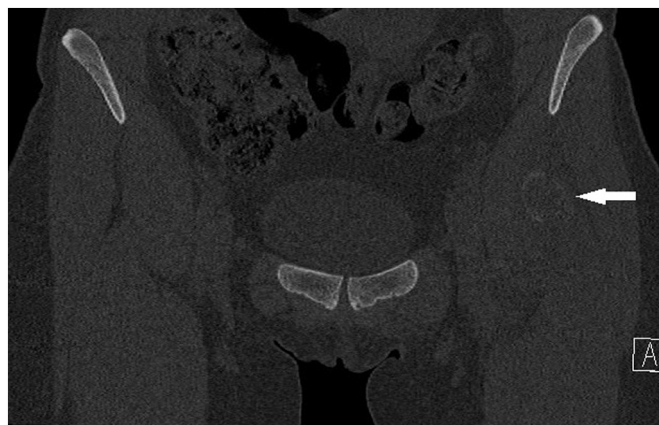

Fig. 1. By CT, a diffuse swelling of the proximal rectus femoris muscle with faint peripheral calcifications was seen (Case 8).

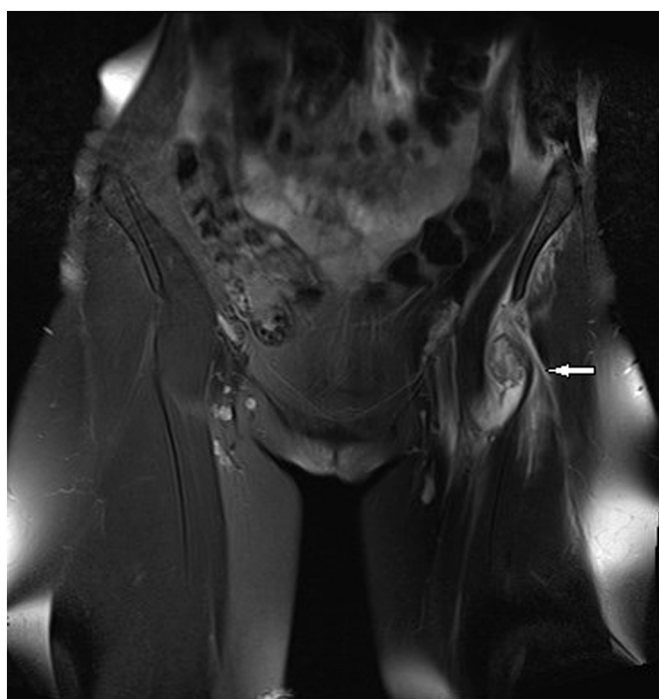


Fig. 2. On MRI, a sharply delineated lesion with inhomogeneous high signal intensity with peripheral low signal intensity was observed (Fig. 2).

weighted coronal image with fat saturation of the same patient showed a sharply delineated lesion with inhomogeneous high signal intensity with peripheral low signal intensity (Fig. 2).

Six patients underwent resection, in the remaining patients, only a biopsy was taken until now.

Grossly, all lesions were located in the voluntary muscle. The resection specimens showed an ill-defined, firm nodule with gray-white appearance and gritty areas. Small cystic spaces were seen in one case (Case 3).

Microscopically, the lesions showed an infiltrative growth with entrapped muscle fibers. Nodular fasciitis-like areas with tissue culture-like myofibroblasts intermingled with woven bone maturing peripherally were seen in all cases. There was osteoblast rimming without atypia. Scattered around, osteoclastic giant cells in a varying number were observed (Fig. 3). ABC-like pseudocystic spaces were present in only one case (Case 3, Fig. 4).

Using FISH, USP6 rearrangement were shown in eight out of 11 cases with one case being negative (< 10% signals) (Fig. 5). Two cases

Table 1
Clinical and FISH results.

Case #	Sex/age	Site	USP6 FISH (% of nuclei)
1	f/24	Perineum	> 50
2	f/19	Lower leg	34
3	m/28	Lower arm	failed
4	m/44	Thoracic wall	20
5	m/25	Thigh	25
6	f/17	Thigh	50
7	f/38	Thigh	30
8	f/32	Thigh	50
9	f/8	Knee	25
10	m/56	Thigh	< 10
11	f/6	Gluteal	Failed

f, female; m, male.

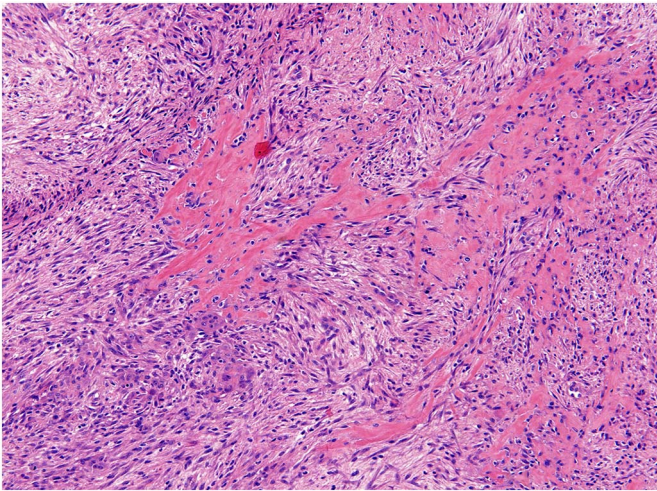


Fig. 3. Classical features of myositis ossificans showing tissue culture-like myofibroblasts intermingled with woven bone were seen in all cases.

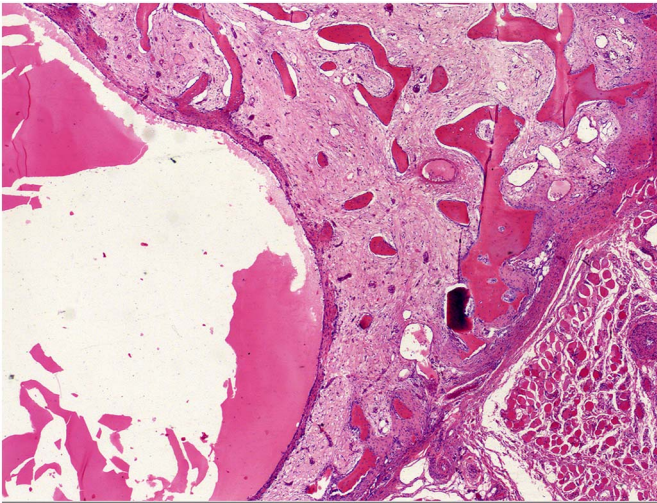


Fig. 4. ABC-like pseudocystic spaces were present in Case 3.

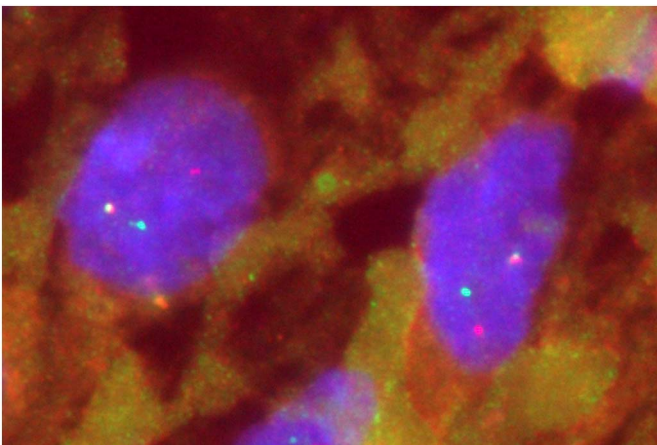


Fig. 5. Using FISH break apart signals of *USP6* were seen in 8/9 cases demonstrating rearrangement.

repeatedly failed for analysis, probably related to decalcified end stage areas (Table 1).

4. Discussion

Nodular fasciitis, myositis ossificans and aneurysmal bone cyst share clinicopathologic characteristics. First, they mainly occur in young patients. Second, the soft tissue lesions, nodular fasciitis and myositis ossificans, are of short duration with rapid growth and secondary involution, also called transient neoplasms [1,2,5,11,12].

All three entities are microscopically related by the presence of bland looking tissue culture like (myo)fibroblastic cells. Osteoclasts are mainly present in the two bone forming lesions and secondary pseudocystic changes are possible in all three neoplasms although they are most prominent in aneurysmal bone cyst, as expected. In exceptional cases, nodular fasciitis shows metaplastic bone formation, called fasciitis ossificans [1,2,11,12].

Another neoplasm clinicopathologically related to aneurysmal bone cyst is giant cell lesion of small bones [13].

The most convincing argument for these conditions forming a spectrum rather than distinct entities is the presence of *USP6* rearrangement [4,5,7,8,13]. This is supported by our study with rearrangement in eight out of nine cases (89%).

Interestingly, the presence of *USP6* rearrangement has also been described in a subset of cellular fibromas of the tendon sheath, retrospectively assigned to nodular fasciitis [14].

USP6 (ubiquitin specific protease) is one of deubiquinating enzymes involved in several cellular processes as intracellular trafficking, protein turnover, inflammatory signaling, and cell transformation [7,11]. It has been shown that the *USP6* fusion genes result in *USP6* overexpression due to promoter switch. This in turn leads to tumorigenesis, osteoblastic maturation, osteolysis, inflammation and neovascularisation [7]. Jak1-STAT3, c-Jun/AP-1 and Wnt signaling are the known involved pathways [15,16,18].

There is a variety of fusion partners described in ABC which are mainly functionally assigned to the fibroblastic-osteoblastic lineage (*CDH11*, *TRAP150*, *ZNF9*, *OMD*, *COL1A1*, *RUNX2*, *PFAFH1B1*, *CTNNB1*, *SEC31A*, *EIF1*, *FOSL2*, *STAT3*) [7,17]. The common *USP6* fusion partner of nodular fasciitis is *MYH9*, normally expressed in subcutaneous fibroblasts [7]. Recently found novel fusion genes are *RRBP1*, *CALU*, *MIR22HG*, *SPARC*, *THBS2*, *COL6A2* and *CTNNB1*. The latter in overlap with aneurysmal bone cyst [8].

What fusion genes are present in myositis ossificans remain to be elucidated as *USP6* FISH has been performed. From the literature it is known that one of the *USP6* rearranged cases of myositis ossificans showed a fusion with *COL1A1*. The other case was negative for *CDH11* [7,10].

The most important entity that myositis ossificans must be distinguished from is extraskeletal osteosarcoma. This very rare tumor shows histologically atypical neoplastic osteoblast-like cells with pleomorphic nuclei. The typical zonation of bone is absent [1].

Other benign fibro-osseous conditions which could be considered in the differential diagnosis are subungual exostosis, florid reactive periostitis, bizarre parosteal osteochondromatous proliferation, and fibro-osseous pseudotumor of digits. However, the clinicopathological features are different with occurrence usually in fingers and toes and absence of the bone zonation pattern [1].

Simple excision is the optimal treatment of myositis ossificans and recurrence is exceptional [2].

In conclusion, we have identified *USP6* rearrangements in a series of myositis ossificans cases. We therefore argue that this entity belongs to the group of clonal transient neoplasms also including nodular fasciitis and aneurysmal bone cyst.

Conflict of interest

There are no conflicts of interest.

References

- [1] Rosenberg AE. Pseudosarcomas of soft tissue. *Arch Pathol Lab Med* 2008;132:579–86.
- [2] Rosenberg AE, Oliveira AM. Myositis ossificans and fibro-osseous pseudotumour of digits. In: Fletcher CDM, Bridge JA, Hogendoorn PCW, Mertens F, editors. *WHO Classification of Tumours of Soft Tissue and Bone*. IARC:Lyon; 2013. p. 50–1.
- [3] Taylor WJ. Myositis ossificans with a report of two cases – one traumatic, the other non-traumatic. *Ann. Surg.* 1903;37:825–33.
- [4] Oliveira AM, Hsi BL, Weremowicz S, Rosenberg AE, Dal Cin P, Joseph N, et al. *USP6 (Tre2)* fusion oncogenes in aneurysmal bone cyst. *Cancer Res* 2004;64:1920–3.
- [5] Erickson-Johnson MR, Chou MM, Evers BR, Roth CW, Seys AR, Jin L, et al. Nodular fasciitis: a novel model of transient neoplasia induced by *MYH9-USP6* gene fusion. *Lab Invest* 2011;91:1427–33.
- [6] Amary MF, Ye H, Berisha F, Tirabosco R, Presneau N, Flanagan AM. Detection of *USP6* gene rearrangement in nodular fasciitis: an important diagnostic tool. *Virchows Arch* 2013;463:97–8.
- [7] Oliveira AM, Chou MM. *USP6*-induced neoplasms: the biologic spectrum of aneurysmal bone cyst and nodular fasciitis. *Hum Pathol* 2014;45:1–11.
- [8] Patel NR, Chrisinger JS, Demicco EG, Sarabia SF, Reuther J, Kumar E, et al. *USP6* activation in nodular fasciitis by promotor-swapping gene fusions. *Mod Pathol* 2017;30:1577–88.
- [9] Li HR, Tai CF, Huang HY, Jin YT, Chen YT, Yang SF. *USP6* gene rearrangement differentiate primary paranasal sinus solid aneurysmal bone cyst from other giant cell-rich lesions, report of a rare case. *Hum Pathol* 2017.
- [10] Sukov WR, Franco MF, Erickson-Johnson M, Chou MM, Unni KK, Wenger DE, et al. Frequency of *USP6* rearrangements in myositis ossificans, brown tumor, and cherubism: molecular cytogenetic evidence that a subset of “myositis ossificans-like lesions” are the early phases in the formation of soft-tissue aneurysmal bone cyst. *Skeletal Radiol* 2008;37:321–7.
- [11] Lazar A, Evans HL, Oliveira AM. Nodular fasciitis. In: Fletcher CDM, Bridge J a., Hogendoorn PCW, Mertens F, editors. *WHO Classification of Tumours of Soft Tissue and Bone*. IARC:Lyon; 2013. p. 46–7.
- [12] Nielsen GP, Fletcher JA, Oliveira AM. Aneurysmal bone cyst. In: Fletcher CDM, Bridge JA, Hogendoorn PCW, Mertens F, editors. *WHO classification of tumours of soft tissue and bone*. Lyon: IARC; 2013. p. 348–9.
- [13] Agaram NP, FV LeLoarer, Zhang L, Hwang S, Athanasian EA, Hameed M, et al. *USP6* gene rearrangements occur preferentially in giant cell reparative granulomas of the hands and feet but not in gnathic location. *Hum Pathol* 2014;45:1147–52.
- [14] Carter JM, Wang X, Dong J, Westendorf J, Chou MM, Oliveira AM. *USP6* genetic rearrangements in cellular of fibroma of the tendon sheath. *Mod Pathol* 2016;29:865–9.
- [15] Madan B, Walker MP, Young R, Quick L, Orgel KA, Ryan M, et al. *USP6* oncogene promotes Wnt signaling by deubiquitylating Frizzleds. *Proc Natl Acad Sci U S A* 2016;113:E2945–54.
- [16] Quick L, Young R, Henrich IC, Wang X, Asmann YW, Oliveira AM, et al. Jak1-STAT3 signals are essential effectors of the *USP6/TRE17* oncogene in tumorigenesis. *Cancer Res* 2016;76:5337–47.
- [17] Guseva NV, Jaber O, Tanas MR, Stence AA, Sompallae R, Schade J, et al. Anchored multiplex PCR for targeted next-generation sequencing reveals recurrent and novel *USP6* fusions and upregulation of *USP6* expression in aneurysmal bone cyst. *Genes Chromosomes Cancer* 2017;56:266–77.
- [18] Li L, Yang H, Li T, Feng J, Chen W, Ao L, et al. The ubiquitin-specific protease *USP6* regulates the stability of the c-Jun protein. *Mol Cell Biol* 2018.