

*Erratum with Corrected and Republished Article*

In the article by Sonekatsu M *et al.* entitled “**Total Hip Arthroplasty for Patients with Residual Poliomyelitis at a Mean Eight Years of Follow-up**”, which appeared in the February 2018 issue, Vol.72, No.1, pp17-22, following corrections should be listed.

Editorial Office sincerely apologizes for making mistakes in the previous galley proof, therefore republish a corrected version.

1. Abstract. Line 6

( $p = 0.028$ )

**Error:**

the Japanese Orthopedic Association (JOA) hip rating score,

**Correction:**

the Japanese Orthopaedic Association (JOA) hip score,

2. Abstract. Line 9-10

**Error:**

JOA hip rating score improved significantly from the mean of 45 preoperatively to 78 at the last follow-up ( $p = 0.0313$ )

**Correction:**

JOA hip score improved significantly from the mean of 42.8 preoperatively to 78.8 at the last follow-up

3. Table 1. Line 1

**Error:**

Preoperative JOA, Postoperative JOA

**Correction:**

Preoperative JOA hip score, Postoperative JOA hip score

4. Table 1. Last line

**Error:**

JOA, the Japanese Orthopaedic Association hip rating score.

**Correction:**

JOA, the Japanese Orthopaedic Association.

5. Table 3

**Error:**

**Table 3** The patients' preoperative and postoperative parameters

Variable	JOA hip score Total	Pain	ROM	Gait ability	ADL	LLD (cm)
Preoperative	45.4 ± 16.4	15 ± 12.6	14.4 ± 3.4	5.7 ± 1.9	10.3 ± 3.9	1.2 ± 1.0
Postoperative	77.7 ± 6.8	39.3 ± 1.9	15.6 ± 3.7	9.7 ± 5.2	13.1 ± 1.1	-0.3 ± 1.1
$p$ value	0.0313*	0.0625	0.5	0.125	0.125	0.0313*

The data are expressed as the mean ± SD. ROM, range of motion; ADL, activities of daily living; LLD, leg length discrepancy. \*Significant difference.

**Correction:**

**Table 3** The patients' preoperative and postoperative parameters

Variable	JOA hip score Total	Pain	ROM	Gait ability	ADL	LLD (cm)
Preoperative	42.8 ± 16.3	12.5 ± 11.7	14.2 ± 3.7	5.8 ± 2.0	10.3 ± 4.3	1.2 ± 1.0
Postoperative	78.8 ± 6.6	39.1 ± 2.0	15.8 ± 4.0	10.5 ± 5.2	13.3 ± 1.0	-0.3 ± 1.1
$p$ value	0.028*	0.034*	0.416	0.059	0.059	0.028*

The data are expressed as the mean ± SD. JOA, Japanese Orthopaedic Association; ROM, range of motion; ADL, activities of daily living; LLD, leg length discrepancy. \* $p < 0.05$ .

6. page 19. Line 1, left column

**Error:**

Association (JOA) Hip Score.

**Correction:**

Association (JOA) hip score.

7. page 19. Line 3-8, right column

**Error:**

improved significantly from  $45.4 \pm 16.4$  preoperatively to  $77.7 \pm 6.8$  postoperatively ( $p < 0.01$ ). Although each of the JOA score subcategories (pain, ROM, gait ability & ADL) did not improve significantly, the pain subscale scores of the five patients improved by more than twofold. The LLD decreased from  $1.2 \pm 1.0$  to  $-0.3 \pm 1.1$  cm ( $p < 0.01$ ).

**Correction:**

improved significantly from  $42.8 \pm 16.3$  preoperatively to  $78.8 \pm 6.6$  postoperatively ( $p < 0.05$ ). In subcategories, the pain subscale score has significantly improved, although the others (ROM, gait ability, and ADL) also had a tendency to increase. The LLD decreased from  $1.2 \pm 1.0$  to  $-0.3 \pm 1.1$  cm ( $p < 0.05$ ).

8. page 20. Fig. 2 legends

**Error:**

Representative paralytic-side

**Correction:**

Representative non paralytic-side

9. Table 4. Variables

**Error:**

Preoperative JOA

**Correction:**

Preoperative JOA hip score

10. Table 4. bottom line

**Error:**

The data are mean  $\pm$  SD. ROM, range of motion; ADL, activities of daily living; LLD, leg length discrepancy.

**Correction:**

The data are mean  $\pm$  SD. BMI, body mass index; JOA, Japanese Orthopaedic Association; ROM, range of motion; ADL, activities of daily living; LLD, leg length discrepancy.

11. page 21. Line 5-9, left column

**Error:**

the paralytic side and four on the nonparalyzed limb-side. We used the same cementless prosthesis in all cases. The JOA hip score was significantly improved following THA, and there have been no complications related to the surgery thus far.

**Correction:**

the paralytic side and 4 on the nonparalyzed limb-side. We used the same cementless prosthesis in all cases. The JOA hip score (especially the pain subscale) and LLD were significantly improved following THA, and there have been no complications related to the surgery thus far.

## Total Hip Arthroplasty for Patients with Residual Poliomyelitis at a Mean Eight Years of Follow-up

Mayumi Sonekatsu<sup>a,b</sup>, Motoki Sonohata<sup>a\*</sup>, Masaru Kitajima<sup>a</sup>,  
Shunsuke Kawano<sup>a</sup>, and Masaaki Mawatari<sup>a</sup>

<sup>a</sup>Department of Orthopaedic Surgery, Faculty of Medicine, Saga University, Saga 849-8501, Japan,

<sup>b</sup>Department of Orthopaedic Surgery, Wakayama Medical University, Wakayama 641-8510, Japan

In patients with poliomyelitis, degenerative arthritis of the hip may be encountered in the paralytic or normal contralateral limb because of leg length discrepancy, pelvic obliquity, or severe deformities of the affected hip. Although total hip arthroplasty (THA) is one of the most common orthopedic procedures, there are few reports of THA in adult patients with residual poliomyelitis. From March 2001 to January 2011, 5 patients with residual poliomyelitis (6 hips) underwent THA using uncemented implants at our hospital. We retrospectively evaluated the Japanese Orthopaedic Association (JOA) hip score, complications, and radiographs. All five patients' follow-up information was available: 4.5 years minimum, 8.4 years average, range 4.5-15 years. Surgery was done at the same side of the paralytic limb in 2 hips and contralateral to the paralytic limb in four hips. All patients had pain relief and improvement in function; JOA hip score improved significantly from the mean of 42.8 preoperatively to 78.8 at the last follow-up ( $p = 0.028$ ). There was no loosening or osteolysis in this series, and no cases of dislocation, infection or nerve palsy. These findings can contribute to decisions regarding treatment for arthritic hips in adults with residual poliomyelitis.

**Key words:** total hip arthroplasty, poliomyelitis, residual, neuromuscular disease, complication

**P**oliomyelitis is an acute-infection disease caused by a group of neurotrophic viruses. The viruses have a special affinity for the spinal anterior horn cells and certain motor nuclei of the brain stem, and the infection triggers asymmetrical flaccid-type paralysis in approx. 1% of the cases. Although widespread vaccination has dramatically reduced the number of poliomyelitis patients [1, 2], individuals who have developed permanent paralysis from poliomyelitis often have deformities of the foot and ankle, upper extremities, and degenerative arthritis of the weight-bearing joints of either the paralyzed or nonparalyzed extremity [3, 4].

Some researchers have asserted that the joints in the paralytic limb are protected from the development of osteoarthritis in patients with residual poliomyelitis, perhaps due to a reduction in the forces across the joint [5]. However, in general, the frequency of hip impairment during the evolution of neuromuscular diseases depends on the intensity and spread of the palsy [6]. In contrast, although it is thought that the almost-normal contralateral hips of poliomyelitis patients are largely protected from osteoarthritis because these patients may be less active due to the sequelae of this condition, degenerative arthritis in a previously normal contralateral hip can be caused by a leg length discrepancy, pel-

Received February 10, 2017; accepted August 7, 2017.

\*Corresponding author. Phone: +81-952-34-2243; Fax: +81-952-34-2059  
E-mail: sonohata@cc.saga-u.ac.jp (M. Sonohata)

Conflict of Interest Disclosures: No potential conflict of interest relevant to this article was reported.

vic obliquity, or severe deformities of the affected hip [7-9]. Therefore, an arthritic hip may be encountered in either the paralytic or normal contralateral limb.

It is expected that performing total hip arthroplasty (THA) in paralytic patients carries a risk of postoperative complications such as dislocation or component loosening resulting from paralysis of the lower limb muscle. However, THA in patients with residual poliomyelitis has not been widely reported. We have been able to identify only 20 THA surgeries in 20 cases of patients with residual poliomyelitis, in 6 reports [6,7, 10-13]. We herein report our case series of THA for patients with residual poliomyelitis, to describe the postoperative results in both paralytic-side THA and contralateral nonparalyzed-side THA.

Our study protocol adhered to the ethical guidelines of the 1975 Declaration of Helsinki, and the institutional review board of Saga University Hospital approved the study design (Reference no.: 2015-09-04).

### Patients and Methods

From March 2001 to January 2011, seven hips in six patients with residual poliomyelitis underwent THA at our hospital. One patient (1 hip) who had a follow-up of <3 years was excluded. Ultimately, we retrospectively analyzed 6 hips in 5 patients (4 women and 1 man). The average age of the patients at the time of

surgery was 54.7 (49-63) years old. The mean follow-up duration was 8.4 (4.5-15) years. THA was performed on the paralytic side in one patient, on the nonparalyzed side in 3 patients, and on both sides in the remaining patient. Two patients had undergone foot arthrodesis, one patient had Achilles tendon lengthening, and one patient had undergone some type of surgery on the ankle and some type of osteotomy on the hip joint during adolescence (details were unavailable) (Table 1). Preoperative radiographic measurements are shown in Table 2. There were no significant differences between the paralytic side and contralateral side data.

The indications for the procedure were severe hip pain and/or considerable difficulty walking and performing daily activities due to hip disease. All operations were performed by two highly experienced hip surgeons at our hospital under spinal anesthesia. We chose the posterolateral approach in all six THA surgeries. The operations were performed using a cementless femoral component (PerFix-HA collared STD stem, neck-shaft angle 135°; Kyocera, Kyoto, Japan) with a 26- or 28-mm zirconia ball and an AMS-HA acetabular shell with a cross-linked ultra-high-molecular-weight polyethylene elevated liner (Kyocera, Kyoto, Japan). The patients were allowed to stand and walk with full weight-bearing after removal of the drain, usually 2 days after the operation.

All hips were evaluated using the Japanese Ortho-

**Table 1** Demographic details of patients

Patient no.	Sex/age at surgery	BMI (kg/m <sup>2</sup> )	Follow-up duration (years)	Side	Prior surgery	Preoperative LLD (cm)	Operation time (min)	Operative Blood loss (g)	Preoperative JOA hip score	Postoperative JOA hip score
1	F/60	24.7	15	Contralateral	Foot arthrodesis on the paralytic limb	0.1	40	636	40	75
2	F/52	38.1	10	Paralytic	Achilles tendon lengthening on the paralytic limb	0.7	35	549	41	71
3	F/55	23.5	4.5	Contralateral	Achilles tendon lengthening on the paralytic limb	2.6	38	280	37	84
4	F/49	22.9	8	Contralateral	None	0.3	39	430	22	75
4	F/49	22.9	7.7	Paralytic	Some type of surgery on the ankle Some type of hip osteotomy	1.2	54	230	45	89
5	M/63	19.8	5	Contralateral	None	2.3	43	380	72	79

BMI, body mass index; LLD, leg length discrepancy; JOA, the Japanese Orthopaedic Association.

**Table 2** Preoperative radiographic measurements

Patient number	CE angle	Sharp angle		Neck-shaft angle		Operation side	
	paralytic side	Contralateral side	paralytic side	Contralateral side	paralytic side		Contralateral side
1	0	36	53	37	157	Contralateral	
2	14	25	48	46	158	Paralytic	
3	12	18	45	43	152	Contralateral	
4	49	21	52	40	122	Both	
5	8*	-14	38*	52	153*	Contralateral	
average	16.6	17.2	47.2	43.6	148.4	140.6	
<i>p</i> value		1.0		0.375		0.1875	

\*After hip osteotomy. *p* values refer to the comparison of the paralytic side and contralateral side.

**Table 3** The patients' preoperative and postoperative parameters

Variable	JOA hip score		ROM	Gait ability	ADL	LLD (cm)
	Total	Pain				
Preoperative	42.8 ± 16.3	12.5 ± 11.7	14.2 ± 3.7	5.8 ± 2.0	10.3 ± 4.3	1.2 ± 1.0
Postoperative	78.8 ± 6.6	39.1 ± 2.0	15.8 ± 4.0	10.5 ± 5.2	13.3 ± 1.0	-0.3 ± 1.1
<i>p</i> value	0.028*	0.034*	0.416	0.059	0.059	0.028*

The data are expressed as the mean ± SD. JOA, Japanese Orthopaedic Association; ROM, range of motion; ADL, activities of daily living; LLD, leg length discrepancy. \**p* < 0.05.

paedic Association (JOA) hip score. The JOA hip score is comprised of 4 subcategories, with 100 points as full marks: pain (40 points), range of motion (ROM) (20 points), walking ability (20 points), and activities of daily living (ADLs) (20 points). Routine radiographic examinations included anteroposterior and frog-leg lateral radiograph. Leg length discrepancy (LLD) was measured from the tear drop to the top of the minor trochanter. Radiographic acetabular cup anteversion was calculated in accordance with the method of Widmer [14]. The components were evaluated at the most recent follow-up assessment for evidence of loosening, in accord with the method reported by Dorr *et al.* in the acetabulum [15] and Kim *et al.* in the femur [16]. The stability of the acetabular and femoral components was evaluated at the most recent follow-up assessment by the method reported by McPherson *et al.* [17-19].

All numerical data are expressed as mean ± standard deviation (SD). Wilcoxon's signed-rank test was used for statistical comparisons, and the criterion for statistical significance was *p* < 0.05. All of the statistical analyses were performed with JMP pro 12 software (SAS Institute Japan, Tokyo, Japan).

## Results

As shown in Table 3, the average JOA hip score improved significantly from 42.8 ± 16.3 preoperatively to 78.8 ± 6.6 postoperatively (*p* < 0.05). In subcategories, the pain subscale score has significantly improved, although the others (ROM, gait ability, and ADL) also had a tendency to increase. The LLD decreased from 1.2 ± 1.0 to -0.3 ± 1.1 cm (*p* < 0.05).

None of the 6 hips showed radiographic signs of osteolysis, and there was no loosening of any components on the paralytic side or nonparalytic contralateral side (Figs. 1, 2). The average cup abduction angle was 41.87° ± 7.87°, and the cup anteversion was 13.37° ± 8.7°. We did not observe any complications related to the surgery. There was no dislocation, deep infection, or nerve palsy at the latest follow-up. The data of the paralytic and nonparalytic contralateral hips are compared in Table 4. There were no obvious trends between the groups, although we could not perform a statistical analysis of the differences between the 2 groups because of the small number of patients.

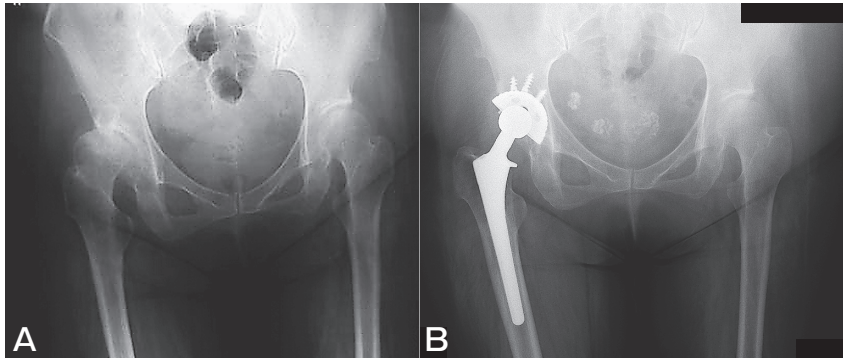


Fig. 1 Representative paralytic-side THA case (Patient 2). **A**, Preoperative AP radiograph; **B**, Postoperative (10 years) AP radiograph.

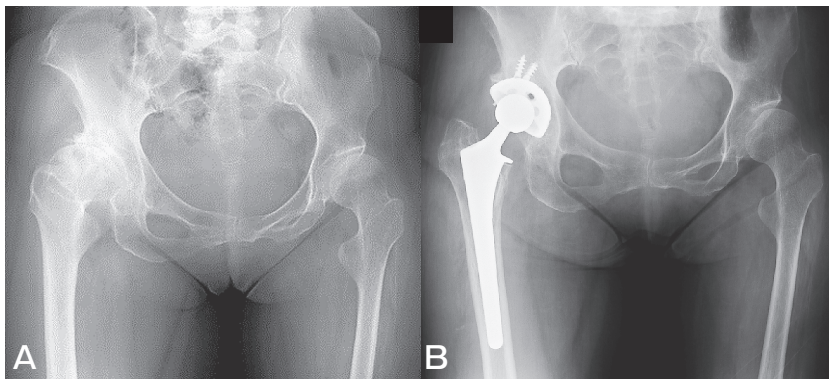


Fig. 2 Representative non paralytic-side THA case (Patient 3). **A**, Preoperative AP radiograph; **B**, Postoperative (4.5 years) AP radiograph.

Table 4 Comparison of demographics and results between paralytic-side THA and contralateral nonparalyzed-side THA

Variables	Operation on paralytic side (n = 2)	Operation on contralateral side (n = 4)
Average age (years)	50.5 ± 2.1	56.8 ± 6.1
BMI (kg/m <sup>2</sup> )	30.5 ± 10.8	22.7 ± 2.1
Follow-up duration (years)	8.9 ± 1.6	8.1 ± 4.8
Operation time (min)	44.5 ± 13.4	40.0 ± 2.2
Operative blood loss (g)	389.5 ± 225.6	431.5 ± 149.9
Preoperative JOA hip score	43.0 ± 2.8	42.8 ± 21.0
pain	10.0 ± 0.0	13.8 ± 14.9
ROM	13.5 ± 3.5	14.5 ± 4.2
Gait ability	7.5 ± 3.5	5.0 ± 0.0
ADL	12.0 ± 2.8	9.5 ± 5.0
Postoperative JOA hip score	80.0 ± 12.7	78.3 ± 4.3
pain	40.0 ± 0.0	38.8 ± 2.5
ROM	17.0 ± 4.2	15.3 ± 4.4
Gait ability	10.0 ± 7.1	10.8 ± 5.4
ADL	13.0 ± 1.4	13.5 ± 1.0
Preoperative LLD (cm)	1.0 ± 0.4	1.3 ± 1.3
Postoperative LLD (cm)	-0.8 ± 1.1	0 ± 1.2
Inclination of cup (°)	45.5 ± 0.7	40.0 ± 9.3
Anteversion of cup (°)	9.0 ± 6.5	15.4 ± 9.7
Cup size (mm)	48.0 ± 2.8	49.0 ± 2.6
Ball size (mm)	27.0 ± 1.4	28.5 ± 2.5
Stem distal size (mm)	12.0 ± 0.0	11.8 ± 1.3

The data are mean ± SD. BMI, body mass index; JOA, Japanese Orthopaedic Association; ROM, range of motion; ADL, activities of daily living; LLD, leg length discrepancy.



**Table 5** Literature review of hip arthroplasty in patients with poliomyelitis

Study	Number of hips (cases)	Side	Follow-up duration (years)	Pain	Complication (number of hips)
Cameron 1995 [10]	1 (1)	Paralytic	3	Free	No
Wicart 1999 [6]	2 (2)	Paralytic	5	Free	Anterior dislocation (1)
Cabanela 2000 [7]	5 (5)	Nonparalyzed	2–8		No
Spinnickie 2007 [11]	1 (1)	Paralytic	< 1		Dissociation of the femoral head and trunnion
Laguna 2008 [12]	1 (1)	Paralytic	3.8	Free	No
Yoon 2014 [13]	10 (10)	4 Paralytic 6 Nonparalyzed	7	Improved	Anterior dislocation (1)
Current study	6 (5)	2 Paralytic 4 Nonparalyzed	8.4	Improved	No

## Discussion

There are few studies regarding THA in patients with residual poliomyelitis (Table 5). Here we have presented our findings from the mid-term follow-up of six THA surgeries in patients with residual poliomyelitis: 2 on the paralytic side and 4 on the nonparalyzed limb side. We used the same cementless prosthesis in all cases. The JOA hip score (especially the pain subscale) and LLD were significantly improved following THA, and there have been no complications related to the surgery thus far.

Generally, patients with poliomyelitis are at risk of having an acquired hip deformity caused by flaccid paralysis and the resulting muscular imbalance. A hip affected by poliomyelitis often has a dysplastic acetabulum and neck-shaft angle. This can result in a painful hip and can limit sitting, standing, and walking due to decreased muscle tone [7], leg length discrepancy, pelvic obliquity and so on [4]. When the gluteus maximus and medius muscles are paralyzed and the hip flexor and adductor strengths are normal, eventual luxation of the hip is almost unpreventable [20]. In addition, the patients often have deformities of the foot and ankle, the upper extremity in the paralyzed extremity, and degenerative arthritis due to excessive weight-bearing in the nonparalyzed extremity [3, 4]. Therefore, in patients with residual poliomyelitis, the hip joints of both the paralytic and nonparalytic sides may require treatment for severe hip pain and/or considerable difficulty walking.

THA reliably eliminates pain, increases ROM, and restores functions in the general population with arthrosis [21, 22]. It is reported that low muscle tone-caused dislocation is the greatest problem for paralytic-side THA in poliomyelitis patients [6, 23]. Thus, when we began performing THA in patients with poliomyelitis in 2001, there was concern about the indication of THA for degenerative arthritis of the paralytic hip in residual poliomyelitis patients, as their limbs do not support excessive loads. Surgery by the standard THA method described above was successful in achieving pain relief. We observed no complications such as dislocation, infection, or loosening of implants through the latest follow-up. We thus consider THA a viable option that can promise substantial benefit for residual poliomyelitis patients with hip pain.

Several limitations associated with the present study warrant mention. First, the postoperative evaluation was done only by JOA hip score and radiographic measurement. This may be insufficient, as many surgeons may want to obtain additional data regarding the manual muscle test (MMT), Harris Hip Score, and/or patient satisfaction. Second, the length of the follow-up period was not uniform for all patients. However, the follow-up minimum was 4.5 years (max. 15 years), and the average follow-up was 8.4 years. This length of follow-up allowed us to determine the mid-term survivorship in this population. Third, the number of patients was small, but we consider this an unavoidable limitation because patients with residual poliomyelitis are rare.

In summary, we have reported the mid-term results of THA for 5 residual poliomyelitis patients. The patients are making satisfactory progress, and these results have encouraged us to continue performing THA for residual poliomyelitis patients. Additional case reports and long-term follow-up are needed.

**Acknowledgments.** We thank Dr. T. Hotokebuchi and Dr. M. Yoshida for their contributions to this study.

### References

1. Thompson KM and Tebbens RJ: Current polio global eradication and control policy options: perspectives from modeling and prerequisites for oral poliovirus vaccine cessation. *Expert Rev Vaccines* (2012) 11: 449–459.
2. World Health Organization: Polio Vaccines: WHO position paper-March (2016) 91: 145–168.
3. Cuckler JM: CORR insights®: Total hip arthroplasty performed in patients with residual poliomyelitis: Does it work? *Clin Orthop Relat Res* (2014) 472: 941–942.
4. Sonohata M, Kitajima M, Kawano S and Mawatari M: Total hip arthroplasty for the paralytic and non-paralytic side in patient with residual poliomyelitis. *The Open Orthopaedics Journal* (2016) 10: 105–110.
5. Haddad FS, Masri BA, Garbuz DS and Duncan CP: Primary total replacement of the dysplastic hip. *Instr Course Lect* (2000) 49: 23–39.
6. Wicart P, Barthas J and Guillaumat M: Replacement arthroplasty of paralytic hip apropos of 18 cases. *Rev Chir Orthop Reparatrice Appar Mot* (1999) 85: 581–590.
7. Cabanela ME and Weber M: Total hip arthroplasty in patients with neuromuscular disease. *AAOS Instructional Course Lectures* (2000) 49: 163–168.
8. Delaunay CP, Bonomet F, Clavert P, Laffargue P and Migaud H: THA using metal-on-metal articulation in active patients younger than 50 years. *Clin Orthop Relat Res* (2008) 466: 340–346.
9. Queally JM, Abdulkarim A and Mulhall KJ: Total hip replacement inpatients with neurological conditions. *J Bone Joint Surg Br* (2009) 91: 1267–1273.
10. Cameron HU: Total hip replacement in a limb severely affected by paralytic poliomyelitis. *Can J Surg* (1995) 38: 386.
11. Spinnickie A and Goodman SB: Dissociation of the femoral head and trunion after constrained conversion total hip arthroplasty for poliomyelitis. *J Arthroplasty* (2007) 22: 634–637.
12. Laguna R and Barrientos J: Total hip arthroplasty in paralytic dislocation from poliomyelitis. *Orthopedics* (2008) 31: 179.
13. Yoon BH, Lee YK, Yoo JJ, Kim HJ and Koo KH: Total hip arthroplasty performed in patients with residual poliomyelitis: does it work? *Clin Orthop Relat Res* (2014) 472: 933–940.
14. Widmer KH: A simplified method to determine acetabular cup anteversion from plain radiographs. *J Arthroplasty* (2004) 19: 387–390.
15. Dorr LD, Wan Z and Cohen J: Hemispheric titanium porous coated acetabular component without screw fixation. *Clin Orthop Relat Res* (1998) 351: 158–168.
16. Kim YH, Kim JS, Oh SH and Kim JM: Comparison of porous-coated titanium femoral stems with and without hydroxyapatite coating. *J Bone Joint Surg Am* (2003) 85: 1682–1688.
17. McPherson EJ, Dorr LD, Gruen TA and Saberi MT: Hydroxyapatite-coated proximal ingrowth femoral stems. A matched pair control study. *Clin Orthop Relat Res* (1995) 315: 223–230.
18. DeLee JG and Charnley J: Radiological demarcation of cemented sockets in total hip replacement. *Clin Orthop Relat Res* (1976) 121: 20–32.
19. Gruen TA, McNeice GM and Amstutz HC: “Modes of failure” of cemented stem-type femoral components: a radiographic analysis of loosening. *Clin Orthop Relat Res* (1979) 141: 17–27.
20. Crowe JF, Mani VJ and Ranawat CS: Total hip replacement in congenital dislocation and dysplasia of the hip. *J Bone Joint Surg Am* (1979) 61: 15–23.
21. Hallan G, Lie SA, Furnes O, Engesaeter LB, Vollset SE and Havelin LI: Medium- and long-term performance of 11516 uncemented primary femoral stems from the Norwegian arthroplasty register. *J Bone Joint Surg Br* (2007) 89: 1574–1580.
22. Learmonth ID, Young C and Rorabeck C: The operation of the century: total hip replacement. *Lancet* (2007) 370: 1508–1519.
23. Sharrard WJ: Paralytic deformity in the lower limb. *J Bone Joint Surg Br* (1967) 49: 731–747.