



## Original article

# Mechanistic target of rapamycin (mTOR) protein expression in the tumor and its microenvironment correlates with more aggressive pathology at cystectomy

Brian R. Winters, M.D.<sup>a</sup>, Funda Vakar-Lopez, M.D.<sup>b</sup>, Lisha Brown, M.S.<sup>a</sup>,  
Bruce Montgomery, M.D.<sup>c</sup>, Roland Seiler, M.D.<sup>d,e</sup>, Peter C. Black, M.D.<sup>d</sup>,  
Joost L. Boormans, M.D., Ph.D.<sup>f</sup>, Marc Dall'Era, M.D.<sup>g</sup>, Elai Davincioni, Ph.D.<sup>h</sup>,  
James Douglas, M.B.B.S., M.Sc.<sup>i</sup>, Ewan A. Gibb, Ph.D.<sup>h</sup>, Bas W.G. van Rhijn, M.D., Ph.D.<sup>j</sup>,  
Michiel S. van der Heijden, M.D., Ph.D.<sup>j</sup>, Andrew C. Hsieh, M.D.<sup>c,k</sup>,  
Jonathan L. Wright, M.D., M.S.<sup>a,l</sup>, Hung-Ming Lam, Ph.D.<sup>a,m,\*</sup>

<sup>a</sup> Department of Urology, University of Washington School of Medicine, Seattle, WA

<sup>b</sup> Department of Pathology, University of Washington School of Medicine, Seattle, WA

<sup>c</sup> Department of Medicine, University of Washington School of Medicine, Seattle, WA

<sup>d</sup> Department of Urologic Sciences, University of British Columbia, Vancouver, British Columbia, Canada

<sup>e</sup> Department of Urology, University of Bern, Bern, Switzerland

<sup>f</sup> Department of Urology, University Medical Center Rotterdam, Rotterdam, The Netherlands

<sup>g</sup> Department of Urology, UC Davis Comprehensive Cancer Center, Sacramento, California

<sup>h</sup> Department of research and development, GenomeDx Biosciences, Inc., Vancouver, British Columbia, Canada

<sup>i</sup> Department of Urology, University Hospital of Southampton, Hampshire, UK

<sup>j</sup> Department of Surgical Oncology, Division of Urology, Netherlands Cancer Institute, Antoni van Leeuwenhoek Hospital, Amsterdam, The Netherlands

<sup>k</sup> Division of Human Biology, Fred Hutchinson Cancer Research Center, Seattle, WA

<sup>l</sup> Division of Public Health Sciences, Fred Hutchinson Cancer Research Center, Seattle, WA

<sup>m</sup> State Key Laboratory of Quality Research in Chinese Medicine, Macau Institute for Applied Research in Medicine and Health, Macau University of Science and Technology, Macau (SAR), China

Received 16 January 2018; received in revised form 2 March 2018; accepted 19 March 2018

## Abstract

**Background:** The mechanistic target of rapamycin (mTOR) has been implicated in driving tumor biology in multiple malignancies, including urothelial carcinoma (UC). We investigate how mTOR and phosphorylated mTOR (pmTOR) protein expression correlate with chemoresponsiveness in the tumor and its microenvironment at final pathologic staging after neoadjuvant chemotherapy (NAC).

**Methods:** A single-institution retrospective analysis was performed on 62 patients with cT2–4Nany UC undergoing NAC followed by radical cystectomy. Diagnostic (transurethral resection specimens, TURBT) and postchemotherapy radical cystectomy specimens were evaluated for mTOR and pmTOR protein expression using immunohistochemistry of the tumor, peritumoral stroma, and normal surrounding stroma. Protein expression levels were compared between clinical and pathologic stage. Whole transcriptome analysis was performed to evaluate mRNA expression relative to mTOR pathway activation.

**Results:** Baseline levels of mTOR and pmTOR within TURBT specimens were not associated with clinical stage and response to chemotherapy overall. Nonresponders with advanced pathologic stage at cystectomy (ypT2–4/ypTanyN+) had significantly elevated mTOR tumor staining ( $P = 0.006$ ) and a sustained mTOR and pmTOR staining in the peritumoral and surrounding normal stroma (NS). Several genes relevant to mTOR activity were found to be up-regulated in the tumors of nonresponders. Remarkably, complete responders at cystectomy (ypT0) had significant decreases in both mTOR and pmTOR protein expression in the peritumoral and normal stroma ( $P = 0.01–0.03$ ).

\*Corresponding author. Tel.: +1-206-543-1461; fax: +1-206-543-1146.

E-mail address: [minglam@uw.edu](mailto:minglam@uw.edu) (H.-M. Lam).

**Conclusions:** Our results suggest that mTOR pathway activity is increased in tumor and sustained in its microenvironment in patients with adverse pathologic findings at cystectomy. These findings suggest the relevance of targeting this pathway in bladder cancer. © 2018 The Authors. Published by Elsevier Inc. This is an open access article under the CC BY-NC-ND license (<http://creativecommons.org/licenses/by-nc-nd/4.0/>).

**Keywords:** mTOR; Neoadjuvant chemotherapy; Immunohistochemistry; Radical cystectomy; Tumor microenvironment

## 1. Introduction

The mechanistic target of rapamycin (mTOR) is a major regulator of fundamental biological processes including cell growth and protein synthesis, and is commonly deregulated in human cancers including urothelial carcinoma (UC) [1]. mTOR has been recognized as a cytoplasmic kinase controlling translation, autophagy, and protein degradation [2] but when dysregulated, can be associated with tumorigenesis, disease recurrence, and worsened overall survival [3]. Further, there is evidence that the mTOR pathway can serve as compensatory mechanism for cancers treated with targeted therapies, possessing both cell-autonomous and nonautonomous resistance capabilities [4].

Emerging evidence has demonstrated that the tumor microenvironment is a complex ecosystem of extracellular matrix and stromal growth factors with significant pathway crosstalk and cellular plasticity, each of which may promote tumor progression and treatment resistance [5,6]. One mechanism by which the tumor microenvironment supports tumor growth is the DNA damage response—a complex and coordinated, evolutionary mechanism which allows an organism to repair DNA damage at a constant rate [7]. During UC treatment, however, the genotoxic stress induced by “standard of care,” platinum-based chemotherapy impacts both tumor and fibroblasts in the surrounding stroma. This genotoxic stress then liberates the DNA damage secretory program involving cytokines, growth factors, and proteases to augment chemoresistance [7]. Subsequently, malignancies can then utilize alternate signaling pathways, including canonical WNT-signaling [8], as escape mechanisms to abrogate chemotherapeutic response. Interestingly, mTOR inhibition has shown some efficacy in limiting inflammatory cytokines (e.g., IL-6) and NF- $\kappa$ B transcriptional activity, the latter of which is thought to be a main regulator of WNT signaling in response to DNA damage [8,9]. Genomic subtyping of bladder cancer tumors [10,11] has shed insight into treatment sensitivity, yet molecular evidence points toward a “field-change effect,” [12] suggesting that targeting the tumor alone may be insufficient and an improved understanding of the tumor microenvironment in UC is required.

In this study, we evaluate mTOR protein expression in both the tumor and its microenvironment in UC, thereby assessing its influence on pathological outcomes and response to neoadjuvant chemotherapy (NAC). We reveal that mTOR protein expression significantly correlates with

more aggressive pathology after NAC and is sustained relative to increasing stage strata. In patients who experience a complete response to NAC, we find minimal mTOR protein expression in the tissue stroma. These results support the relevance of mTOR activity in the UC tumor microenvironment.

## 2. Materials and methods

### 2.1. Patient population

All patients undergoing radical cystectomy for UC after NAC at a single institution were retrospectively reviewed under an IRB approved study (2003–2011; UW/FHCRC). The analysis was limited to those patients with available pre-NAC, transurethral resection specimens (TURBT) ( $N = 62$ ). We focused on patients with  $\geq$  clinical T2 disease at diagnosis [13]. Pre-NAC samples were acquired from outside and institutional pathology laboratories, followed by matching with final pathologic, radical cystectomy specimens from our institution. Clinical and pathologic variables of the cohort included age, sex, race, histology, chemotherapy regimen, clinical, and pathologic staging. For evaluating the effects of chemotherapy relative to mTOR protein expression, we grouped patients into complete responders (ypT0), partial responders (ypTa/ypTIS/ypT1), and nonresponders (ypT2–4/ypTanyN+) at cystectomy. All staging refers to the AJCC Cancer Staging Handbook, Seventh Edition (2010) [13].

### 2.2. Tissue microarray construction

Replicate 1-mm cores were taken from tumor, peritumoral, and normal surrounding stromal regions from both TURBT and cystectomy specimens, as defined by a genitourinary pathologist (FVL). For patients experiencing a complete pathologic response (ypT0), fibrosis at the site of the previous diagnostic TURBT was sampled to allow direct comparison of post-NAC tissue. See [supplemental methods](#) for full details.

### 2.3. Immunohistochemical (IHC) analyses

mTOR, pmTOR, and Ki67 expression was graded in a blinded fashion. Signal intensity (0–3: 0 for negative stain, 1 for faint/equivocal stain, 2 for moderate stain, and 3 for intense stain) and percentage of signal coverage (0–100) of each core were scored, and the product of the intensity and

coverage was represented as an H-score (0–300) [14,15]. The score for each sample was an average of duplicated cores of each patient. See [supplemental methods](#) for full details.

#### 2.4. mRNA expression analysis

To interrogate drivers and effectors of mTOR pathway activation, we performed whole transcriptome analysis on formalin-fixed, paraffin-embedded tumor tissues ( $N = 26$  nonresponders at TURBT,  $N = 22$  nonresponders at cystectomy). See [supplemental methods](#) for full details. We evaluated differentially expressed genes ( $P < 0.05$ ) in cystectomy specimens compared with TURBT specimens in our UW cohort and then validated these findings in a multi-institutional cohort (metaset) consisting of 103 paired TURBT and cystectomy specimens [11]. These data are accessible through the NCBI Gene Expression Omnibus Series accession number GSE87304 (TURBT).

#### 2.5. Statistical analyses

Student's *t*-test and Chi-square tests were utilized to compare dependent variables as appropriate. One-way ANOVA and post hoc Bonferroni tests were used to compare means for 3 or more groups. Spearman correlation of mTOR staining with Ki67 in tumor cells was performed with Student's *t*-tests. Analyses were performed using GraphPad Prism version 6.0 (GraphPad Software, La Jolla, CA) and Stata 14 (Stata, Inc., College Station, TX), with statistical significance set at  $P < 0.05$ . Genomic analysis on our cohort and the validation cohort was performed using R version 3.3.3 with signature scores calculated as the median of mRNA expression. The heatmap.3 function plotted representative heatmaps using median centered expression values ranging from  $-1.5$  to  $1.5$ .

### 3. Results

#### 3.1. Patient demographics and clinicopathologic results

We identified 62 patients with UC who had paired, pre-NAC TURBT and post-NAC cystectomy specimens available. Demographics of the cohort are shown in [Table 1](#). All patients had UC ( $N = 54$  with pure histology) with 8 patients having components of variant histology which did not influence response rates. Further, 89% of patients ( $N = 55$ ) received a complete course of full dose chemotherapy, while 7 had level dose reductions. Ten patients (16%) received gemcitabine and carboplatin as their primary mode of chemotherapy. The mean and median number of lymph nodes removed on standard dissection was 18 (standard deviation 9) and 17 (interquartile range 11–24).

The clinical and pathological staging of all patients is summarized in [Table 1](#). Most patients presented with cT2

Table 1  
Clinical and pathologic demographics of patient cohort

Category	<i>N</i> (%) <sup>*</sup>
Age	
Mean (SD)	61.6 (10.4)
Median (IQR)	61.5 (56–69)
Sex	
Male	46 (74)
Female	16 (26)
Race	
White	54 (87)
Black	2 (3)
Other	6 (10)
Clinical stage	
cT2	36 (58)
cT3	18 (29)
cT4	8 (13)
Clinically node positive	10 (16)
Chemotherapy	
GC	30 (48)
MVAC	10 (16)
ddMVAC	12 (19)
Other	10 (16)
Pathologic stage	
ypT0	15 (24)
ypTa/ypTIS/ypT1	17 (27)
ypT2-4/ypTanyN+	30 (48)
Pathologically node positive	11 (18)
Clinical to pathologic stage comparison	
No change	9 (15)
Up-staged	18 (29)
Down-staged	35 (56)

SD = standard deviation; IQR = interquartile range; GC = gemcitabine, cisplatin; MVAC = methotrexate, vinblastine, doxorubicin (Adriamycin), cisplatin; dd = dose-dense; other chemotherapy: gemcitabine, carboplatin.

<sup>\*</sup>All values in parenthesis are % unless otherwise noted. Clinical and pathological staging refers to AJCC Cancer Staging Handbook, Seventh Edition (2010).

disease (58%,  $N = 36$ ). Final pathologic evaluation revealed 15 complete responders (ypT0, 24%), 17 partial responders (ypTa/ypTIS/ypT1, 27%), and 30 nonresponder patients (ypT2–4/ypTanyN+, 48%) ([Table 1](#) and accompanying Figures). We found no overall differences in pathologic outcomes based on the chemotherapy regimen received ( $P = 0.22$ ). At the time of this analysis, mean and median length of follow up was 37.5 months (standard deviation 30.6 months) and 36.5 months (Interquartile range: 8–55 months), respectively. We found 12 cases of recurrent UC and 16 all-cause deaths during this follow-up period. There were no statistically significant differences in recurrence rates between response groups, though recurrence was numerically more common in nonresponders ( $N = 9$ , 30%) vs. complete responders ( $N = 2$ , 13%;  $P = 0.105$ , Chi-square test). Median time to recurrence in nonresponder patients was 9 months (IQR: 3–12 months). When evaluating mTOR and pmTOR protein expression specifically, only a small subset of patients had both complete mTOR expression data (TURBT and cystectomy) and long-term follow up, precluding a robust survival analysis.

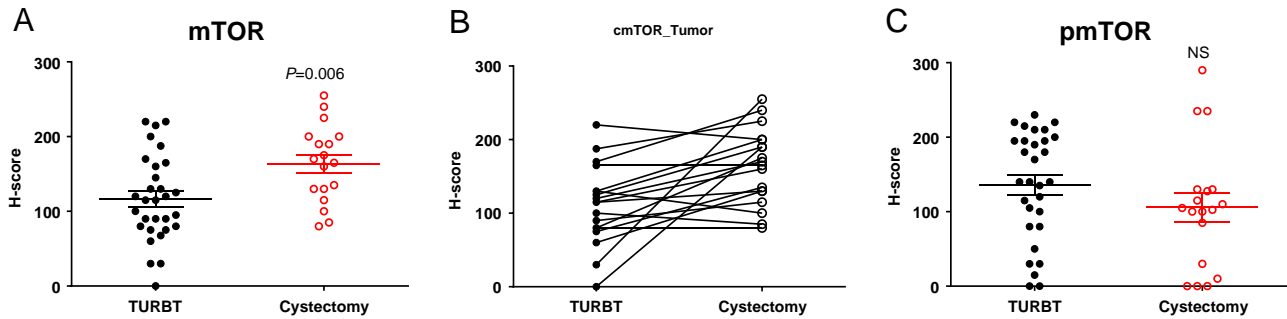


Fig. 1. mTOR tumor protein expression is elevated in nonresponder (ypT2-4/ypTanyN+) patients with viable tumor at cystectomy. Tumor mTOR expression is increased in cystectomy vs. TURBT samples (A) while individual patient plots (B) show elevated/sustained level of mTOR in post-NAC tumors at cystectomy. pmTOR tumor expression was also sustained in nonresponders (C). The 2 nonresponder patients who were pT0, N+ are excluded from tumor staining analysis. Statistical significance is set at  $P < 0.05$ .

### 3.2. Tumor mTOR protein expression is increased in nonresponders and sustained with increasing pathologic stage

Baseline levels of mTOR, pmTOR, and Ki67 index in pre-NAC TURBT specimens were similar for all stages at diagnosis (Supplemental Table S1A and Supplemental Figure S1A). When evaluating nonresponder patients with viable tumor present (ypT2-4), we found significantly elevated tumoral mTOR expression in the post-NAC samples compared with pre-NAC TURBT tumor samples (Figure 1A;  $P = 0.006$ ). Figure 1B reveals individual, matched patient plots of pre-NAC TURBT and post-NAC cystectomy mTOR tumor staining. Figure 1C reveals a sustained level of pmTOR expression in post-NAC tumors (NS). Pre-NAC mTOR protein expression in nonresponders was positively correlated with proliferation (as assessed by Ki67 staining, Pearson  $R = 0.4$ ,  $P = 0.04$ ) but this correlation was lost in post-NAC specimens (Pearson  $R = 0.1$ ,  $P = 0.6$ ). Pre-NAC Ki67 index was comparable for all tumors stratified by subsequent pathological stages (Supplemental Figure S1B). In general, proliferation was sustained in nonresponders (Supplemental Figure S1C). Taken together, these data reveal an increased mTOR protein expression in the tumor of those with no response to chemotherapy, while pmTOR was sustained, suggesting pathway activity with aggressive disease.

### 3.3. mTOR IHC expression is increased in the surrounding tumor stroma and associated with higher pathologic stage

Baseline levels of mTOR and pmTOR in pre-NAC TURBT samples were similar in peritumoral and normal surrounding stroma for all stages at diagnosis (Supplemental Table S1B and C). In the peritumoral samples, both mTOR and pmTOR protein expression was sustained in partial and nonresponder patients (Figures 2 and 3), whereas both mTOR ( $P = 0.01$ ) and pmTOR ( $P = 0.03$ ) expression was significantly decreased in complete responders (Figure 3). Eight of 11 patients (73%)

demonstrated a complete loss of mTOR expression in the peritumoral stroma after NAC (Table 2). Similarly, in normal stroma, sustained mTOR and pmTOR protein expression was detected in those with more aggressive pathology at cystectomy, while there was essentially no mTOR activity in complete responders (Figure 4). Overall, we reveal a stage dependent, sustained mTOR protein expression in the peritumoral and normal surrounding stroma of post-NAC patients, suggesting mTOR activity in the tumor microenvironment reflects treatment response.

### 3.4. Genes associated with mTOR activity are up-regulated in the tumors of chemotherapy resistant, nonresponding patients

Whole transcriptome analysis revealed 74 genes that are significantly up-regulated in the tumors of nonresponder patients after NAC (cystectomy vs. TURBT,  $P < 0.05$ , Supplemental Table S2). Five out of the top 20 up-regulated, protein-coding genes were relevant to mTOR pathway activation (Figure 5A, Supplemental Table S2). Genes activating the mTOR pathway include thrombospondin (THBS1,  $P = 0.006$ ) and fibronectin 1 (FN1,  $P = 0.029$ ). THBS1 is a multimodular protein associated with the extracellular matrix which is postulated to promote chemotherapy resistance through activating the  $\beta$ 1/mTOR pathway via p70S6K and S6RP phosphorylation and is associated with increasing pathologic stage in breast cancer [16]. FN1 is a glycoprotein on the cell surface, involved in adhesive and migratory processes of cells, which has been linked to increased cellular proliferation and invasion through phosphorylation of mTOR and 4E-BP1 signaling mechanisms [17]. Up-regulated genes, downstream of mTOR include the human oncogene c-fos (FOS,  $P = 0.016$ ), calponin 1 (CNN1,  $P = 0.017$ ), and collagen, type I, alpha-2 (COL1A2,  $P = 0.021$ ). FOS is regulated by mTOR and is a major component of the activator protein-1 (AP-1) transcription factor complex involved in cytokine expression and immune response [18]. CNN1 is a smooth

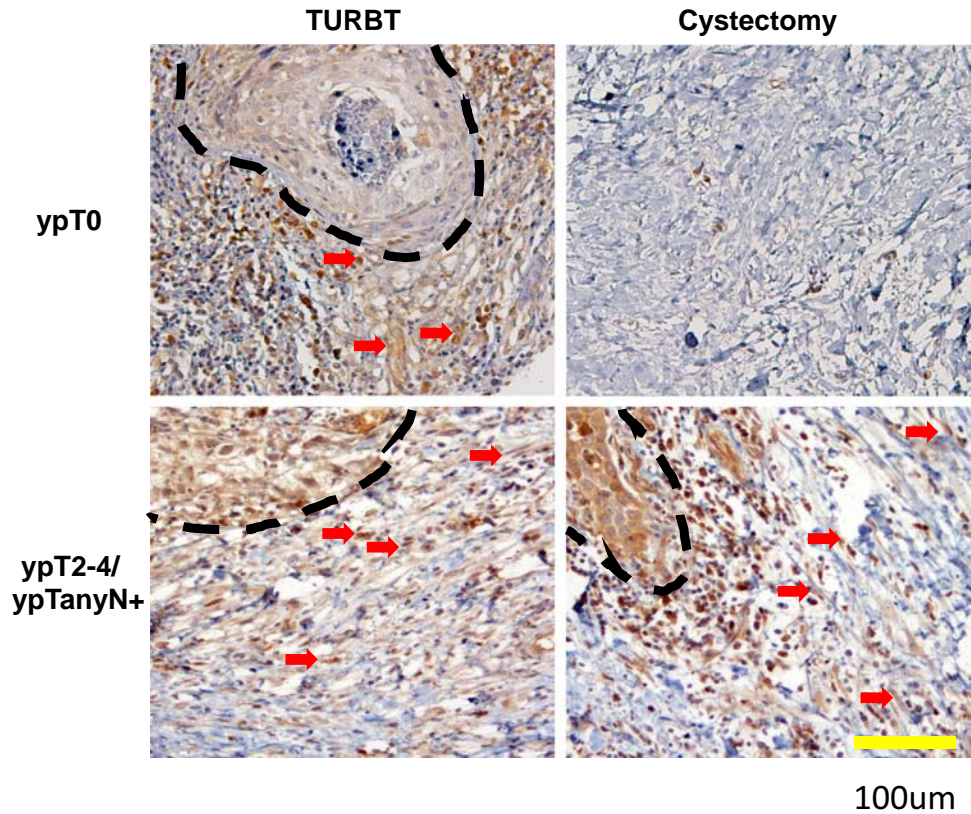


Fig. 2. Peritumoral mTOR expression is lost in complete responder patients (ypT0). Representative images showing the peritumoral expression of mTOR is decreased/lost in complete responders (ypT0, top right panel) but sustained in nonresponders (ypT2-4/ypTanyN+, bottom right panel) after NAC. Red arrow: mTOR-positive stromal cells. Tumor is outlined by dotted line.

muscle differentiation marker whose expression is inhibited by rapamycin in the bladder [19]. Finally, COL1A2 is a collagen type I marker regulated by mTOR [20]. In our cohort of nonresponders, expression of this 5-gene signature was higher in cystectomy vs. TURBT specimens, though this did not reach statistical significance ( $P = 0.15$ , Figure 5B, left). However, with an increase in sample size, using the validation cohort, this signature was significantly

overexpressed in cystectomy specimens ( $P < 0.001$ , Figure 5B, right).

#### 4. Discussion

We performed the first evaluation of mTOR protein expression in both the tumor and its microenvironment in

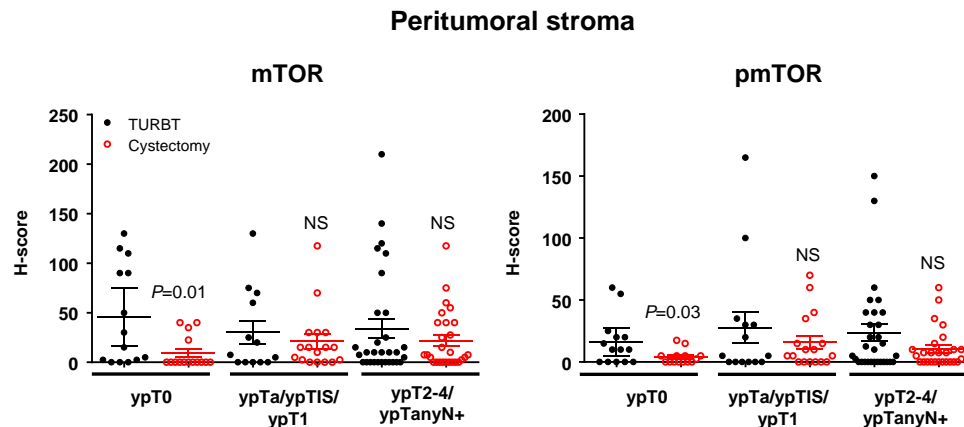


Fig. 3. mTOR and pmTOR protein expression in the peritumoral stroma shows differential activity based on stage at cystectomy. mTOR (left panel) and pmTOR (right panel) protein expression is decreased in complete responders (ypT0), but sustained in partial (ypTa/ypTIS/ypT1) and nonresponders (ypT2-4/ypTanyN+). Statistical significance is set at  $P < 0.05$ ; NS: nonsignificant.

Table 2  
mTOR and pmTOR expression loss in tumor stroma postchemotherapy at cystectomy

	mTOR		pmTOR	
	Peritumoral stroma	Normal stroma	Peritumoral stroma	Normal stroma
ypT0	8/11 (73%)	4/8 (50%)	4/9 (44%)	4/6 (67%)
ypTa/ypTIS/ypT1	2/8 (25%)	1/6 (17%)	2/8 (25%)	5/6 (83%)
ypT2-4/ypTanyN+	6/18 (33%)	1/7 (14%)	3/17 (18%)	5/7 (71%)

Note: The table represents only patients who demonstrated a detectable expression at TURBT and a complete loss of expression at cystectomy.

pre- and post-NAC treated UC. In our patient population, 24% ( $N = 15$ ) experienced a complete pathologic response (ypT0), while nearly half were nonresponders to NAC (ypT2-4/ypTanyN+, 48%,  $N = 30$ ). We found that tumor mTOR protein expression was significantly increased at cystectomy (compared with TURBT samples) in nonresponder patients. Interestingly, we also show that mTOR expression in the tumor microenvironment is sustained in the nonresponders but largely abated in the complete responders, suggesting influence from the tumor microenvironment on invasive UC. We evaluated transcriptomic expression data associated with mTOR activation in treated tumors, finding consistent up-regulated genes in both our cohort and an external validation cohort. These findings highlight mTOR activation in pathologically aggressive UC, which involves the tumor microenvironment, and supports the continued relevance of targeting mTOR in bladder cancer.

Initial mTOR work by Mansure and colleagues, revealed RAD001 (Everolimus) inhibited proliferation in urothelial carcinoma cell lines and xenografts [21]. Study

of mTOR protein expression by Hansel et al. implicated pmTOR as a marker of pathway activation in UC, revealing that it corresponds with increased pathologic stage at cystectomy, is associated with increased invasion in vitro, can be inhibited in a dose-response manner by rapamycin in cell lines, and reduces tumor growth in xenografts [22]. Our data adds significantly to this by confirming that mTOR protein expression is associated with increased aggressiveness, while revealing the novel finding of sustained mTOR activity in the tumor microenvironment. Additionally, we found multiple up-regulated genes relevant to mTOR activity, in patients with more aggressive pathology at cystectomy, a known surrogate for worsened cancer survival. These up-regulated genes included an important growth transcription factor (FOS), as well as genes involved in the extracellular matrix (THBS1, FN1, COL1A2) and bladder smooth muscle (CNN1), the latter of which likely contribute to the tumor microenvironment. These combined IHC and RNA expression data suggest the complexity of UC and a proposed need to consider treating the entire tumor environment, in order to decrease chemoresistance for cisplatin-based chemotherapy [5].

The role of the tumor microenvironment in treatment resistance is an active area of study. Previous authors from our institution have discussed the role of DNA damage response and the DNA secretory program's role in treatment resistance [7,8] as well as the critical role of the mTOR pathway [9]. Our results reveal that, in chemoresistant patients, increased mTOR activity is present in both the tumor and its microenvironment. The selection pressures for this chemoresistance are likely contributed to by the genotoxic stress response and resistant pathways exercised by aggressive UC [7-9]. Genomic subtyping of UC has the potential to improve the overall treatment landscape and initial experiments interrogating specific components of the mTOR pathway relative to these

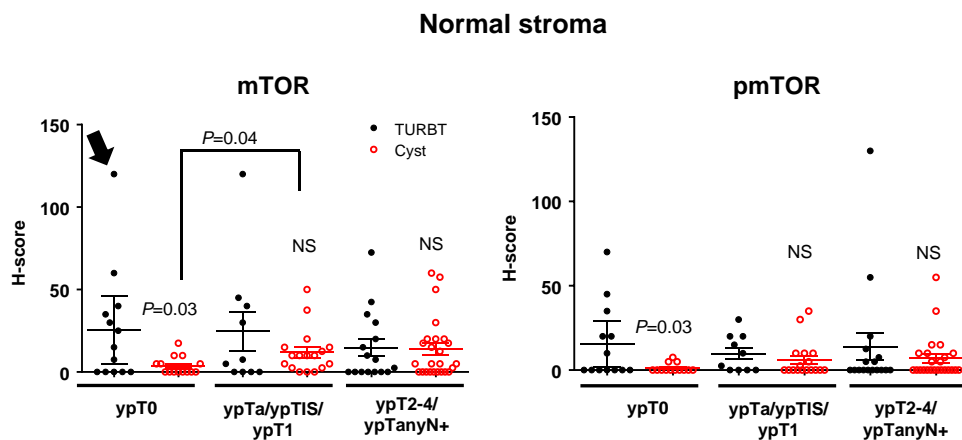


Fig. 4. mTOR and pmTOR protein expression in the normal surrounding stroma shows differential activity based on stage at cystectomy. mTOR (left panel) and pmTOR (right panel) protein expression in the normal surrounding stroma is decreased in complete responders (ypT0), but sustained in partial (ypTa/ypTIS/ypT1) and nonresponder patients (ypT2-4/ypTanyN+). Arrow denotes 1 patient with exceptionally high mTOR expression at pre-NAC, TURBT (H-score = 120) with near complete response at cystectomy (H-score = 10). Statistical significance is set at  $P < 0.05$ ; NS: nonsignificant.

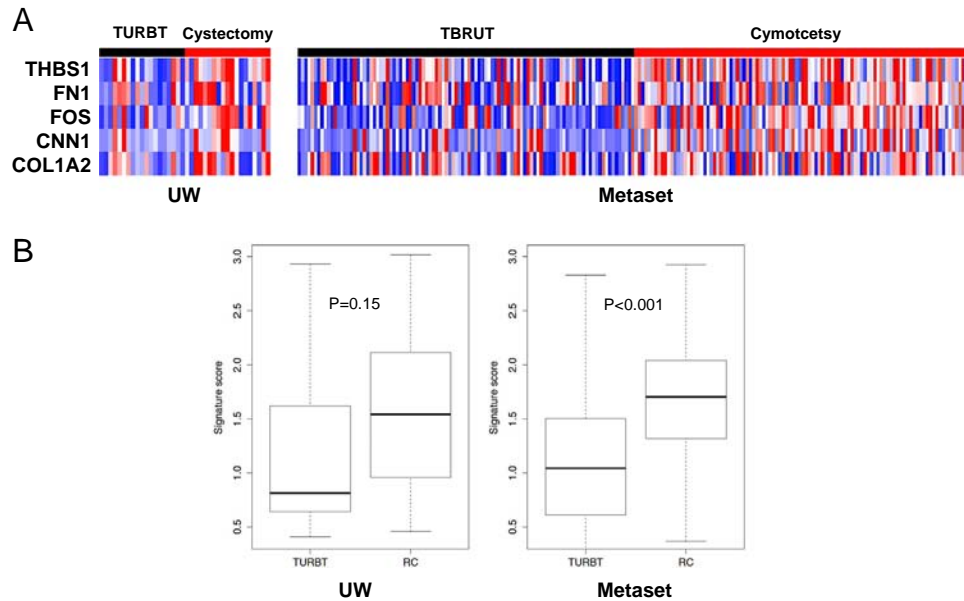


Fig. 5. Differentially expressed protein-coding genes relevant to the mTOR pathway are found in nonresponder (ypT2–4/ypTanyN+) patients. Transcriptome analysis of the top 20 up-regulated protein-coding genes revealed 5 genes, relevant to mTOR activity, that were up-regulated at cystectomy in nonresponder patients in both the UW cohort and validation metaset (A; red: up-regulated; blue: down-regulated). A signature score of the 5 mTOR-associated genes in RC vs. TURBT samples was calculated (B; error bars represent mean  $\pm$  SEM) revealing increased expression in the cystectomy samples of nonresponder patients. Statistical significance is set at  $P < 0.05$ .

subtypes has shown some efficacy [11,23]. Further, selective mutations in the mTOR pathway (e.g., TSC) have shown encouraging influence on treatment sensitivity [24]. However, the clear real-world efficacy of mTOR inhibition in UC remains elusive [25,26]. Ongoing trials focusing on mTOR inhibition hold promise (e.g., NCT01182168 and NCT01182168) but the complex interplay of factors inherent to the tumor microenvironment signal the need for more comprehensive research. Prospective studies targeting mTOR [4,27] as well as other compensatory resistance pathways, particularly in the tumor microenvironment, will improve understanding of treatment resistance and therapeutic efficacy in UC.

Limitations to this study include the retrospective design and patient selection from a single institution. All pathologic samples obtained were subject to individual storage methods and ranged in time from acquisition, which may have influenced quality of the cores for TMA creation. IHC analysis is limited by the inability to evaluate tumor mTOR expression in the “complete” and “partial responder” groups, due to the ablation of tumor cells. Further, assessing biomarkers from TMA has its inherent limitations in terms of small representation of the tumor and the lack of tumor heterogeneity on a particular core. From a clinical perspective, there may be some heterogeneity in the TURBT specimens acquired by outside providers given the referral nature of our institution. Finally, given the small sample size and the nature of this retrospective study, robust, long-term recurrence and survival analysis was not possible. Our report of sustained

mTOR protein expression in the tumor microenvironment of nonresponder UC patients and whether this expression has definitive implications for recurrence and prognosis, requires further study.

## 5. Conclusions

This study is the first to evaluate mTOR protein expression in the tumor microenvironment of UC, before and after NAC. Our results show that mTOR protein expression is significantly increased in tumor and sustained in the tumor microenvironment of patients with adverse pathologic findings at cystectomy. Transcriptome analysis revealed multiple up-regulated genes relevant to mTOR pathway activity. Together, these results suggest the continued relevance of targeting this pathway in urothelial carcinoma.

## Source of funding

Howard J Cohen Bladder Cancer Foundation, Seattle Translational Tumor Research.

## Funding

This work was supported by Howard J Cohen Bladder Cancer Foundation and Seattle Translational Tumor Research.

## Acknowledgments

We thank Cody Rogers for assisting preparation of figures and Kristine von Maltzan for additional pathologic assistance. A.C.H. is a V Foundation Scholar and funded by an AACR NextGen Grant for Transformative Cancer Research, NIH 1K08CA175154–01, and the Burroughs Wellcome Fund. H.M.L. is funded by NCI Cancer Center Support Grant P30 CA015704.

## Appendix A. Supporting information

Supplementary data associated with this article can be found in the online version at <http://doi.org/10.1016/j.urolonc.2018.03.016>.

## References

- [1] Guertin DA, Sabatini DM. Defining the role of mTOR in cancer. *Cancer Cell* 2007;12(1):9–22.
- [2] Averous J, Proud CG. When translation meets transformation: the mTOR story. *Oncogene* 2006;25(48):6423–35.
- [3] Park SJ, Lee TJ, Chang IH. Role of the mTOR Pathway in the Progression and Recurrence of Bladder Cancer: an Immunohistochemical Tissue Microarray Study. *Korean J Urol* 2011;52(7):466–73.
- [4] Guri Y, Hall MN. mTOR signaling confers resistance to targeted cancer drugs. *Trends Cancer* 2016;2(11):688–97.
- [5] van der Horst G, Bos L, van der Pluijm G. Epithelial plasticity, cancer stem cells, and the tumor-supportive stroma in bladder carcinoma. *Mol Cancer Res* 2012;10(8):995–1009.
- [6] Alfano M, Canducci F, Nebuloni M, Clementi M, Montorsi F, Salonia A. The interplay of extracellular matrix and microbiome in urothelial bladder cancer. *Nat Rev Urol* 2016;13(2):77–90.
- [7] Sun Y, Nelson PS. Molecular pathways: involving microenvironment damage responses in cancer therapy resistance. *Clin Cancer Res* 2012;18(15):4019–25.
- [8] Sun Y, Campisi J, Higano C, et al. Treatment-induced damage to the tumor microenvironment promotes prostate cancer therapy resistance through WNT16B. *Nat Med* 2012;18(9):1359–68.
- [9] Laberge RM, Sun Y, Orjalo AV, et al. MTOR regulates the pro-tumorigenic senescence-associated secretory phenotype by promoting IL1A translation. *Nat Cell Biol* 2015;17(8):1049–61.
- [10] Cancer Genome Atlas Research N: Comprehensive molecular characterization of urothelial bladder carcinoma. *Nature* 2014;507(7492):315–22.
- [11] Seiler R, Ashab HAD, Erho N, et al. Impact of molecular subtypes in muscle-invasive bladder cancer on predicting response and survival after neoadjuvant chemotherapy. *Eur Urol* 2017;72(4):544–54.
- [12] Jones TD, Wang M, Eble JN, et al. Molecular evidence supporting field effect in urothelial carcinogenesis. *Clin Cancer Res* 2005;11(18):6512–9.
- [13] Edge SB BD, Compton CC, Fritz AG, Green FL, Trotti A, editors. *American Joint Committee on Cancer Staging Manual*, 2009. New York: Springer; 2009.
- [14] Huang HJ, Neven P, Drijkoningen M, et al. Association between tumour characteristics and HER-2/neu by immunohistochemistry in 1362 women with primary operable breast cancer. *J Clin Pathol* 2005;58(6):611–6.
- [15] Lam HM, Ouyang B, Chen J, et al. Targeting GPR30 with G-1: a new therapeutic target for castration-resistant prostate cancer. *Endocr Relat Cancer* 2014;21(6):903–14.
- [16] Wang T, Srivastava S, Hartman M, et al. High expression of intratumoral stromal proteins is associated with chemotherapy resistance in breast cancer. *Oncotarget* 2016;7(34):55155–68.
- [17] Cao Y, Liu X, Lu W, et al. Fibronectin promotes cell proliferation and invasion through mTOR signaling pathway activation in gallbladder cancer. *Cancer Lett* 2015;360(2):141–50.
- [18] He L, Zang A, Du M, et al. mTOR regulates TLR-induced c-fos and Th1 responses to HBV and HCV vaccines. *Virology* 2015;53(3):174–89.
- [19] Tolg C, Ahsan A, Dworski S, et al. Pathologic bladder microenvironment attenuates smooth muscle differentiation of skin derived precursor cells: implications for tissue regeneration. *PLoS One* 2013;8(4):e59413.
- [20] Shegogue D, Trojanowska M. Mammalian target of rapamycin positively regulates collagen type I production via a phosphatidylinositol 3-kinase-independent pathway. *J Biol Chem* 2004;279(22):23166–75.
- [21] Mansure JJ, Nassim R, Chevalier S, Rocha J, Scarlata E, Kassouf W. Inhibition of mammalian target of rapamycin as a therapeutic strategy in the management of bladder cancer. *Cancer Biol Ther* 2009;8(24):2339–47.
- [22] Hansel DE, Platt E, Orloff M, et al. Mammalian target of rapamycin (mTOR) regulates cellular proliferation and tumor growth in urothelial carcinoma. *Am J Pathol* 2010;176(6):3062–72.
- [23] Hau AM, Nakasaki M, Nakashima K, Krish G, Hansel DE. Differential mTOR pathway profiles in bladder cancer cell line subtypes to predict sensitivity to mTOR inhibition. *Urol Oncol* 2017.
- [24] Iyer G, Hanrahan AJ, Milowsky MI, et al. Genome sequencing identifies a basis for everolimus sensitivity. *Science* 2012;338(6104):221.
- [25] Seront E, Rottey S, Sautois B, et al. Phase II study of everolimus in patients with locally advanced or metastatic transitional cell carcinoma of the urothelial tract: clinical activity, molecular response, and biomarkers. *Ann Oncol* 2012;23(10):2663–70.
- [26] Milowsky MI, Iyer G, Regazzi AM, et al. Phase II study of everolimus in metastatic urothelial cancer. *BJU Int* 2013;112(4):462–70.
- [27] Rodrik-Outmezguine VS, Okaniwa M, Yao Z, et al. Overcoming mTOR resistance mutations with a new-generation mTOR inhibitor. *Nature* 2016;534(7606):272–6.