

Bowman's layer dystrophy with irido-fundal coloboma in the same patient: a case report

Mafalda Mota¹, Catarina Pedrosa¹, Diana Silva¹, Graça Pires¹, Peter Pêgo¹, Cristina Vendrell¹, Isabel Prieto¹
¹Hospital Prof. Dr. Fernando Fonseca, Amadora, Portugal

RESUMO

Introduction: Corneal dystrophies are rare corneal diseases, defined as bilateral, symmetric and inherited conditions. Ocular coloboma is a congenital defect caused by an embryogenesis abnormality, during the sixth week of development.

Purpose: The authors report the first clinical case in the literature of a corneal dystrophy associated with irido-fundal coloboma.

Case report: We describe the case of a 34-year-old woman, with decreased visual acuity (VA) in the right and left eyes (RLE) and a history of ocular illness and corneal erosions from a young age. Her family members report having corneal alterations and her father had a bilateral corneal transplant. Ophthalmic examination showed a best-corrected visual acuity (BCVA) of 20/40 in the RE and 20/100 in the LE. Biomicroscopy showed an inferior iris coloboma in the LE. Deposition of a reticular/granular substance in the Bowman's layer was observed in both eyes, sparing the limbal portion, compatible with a corneal dystrophy. Fundus examination showed a coloboma in the LE that involves the inferior retina and the optic nerve, no changes in the RE fundus was observed. She started treatment with lubricant preservative-free eyedrops. The patient has remained stable within 1-year follow-up.

Conclusions: This is the first case report depicting an association of corneal dystrophy and irido-fundal coloboma. The greater decrease in VA in the LE appears to be due to the combination of these two entities in this eye. Although Bowman's layer corneal dystrophy has an autosomal dominant pattern, coloboma seems to have been an acquired change. However, we cannot exclude that this is not a first description of the same disease, given that they share the same genetic loci (5q31).

Keywords: Cornea dystrophy, Bowman's layer, Irido-fundal coloboma

INTRODUCTION

Corneal dystrophies are rare corneal diseases that are defined as bilateral, symmetric and inherited conditions.¹⁻⁴ Ocular coloboma is a congenital anomaly caused by defective embryogenesis, during the sixth week of development.^{5,6} The location depends on the part of the optic fissure that failed to close.⁵ This entity can be seen in isolation and in an multiple number of multisystem syndromes, but an association with corneal dystrophies has not been reported in literature so far.^{5,6} The authors will describe the first case report of an association of corneal dystrophy with irido-fundal coloboma.

CASE REPORT

A 34-year-old Brazilian woman came to the Emergency Room with decreased visual acuity (VA) in the right eye (RE). She reports history of ocular illness from a young age, with decreased VA in the left eye (LE), as well as recurrent corneal erosions in both eyes. She does not refer other ophthalmologic or systemic diseases. Regarding her family history, she reported that some of her family members have corneal alterations (Fig. 1) and her father had a bilateral corneal transplant due to Reis-Bucklers corneal dystrophy (RBCD), according to his medical report.

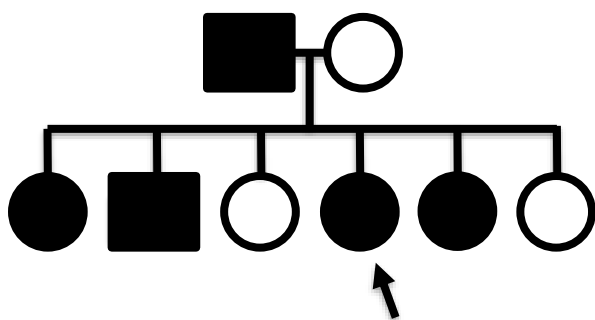


Figura 1 - Family Tree

Ophthalmic examination showed a best-corrected visual acuity (BCVA) of 20/40 in the right eye (RE) and 20/100 in the left eye (LE). Intraocular pressure (IOP) was 18/20 mmHg. Biomicroscopy of the anterior segment showed an inferior iris coloboma in the LE (Fig. 2). Deposition of a reticular/granular substance in the Bowman's layer was observed in both eyes, sparing the limbal portion, compatible with a corneal dystrophy (Fig. 3). Fundus

examination showed a coloboma in the LE that involves the inferior retina and the optic nerve (Fig. 4). No changes in the RE fundus was observed. She is the only family member with iris coloboma.

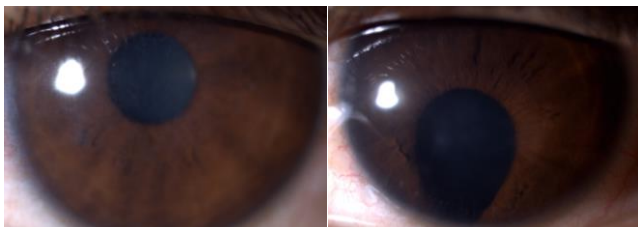

Figura 2 - Biomicroscopy of the anterior segment showed an inferior iris coloboma in the LE. A deposition of reticular/granular substance in the cornea was observed in both eyes.

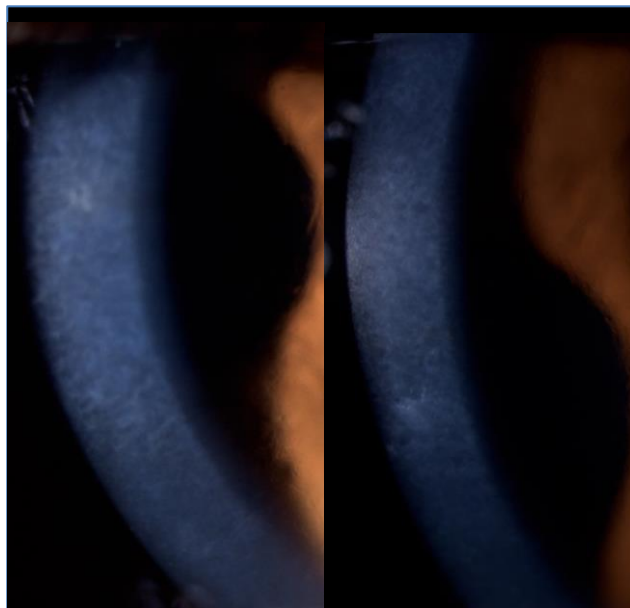


Figura 3 - Biomicroscopy of the anterior segment showed a deposition of reticular/granular substance in the Bowman's layer, in both eyes.

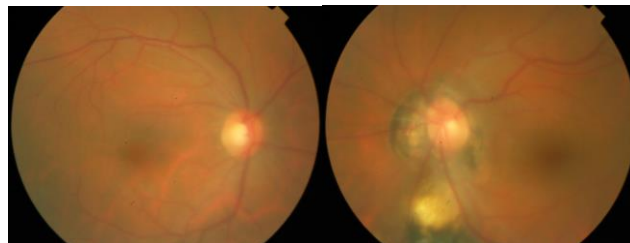


Figura 4 - Fundus examination showed a coloboma in the LE.

Optical Coherence Tomography (OCT) of the inferior retina of the LE confirmed the diagnosis of coloboma by identifying an area of bare sclera with absence of the overlying retinal pigment epithelium (RPE), retinal and choroidal layers (Fig. 5). The endothelial cell count, measured by specular microscopy, and corneal pachymetry were normal in both eyes. An anterior segment photography obtained by corneal topography (Pentacam®) enables visualization of the iris coloboma in the LE (Fig. 6).

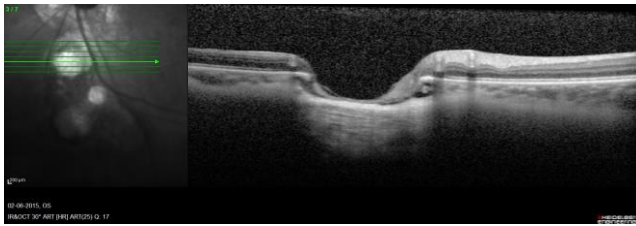


Figura 5 – OCT showed an area of bare sclera with the overlying RPE, retina and choroidal layers missing in the LE.

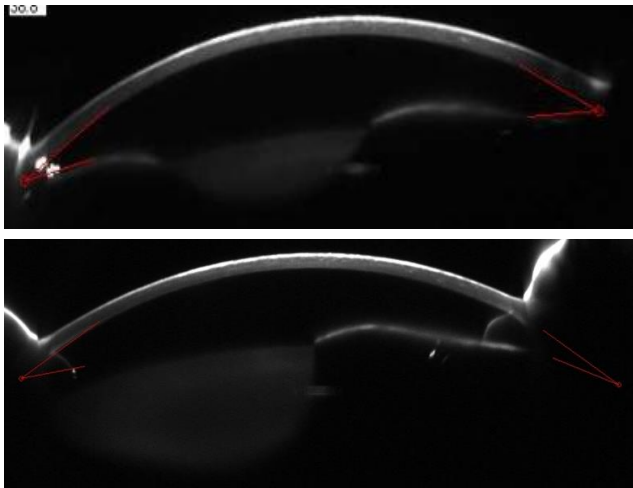


Figura 6 – Pentacam® image of the anterior segment showing an iris coloboma in the LE. Anterior layers of the cornea are hyperreflective in the both eyes.

The condition was explained to our patient and she started treatment with lubricant preservative-free eyedrops. The biomicroscopy and fundus examination of her 6-year-old daughter revealed no alterations compatible with the presence of corneal dystrophy or coloboma. The patient has remained stable within 1-year follow-up.

DISCUSSION

This case report illustrates the typical clinical presentation and transmission pattern of a corneal dystrophy. Concurrently, an irido-fundal coloboma is also present, and to the best of our knowledge, this is the first clinical description of a patient with an association of corneal dystrophy and irido-fundal coloboma.

Corneal dystrophies are defined as bilateral, symmetric and inherited conditions.^{1,2} As demonstrated in our case, dystrophies tend to be slowly progressive and may not become clinically significant until later in life.² These diseases are anatomically classified according to the corneal layers that are involved.^{2,3} In this case, the Bowman's layer appears to be the affected area, and the two corneal dystrophies that characteristically affect this area are Reis-Bucklers corneal dystrophy (RBCD) and Thiel-Behnke corneal dystrophy (TBCD).^{2,3} Both have autosomal dominant inheritance, a pattern that is also observed in our patient's family tree; and both are related to a mutation in the TGFBI gene in loci 5q31, although TBCD is also associated with a mutation in an unknown gene located in loci 10q24.^{2,4} Clinically, the two entities are very similar, with both being characterized by disruption and/or absence of the Bowman's layer, which is progressively replaced by abnormal fibrocellular material.^{2,4} Therefore, a definitive diagnosis is only established by electron microscopy, but attending to the fact that her father was diagnosed with RBCD, this is the most likely diagnosis.^{1,2} Our case also illustrates the typical clinical course of these types of dystrophies, that may be associated with recurrent epithelial erosions, especially in the first decades of life, with gradual visual impairment due to corneal opacification.² Erosions are more frequent and severe in RBCD.^{2,4} Regarding corneal opacification, unlike TBCD, in RBCD the opacities may extend to the limbus and deeper stroma with time, although not always.^{2,3} Our patient's condition did not appear to evolve in this particular manner.

Initial treatment is aimed at diminishing the patient's symptoms, with lubricant preservative-free eyedrops and treatment of recurrent corneal erosions.² More invasive techniques are usually necessary, such as superficial keratectomy, lamellar keratoplasty, phototherapeutic keratectomy or, in more severe cases, penetrating keratoplasty. Unfortunately, in most dystrophies, recurrence in the graft is common, so long-term follow-up with ophthalmological, genetic and psychological

evaluation is required in these families.²⁻⁴ In this case, RBCD appears to be the most likely diagnosis, given that this condition has been previously diagnosed in her father.

Ocular coloboma is a congenital defect caused by abnormal embryogenesis.⁵ The pathogenesis of this condition is determined by an incomplete closure of the optic fissure, during the sixth week of development.⁶ The incomplete optic fissure closure, typically in the inferior nasal quadrant, prevents normal development of the ocular structures, which become absent.^{5,6} The location of the coloboma depends on the portion of the optic fissure that failed to close, and one or more structures can be simultaneously involved, from the iris to the optic nerve^{5,6}. If a coloboma is present in the iris and retina it is known as an irido-fundal coloboma, as described in our case.⁶

Ocular colobomas can be seen in isolation and in an impressive number of multisystem syndromes.^{5,6} However, an association with Bowman's layer dystrophies has not been reported in the literature yet.⁵ Most often, ocular colobomas are isolated, are not inherited and there is only one affected individual in a family.⁵ The affected individuals are still at risk of transmitting the coloboma to their own children.^{5,6} The genetic basis of coloboma is complex, controlled by multiple transcriptional factors, cell cycle regulators and diffusible signaling molecules, and not fully understood yet.⁵

In our clinical case, given that most colobomas are sporadic and the fact that our patient is the only family member with irido-fundal coloboma leads us to consider that it is most likely an acquired condition. However, mutations causing coloboma have already been described in the same loci of Bowman's layer dystrophies mutated genes (gene FBN2 - loci 5q31; gene RBP4 and PAX2 – loci 10q24).^{2,5} Thus, we cannot exclude that a single mutation in the same genetic loci is the cause of both diseases (corneal dystrophy and unilateral coloboma), an association not yet described in the literature. This possibility can only be excluded through genetic testing.

CONCLUSIONS

This is the first case report depicting an association of corneal dystrophy and irido-fundal coloboma. The greater decrease in VA in the LE appears to be due to the combination of these two entities in this eye. Despite Bowman's layer dystrophy has an autosomal dominant

pattern, coloboma seems to have been an acquired change, which aggravates the phenotype of corneal dystrophy. However, we cannot exclude that this is not a first description of the same disease, given that they share the same genetic loci (FBN2 and TGFBI genes in loci 5q31). Long-term ophthalmologic follow-up of this family is indicated. Psychological and genetic evaluation should be desirable for these families, due to the decreased VA and the associated hereditary pattern.

BIBLIOGRAPHY

1. Sanharawi M, Sandali O, Basli E, Bouheraoua N, Ameline B, Goemaere I, Georgeon C, Hamiche T, Borderie, Laroche L, Fourier-domain optical coherence tomography imaging in corneal epithelial basement membrane dystrophy: A structural analysis, *AM J Ophthalmol*, 159: 755-763, (2015).
2. American Academy of Ophthalmology, External disease and cornea, Section 8, Chapter 10 (2014-2015).
3. Moller HU, Wittebolpost D, Weidle EG, Reis-Bucklers dystrophy, *Cornea*, 2005 May, 25 (4): 499 (2006).
4. Nakamura H, Li FT, Foltermann MO, Macsai M, Ma X, Zhao XC, Flaherty K, Yee RW, Individual phenotypic variances in a family with Thiel-Behnke corneal dystrophy, *Cornea*, 2012 Nov, 31 (11): 1217-22 (2012).
5. Gregory-Evans C, Williams M, Halford S, Gregory-Evans K, Ocular coloboma: a reassessment in the age of molecular neuroscience, *J Med Genet*, 41: 881-891 (2004).
6. Kumar K, Tanwar M, Naithani P, Insaan R, Garg S, Venkatesh P, Dada R, PAX6 gene analysis in irido-fundal coloboma, *Molecular Vision*, 17: 1414-1419 (2011).

CONTACTO

Mafalda Mota
Rua do Olival, Bloco F, 2º Esquerdo
2625-448 Forte da Casa
E-mail: mafaldamsbm@gmail.com