

Case Report

Successful treatment for a gastric persimmon bezoar in a pony using nasogastric lavage with a carbonated cola soft drink

I. RODRIGUEZ HURTADO, A. STEWART AND A. PELLEGRINI-MASINI

Department of Clinical Sciences, College of Veterinary Medicine, Auburn University, Auburn 36832, Alabama, USA.

Keywords: horse; gastric impactions; persimmons; phytobezoar; Coca-Cola

Introduction

Gastric impactions in horses are caused by the ingestion of foreign materials, coarse roughage or feed that may swell after ingestion (Sanchez 2004). Poor dentition, chronic hepatic disease and inadequate consumption of water are identified as predisposing factors (Murray 2002). Clinical signs of gastric impaction range from anorexia and weight loss to severe abdominal pain. Recommended treatment involves repeated gastric lavage via nasogastric intubation or fragmentation of the impaction via laparotomy (Barclay *et al.* 1982; Honnas and Schumacher 1985; Owen *et al.* 1987).

Ingestion of persimmons by horses can produce signs of abdominal pain by causing gastric impaction and gastric ulceration that may lead to perforation. Small intestinal obstruction with persimmons in horses has also been previously reported (Honnas and Schumacher 1985; Morgan 1994; Cummings *et al.* 1997; Kellam *et al.* 2000). Persimmon bezoars are often not discovered until a *post mortem* examination is performed. Laparotomy has been recommended for treatment of persimmon gastric impactions in horses (Honnas and Schumacher 1985; Kellam *et al.* 2000). Oral administration of a carbonated cola soft drink (Diet Coca-Cola)¹ for resolution of persimmon impactions was first described in 3 human patients in Greece (Ladas *et al.* 2002), and was followed by multiple case reports of successful treatments (Kato *et al.* 2003; Sechopoulos *et al.* 2004; Martinez de Juan *et al.* 2006). For treatment of persimmon impactions, a large volume (3 l) of Diet Coca-Cola was administered through a feeding tube as a constant rate infusion. This resulted in the complete dissolution of the bezoars after 12 h of infusion. The patients were also recommended to drink Diet Coca-Cola as a prelude to further treatment. Other recommended

treatments include the injection, via endoscopy, of Diet Coca-Cola directly into the bezoar (Chung *et al.* 2006). In this report we describe the successful medical treatment of one horse with gastric impaction caused by persimmons. To the authors' knowledge, no successful medical treatment for horses with gastric persimmon impactions has been previously reported.

This report describes the treatment of a horse with a persimmon gastric impaction by administering a carbonated cola soft drink (Diet Coca-Cola) through a nasogastric tube.

Case history

A 6-year-old, 123 kg, pony gelding was referred to Auburn for treatment of abdominal pain. The pony had ingested ripe persimmons 4 days prior to presentation and for the last 12 h had been lethargic, anorexic and had signs of abdominal pain. Three hours prior to presentation, the referring veterinarian had noticed orange-tinged fluid containing feed particles draining from the nares. The veterinarian siphoned 7.5 l of gastric fluid through a nasogastric tube and administered flunixin meglumine (Banamine)² (1.1 mg/kg bwt i.v.). The recurrence of abdominal pain 2 h after this treatment prompted referral.

Clinical findings and diagnosis

At presentation, the pony was lethargic with a moderately distended abdomen. The pony had a body condition score of 7 out of 9. He appeared painful and became recumbent during examination. Heart rate was 84 beats/min, respiratory rate 42 breaths/min, rectal temperature 37.6°C and mucous membranes were dark pink and dry, with a capillary refill time of 3 sec. The pony was estimated to be 10–12% dehydrated. The signs of abdominal pain were ameliorated by siphoning 4 l of gastric fluid that had a strong odour of fermentation.

*Author to whom correspondence should be addressed.

A distended stomach with no evidence of small intestinal distention was identified during transabdominal ultrasonography. Abdominocentesis yielded no fluid. Palpation of the abdomen *per rectum* was not attempted because of the small size of the pony. Gastroscopic findings included mucosal ulceration of the cardia and severe hyperkeratosis of the visible portion of the squamous region of the stomach. A large mass of impacted food material containing black seeds also was identified (**Fig 1**). The mass was estimated to involve 80% of the gastric lumen. The *margo plicatus* could not be visualised and the pylorus and duodenum could not be accessed. Based on the history of known exposure to persimmons, orange-tinged reflux, season (autumn), clinical signs compatible with a gastric impaction and endoscopic appearance, the mass was presumed to be a persimmon phytobezoar.

The moderate distention of the abdomen could not be entirely explained by the size of the gastric impaction. Other possible causes for abdominal distention, such as mild gas accumulation in the large colon, could not be ruled out at this point.

Results of a complete blood cell count indicated mild leucocytosis (13.5×10^9 cells/l; reference range [rr] $6\text{--}12 \times 10^9$ cells/l) and neutrophilia (11.2×10^9 cells/l; rr $3\text{--}6 \times 10^9$ cells/l). A high packed cell volume (PCV; 58%; rr 28–40%) and increased plasma proteins (98 g/l; rr 55–79 g/l) indicated haemoconcentration. Abnormalities in serum biochemistries included hypochloraemia (88.1 mmol/l; rr 97–111 mmol/l), low ionised calcium (1 mmol/l; rr 1.375–1.625 mmol/l), low ionised magnesium (0.38 mmol/l; rr 0.45–0.53 mmol/l), hyperglycaemia (2.49 g/l; rr 0.81–1.27 g/l), high lactate (18 mmol/l; rr 1.11–1.78 mmol/l), azotaemia (creatinine 60 mg/l; rr 0–20 mg/l), moderate hyperfibrinogenaemia (6 g/l; rr 1–4 g/l) and mildly elevated triglycerides (1.26 g/l; rr 0.14–0.77 g/l).

Arterial blood gas results indicated acidaemia (pH of 7.3; reference value 7.4) with an increased pCO₂ (56 mmHg; reference value 40 mmHg) and normal bicarbonate (26 mmol/l; rr 20–28 mmol/l). Strong ion calculations showed high unmeasured anions and hypochloraemic alkalosis. These results were interpreted as two concomitant metabolic

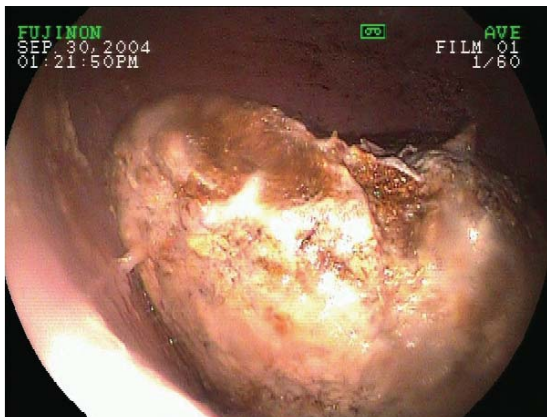


Fig 1: Persimmon phytobezoar impaction in the stomach of the pony. The *margo plicatus* could not be fully visualised and the mass occupied 2/3 of the stomach.

derangements: a hypochloraemic alkalosis consequence of a loss of chloride in the gastric reflux and an acute and severe lactic acidosis due to tissue hypoperfusion in an animal with hypovolaemic shock.

Treatment and outcome

Initial treatment included repeated gastric siphonage through a nasogastric tube and i.v. administration of a balanced electrolyte solution (Normosol R)³ at 450 ml/h, after an initial bolus of 5 l, supplemented with potassium chloride (20 mEq/l), magnesium sulphate (50 mg/kg bwt/24 h), calcium borogluconate 23% (200 mg/kg bwt every 24 h) and glucose (4 mg/kg bwt/min). Flunixin meglumine (Banamine, 0.3 mg/kg bwt i.v.) was administered every 8 h as antiendotoxic therapy. Food and water were withheld and gastric siphonage was performed every 2 h through a nasogastric tube. Gastric fluid continued to have a fermented odour and fumes emanating from the nasogastric tube were usually seen prior to the fluid evacuation.

Diocetyl sodium sulfosuccinate (DSS)⁴ at 20 mg/kg bwt, was administered through the accessory port of the endoscope during the gastroscopy and again through an indwelling nasogastric tube 12 h later. Cimetidine (Tagamet)⁵ at 6.6 mg/kg bwt was administered i.v. every 8 h and sucralfate (Carafate)⁶ (30 mg/kg bwt) was administered through the nasogastric tube every 6 h.

On Day 2 of hospitalisation, the pony was moderately uncomfortable and the gastric reflux persisted. Gastric drainage was continued every 2 h, obtaining decreasing amounts throughout the night. Selected clinicopathological abnormalities were re-evaluated indicating improvement of the hydration status (based on improved physical parameters, PCV and total solids), and improved azotaemia (creatinine 29 mg/l; rr 0–20 mg/l), supporting a pre-renal origin. Blood gas data showed resolution of the acidaemia with a decrease of the lactate value (2.4 mmol/l; rr 1.11–1.78 mmol/l) and normal pCO₂.

On Day 3 of hospitalisation, gastric fluid could no longer be siphoned, but during gastroscopy there appeared to be no change in the phytobezoar size or consistency. The absence of gastric reflux could have been explained at this point by the resolution of a small intestinal bezoar that could not have been identified. The pony continued to show mild signs of colic, attributable to the gastric impaction. Surgical treatment of the impaction was declined by the owner. Seven hundred millilitres (contents of two cans) of a carbonated cola soft drink (Diet Coca-Cola) were administered through the nasogastric tube. The dose was extrapolated from human literature describing a one time endoscopic infusion in an adult of similar weight (Sechopoulos *et al.* 2004).

A complete blood cell count and fibrinogen were re-evaluated indicating improved leucocyte count (12.8×10^9 cells/l; rr $6\text{--}12 \times 10^9$ cells/l), improved hyperfibrinogenaemia (500 mg/dl; rr 100–400 mg/dl), but persistent neutrophilia (8.2×10^9 cells/l; rr $3\text{--}6 \times 10^9$ cells/l) indicating continual inflammation. Triglycerides were reported normal (0.73 g/l; rr

0.14–0.77 g/l), as well as creatinine (19 mg/l; rr 0–20 mg/l).

On Day 4 of hospitalisation, i.v. fluid therapy was discontinued and an oral feeding tube⁷ was placed and a 5% sucrose electrolyte solution (4 mg/kg bwt/min) administered. The pony tolerated the infusion without signs of colic and the flunixin meglumine was discontinued as there was no evidence of toxicity. Nasogastric administration of 700ml of carbonated cola soft drink was performed as on Day 3.

Gastroscopy was repeated on Day 5 and the phytobezoar appeared to be half of its original size (**Fig 2**) and could be indented with the endoscopic forceps. Administration of 700 ml of carbonated cola soft drink was repeated. The pony remained comfortable throughout the next 48 h.

During the gastroscopic examination on Day 7 of hospitalisation, the gastric impaction was no longer present. The pylorus could be seen and appeared to be severely ulcerated (*Grade 3*) (**Fig 3**). Persimmon seeds were recovered from the pony's stool, supporting the presumptive diagnosis of persimmon impaction. Oral fluids and cimetidine were discontinued. Sucralfate administration was continued for 2 more days.

The pony's complete blood cell count and fibrinogen had normalised on Day 8 of hospitalisation, and the triglyceride levels had remained normal indicating the absence of hyperlipaemia. The pony was slowly reintroduced to hay during the next 2 days. He was then discharged with instructions to monitor for any further colic signs and avoid the pasture with persimmon trees. The pony was reported to be healthy one year after discharge.

Discussion

Primary gastric impaction is uncommon in the horse and usually requires surgical resolution (Barclay *et al.* 1982). Treatment of gastric impactions by administering mineral oil or a surfactant such as dioctyl sodium succinate is unrewarding when impactions are caused by bezoars or foreign materials (Honnas and Schumacher 1985). The pony described in this report was refractory to the treatment with gastric lavages and dioctyl sodium succinate infusions. However, the impaction resolved soon after the administration of a carbonated cola soft drink. The clinical signs improved before the gastric impaction was resolved suggesting the presence of a concomitant small intestinal obstruction, that responded to treatment. Small intestinal bezoars have been previously reported in both man and horses, and are believed, on occasion, to derive from fragmentation of the primary gastric bezoar (Benharroch *et al.* 1993; Kellam *et al.* 2000).

Persimmon is a deciduous tree or shrub native to China. The variety *Diospyros kaki* was introduced in Europe in the mid-19th century and is currently grown in the south of France, Spain and Italy. The American varieties, *Diospyros virginiana* and *Diospyros texana*, are commonly found in the southern and eastern United States. The fruit is well known for its sour taste and astringent properties prior to ripening and once mature, it is used in breads, pies and beer. The fruit matures in the autumn and is commonly ingested by birds and mammals.

Persimmon fruit contains soluble tannins such as shibuol around the calyx and under the skin. The tannins decline in concentration as environmental temperatures decrease during the winter. Once ingested, the tannic acid from unripe fruit binds proteins such as digestive enzymes and glycoproteins. In the presence of dilute hydrochloric acid in the stomach, the tannic acid polymerises forming a coagulum that includes cellulose, hemicellulose and proteins (Holloway *et al.* 1980). This plant concretion is called a phytobezoar, and more exactly a diospyrobezoar because it originates from persimmons. The persimmon seeds become cemented in the phytobezoar causing mechanical damage and abrasion of the mucosal lining of the stomach. Persimmon phytobezoars are the most common cause of gastric impactions in man. Risk factors are ingestion of unpeeled fruits and a history of gastric surgery (Benharroch *et al.* 1993). The diagnosis of a persimmon diospyrobezoar in this pony was based on the exposure to persimmons in the autumn, presence of fermented and orange-tinged reflux, colic signs, endoscopic identification of persimmon seeds in the mass and in the feces described in the literature (Honnas and Schumacher 1985; Morgan 1994; Cummings *et al.* 1997; Kellam *et al.* 2000).

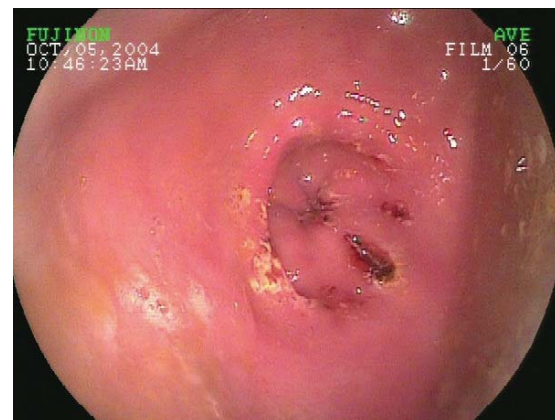

Fig 3: Day 7 of treatment. The pylorus can be seen and appears severely ulcerated.

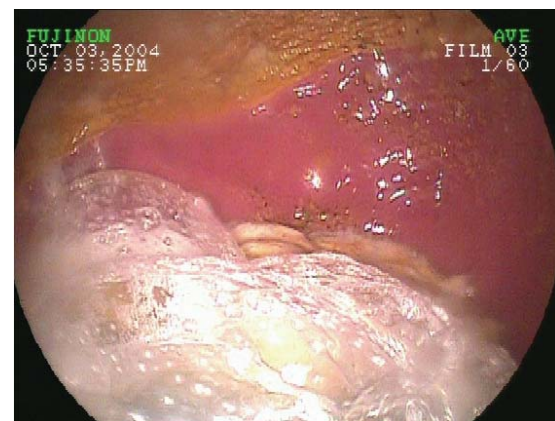


Fig 2: Persimmon phytobezoar impaction in the stomach of the pony on Day 5 of treatment. The margo plicatus can be fully visualised. Areas of hyperkeratosis are evident.

In man, endoscopic or surgical removal of the bezoars is the most common treatment recommended for gastric impactions caused by persimmons. Other methods described for resolution of human gastric bezoars are enzymatic digestion, endoscopic fragmentation alone or combined with oral administration of cysteine, metoclopramide and cellulose, and lithotripsy (Holloway *et al.* 1980; Kuo *et al.* 1993,1999; Gaya *et al.* 2002).

As in other reported cases of horses with persimmon impactions (Honnas and Schumacher 1985; Kellam *et al.* 2000), initial treatment with dioctyl sodium sulphosuccinate was unrewarding in our case. To the authors' knowledge, successful medical treatment for horses with persimmon impactions has not been previously reported.

The dissolution of the diospyrobezoar may have resulted from the acidifying effect of the carbonated cola beverage on the gastric contents (pH 2.6) (McCloy *et al.* 1984), and the penetration of carbon dioxide bubbles into the surface of the bezoar which are thought to digest the fibres of the concretion (Ladas *et al.* 2002). Other recommended treatment includes the direct injection of Coca-Cola into the bezoar or the oral intake by the patients for days prior to injection (Chung *et al.* 2006). Although Diet Coca-Cola was used to treat the horse in this report, other acidic and/or carbonated fluids may be found efficacious.

Although Surgical treatment of gastric impactions of any type has been recommended as the treatment of choice, oral administration of a carbonated cola soft drink could be attempted before surgical removal and may be the treatment of choice for persimmon impactions.

Manufacturers' addresses

¹The Coca-Cola Company, Atlanta, Georgia, USA.

²Shering-Plough Animal Health Corp., Union, New Jersey, USA.

³Abbott Laboratories, North Chicago, Illinois, USA.

⁴The Butler Company, Columbus, Ohio, USA.

⁵SK-Beecham, Parsippany, New Jersey, USA.

⁶Hoechst Marion Roussel, King of Prussia, Pennsylvania, USA.

⁷Mila- Eli Lilly and Co., Indianapolis, Indiana, USA.

References

- Barclay, W.P., Foerner, J.J., Phillips, T.N. and MacHarg, M.A. (1982) Primary gastric impaction in the horse. *J. Am. vet. med. Ass.* **181**, 682-683.
- Benharoch, D., Krugliak, P., Porath, A., Zurgil, E. and Niv, Y. (1993) Pathogenetic aspects of persimmon bezoars. A case-control retrospective study. *J. Clin. Gastroenterol.* **17**, 149-152.
- Chung, Y.W., Han, D.S., Park, Y.K., Son, B.K., Paik, C.H., Jeon, Y.C. and Sohn, J.H. (2006) Huge gastric diospyrobezoars successfully treated by oral intake and endoscopic injection of Coca-Cola. *Dig. Liver. Dis.* **38**, 515-517.
- Cummings, C.A., Copedge, K.J. and Confer, A.W. (1997) Equine gastric impaction, ulceration, and perforation due to persimmon (*Diospyros virginiana*) ingestion. *J. vet. Diagn. Invest.* **9**, 311-313.
- Gaya, J., Barranco, L., Llopart, A., Reyes, J. and Obrador, A. (2002) Persimmon bezoars: a successful combined therapy. *Gastrointest. Endosc.* **55**, 581-583.
- Holloway, W.D., Lee, S.P. and Nicholson, G.I. (1980) The composition and dissolution of phytobezoars. *Arch. Pathol. Lab. Med.* **104**, 159-161.
- Honnas, C.M. and Schumacher, J. (1985) Primary gastric impaction in a pony. *J. Am. vet. med. Ass.* **187**, 501-502.
- Kato, H., Nakamura, M., Orito, E., Ueda, R. and Mizokami, M. (2003) The first report of successful nasogastric Coca-Cola lavage treatment for bitter persimmon phytobezoars in Japan. *Am. J. Gastroenterol.* **98**, 1662-1663.
- Kellam, L.L., Johnson, P.J., Kramer, J. and Keegan, K.G. (2000) Gastric impaction and obstruction of the small intestine associated with persimmon phytobezoar in a horse. *J. Am. vet. med. Ass.* **216**, 1279-1281.
- Kuo, J.Y., Mo, L.R., Tsai, C.C., Chou, C.Y., Lin, R.C. and Chang, K.K. (1999) Nonoperative treatment of gastric bezoars using electrohydraulic lithotripsy. *Endoscopy* **31**, 386-388.
- Kuo, J.Y., Mo, L.R., Tsai, C.C., Yueh, S.K., Lin, R.C. and Hwang, M.H. (1993) Endoscopic fragmentation of gastric phytobezoar by electrohydraulic lithotripsy. *Gastrointest. Endosc.* **39**, 706-708.
- Ladas, S.D., Triantafyllou, K., Tzathas, C., Tassios, P., Rokkas, T. and Raptis, S.A. (2002) Gastric phytobezoars may be treated by nasogastric Coca-Cola lavage. *Eur. J. Gastroenterol. Hepatol.* **14**, 801-803.
- Martinez de Juan, F., Martinez-Lapiedra, C. and Picazo, V. (2006) [Phytobezoar dissolution with Coca-Cola]. *Gastroenterol. Hepatol.* **29**, 291-293.
- McCloy, R.F., Greenberg, G.R. and Baron, J.H. (1984) Duodenal pH in health and duodenal ulcer disease: effect of a meal, Coca-Cola, smoking, and cimetidine. *Gut* **25**, 386-392.
- Morgan, S.E. (1994) Persimmon colic in a mare. *Equine Pract.* **16**, 8-10.
- Murray, M.J. (2002) Disorders of the stomach. In: *Large Animal Internal Medicine*, 3rd edn., Ed: B.P. Smith, Mosby, St. Louis. p 1735.
- Owen, R.A., Jagger, D.W. and Jagger, F. (1987) Two cases of equine primary gastric impaction. *Vet. Rec.* **121**, 102-105.
- Sanchez, L.C. (2004) Diseases of the stomach. In: *Equine Internal Medicine*, 2nd edn., Eds: S.M. Reed, W.M. Bayly and D.C. Sellon, W.B. Saunders, Philadelphia. pp 863-873.
- Sechopoulos, P., Robotis, J.F. and Rokkas, T. (2004) Gastric bezoar treated endoscopically with a carbonated beverage: case report. *Gastrointest. Endosc.* **60**, 662-664.