



The University of
Nottingham

UNITED KINGDOM • CHINA • MALAYSIA

Hariharan, D. and Lobo, Dileep N. (2017) Spontaneous extrusion of gallstones after percutaneous drainage. *Annals of the Royal College of Surgeons of England*, 99 (3). e1-e2. ISSN 1478-7083

Access from the University of Nottingham repository:

http://eprints.nottingham.ac.uk/51213/1/2017_Spontaneously%20extruded%20gallstones.pdf

Copyright and reuse:

The Nottingham ePrints service makes this work by researchers of the University of Nottingham available open access under the following conditions.

This article is made available under the University of Nottingham End User licence and may be reused according to the conditions of the licence. For more details see: http://eprints.nottingham.ac.uk/end_user_agreement.pdf

A note on versions:

The version presented here may differ from the published version or from the version of record. If you wish to cite this item you are advised to consult the publisher's version. Please see the repository url above for details on accessing the published version and note that access may require a subscription.

For more information, please contact eprints@nottingham.ac.uk

Spontaneous extrusion of gallstones after percutaneous drainage

D Hariharan, DN Lobo

Gastrointestinal Surgery, National Institute for Health Research Nottingham Digestive Diseases Biomedical Research Unit, Nottingham University Hospitals and University of Nottingham, Queen's Medical Centre, Nottingham, UK

ABSTRACT

There have been reports of late discharge of gallstones through operative wounds after spillage into the peritoneal cavity during laparoscopic cholecystectomy and after the development of spontaneous cholecystocutaneous fistulae. However, spontaneous discharge of gallstones from the tract of a percutaneous cholecystostomy or percutaneous drainage of a perforated gall bladder has not, to the best of our knowledge, been reported previously. We report a case in which a patient who had a percutaneous drain inserted for a perforated gall bladder discharged 34 gallstones from the tract after removal of the 7-F pigtail catheter.

KEYWORDS

Gallstones – Gallbladder perforation – Percutaneous drainage – Spontaneous extrusion – CT

Accepted 4 December 2016

CORRESPONDENCE TO

Dileep N Lobo, E: dileep.lobo@nottingham.ac.uk

Introduction

A cholecystocutaneous fistula is a rare complication of complicated gallstone disease¹ and the discharge of gallstones from a fistula tract is an even rarer event. There have been reports of late discharge of gallstones through operative wounds^{2,3} after spillage into the peritoneal cavity during laparoscopic cholecystectomy. A percutaneous cholecystostomy is used sometimes to drain the gall bladder in patients with acute cholecystitis in whom comorbidity precludes cholecystectomy. However, spontaneous discharge of gallstones from such a tract has, to the best of our knowledge, been unreported previously.

Case history

An 83-year-old woman was admitted with an ultrasound diagnosis of acute cholecystitis. She was treated with intravenous antibiotics (piperacillin and tazobactam) and intravenous fluids. She remained septic (white cell count 22.4×10^9 cells/mm³, C-reactive protein 380 mg/l, bilirubin 28 μ ol/l, alkaline phosphatase 443 iu/l, alanine transaminase 65 iu/l, lactate 1.1mmol/l) and blood culture grew *Streptococcus milleri*. Despite being on appropriate antibiotics, her clinical condition did not improve. Computed tomography revealed a 7 × 7cm sub-hepatic abscess containing multiple gas locules and gallstones, suspicious of a perforated gallbladder (Fig 1). As multiple cardiovascular comorbidities precluded surgery, a percutaneous 7-F pigtail drain was inserted into the sub-hepatic collection under

ultrasound guidance. This drained 70 ml of pus initially. Her clinical condition improved and the pus stopped draining after 5 days. The drain was removed and she was discharged, to be readmitted after 48 hours complaining of solid matter discharging from the drain sinus tract. A gallstone was visible at the cutaneous end of the tract (Fig 2, top) and eventually a total of 34 gallstones were extruded (Fig 2, bottom). Repeat imaging showed no further

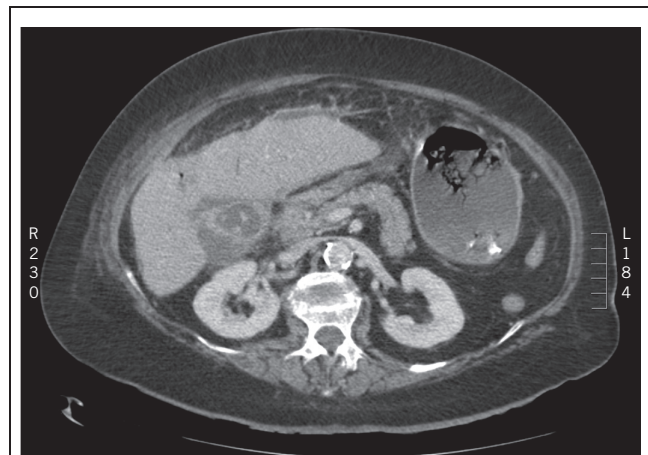


Figure 1 Computed tomography image showing a 7 × 7cm sub-hepatic abscess containing gallstones.

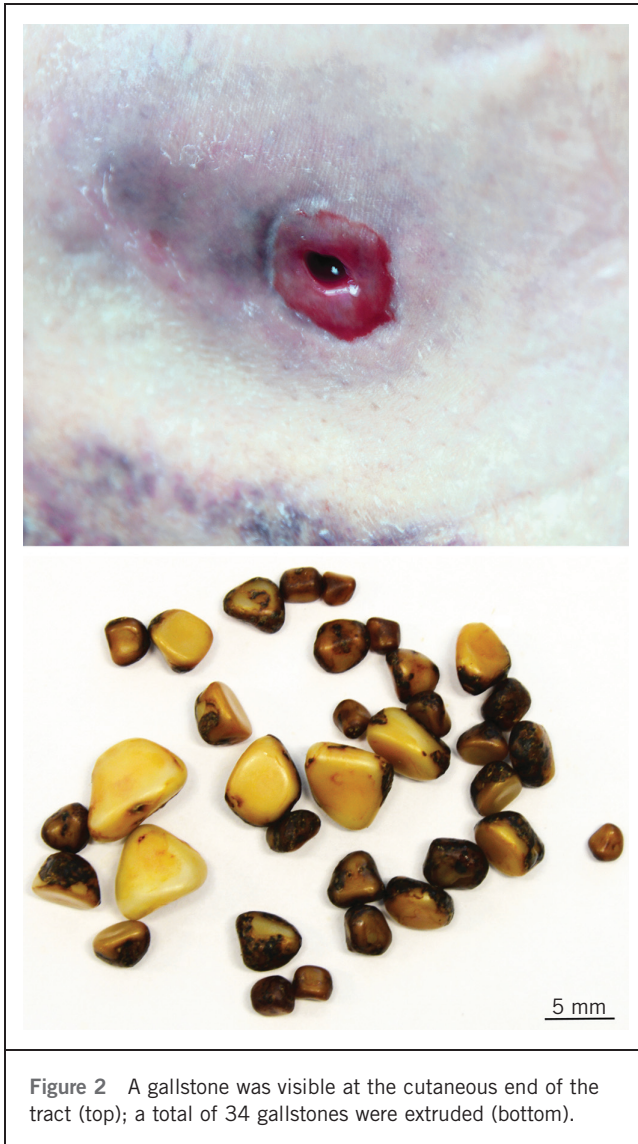

Figure 2 A gallstone was visible at the cutaneous end of the tract (top); a total of 34 gallstones were extruded (bottom).

collections or stones. She was ultimately discharged 4 days after readmission and continues to be well.

Discussion

Cholecystocutaneous fistula is a rare complication of neglected biliary tract disease. The increased pressure in the gallbladder because of cystic duct obstruction impairs blood flow and lymphatic drainage, causing mural necrosis and perforation. Nayman, in 1963, described a 'burrowing abscess' of the abdominal wall because of gallbladder inflammation leading to cutaneous fistulation.⁴ Gangrene of an acutely inflamed gallbladder can occur in up to 20% of patients⁵ and can sometimes result in transmural perforation and spillage of gallstones.⁶

Our patient had a perforation of her gallbladder with spillage of stones and responded well to percutaneous drainage and antibiotic therapy. Although it is unusual for peritoneocutaneous tracts to become established so early after insertion of siliconised percutaneous drains, this apparently happened in our patient, facilitating extrusion of the spilled gallstones. This spontaneous event was fortuitous, as it led to resolution of her condition, especially as surgical intervention was an extremely high-risk option. Resolution was also facilitated by the fact that the cystic duct was probably blocked, as indicated by absence of bile in the drain effluent and lack of sub-hepatic fluid collections on subsequent scans.

References

1. Vasanth A, Siddiqui A, O'Donnell K. Spontaneous cholecystocutaneous fistula. *South Med J* 2004; **97**: 183–185.
2. Zehetner J, Shamiyeh A, Wayand W. Lost gallstones in laparoscopic cholecystectomy: all possible complications. *Am J Surg* 2007; **193**: 73–78.
3. Woodfield JC, Rodgers M, Windsor JA. Peritoneal gallstones following laparoscopic cholecystectomy: incidence, complications, and management. *Surg Endosc* 2004; **18**: 1,200–1,207.
4. Nayman J. Empyema necessitatis of the gall-bladder. *Med J Aust* 1963; **1**: 429–430.
5. Macafee DAL, Humes DJ, Bouliotis G *et al*. Prospective randomized trial using cost-utility analysis of early versus delayed laparoscopic cholecystectomy for acute gallbladder disease. *Br J Surg* 2009; **96**: 1,031–1,040.
6. Walton TJ, Dhingra R, Kaye PV *et al*. Imaging after medically managed severe acute cholecystitis. *Gut* 2009; **58**: 421, 472.