



Swansea University
Prifysgol Abertawe



Cronfa - Swansea University Open Access Repository

This is an author produced version of a paper published in:

Journal of Cardiovascular Ultrasound

Cronfa URL for this paper:

<http://cronfa.swan.ac.uk/Record/cronfa39497>

Paper:

Galusko, V., Khanji, M., Bodger, O., Weston, C., Chambers, J. & Ionescu, A. (2017). Hand-held Ultrasound Scanners in Medical Education: A Systematic Review. *Journal of Cardiovascular Ultrasound*, 25(3), 75

<http://dx.doi.org/10.4250/jcu.2017.25.3.75>

Released under the terms of a Creative Commons Attribution Non-Commercial License (CC-BY-NC-ND).

This item is brought to you by Swansea University. Any person downloading material is agreeing to abide by the terms of the repository licence. Copies of full text items may be used or reproduced in any format or medium, without prior permission for personal research or study, educational or non-commercial purposes only. The copyright for any work remains with the original author unless otherwise specified. The full-text must not be sold in any format or medium without the formal permission of the copyright holder.

Permission for multiple reproductions should be obtained from the original author.

Authors are personally responsible for adhering to copyright and publisher restrictions when uploading content to the repository.

<http://www.swansea.ac.uk/library/researchsupport/ris-support/>

HAND-HELD ULTRASOUND SCANNERS IN MEDICAL EDUCATION: A SYSTEMATIC REVIEW

VICTOR GALUSKO, MBBCH, BSC¹, MOHAMMED YUNUS KHANJI, MD², OWEN BODGER, PHD¹, CLIVE WESTON, MB¹, JOHN CHAMBERS, MD³, AND ADRIAN IONESCU, MD²

¹SWANSEA UNIVERSITY MEDICAL SCHOOL, SINGLETON PARK, SWANSEA, UK

²MORRISTON CARDIAC REGIONAL CENTRE, ABMU LHB, SWANSEA, UK

³GUY'S AND ST THOMAS' NHS TRUST, LONDON, UK

BACKGROUND: Ultrasound imaging devices are becoming popular in clinical and teaching settings, but there is no systematic information on their use in medical education. We conducted a systematic review of hand-held ultrasound (HHU) devices in undergraduate medical education to delineate their role, significance, and limitations.

METHODS: We searched Cochrane, PubMed, Embase, and Medline using the strategy: [(Hand-held OR Portable OR Pocket OR "Point of Care Systems") AND Ultrasound] AND (Education OR Training OR Undergraduate OR "Medical Students" OR "Medical School"). We retained 12 articles focusing on undergraduate medical education. We summarised the patterns of HHU use, pooled and estimated sensitivity, and specificity of HHU for detection of left ventricular dysfunction.

RESULTS: Features reported were heterogeneous: training time (1–25 hours), number of students involved (1–an entire cohort), number of subjects scanned (27–211), and type of learning (self-directed vs. traditional lectures + hands-on sessions). Most studies reported cardiac HHU examinations, but other anatomical areas were examined, e.g. abdomen and thyroid. Pooled sensitivity 0.88 [95% confidence interval (CI) 0.83–0.92] and specificity 0.86 (95% CI 0.81–0.90) were high for the detection of left ventricular systolic dysfunction by students.

CONCLUSION: Data on HHU devices in medical education are scarce and incomplete, but following training students can achieve high diagnostic accuracy, albeit in a limited number of (mainly cardiac) pathologies. There is no consensus on protocols best-suited to the educational needs of medical students, nor data on long-term impact, decay in proficiency or on the financial implications of deploying HHU in this setting.

KEY WORDS: Hand-held ultrasound · Undergraduate medical education · Sensitivity · Specificity · Echocardiography.

INTRODUCTION

Recent advances in ultrasound technology have led to the miniaturization of machines initially to the size of a laptop computer and more recently to that of a mobile phone. In the hands of a trained user, the hand-held ultrasound (HHU) device allows a more accurate examination^{1,2)} augmenting the standard physical examination,^{3,4)} often sufficiently to change clinical management.^{4,5)} It is also quicker and more accessible than standard transthoracic echocardiography,^{1,2)} offering a more cost-effective patient assessment.⁶⁾ As the use of bedside ultrasound becomes common place,⁷⁾ familiarity with this imaging technique in medical school might be beneficial. Ultrasound can be combined with simulation techniques and interactive web-based re-

sources to present complex concepts in multiple modalities.⁸⁾

In fact, some medical schools have already incorporated ultrasound teaching into their curricula. The USA "national ultrasound curriculum" outlines areas for which ultrasound examination should be taught.⁹⁾ Although difficulties in integrating such changes are anticipated,^{9,10)} there is evidence that ultrasound imaging improves medical students' knowledge of living anatomy and physiology^{10,11)} and increases their motivation to learn.¹²⁾ However, little work exists on the use of HHU in this setting and many programmes use high-end machines as they offer better on-screen resolution and are easier to use than the HHU. The cheapness, portability, and accessibility of HHU devices make them more suitable for a 'hands-on' ap-

• Received: July 6, 2017 • Revised: August 31, 2017 • Accepted: September 1, 2017

• Address for Correspondence: Victor Galusko, Swansea University Medical School, Singleton Park, Swansea SA2 8PP, UK

Tel: +44-179-251-3400, Fax: +44-179-261-8889, E-mail: victorgalusko@hotmail.co.uk

• This is an Open Access article distributed under the terms of the Creative Commons Attribution Non-Commercial License (<http://creativecommons.org/licenses/by-nc/4.0>) which permits unrestricted non-commercial use, distribution, and reproduction in any medium, provided the original work is properly cited.

proach to teaching – a proposition supported by a statement from the European Association of Echocardiography¹³⁾ on the use of HHU devices for teaching medical students, which recognises their utility in everyday practice.

We conducted a novel systematic literature review focused on undergraduate medical education in order to document patterns of usage of HHU devices, evaluate teaching techniques, and define the examination protocols taught to medical students. We hope the review will stimulate further systematic research leading to a rigorous definition of the place of HHU in medical school curricula.

METHODS

We searched four on-line medical literature databases (Cochrane, PubMed, Embase, and Medline) on the 08/01/2017 using the search strategy: [{"Hand-held" OR "Portable" OR "Pocket" OR "Point of Care Systems"}] and ["Ultrasound"]} and {"Education" OR "Training" OR "Undergraduate" OR "Medical Students" OR "Medical School"}. "Point of care systems" was the only Medical Subject Heading (MeSH) term used; other terms were part of the search as keywords. We screened Open Grey for unpublished studies using the key words ("Hand-held" OR "Portable" OR "Point of Care Systems"). The search was limited to "Human" studies and to English language publications, but not by date of publication.

ELIGIBILITY AND DATA COLLECTION

The search yielded 1365 abstracts. Two authors (AI and VG) selected those featuring, 1) medical students who were, 2) trained/educated using a, 3) genuinely hand-held device (as opposed to cart- or laptop-based ultrasound). We included primary and secondary research literature but not conference abstracts. References in relevant papers were searched manually to identify additional studies of interest. We identified 26 papers that fulfilled the inclusion criteria. Analysis of full texts led to the removal of 14 of these studies, which included 5 abstracts for which full text was not available. A flow diagram for the search is displayed in Fig. 1.

DATA EXTRACTION AND ANALYSIS

The following items were extracted from the papers selected for analysis: type of HHU device used; intensity, type, and duration of HHU-specific training offered; setting (clinical, e.g., ward-based or out-patient, or laboratory setting); pathologies detected/body areas scanned; metrics for the detection of left ventricular (LV) dysfunction; number of medical students involved and their year of medical studies, and any metrics reflecting student performance before and after the introduction of HHU-based scanning. We extracted sensitivity and specificity parameters, and calculated a diagnostic odds ratio (OR) for the detection of LV dysfunction using the HHU device. Data was collated and analysed using MetaDisc, a freely available

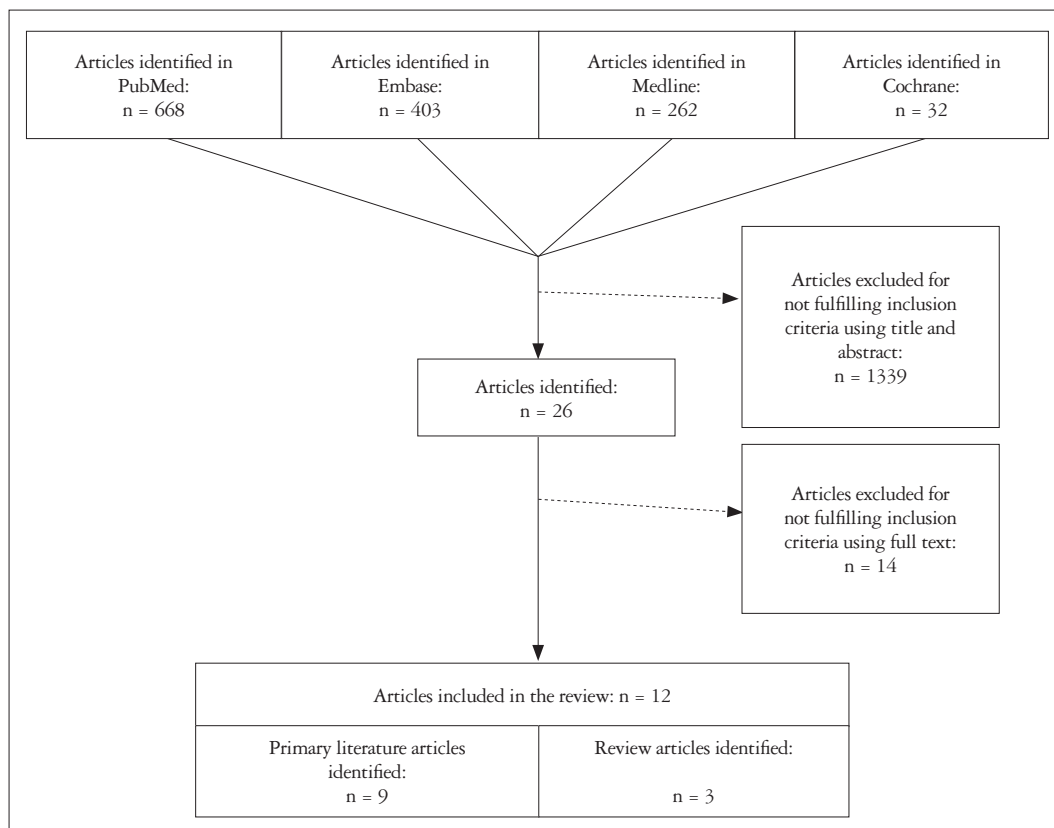


Fig. 1. Flow chart of the study selection process.

statistical package designed for the meta-analysis of diagnostic data. The results were represented as forest plots and an analysis of heterogeneity was performed.

RESULTS

STUDIES INCLUDED

We retained nine primary literature articles for which full text articles were available.¹⁴⁻²² Three relevant non-systematic reviews were also identified,²³⁻²⁵ containing information on HHU use in undergraduate medical education, yielding a total of 12 studies (Fig. 1).

Studies were published between 2010 and 2014, three from USA¹⁴⁻¹⁶ and six from Europe.¹⁷⁻²² The mean number of medical student participants [standard deviation (SD)], based on studies where this information was available, was 18 (15.5), (range 1–45). The one study where the number of participants was unavailable, all students across four years of medical school participated.¹⁵

TRAINEES

While all studies included medical students, 2 also included other healthcare professionals (medical residents²² and pharmacy residents¹⁶), and did not separate the findings by type of participant in their final analyses. However, none of the participants had previous experience in ultrasonography thus qualifying as genuine “novices.”

SETTING

Most studies were carried out on unselected patients in the hospital.^{16-18,20-22} Two studies were primarily classroom based, utilising volunteers^{14,19} with some inpatient scanning.¹⁴ The mean number (SD) of patients scanned, based on 6 studies for which the information was available, was 96 (65), range 27–211.

HHU DEVICES USED

Studies reported using 2 types of HHU device: Vscan (GE Vingmed Ultrasound AS, Horten, Norway) used in 6 studies, and Acuson P10 (Siemens Ultrasound, Surrey, UK) used in 3 studies. One of the studies did not report the model of HHU used.¹⁵ In all studies, results obtained by HHU examinations were compared to formal, comprehensive ultrasound examinations performed by an expert using high-end scanners in the local ultrasound department. We also noted that some literature featured hand-carried devices (such as the OptiGo and Micro-Maxx) and, incorrectly in our view, referred to them as hand-held.²⁵

TRAINING TO USE HHU

All studies reported hands-on, skills-teaching sessions, complemented by either didactic teaching (7 studies) or self-directed learning resources (1 study), or both (3 studies). One study used purely self-directed learning groups of students,¹⁴ while

others utilised radiologists,¹⁸ sonographers,¹⁴ cardiologists and senior cardiology trainees,¹⁸ and even senior medical students, as teachers.¹⁵ When self-directed echocardiography simulators were used to teach image interpretation efficacy was lower than for a traditional lecture-based approach.¹⁴ The teaching itself varied in length and the mean (SD) duration of training was 9.8 (7.5) hours, range from 1 hour¹⁶ to 25 hours.²¹ There was no correlation between length of training and diagnostic accuracy assessed at the end of training, but such an association would have been difficult to detect due to the heterogeneity of the data and small sample size (Supplementary Fig. 1A, B, and C).

Fox et al.¹⁵ used on-line self-directed teaching materials and Apple iTunes-based podcasts to support learning. Another study compared the efficacy of traditional lecture-based approaches with fully self-directed online e-modules and self-directed simulation for the purposes of ultrasound education; no difference was detected with respect to understandings of theoretical aspects of ultrasonography and image interpretation.¹⁴ However, the presence of facilitators to guide the students resulted in better image acquisition abilities.

CLINICAL APPLICATIONS

Medical students were taught to obtain and interpret ultrasound images of a variety of anatomical structures and organs (Fig. 2); others were trained to carry out the focused assessment with sonography for trauma (FAST) scan.¹⁹ The most widely studied application was imaging of the heart, featuring in 8 of the 9 primary literature articles. Medical students reported feeling confident to use the HHU device even after short (5 hours) training sessions.¹⁹

A medical student trained to use a HHU device can achieve superior diagnostic accuracy compared with physical examination.¹⁷ Moreover, after only short training sessions (< 1 hr), novices can be guided ‘in real time’ to perform a focused cardiac examination under off-site expert guidance, with image quality comparable to that achieved by experienced sonographers.¹⁶ However, HHU devices achieve lower diagnostic accuracy than larger, more sophisticated scanners.²¹ Furthermore, medical students prefer cart-based devices to HHU and are able to obtain better quality images using the larger machines.¹⁹

EFFECTS OF TRAINING

Assessment of the short-term effects of training varies between studies, making head-to-head comparison of results difficult. The most consistently detected pathology across the studies was LV systolic dysfunction. Sensitivity and specificity for the detection of LV dysfunction from four studies is summarised in the Supplementary Fig. 1A, B, and C. The summary receiver operating characteristic curve (Supplementary Fig. 2) demonstrates high diagnostic accuracy for detection of LV dysfunction. Although pooled sensitivity and specificity [95% confidence interval (CI)] for LV dysfunction reached 0.88 (0.83–0.92) and 0.86 (0.81–0.90) respectively, the data was heterogeneous

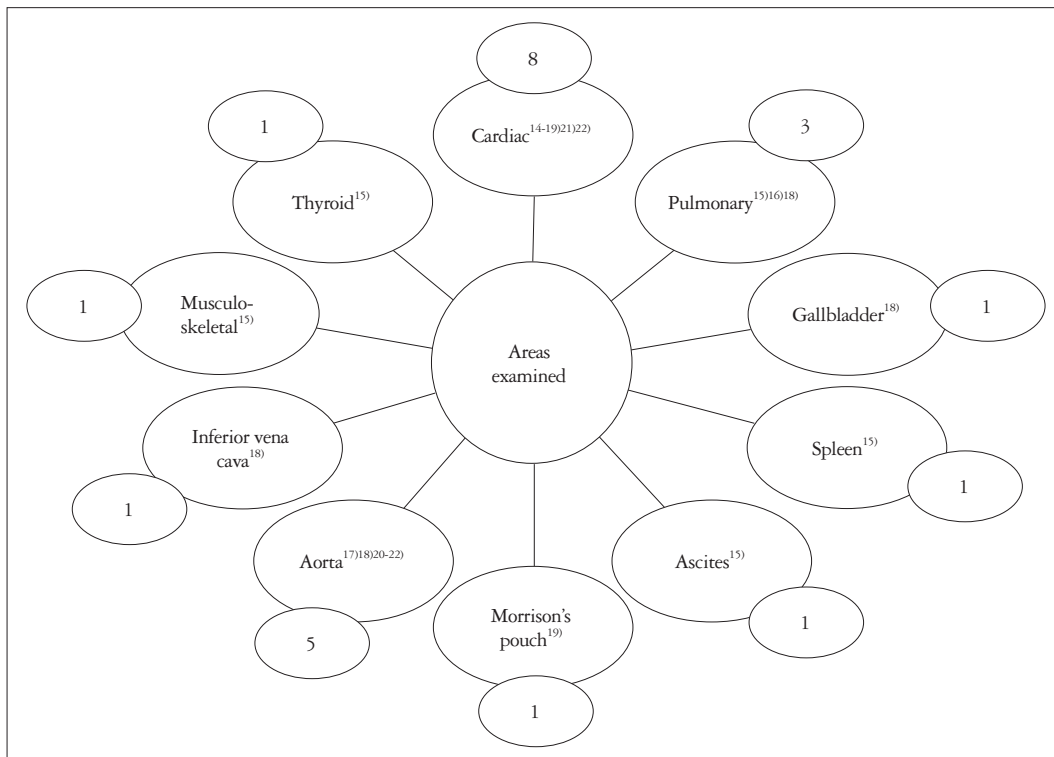


Fig. 2. Structures examined with hand-held ultrasound (with number of studies for each structure and with references).

(I² values of 85.0% and 90.5% respectively). The diagnostic OR (95% CI) for the detection of LV dysfunction was 62.3 (12.8–303.8).

The sensitivity for the detection of pericardial effusions was variable, with one study reporting 100%,²²⁾ while the other reporting 40%.¹⁷⁾ Similarly sensitivities for valvular regurgitation and stenosis varied (Table 1), but were consistently > 70%,^{17,22)} aside from aortic regurgitation where one report demonstrates sensitivity to be 43%.¹⁷⁾ Aortic root dilatation detection had the lowest sensitivity at 25% with a specificity of 88%.¹⁷⁾ Diagnostic accuracy reached 100% for measurement of the abdominal aorta or for detection of ascites, and was at its lowest for detecting gallstones or cholecystitis.¹⁸⁾

To further emphasise the heterogeneity, some students were assessed using an objective structured clinical examination (OSCE) in a controlled environment, using written cases and a normal volunteer examination,¹⁹⁾ while others were assessed based on a log of selected examinations, performed on non-standardised (authentic) patients on hospital wards.¹⁸⁾ All studies confirmed that using HHU devices produced an improvement of the performance parameters monitored. The results are summarised in Table 1.

DISCUSSION

Research into the use of HHU in medical education is scarce and highly heterogeneous. Studies focus on teaching medical students to identify pathology, mostly pertaining to the heart, rather than teaching anatomy and physiology. Nevertheless,

we have found that teaching medical students the basics of ultrasound using novel HHU devices is feasible and effective. Many investigators recognise the use of self-directed learning packages to aid ultrasound learning and recognition of pathology. HHU is ‘the stethoscope of the future’ and may have multiple uses in the hands of the physician.^{2,26,27)} While formal scanning with ‘full-blown’ ultrasound machines^{11,12)} has been shown to increase the understanding of anatomy and physiology in undergraduate medical education, whether HHU has a similar effects has not yet been evaluated.

BENEFITS OF HHU TRAINING FOR MEDICAL STUDENTS AND ITS EFFECTS

HHU is not a substitute for clinical examination, but rather an extension of it, improving diagnostic accuracy for a range of conditions.^{3,17,28)} Although, data are inconsistent, high sensitivities are achieved for a number of cardiac and non-cardiac pathologies, which may not be detected on physical examination alone. Even with limited training, medical students across the studies demonstrated relatively high sensitivities (88%) and specificities (86%) for the detection of LV systolic dysfunction. It is fairly certain that HHU is always discriminatory between those with and those without LV systolic dysfunction, according to the odd's ratio (62.3).

Students also perform well when asked to complete a FAST scan and are able to detect free fluid on simulators as part of an OSCE, despite receiving only 5 hours of training.¹⁹⁾ Abdominal aortic diameters²⁰⁾ can be measured accurately by novices, while

Table 1. Findings from studies available in full text format

Reference	Device	Students, year of study	Patients, setting	Training	Study design	Areas and structures examined	Results	Comments
Stokke ¹⁷⁾	Vscan	21, final 2 years	72 patients attending for routine echo ^{a)}	4 hours	Diagnostic accuracy in 2 scenarios: history + physical examination, with and without HHU	Cardiac: LV, RV, LA, RA, aortic root, AV, MV, TV, pericardial effusion	Addition of HHU achieved sensitivity of: 69% for MR (improved from 26%, $p < 0.001$) 70% for moderate AS* 43% for AR* 90% for IV dysfunction 79% for RV dysfunction 53% for dilated LA 49% for dilated RA 40% for pericardial effusion 25% for dilation of the aortic root * $p = NS$ vs. physical exam	HHU improved sensitivity for mild AR (19% vs. 77%) and mild AS (72% vs. 97%) Mean duration of HHU exam = 17 minutes
Andersen ¹⁸⁾	Vscan	30, 5th year	211 patients in the hospital (including in-patients and out-patient clinics)	9 hours	Diagnostic accuracy in 2 scenarios: physical examination, with and without HHU	Cardiac: IV function, pericardial effusion Lung: Pleural effusion, lung comets Renal: Hydronephrosis, bladder distension GI: Gallstones, abdominal free fluid, cholecystitis Vascular: Diameter of abdominal aorta and inferior vena cava	Acceptable image quality in 74% of cardiac scans and in 88% of abdominal scans Sensitivity and specificity for detection of pathology: CVS-96% and 92% Lung-91% and 95% Abdominal aorta-92% and 100% Renal system-90% and 93% Gallbladder-94% and 86% Free abdominal fluid-100% and 100%	Students kept a log of their HHU scanning on the wards Potential for selection bias as students decided which loops were reviewed
Fox ¹⁵⁾	HHU ^{b)}	Number not reported, all years	N/A	1 h/week × 16 weeks	Ultrasound curriculum taught using HHU	Eye, thyroid, neck, pulmonary, cardiac, liver, ascites, spleen, musculoskeletal and peripheral IV insertion	Detailed description of how the Stanford Medicine 25 examination can be augmented using HHU	HHU across all 4 years of medical school across many organ systems Student-to-instructor ratio 4:1
Bonnafy ²⁰⁾	Vscan	Not reported	56 unselected in-patients	9 hours	Aortic diameter measured by students using HHU vs. experts using HHU and formal echo with high-end scanners	Abdominal aorta	Mean difference between measurements by experts using conventional ultrasound and medical students using HHU was < 4 mm in 92% of cases Intra-class correlation coefficient between the medical students using HHU and the experts using conventional ultrasound was > 0.90 (0.84–0.94)	Only 2 patients in the study had AAAA Briefly trained medical students can reliably measure the diameter of the abdominal aorta

Table 1. Findings from studies available in full text format (continued)

Reference	Device	Students, year of study	Patients, setting	Training	Study design	Areas and structures examined	Results	Comments																				
Panoulas ²³⁾	Vscan	5, final year 3, junior doctors	122 in-patients	2 hours	Diagnostic accuracy in 2 scenarios: history + physical examination + 12-lead ECG, with or without HHU	Cardiac: IV, RV, aorta, pericardial effusion, valvular abnormalities	<table border="1"> <thead> <tr> <th>Pathology</th> <th>HHU</th> <th>Sensitivity</th> <th>Specificity</th> </tr> </thead> <tbody> <tr> <td>IV dysfunction</td> <td>Yes</td> <td>26</td> <td>85</td> </tr> <tr> <td>Valve lesions</td> <td>No</td> <td>46</td> <td>94</td> </tr> <tr> <td></td> <td>Yes</td> <td>70*</td> <td>98*</td> </tr> <tr> <td></td> <td></td> <td>86[†]</td> <td>100[†]</td> </tr> </tbody> </table>	Pathology	HHU	Sensitivity	Specificity	IV dysfunction	Yes	26	85	Valve lesions	No	46	94		Yes	70*	98*			86 [†]	100 [†]	53% of examinations were performed by medical students and 47% were performed by junior doctors
Pathology	HHU	Sensitivity	Specificity																									
IV dysfunction	Yes	26	85																									
Valve lesions	No	46	94																									
	Yes	70*	98*																									
		86 [†]	100 [†]																									
Filipiak-Strzecka ²¹⁾	Acuson P10	2, years 4 and 5	90 unselected patients referred to cardiac intensive care unit and 30 out-patients	25 hours	Direct comparison between HHU findings by students and formal comprehensive echo by experts	Cardiac: IV, RV, LA, aorta, mitral and aortic valves and pericardial effusion	<p>*regurgitation, [†]stenosis</p> <p>Pericardial effusion was detected with 100% sensitivity and specificity using HHU</p> <p>Agreement between standard echo and HHU: fair (kappa 0.29–0.57) to very good (kappa 0.73–1.00), Agreement with standard echo was better in outpatients than in ITU</p>	89% of patients had abnormalities on standard echo																				
Gogalniceanu ¹⁹⁾	Acuson P10, Acuson 300PE, Acuson x 150	25, years 3 and 5	Case-based discussions, volunteer, simulators	5 hours	Assessment of the ability of students to learn and perform a FAST scan; A score was calculated for the performance of a FAST scan and the students' ability to interpret images on a simulator in an OSCE setting	FAST scanning: Morrison's pouch, splenorenal recess, A4C view of the heart, pericardium, bladder and pelvis	<p>85% of students completed the FAST scan in < 6 minutes to an adequate level</p> <p>Mean assessment score was 86%;</p> <p>88% of correctly diagnosed the presence or absence of free abdominal fluid on the simulator</p>	Trained students were able to perform FAST scanning (OSCE assessment). Students preferred the cart-based machines, for better image quality ease of use																				
Mat ¹⁶⁾	Vscan, Acuson P10	3 subjects: 1 medical student, 1 intern, 1 pharmacy resident	27 (22 out-patients and 5 normal volunteers)	< 1 hour	Assessment of the ability of novice operators to obtain adequate images with continuous, real-time audio guidance from off-site experts who had access to the 'live' images, compared to standard echo by expert sonographers	Cardiac limited ultrasound exam (CLUE): IVD, LA size, interstitial lung oedema, elevated central venous pressure	<p>Novices obtained adequate views in 90% of cases, sonographers in 96%</p> <p>'Novice' HHU scan sensitivity and specificity were:</p> <p>80% and 95% for IVD</p> <p>69% and 82% for LA enlargement</p> <p>40% and 100% for lung comets</p> <p>100% and 96% for elevated central venous pressure</p>	Novice operators can perform high-standard CLUE examinations with live guidance from off-site expert.																				

Table 1. Findings from studies available in full text format (continued)

Reference	Device	Students, year of study	Patients, setting	Training	Study design	Areas and structures examined	Results	Comments
Cawthorn ¹⁰⁾	Vscan	12, first year	Training mainly in the classroom; 2 hours were spent examining hospital in-patients	16 hours (2 hours for 8 weeks)	Students were evaluated on their ability to interpret images as part of online questionnaire and their abilities to acquire images were examined whilst performing an examination on a health volunteer	Cardiac: LV dysfunction, LVH, stenosis or regurgitation of the aortic and mitral valves and pericardial effusion	Students improved their ability to interpret ultrasound scans for mitral regurgitation, LV hypertrophy and recognition of absence of pathology as compared to the pre-test values, not for the other pathologies Mean scanning score assessing imagine acquisition was 2.14 (on a four point scale, 1 = excellent, 4 = poor)	Students have not yet had their core cardiology teaching Students had the availability to about 10 hours of e-modules Students had the ability to use HHU units in their own time to gain extra practice
	Vscan	45, third year	Classroom based training	Program 1 (lecture- based)-8 hrs Program 2 (E-module and sonographer-guided training)-14 hrs Program 3 (self-directed E-module and cardiac ultrasound simulator)-12 hrs	Direct comparison of effect of 3 types of training on the ability of medical student to interpret HHU recordings of cardiac pathology. The ability of students to interpret scans was assessed by an online questionnaire; and their abilities to acquire images were examined whilst performing an examination on a health volunteer	Cardiac: LV dysfunction, LVH, regurgitation of the aortic and mitral valves and pericardial effusion	Mean image interpretation score Group Mean post-intervention score Improve-ment <i>p</i> value Program 1 85% 125% < 0.001 Program 2 82% 141% < 0.001 Program 3 81% 148% < 0.001 No significant difference in image interpretation among the three educational programs (<i>p</i> = 0.65) Mean image acquisition score Group Mean scanning accuracy (i.e., probe positioning) Mean quality score (0-9); 0-unreadable; 9- excellent Program 1 82% 3.87 < 0.001 Program 2 85% 3.15 < 0.001 Program 3 81% 2.58 < 0.001 Program 3 had significantly lower image quality score (no <i>p</i> value) There was no significant difference in the mean scanning accuracy between the three programs Image quality scores	All three programmes had comparable image interpretation scores and probe positioning abilities. Purely self-directed learning (program 3) yielded worse image quality highlighting the importance of expert instruction Students had the availability to about 10 hours of E-modules across all the training programs Students had the ability to use HHU units in their own time to gain extra practice
							Echocardiographic view Image quality (range 0-9, 0-unreadable, 9 excellent)	
							A2C 2.14	
							A4C 3.13	
							A5C 2.70	
							PLX 3.98	
							PSX-AV 3.27	
							PSX-MV 3.29	
							PSX-LV 3.73	
							PSX-A 3.47	

a) No further information available. A4C: apical four-chamber, AAA: abdominal aortic aneurysm, AR: aortic regurgitation, AS: aortic stenosis, AV: aortic valve, CVS: cardiovascular system, FAST: focused assessment with sonography for trauma, GI: gastro-intestinal, HHU: hand-held ultrasound, LA: left atrium, LV: left ventricle, LV/D: left ventricular dilatation, LVH: left ventricular hypertrophy, MR: mitral regurgitation, MV: mitral valve, OSCE: objective structured clinical examination, PLX: parasternal long axis, PSX: parasternal short axis, PSX-AV: parasternal short axis, RA: right atrium, RV: right ventricle, TV: tricuspid valve, WMAs: wall-motion abnormalities

the accuracy for the detection of pericardial effusions remains uncertain.^{17,22)}

HHU can change patient management in emergencies when used by an expert.⁵⁾ It is unlikely that a novice would be able to achieve the same accuracy. Nevertheless, diagnostic values are high when HHU is used by the students and may help with early recognition and management of the acutely ill patient (e.g., differentiating between LV dysfunction vs. acute exacerbation of chronic obstructive pulmonary disease.²⁶⁾ Familiarity with echocardiography during undergraduate medical education may also allow 'tomorrow's doctors' later to prioritise particular patients for standard 'departmental' echocardiogram, to recognise the limitations of the technique and, in some, to nurture a desire to further develop their skills in non-invasive imaging; all of these would support inclusion of HHU in the curriculum of medical schools.

BARRIERS TO THE WIDESPREAD ADOPTION OF HHU IN UNDERGRADUATE MEDICAL EDUCATION

POOR QUALITY OF AVAILABLE DATA TO GUIDE POLICY

There is substantial variation within the literature for all the parameters we extracted. There is no consensus on what defines the appropriate use of HHU in medical education. Until a position statement from relevant professional bodies is adopted, it is likely that penetration of HHU will remain patchy and inconsistent—driven mainly by local interest and resource.

LACK OF CONSENSUS ON THE DESIRABLE LEVEL OF COMPETENCE

There is no generally held agreement about a minimal level of competence or a standard set of skills that should be taught. It may be possible to certify medical students in focused ultrasound scanning, but this approach has not been reported. Criteria and pathways for accreditation need to be developed and monitored to ensure appropriate clinical governance. Formal accreditation early in the career, with the provision of evidence of continuing use²⁹⁾ may be effective in maintaining competence in the longer term.

LIMITED AVAILABILITY OF QUALIFIED TEACHERS/TRAINERS

Cardiologists and accredited cardiac sonographers are the 'gold standard' for teaching HHU of the heart, and are not easily released from their clinical duties to provide support for medical student education. Alternatives may be considered, such as non-clinical instructors, specially-trained students with an interest in imaging,¹⁵⁾ junior doctors, and this may represent a fertile area for research and development. The most important factor for the success of integration of HHU teaching into the curriculum is a good team to drive the change.³⁰⁾ Free on-line HHU learning resources, such as podcasts,¹⁵⁾ i-books,³¹⁾ and e-modules,¹⁴⁾ may have an important part to play.

UNCERTAINTY ABOUT LONG-TERM RETENTION OF SKILLS

Any attempt at disseminating ultrasound education using HHU in the medical school needs to be synchronised with a similar drive in the postgraduate arena. A recent study by Kimura et al.³²⁾ conducted on physician graduates shows that cardiac ultrasound skills decline within 2 years of non-use. Therefore, unless doctors have opportunities to maintain the ability to use HHU, it can be argued that undergraduate training is not worth the trouble.

LIMITATIONS

This review was limited to studies published in English. The studies were markedly inhomogeneous, which prevented rigorous comparisons. Most students included in the studies were volunteers, presumably with a specific interest in the topic, so results cannot be generalised to a situation where HHU would be 'rolled-out' to all students in a cohort.

CONCLUSION

It is possible to teach medical students how to use HHU scanners, and this enhances their diagnostic accuracy, especially for cardiac conditions. Current data on integrating HHU within medical curricula is suboptimal and highly heterogeneous. Further study is required to assess the longevity of skills retention for HHU, their precise role in the curriculum and in the development of medical careers, the financial impact of a HHU-based approach to medical curricula, pathways to accreditation, and to inform the development of consensus among educators and clinical leaders concerning the use of HHU.

SUPPLEMENTARY MATERIALS

The online-only Data Supplement is available with this article at <https://doi.org/10.4250/jcu.2017.25.3.75>.

REFERENCES

1. Lapostolle F, Petrovic T, Lenoir G, Catineau J, Galinski M, Metzger J, Chanzy E, Adnet F. *Usefulness of hand-held ultrasound devices in out-of-hospital diagnosis performed by emergency physicians.* *Am J Emerg Med* 2006; 24:237-42.
2. Wright J, Noriega O, Ho H. *The application of hand-held ultrasound scanner in teaching of telemedicine and rural medicine.* *Donald Sch J Ultrasound in Obstet Gynecol* 2014;8:87-91.
3. Kobal SL, Trento L, Baharami S, Tolstrup K, Naqvi TZ, Cercek B, Neuman Y, Mirocha J, Kar S, Forrester JS, Siegel RJ. *Comparison of effectiveness of hand-carried ultrasound to bedside cardiovascular physical examination.* *Am J Cardiol* 2005;96:1002-6.
4. Kimura BJ, Shaw DJ, Agan DL, Amundson SA, Ping AC, DeMaria AN. *Value of a cardiovascular limited ultrasound examination using a hand-carried ultrasound device on clinical management in an outpatient medical clinic.* *Am J Cardiol* 2007;100:321-5.
5. Egan M, Ionescu A. *The pocket echocardiograph: a useful new tool?* *Eur J Echocardiogr* 2008;9:721-5.
6. Greaves K, Jeetley P, Hickman M, Dwivedi G, Sabharwal N, Lim T, Janardhanan R, Senior R. *The use of hand-carried ultrasound in the hospital setting—a cost-effective analysis.* *J Am Soc Echocardiogr* 2005;18:620-5.
7. Otto CM. *Heartbeat: Echo anytime, anywhere by anyone?* *Heart* 2016;102:

- 1-2.
8. Estai M, Bunt S. *Best teaching practices in anatomy education: a critical review.* *Ann Anat* 2016;208:151-157.
 9. Baltarowich OH, Di Salvo DN, Scutt LM, Brown DL, Cox CW, DiPietro MA, Glazer DI, Hamper UM, Manning MA, Nazarian LN, Neutze JA, Romero M, Stephenson JW, Dubinsky TJ. *National ultrasound curriculum for medical students.* *Ultrasound Q* 2014;30:13-9.
 10. Sweetman GM, Crawford G, Hird K, Fear MW. *The benefits and limitations of using ultrasonography to supplement anatomical understanding.* *Anat Sci Educ* 2013;6:141-8.
 11. Tshibwabwa ET, Groves HM. *Integration of ultrasound in the education programme in anatomy.* *Med Educ* 2005;39:1148.
 12. Hammoudi N, Arangalage D, Boubrit L, Renaud MC, Isnard R, Collet JP, Cohen A, Duguet A. *Ultrasound-based teaching of cardiac anatomy and physiology to undergraduate medical students.* *Arch Cardiovasc Dis* 2013;106:487-91.
 13. Sicari R, Galderisi M, Voigt JU, Habib G, Zamorano JL, Lancellotti P, Badano LP. *The use of pocket-size imaging devices: a position statement of the European Association of Echocardiography.* *Eur J Echocardiogr* 2011;12:85-7.
 14. Cawthorn TR, Nickel C, O'Reilly M, Kafka H, Tam JW, Jackson LC, Sanfilippo AJ, Johri AM. *Development and evaluation of methodologies for teaching focused cardiac ultrasound skills to medical students.* *J Am Soc Echocardiogr* 2014;27:302-9.
 15. Fox JC, Schlang JR, Maldonado G, Lotfipour S, Clayman RV. *Proactive medicine: the "UCI 30," an ultrasound-based clinical initiative from the University of California, Irvine.* *Acad Med* 2014;89:984-9.
 16. Mai TV, Ahn DT, Phillips CT, Agan DL, Kimura BJ. *Feasibility of remote real-time guidance of a cardiac examination performed by novices using a pocket-sized ultrasound device.* *Emerg Med Int* 2013;2013:627230.
 17. Stokke TM, Ruddox V, Sarvari SI, Otterstad JE, Aune E, Edvardsen T. *Brief group training of medical students in focused cardiac ultrasound may improve diagnostic accuracy of physical examination.* *J Am Soc Echocardiogr* 2014;27:1238-46.
 18. Andersen GN, Viset A, Mjølstad OC, Salvesen O, Dalen H, Haugen BO. *Feasibility and accuracy of point-of-care pocket-size ultrasonography performed by medical students.* *BMC Med Educ* 2014;14:156.
 19. Gogalniceanu P, Sheena Y, Kashef E, Purkayastha S, Darzi A, Paraskeva P. *Is basic emergency ultrasound training feasible as part of standard undergraduate medical education?* *J Surg Educ* 2010;67:152-6.
 20. Bonnafy T, Lacroix P, Desormais I, Labrunie A, Marin B, Leclerc A, Oueslati A, Rollé F, Vignon P, Aboyans V. *Reliability of the measurement of the abdominal aortic diameter by novice operators using a pocket-sized ultrasound system.* *Arch Cardiovasc Dis* 2013;106:644-50.
 21. Filipiak-Strzecka D, John B, Kasprzak JD, Michalski B, Lipiec P. *Pocket-size echocardiograph—a valuable tool for nonexperts or just a portable device for echocardiographers?* *Adv Med Sci* 2013;58:67-72.
 22. Panoulas VF, Daigeler AL, Malaweera AS, Lota AS, Baskaran D, Rahman S, Nihoyannopoulos P. *Pocket-size hand-held cardiac ultrasound as an adjunct to clinical examination in the hands of medical students and junior doctors.* *Eur Heart J Cardiovasc Imaging* 2013;14:323-30.
 23. Lewiss RE, Hoffmann B, Beaulieu Y, Phelan MB. *Point-of-care ultrasound education: the increasing role of simulation and multimedia resources.* *J Ultrasound Med* 2014;33:27-32.
 24. Solomon SD, Saldana F. *Point-of-care ultrasound in medical education—stop listening and look.* *N Engl J Med* 2014;370:1083-5.
 25. Seraphim A, Paschou SA, Grapsa J, Nihoyannopoulos P. *Pocket-sized echocardiography devices: one stop shop service?* *J Cardiovasc Ultrasound* 2016;24:1-6.
 26. Hothi SS, Springs D, Chambers J. *Point-of-care cardiac ultrasound in acute medicine—the quick scan.* *Clin Med (Lond)* 2014;14:608-11.
 27. Barrett PM, Topol EJ. *To truly look inside.* *Lancet* 2016;387:1268-9.
 28. Mehta M, Jacobson T, Peters D, Le E, Chadderdon S, Allen AJ, Caughey AB, Kaul S. *Handheld ultrasound versus physical examination in patients referred for transthoracic echocardiography for a suspected cardiac condition.* *JACC Cardiovasc Imaging* 2014;7:983-90.
 29. Chambers JB, Rajani R, Short N, Victor K, O'Kane K. *Point-of-care cardiac ultrasound in acute internal medicine: how can it be delivered?* *Clin Med (Lond)* 2015;15:403-4.
 30. Webb EM, Cotton JB, Kane K, Straus CM, Topp KS, Naeger DM. *Teaching point of care ultrasound skills in medical school: keeping radiology in the driver's seat.* *Acad Radiol* 2014;21:893-901.
 31. Johri A, Nadeau-Routhier C, Jaidka A, Church M. *Handheld cardiac ultrasound: case series.* 2014 Dec 11 [cited 2016 Jul 26]. Available from: <https://itunes.apple.com/gb/book/handheld-cardiac-ultrasound/id950815260?mt=13>.
 32. Kimura BJ, Sliman SM, Waalen J, Amundson SA, Shaw DJ. *Retention of ultrasound skills and training in "point-of-care" cardiac ultrasound.* *J Am Soc Echocardiogr* 2016;29:992-7.