
Use of caudal epidural catheter in a child with cerebral palsy with prior posterior spine (T1-sacrum) fusion

Sir,

Children with spastic cerebral palsy (CP) undergo extensive bilateral orthopaedic procedures such as pelvic and femoral osteotomies and tendon transfers and releases. Epidural catheter placement for pain management is an effective, reliable method of post-operative pain control in children with CP^[1] and is our primary choice for post-operative pain management. However, a prior posterior spine fusion (PSF) from the first thoracic vertebra (T1) to the sacrum renders placing a lumbar epidural procedurally difficult.^[2,3] A caudal approach may be

used as the sacrococcygeal structures distal to the first sacral vertebra are intact.

Insertion of caudal epidural catheter in patients with previous PSF is not a commonly performed procedure as evidenced by the scarcity of literature reports. In our institution, the patient population of children with CP is fairly large and they frequently undergo major lower extremity orthopaedic surgery. Caudal access to the epidural space is a familiar approach to post-operative pain management at our institution. We present such a case and its management, including the procedural aspects. Institutional review board approval and written consent from the parent were obtained for publication.

A 15-year-old boy, weighing 35.4 kg with medical history of spastic quadriplegic CP pattern secondary to post-traumatic brain injury, developmental delays, seizure disorder, reactive airway disease and gastroesophageal reflux disease with gastrostomy tube,

was scheduled for bilateral femoral osteotomies, right pelvic osteotomy, open reduction of dislocated spastic right hip and right adductor release. He had undergone PSF with unit rod instrumentation at 12 years of age, fusing the spine from T1 to the sacrum for scoliosis correction. Following induction of general anaesthesia and intubation of the trachea, the patient was positioned in the lateral decubitus position. The sacral hiatus was palpated, and an 18-gauge cannula was used to access the caudal epidural space. A 20-gauge epidural catheter was threaded without difficulty via the cannula into the epidural space. Then, iohexol dye was injected (Omnipaque 240, GE Healthcare, Chicago, IL, USA) to obtain an epidurogram [Figure 1] as is our practice to document catheter position and visualise spread of dye. We did not perform repeated fluoroscopic examinations of dye spread to minimise exposure to both radiation and iohexol dye. However, we anticipate further cephalad spread of epidural medication by 1–2 interspaces from our experience in this patient population. To minimise infection risk in the sacral area, the epidural catheter was looped to stay away from the anus and secured in a sterile fashion with transparent sterile dressings to prevent seepage while providing opportunity for daily examination of the catheter insertion site. A bolus dose of 20 mL of 0.25% bupivacaine was administered in increments, followed by an epidural infusion of 0.1% ropivacaine at 0.28 mg/kg/h. Epidural local anaesthetic was effective, as evidenced by the minimal fluctuation in heart rate and blood pressure measurements during a surgical duration of 4.1 h. As anticipated, the patient had an estimated blood loss of 1100 mL, for which he received a transfusion of packed red cells and fresh

frozen plasma in addition to crystalloids to correct coagulopathy.^[4] At the end of surgery, the trachea was extubated, and the patient was observed overnight in the Intensive Care Unit because of his history of chronic upper airway obstruction. Epidural infusion of 0.1% ropivacaine was maintained at 0.23 mg/kg/h until post-operative day 3 when the epidural catheter was discontinued, and the patient was transitioned to an acetaminophen and hydrocodone combination via gastric tube. He did not require additional narcotics or benzodiazepines during the 3 days for which the caudal epidural catheter was used to provide analgesia. His face, legs, activity, cry, consolability (FLACC) scale pain scores were recorded as 0 during the first 3 days' post-surgery except once on post-operative day 2 when his pain score was 2. In the event of a high FLACC score, clinical correlation would have been performed.

Alternative methods of pain relief that could have been used in this child are intravenous and enteral opioids and benzodiazepines. Opioids were avoided in this child as he had a history of upper airway obstruction. Benzodiazepines are part of our protocol for the management of muscle spasms post-operatively; however, they were not needed in this child. As the child did not require any rescue analgesics, he was therefore able to be discharged from the Intensive Care Unit on the post-operative day 1.

PSF in children with CP fuses the spine from T1 to the sacrum with additional pelvic fixation to correct obliquity of the pelvis using unit rod instrumentation [Figure 2].^[5] The surgical procedure

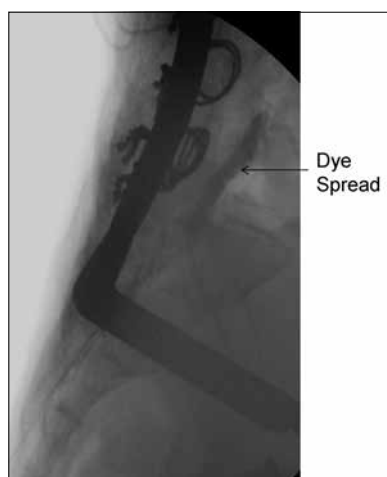


Figure 1: Caudal epidurogram. Lateral view demonstrating spread of iohexol dye (Omnipaque 240) in the epidural space extending cephalad to the fourth and fifth lumbar vertebrae

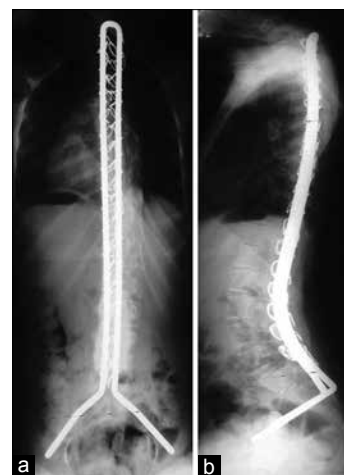


Figure 2: (a) Anteroposterior and (b) lateral view of unit rod *in situ* with sublaminar wires. Extensive nature of the surgical procedure is evident from the double-rod configuration extending from the first thoracic vertebra to sacrum with pelvic fixation

involves subperiosteal dissection extending midline from the T1 vertebra to the sacrum that includes removal of spinous processes followed by removal of the ligamentum flavum, exposing epidural fat.^[6] In addition, the facet joints are excised, and the transverse processes and lateral laminae are decorticated from T1 to the sacrum.^[7] Despite the possibility of scarring and obliteration of the epidural space, there was adequate cephalad spread of the epidural agents providing optimal pain control. Literature is available describing epidural anaesthetic being performed in adult patients for obstetric reasons where they had undergone segmental fusion of the spine leaving short segments of lumbar spine intact.^[8] What makes our case unique is the unavailability of all but caudal access to the epidural space.

Epidural analgesia in this patient with CP, who had chronic upper airway obstruction and had undergone extensive bilateral osteotomies, allowed us to safely extubate the trachea, which otherwise may have been difficult or delayed, given the patient's comorbid conditions. We hope to encourage practitioners to consider caudal approach for epidural catheter placement in children with CP whose post-operative pain is best managed neuraxially.

Financial support and sponsorship

Nil.

Conflicts of interest

There are no conflicts of interest.

**Divya Dixit^{1,2}, Mary C Theroux^{1,2}, Kirk W Dabney^{2,3},
Freeman Miller^{2,3}**

Departments of ¹Anesthesiology and ³Orthopaedics,
Nemours/Alfred I. duPont Hospital for Children, Wilmington, DE,
²Departments of Perioperative Medicine and Anaesthesiology, Sidney
Kimmel Medical College, Thomas Jefferson University, Philadelphia,
PA, USA

Address for correspondence:

Dr. Divya Dixit,
Nemours/Alfred I. duPont Hospital for Children,
PO Box 269, Wilmington, DE 19899, USA.
E-mail: divya.dixit@nemours.org

REFERENCES

1. Brenn BR, Brislin RP, Rose JB. Epidural analgesia in children with cerebral palsy. *Can J Anaesth* 1998;45:1156-61.
2. Sharrock NE, Urquhart B, Mineo R. Extradural anaesthesia in patients with previous lumbar spine surgery. *Br J Anaesth* 1990;65:237-9.
3. Ko JY, Leffert LR. Clinical implications of neuraxial anesthesia in the parturient with scoliosis. *Anesth Analg* 2009;109:1930-4.
4. Brenn BR, Theroux MC, Dabney KW, Miller F. Clotting parameters and thromboelastography in children with neuromuscular and idiopathic scoliosis undergoing posterior spinal fusion. *Spine (Phila Pa 1976)* 2004;29:E310-4.
5. Sponseller PD, Shah SA, Abel MF, Sucato D, Newton PO, Shufflebarger H, *et al.* Scoliosis surgery in cerebral palsy: Differences between unit rod and custom rods. *Spine (Phila Pa 1976)* 2009;34:840-4.
6. Bell DF, Moseley CF, Koreska J. Unit rod segmental spinal instrumentation in the management of patients with progressive neuromuscular spinal deformity. *Spine (Phila Pa 1976)* 1989;14:1301-7.
7. Dias RC, Miller F, Dabney K, Lipton G, Temple T. Surgical correction of spinal deformity using a unit rod in children with cerebral palsy. *J Pediatr Orthop* 1996;16:734-40.
8. Feldstein G, Ramanathan S. Obstetrical lumbar epidural anesthesia in patients with previous posterior spinal fusion for kyphoscoliosis. *Anesth Analg* 1985;64:83-5.

This is an open access article distributed under the terms of the Creative Commons Attribution-NonCommercial-ShareAlike 3.0 License, which allows others to remix, tweak, and build upon the work non-commercially, as long as the author is credited and the new creations are licensed under the identical terms.

Access this article online	
Quick response code	Website: www.ijaweb.org
	DOI: 10.4103/ija.IJA_562_17

How to cite this article: Dixit D, Theroux MC, Dabney KW, Miller F. Use of caudal epidural catheter in a child with cerebral palsy with prior posterior spine (T1-sacrum) fusion. *Indian J Anaesth* 2018;62:80-2.
© 2018 Indian Journal of Anaesthesia | Published by Wolters Kluwer - Medknow