


Maggot debridement therapy with a direct dressing can cause compression injuries in patients with chronic limb ischemia

著者	Nishijima Akio, Yamamoto Naoto, Yoshida Ryuichi, Yanagibayashi Satoshi, Takikawa Megumi, Hayasaka Rie, Maruyama Eri, Nishijima Junko, Sekido Mitsuru
journal or publication title	Case Reports in Plastic Surgery and Hand Surgery
volume	4
number	1
page range	84-88
year	2017-09
権利	2017 The Author(s). Published by Informa UK Limited, trading as Taylor & Francis Group. This is an Open Access article distributed under the terms of the Creative Commons Attribution-NonCommercial License (http://creativecommons.org/licenses/by-nc/4.0/), which permits unrestricted non-commercial use, distribution, and reproduction in any medium, provided the original work is properly cited.
URL	http://hdl.handle.net/2241/00151202

doi: 10.1080/23320885.2017.1373596



Maggot debridement therapy with a direct dressing can cause compression injuries in patients with chronic limb ischemia

Akio Nishijima, Naoto Yamamoto, Ryuichi Yoshida, Satoshi Yanagibayashi, Megumi Takikawa, Rie Hayasaka, Eri Maruyama, Junko Nishijima & Mitsuru Sekido

To cite this article: Akio Nishijima, Naoto Yamamoto, Ryuichi Yoshida, Satoshi Yanagibayashi, Megumi Takikawa, Rie Hayasaka, Eri Maruyama, Junko Nishijima & Mitsuru Sekido (2017) Maggot debridement therapy with a direct dressing can cause compression injuries in patients with chronic limb ischemia, *Case Reports in Plastic Surgery and Hand Surgery*, 4:1, 84-88, DOI: [10.1080/23320885.2017.1373596](https://doi.org/10.1080/23320885.2017.1373596)

To link to this article: <https://doi.org/10.1080/23320885.2017.1373596>



© 2017 The Author(s). Published by Informa UK Limited, trading as Taylor & Francis Group.



Published online: 04 Sep 2017.



[Submit your article to this journal](#)



Article views: 184



[View related articles](#)



[View Crossmark data](#)

CASE REPORT



Maggot debridement therapy with a direct dressing can cause compression injuries in patients with chronic limb ischemia

Akio Nishijima^a, Naoto Yamamoto^a, Ryuichi Yoshida^a, Satoshi Yanagibayashi^a, Megumi Takikawa^a, Rie Hayasaka^a, Eri Maruyama^a, Junko Nishijima^a and Mitsuru Sekido^b

^aDepartment of Plastic and Reconstructive Surgery, New Tokyo Hospital, Matsudo, Chiba, Japan; ^bDepartment of Plastic and Reconstructive Surgery, University of Tsukuba, Tsukuba, Ibaraki, Japan

ABSTRACT

While there are no reports regarding dressing-associated iatrogenic skin ulcer as an adverse event of maggot debridement therapy (MDT), MDT is clinically used on patients with critical limb ischaemia with dermal fragility. Herein we report causes and counter measures for a case of iatrogenic skin ulcer induced by MDT dressing.

ARTICLE HISTORY

Received 26 March 2017
Accepted 28 August 2017

KEYWORDS

Maggot debridement therapy; critical limb ischaemia; dressing; pressure ulcer; direct method; indirect method

Introduction

Maggot debridement therapy (MDT) dates back to the ancient Mayans and as a Burmese folk remedy [1]. The first scientific report was published in 1931 by William Baer who performed MDT for chronic osteomyelitis [2]. MDT gradually fell into disuse due to the development of antibiotics and improved surgical techniques; however, it started to draw renewed attention as a result of the increasing need of intractable ulcer treatment associated with diabetes, arterial sclerosis, as well as the appearance of multiple-drug resistant bacteria.




One caution when applying dressing for MDT is to prevent the escape of maggots. Two methods for appropriately positioning the maggots are the direct and indirect (using bags containing maggots) methods [3]. We conducted MDT on a patient with critical limb ischaemia (CLI) for the purpose of wound-bed preparation (WBP) following Chopart disarticulation. However, a pressure ulcer developed during the treatment period due to compression of the skin by the dressing material, resulting in necrosis of the entire skin layer. Herein, we report causes and measures for iatrogenic skin ulcer during maggot debridement therapy for a CLI patient.

Case report

A 64-year-old man complained of a low temperature burn of the left ankle in January 2015. He had a clinical history of chronic renal failure (undergoing dialysis), cardiac failure, angina, diabetes, chronic obstructive pulmonary disease, hypertension and hyperlipidaemia.

In March 2016, distal bypass surgery was conducted for a lesion in the arterial trifurcation of the left lower limb, using the right great saphenous vein for the posterior tibial artery in the range between the popliteal artery and the ankle, followed by Chopart disarticulation. The amputated surface was left as an open wound, to permit cleansing, application of ointment and spray of basic fibroblast growth factor (bFGF) (Fiblast Spray[®], Kaken Pharmaceutical Co., Tokyo, Japan) depending on the condition of the lesion. However, the wound resisted healing, with yellowish necrotic tissue and local infection noted on the wound surface. As the patient refused to undergo major amputation, MDT was initiated from July 2016, after the determination that limb salvage by conventional treatment was ineffective.

Laboratory test results before the onset of MDT were as follows: left ankle brachial index (ABI): 0.63;

CONTACT Dr Akio Nishijima  handbal1016@yahoo.co.jp  Department of Plastic and Reconstructive Surgery,  New Tokyo Hospital, 1271 Wanagaya, Matsudo 27022232, Japan

© 2017 The Author(s). Published by Informa UK Limited, trading as Taylor & Francis Group.

This is an Open Access article distributed under the terms of the Creative Commons Attribution-NonCommercial License (<http://creativecommons.org/licenses/by-nc/4.0/>), which permits unrestricted non-commercial use, distribution, and reproduction in any medium, provided the original work is properly cited.

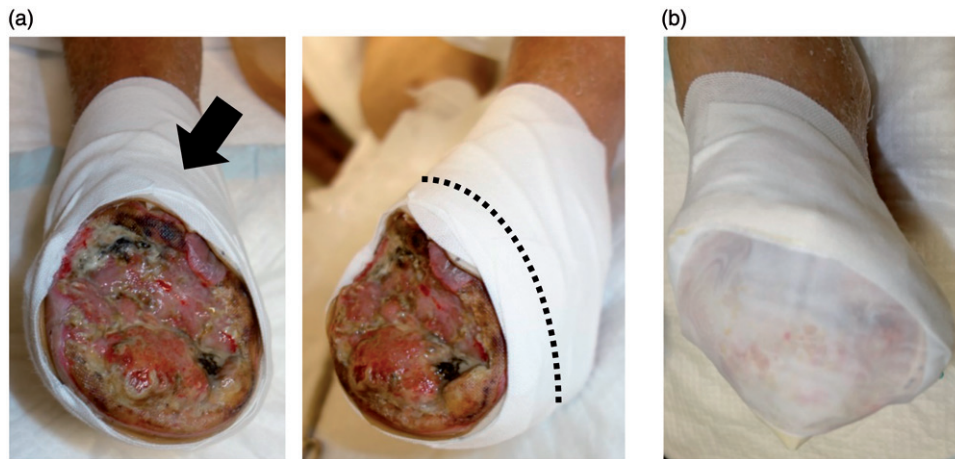


Figure 1. Confinement dressing for maggot debridement therapy. (a) Acrylic adhesive tape (arrow) was applied around the wound to fill the gap between the periphery and hydrocolloid material. The tape extends to the ankle joint. The dotted line shows the border at the portion where hydrocolloid material is pasted. (b) After placing second-instar larvae, a meshed nylon net-sheet was used to cover the site.

skin perfusion pressure (SPP) of the dorsum of the left foot: 26 mmHg, SPP of the left sole: 30 mmHg; C-reactive protein: 9.48 mg/dL; white blood cell count: 7700/ μ L. Wound culture detected *Enterococcus faecalis* and *Escherichia coli*.

Dressing method at the first hospitalisation: maggot confinement dressings

1. The wound was cleansed with tap water, and bio-films and ointment were removed from the wound surface. Hydrocolloid dressing material (Duo-active[®], ConvaTec, Inc.) was applied to fit the shape of the lesion for prevention of maceration and for formation of an embankment for the wound periphery.
2. An acrylic resin adhesive tape (Taketora Co., Yokohama, Japan) was applied around the wound to fill the gap between the periphery and hydrocolloid material (Figure 1(a)).
3. Second-instar larvae were placed on the wound surface in the amount of 10 larvae/ 1 cm^2 , and covered with a meshed nylon net-sheet (Figure 1(b)). Aseptic larvae were purchased from the Japan Maggot Company, for which sterility was proved by the fungus body carrier test.
4. Double stockings were applied, and then covered by a paper diaper to absorb exudative fluid.

Using a 48-h duration period as one session of MDT, two sessions were performed with the same procedure for treatment of the left foot necrosis (Figure 2(a)). At that time, the patient received no restrictions regarding his lower limb movements, including bearing load. After the second session of MDT, dermal

necrosis occurred in the dorsum of the ankle, accompanied by pain (Figure 2(b)), resulting in necrosis of the entire skin layer and necessitating debridement of the lesion (Figure 2(c)). Such dermal necrosis was not seen in the medial or lateral portions of the ankle, Achilles tendon or sole.

After the two MDT sessions, infection deteriorated, showing CRP of 20.16 mg/dL and WBC count of 6390/ μ L; thus, administration of Tazobactam/Piperacillin was started at 9 g/day for 16 days. At 16 days of this administration, the condition improved, showing CRP of 2.85 mg/dL and WBC count of 3860/ μ L. The patient was discharged from hospital 24 days after the onset of MDT, and followed up with outpatient consultations.

At 5 months after debridement, granulation formation was observed, though wound-bed preparation (WBP) was necessary. Therefore, one additional session of MDT was done, applying 10 maggots/ cm^2 for 24 h. At that time, the surrounding intact skin was protected by a spray coating agent (Brava[®]) and an ultra-thin film dressing (Perme-Roll[®], Nitoms, Inc., Tokyo Japan) (Figure 2(d)). The necrotic wound tissues were then removed by MDT with favourable granulation formation (Figure 2(e)). Skin graft of the entire skin layer was performed in January 2017 (Figure 2(f)). The grafted skin was completely taken, and epithelization was observed 1 month later (Figure 2(g)).

Discussion

Generally, two methods are known for applying maggots to wounds: directly or indirectly. The direct maggot application method is generally done either by

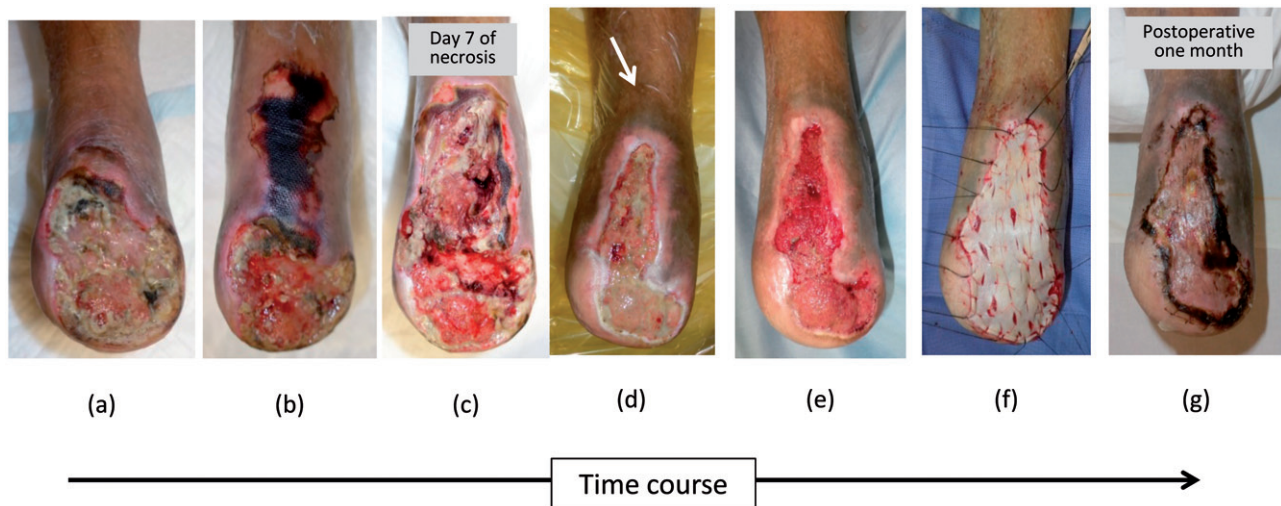


Figure 2. Treatment course of the wound. (a) Before maggot therapy. (b) After two sessions, necrosis of the skin was observed at the dorsal side of the ankle. (c) Day 7 of necrosis site after debridement by the bedside. The necrosis extended to the entire ankle. (d) Five months after debridement. Granulation formation was seen, so that the maggot therapy was planned on the yellowish necrosis lesion on the surface. Before dressing, spray of a film forming agent and pasting of a film were done on the normal skin (arrow). (e) After one session of maggot therapy. Marked reduction of necrotic tissues and favourable granulation formation were seen. Peripheral normal skin was intact. (f) Skin graft was performed. (g) One month after operation. Complete take of the graft was observed.

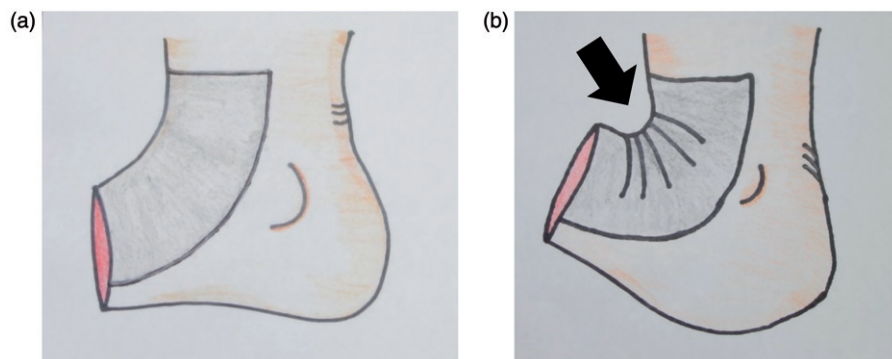


Figure 3. Illustration of compression on the skin after dressing the ankle. (a) Dressing is made on the dorsal side at rest position. (b) Dressing material is compressing at flexion position (arrow).

stocking or peripheral confinement. Jukema et al. presented a flow chart for the selection of dressing method most suited to the location of the wound and the amount of necrotic tissue [3]. For our patient, we selected the direct method by peripheral confinement with dressings because of: (1) the purpose of expediting WBP, (2) the relative ease of dressing a flat wound surface and (3) the fact that the patient's pain was well-controlled.

Special attention is given toward minimising pressure to the skin during dressing; however, in the present CLI case, iatrogenic pressure ulceration occurred due to the excessive dressing pressure to prevent the escape of maggots. Three causes are considered for the iatrogenic pressure ulcer. First, increased skin pressure associated with excessive load when the ankle

was flexed, or due to oedema that occurred when the foot was relaxed to the lower position (Figure 3). One of the benefits of MDT is almost no restriction for patients while resting after application of the dressing. However, when the dressing material covers the ankle, such as with our patient, the effect of bending or occurrence of oedema should be taken into account, as it may raise skin pressure at the dorsal flexion. Second, the skin of the dorsum of the foot remained fragile, which is a dominant region for the anterior tibial artery. In our patient, post-operative angiography indicated less blood flow to the dorsum of the foot. In fact, a skin colour change appeared in the dorsum of the ankle and gradually extended to the distal portions (Figure 2(b,c)). Third, infection of the wound worsened in our patient. Generally, maggots provide a

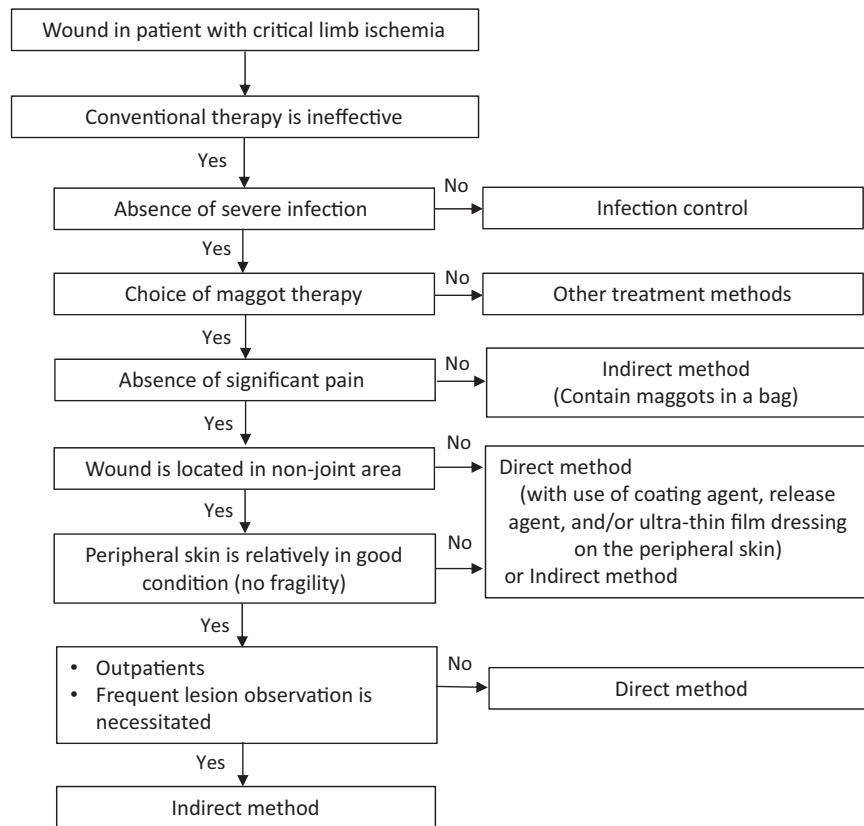


Figure 4. Flow chart for selection of maggot debridement and dressing methods in our hospital.

bactericidal action for both the inside and outside of the body. In particular, antibacterial peptide contained in the secretions of maggots is considered effective for suppressing Gram-positive bacterium such as *Methicillin-resistant Staphylococcus aureus* (MRSA) [4]. However, there is a lack of efficacy against Gram-negative bacterium [5], thus *Escherichia coli* detected in the wound culture of our patient was not affected by MDT. Negative pressure wound therapy is beneficial after the infection is stopped; however, we did not use it because of the concern about recurrence of infection in enclosed wound environment in our case.

At the second hospitalisation, we could prevent damage of the skin by using a coating agent (Brava[®]) to the peripheral normal skin, covering the site with an ultra-thin film dressing (Perme-Roll[®]) at the time of MDT (Figure 2(d,e)). To ensure a safer treatment, perhaps the indirect MDT method should have been used. However, we chose the direct MDT method with careful gently handling the skin, because the patient desired to shorten the treatment period as much as possible.

Angioplasty is no doubt the highest priority in the treatment of CLI patients. Thus, after reconstructing vascular flow in the limb, appropriate treatments are undertaken, such as debridement, amputation or

wound closure. However, successful WBP may not be achieved in some CLI patients, even after attempting angioplasty management. Adjuvant treatment methods other than MDT include hyperbaric oxygen therapy [6], cell therapy [7], gene therapy (intravascular growth factor) [8] and LDL apheresis [9]. However, these therapies require special equipment and the qualification of being an expert; thus, the availability may be limited depending on the particular situation. On the other hand, MDT can be conducted less problematically in ordinary hospitals or outpatient clinics. Four debridement methods for selective removal of necrotic tissues are: (1) surgical debridement, (2) enzymatic debridement, (3) autolytic debridement and (4) biological debridement (MDT). Of these, MDT selectively and effectively debrides necrotic tissues, as well as providing sterilising effects and the promotion of granulation formation; thus, MDT should be considered one of the adjuvant treatment strategies for CLI patients following revascularization of the limb [10].

To the best of our knowledge, there have been no reports on iatrogenic skin ulcer induced by wound dressing, though adverse effects of MDT have been reported, including pain, dermatitis in the periphery of wound, and ammonia-like odour. In clinical practice, MDT is sometimes performed for patients with

diabetes or CLI in whom the skin is fragile; thus, careful management is necessary for such patients. Based on our experience, we propose three cautions in applying dressing during MDT for CLI patients: (1) avoid placement of dressing in the joint motion range as far as possible, (2) take into account the possibility of an increase of skin pressure in the motion range after dressing and (3) when the peripheral skin is fragile, select an indirect method or very gently handle by applying a coating agent, release agent, and/or ultra-thin films. Based on the above considerations, we created a flow chart in the selection of MDT dressing for wounds of CLI patients as shown in [Figure 4](#).

Conclusion

Although MDT is apparently effective for chronic skin ulcer, cautions need to be taken for patients with CLI, considering the fragility and infectiousness of the skin surface at the time of dressing, especially at the joint portion where pressure comes to bear when flexed.

Disclosure statement

No potential conflict of interest was reported by the authors.

References

- [1] Zarchi K, Jemec GB. The efficacy of maggot debridement therapy – a review of comparative clinical trials. *Int Wound J*. 2012;9:469–477.
- [2] Baer WS. The classic: the treatment of chronic osteomyelitis with the maggot (larva of the blow fly). 1931. *Clin Orthop Relat Res*. 2011;469:920–944.
- [3] Jukema GN, Menon AG, Bernards AT, et al. Amputation-sparing treatment by nature: “surgical” maggots revisited. *Clin Infect Dis*. 2002;35:1566–1571.
- [4] Cerovsky V, Bem R. Lucifensins, the insect defensins of biomedical importance: the story behind maggot therapy. *Pharmaceuticals* (Basel, Switzerland). 2014;7: 251–264.
- [5] Andersen AS, Sandvang D, Schnorr KM, et al. A novel approach to the antimicrobial activity of maggot debridement therapy. *J Antimicrob Chemother*. 2010; 65:1646–1654.
- [6] Abidia A, Laden G, Kuhan G, et al. The role of hyperbaric oxygen therapy in ischaemic diabetic lower extremity ulcers: a double-blind randomised-controlled trial. *Eur J Vasc Endovasc Surg*. 2003;25: 513–518.
- [7] Ishigatsubo Y, Ihata A, Kobayashi H, et al. Therapeutic angiogenesis in patients with systemic sclerosis by autologous transplantation of bone-marrow-derived cells. *Mod Rheumatol*. 2010;20:263–272.
- [8] De Haro J, Acin F, Lopez-Quintana A, et al. Meta-analysis of randomized, controlled clinical trials in angiogenesis: gene and cell therapy in peripheral arterial disease. *Heart Vessels*. 2009;24:321–328.
- [9] Norgren L, Hiatt WR, Dormandy JA, et al. Inter-society consensus for the management of peripheral arterial disease (TASC II). *Eur J Vasc Endovasc Surg*. 2007; 33:S1–S75.
- [10] Nishijima A, Yamamoto N, Yoshida R, et al. Maggot debridement therapy for a patient with critical limb ischaemia and severe cardiac dysfunction: possibility of limb salvage. *Case Reports Plast Surg Hand Surg*. 2017;4:42–47.