

An eighteen-month follow-up study on the effects of Intravitreal Dexamethasone Implant in diabetic macular edema refractory to anti-VEGF therapy

Fernanda Pacella ¹, Maria Rosaria Romano ², Paolo Turchetti ³, Giovanna Tarquini ⁴, Anna Carnovale ⁴, Antonella Mollicone ¹, Alessandra Mastromatteo ¹, Elena Pacella ¹

¹Department of Sense Organs, Faculty of Medicine and Dentistry, Sapienza University of Rome, Rome 00161, Italy

²IRCCS, Neuromed, Pozzilli, Isernia 86077, Italy

³National Institute for Health, Migration and Poverty (INMP/NIHMP), Rome 00153, Italy

⁴Department of Internal Medicine and Clinical Specialities, Sapienza University of Rome, Rome 00161, Italy

Correspondence to: Elena Pacella. Department of Sense Organs, Faculty of Medicine and Dentistry, Sapienza University of Rome, Viale del Policlinico, Rome 00161, Italy. elena.pacella@uniroma1.it

Received: 2015-11-05 Accepted: 2016-04-14

Abstract

• **AIM:** To evaluate the long-term efficacy and safety of dexamethasone implants in subjects affected by diabetic macular edema (DME) resistant to anti-vascular endothelial growth factor (VEGF) therapy.

• **METHODS:** Thirty-two DME patients were enrolled. A 700 microgram slow release Intravitreal Dexamethasone Implant (Ozurdex®) was placed in the vitreous cavity. All patients were followed for 18mo. Best-corrected visual acuity (BCVA) measured with Early Treatment Diabetic Retinopathy Study (ETDRS) and central macular thickness (CMT) exams were carried out at baseline (T0) and after 1 (T1), 3 (T3), 4 (T4), 6 (T6), 9 (T9), 12 (T12), 15 (T15), and 18mo (T18) post injection.

• **RESULTS:** Repeated measures ANOVA showed an effect of treatment on ETDRS ($P < 0.0001$). Post hoc analyses revealed that ETDRS values were significantly increased at T1, T3, T4, T9, and T15 ($P < 0.001$) as compared to baseline value (T0). At T6, T12, and T18, ETDRS values were still statistically higher than baseline ($P < 0.001$ vs T0). However, at these time points, we observed a trend to return to baseline conditions. ANOVA also showed an effect of treatment ($P < 0.0001$). CMT decreased significantly at T1, T3, T4, T9, and T15 ($P < 0.001$). At T6 ($P < 0.01$), T12 and T18 ($P < 0.001$) CMT was also significantly lower than T0 although a trend to return to the baseline conditions was also observed.

• **CONCLUSION:** Our findings demonstrate that Intravitreal Dexamethasone Implant is a good option to improve

BCVA and CMT in DME patients resistant to anti-VEGF therapy. Our data also show that the use of drugs administered directly into the vitreous allows achieving appropriate and long-lasting concentration at the site of disease without systemic side effects.

• **KEYWORDS:** diabetic macular edema; Intravitreal Dexamethasone Implant; anti-vascular endothelial growth factor therapy

DOI:10.18240/ijo.2016.10.10

Pacella F, Romano MR, Turchetti P, Tarquini G, Carnovale A, Mollicone A, Mastromatteo A, Pacella E. An eighteen-month follow-up study on the effects of Intravitreal Dexamethasone Implant in diabetic macular edema refractory to anti-VEGF therapy. *Int J Ophthalmol* 2016;9(10):1427-1432

INTRODUCTION

Diabetic macular edema (DME) is one of the leading causes of visual loss in diabetes [1]. DME represents the first change occurring in the retina, leading to reduced visual acuity and breakdown of the blood-retinal barrier [2]. Increased glucose levels can induce numerous biochemical and metabolic changes contributing to endothelial dysfunction, inflammatory processes and increased trans-vascular passage of macromolecules [3-4]. All these factors contribute to disruption of the blood-retinal barrier, accumulation of free radicals, activation of vascular endothelial growth factor (VEGF) pathway in endothelial intercellular junctions, pericyte loss, and retinal vessel leukostasis [5-7].

To date, the goals of local eye treatment are the diminution of macular edema, to stop the disease progression and, possibly, to improve the vision. Intravitreal injections of anti-VEGF agents is the current treatment of choice in DME [7-8]. Other therapeutic options are vitrectomy, protein kinase C (PKC) inhibitors and steroids [7,9-11].

Dexamethasone is one of the most potent glucocorticoid available in ophthalmology [12]. It exerts anti-inflammatory, anti-angiogenic, anti-edematous and anti-proliferative effects by influencing several signal transduction pathways [13]. Dexamethasone stabilizes the blood-retinal barrier via modulation of proteins involved in VEGF receptor downstream pathway [14]. Previous study [15] has shown that

intravitreal injection of dexamethasone improves DME by inhibiting leukostasis and decreasing synthesis and expression of intracellular adhesion molecule-1 (ICAM-1). Moreover, it has been shown that activation of glucocorticoid receptor may protect the retinal photoreceptors through an anti-apoptotic action^[16].

The dexamethasone implant (Ozurdex, Allergan Inc., Irvine, CA, USA) is a new therapeutic approach approved in Italy for the intravitreal treatment of macular edema after vascular retinal occlusions^[17]. Due to its progressively biodegradable form of lactic and glycolic acid copolymers, it is found in good concentrations in the vitreous chamber for a period of up to 180d after a single injection^[18-19].

One study has shown that Intravitreal Dexamethasone Implant is efficient in patients with recalcitrant macular edema secondary to retinal vein occlusion^[20]. In addition, data on the long term efficacy and safety of dexamethasone implant in DME have been provided in the study of Haller *et al*^[21] and, more recently, in that of Mastropasqua *et al*^[22].

In order to confirm these data and provide further evidence for the use of dexamethasone in DME, in this study we evaluated the efficacy and safety of dexamethasone implant injections in patients affected by DME resistant to anti-VEGF therapy (loading phase), as ascertained by optical coherence tomography (OCT) showing no signs of improvements in central macular thickness (CMT) and best-corrected visual acuity (BCVA).

SUBJECTS AND METHODS

Subjects From 4/2014 to 9/2015, thirty-two type 2 diabetic patients (32 eyes) were enrolled in this retrospective study. Demographic data of the patients, duration of DME and type 2 diabetes are reported in Table 1. The presence of macular ischemia was evaluated at baseline with fluorescein angiography. Evaluation of the integrity of external limiting membrane (ELM) and ellipsoid zone (EZ) of the photoreceptor interface was performed by OCT at baseline, 6, 12 and 18mo after dexamethasone treatment.

The study was approved by the Ethics Committee of the University of Rome "La Sapienza" and was performed in accordance with the ethical standards of the Declaration of Helsinki. A written informed consent was obtained from each patient.

All patients underwent general preoperative anamnesis, and blood tests including glycosilated Hb (HbA1c). All patients gave their informed consent to the injection and were followed for 18mo.

Treatment All recruited patients had previously undergone a cycle of treatment (loading phase of three monthly intravitreal injections) with anti-VEGF: sixteen with bevacizumab (Avastin[®]; Genentech, Inc., South San Francisco, CA, USA), thirteen with ranibizumab (Lucentis[®]; Genentech, Inc., South San Francisco, CA, USA) and three

Table 1 Demographic and clinical features of subjects with persistent DME

Demographic and clinical features	Average
Age (a)	66.34±9.35
Gender	23M/9F
Eyes (n)	32
Duration of type 2 diabetes (a)	18.12±6.49
Duration of DME (mo)	41.94±18.39

DME: Diabetic macular edema. Data are expressed as mean±standard deviation.

with pegaptanib (Macugen[®]; Eyetech Pharmaceuticals, Inc., New York, NY, USA). No combination of these therapies were given.

Resistance to anti-VEGF therapy was determined by clinical parameters and OCT data. In absence of improvements of central macular thickness (CMT) and BCVA values after the loading phase of anti-VEGF treatment, the patient was classified as resistant to therapy. All intravitreal therapies were suspended 3mo before the beginning of the study.

During the study period, none of the patients received additional therapy, except for a prophylactic antibiotic therapy (6d) starting 1d before the intravitreal dexamethasone injection.

Inclusion Criteria Criteria for inclusion were: age (18y; persistent DME; BCVA between 5 [corresponding to 1/10, logarithm of the minimum angle of resolution (logMAR) 1.0 or more] and 40 (corresponding to 5/10, logMAR 0.3 or less) letters; macular edema with thickness (285 µm measured by spectral domain HRA-OCT with a volumetric 512×49-scan (Heidelberg Engineering, Germany) system. The mean BCVA at T0 was 16.54±10.85 letters and CMT was 521.8±174.5 µm.

Evaluations Baseline vision evaluation was carried out pre-therapy at T0. Fluorangiography (FAG) evaluated the presence of macular ischemia, while BCVA was measured with Early Treatment Diabetic Retinopathy Study (ETDRS) tables placed at a distance of 4 m. Slit lamp biomicroscopy evaluated the lens opacity. Ocular tonometry (using a Goldman applanation tonometer) was used to determine the intraocular pressure (IOP). Fundus biomicroscopy and color fundus photography were utilized to evaluate the objective state of the retina. OCT was used for measurement of macular thickness and morphology using a Spectralis HRA-OCT produced by Heidelberg Engineering with a volumetric 512×49-scan.

BCVA and CMT exams were carried out at baseline (T0) and after 1 (T1), 3 (T3), 4 (T4), 6 (T6), 9 (T9), 12 (T12), 15 (T15), and 18mo (T18) post injection.

Efficacy Criteria Primary outcome measures included mean BCVA and CMT values at baseline and at all follow-up visits. The implant was considered efficient when a mean improvement of BCVA ≥10 letters (2 lines) ETDRS was observed.

Secondary outcomes were the analysis of the retinal layer structure using OCT. The outcomes expected were: a reduction of CMT $\geq 250 \mu\text{m}$. The evaluation of the integrity of ELM and EZ of the photoreceptor interface was carried out at baseline, 6, 12 and 18mo.

Intravitreal Dexamethasone Implant All implants were performed under sterile conditions. Povidone-iodine solution (5%) and topical anesthetic (ropivacaine) were used to prepare the conjunctiva and the blepharostat was positioned.

A 700 microgram Intravitreal Dexamethasone Implant (Ozurdex[®]) at slow release was placed in the vitreal cavity, behind the crystalline lens [11-14,23]. A topical ophthalmic antibiotic was administered for 7d after treatment.

Local or systemic side effects caused by the implant were monitored for the entire study time.

Safety Criteria The insurgence of undesired side-effects correlated to the drug (*i.e.* inflammation of the anterior chamber; ocular pain; keratitis or vitreous opacity; increase in IOP and insurgence of cataract) was monitored monthly.

Side effects correlated to the surgical intervention (*i.e.* endophthalmitis; perforation of the eye; conjunctival hemorrhage and systemic effects related to the drug) were also monitored monthly.

Re-injection Criteria Patients showing a worsening of clinical/functional condition (a reduction of at least 0.2 or 10 letters or an increase of macular thickness of at least $150 \mu\text{m}$) after 4mo were recommended for a retreatment.

Statistical Analysis Data were analyzed by repeated measures ANOVA. Posthoc analyses were performed with Fisher's protected least significant difference. The significance level was set at a P -value <0.05 . StatView software from SAS Institute was used.

RESULTS

Number of Dexamethasone Injections Performed During the Follow-up Period In all patients, we observed that the BCVA and CMT values tended to return to baseline levels after 6mo from injection. Thus, according to the re-injection criteria defined above, all patients underwent a reinjection of dexamethasone implant during each semester of the follow-up. Thus, all patients received a total of four dexamethasone injections during the time of the study: at baseline (T0), 6 (T6), 12 (T12) and 18mo (T18).

Visual Acuity Measured with Early Treatment Diabetic Retinopathy Scale The BCVA was measured using the ETDRS. The response to treatment was evaluated independently of sex, age, and comorbidities.

ANOVA showed a significant effect of the treatment on ETDRS ($P < 0.0001$) (Figure 1). Post hoc analyses revealed that ETDRS values were significantly increased at T1, T3, T4, T9, and T15 ($P < 0.001$) as compared to baseline value (T0). At T6, T12, and T18, ETDRS values were still

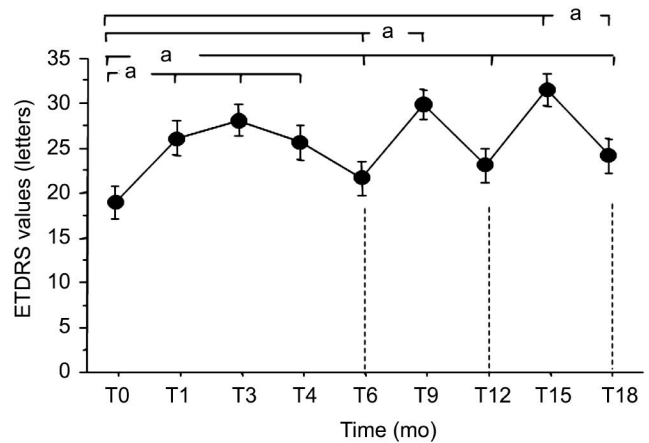


Figure 1 ETDRS in patients affected by persistent DME and treated with Intravitreal Dexamethasone Implant (Ozurdex[®]) over 18mo. Data are the mean \pm SEM. Data are expressed in letters (ETDRS values). ^a $P < 0.001$.

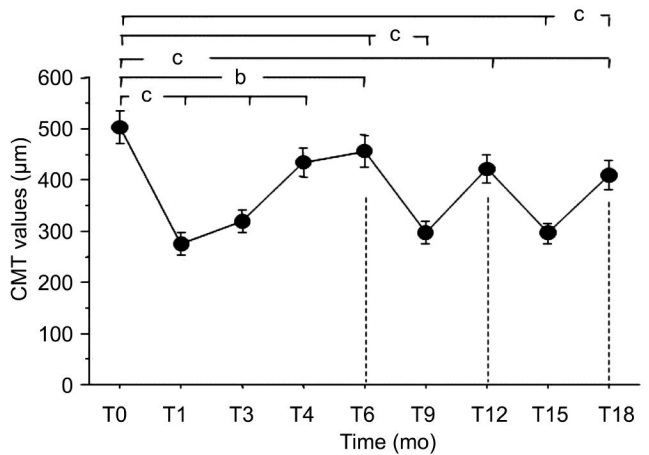


Figure 2 CMT in patients affected by persistent DME and treated with Intravitreal Dexamethasone Implant (Ozurdex[®]) over 18mo. Data are the mean \pm SEM. Values are expressed in μm . ^b $P < 0.01$; ^c $P < 0.001$.

statistically higher than baseline ($P < 0.001$ vs T0). However, at these time points, we observed a trend to return to baseline conditions (Figure 1).

Central Macular Thickness As for ETDRS values, repeated measures ANOVA also showed a significant effect of Intravitreal Dexamethasone Implant ($P < 0.0001$) (Figure 2). CMT decreased significantly at T1, T3, T4, T9, and T15 ($P < 0.001$). At T6 ($P < 0.01$), T12 and T18 ($P < 0.001$) CMT was also significantly lower than T0 although a trend to return to the baseline conditions was also observed.

Complications None of the patients had uncontrolled hypertension, hyperlipidemia, renal disease, or other comorbidities at admission and in the successive follow-up. The IOP values registered during the 18mo of follow-up did not show significant increments. In 5 patients, IOP was higher than 21 mm Hg, and this condition was successfully treated with beta-blocker drugs.

Twenty-six patients were pseudophakic. The remaining 6 patients did not show lens opacities at baseline. At the end of

follow up, these patients showed a nuclear cataract grade 1 and cortical grade 1.

Optical Coherence Tomography Evaluation The evaluation of the integrity of ELM and EZ of the photoreceptor interface, carried out at baseline, 6, 12 and 18mo, did not reveal alterations due to the dexamethasone implant.

DISCUSSION

This study was performed to investigate the efficacy and safety of Intravitreal Dexamethasone Implant (Ozurdex®) over time in patients affected by persistent DME.

The results, as previously reported^[24], showed that Intravitreal Dexamethasone Implant induced an improvement in BCVA, and CMT values with an effect lasting 6mo. In addition, we found that BCVA and CMT values did not return to the baseline conditions during 18mo follow-up.

This study indicates that the Intravitreal Dexamethasone Implant is both efficient and safe not only for the treatment of secondary macular edema produced by branch retinal vein occlusion (BRVO) and central retinal vein occlusion (CRVO)^[19-20], but also for secondary macular edema after diabetic retinopathy^[22]. In patients with persistent DME, important functional (BCVA) and morphologic (CMT) improvement of the retina in the treated eye were observed. Our data suggest that the maximum effects of the dexamethasone implant occur at 3mo and slowly decrease from month 4 to 6. This finding is in line with previous studies showing that the improvement of visual parameters already starts from day three of the intravitreal implant and decreases over time^[25-28]. Our results also showed a similar clinical course after the second and the third dexamethasone reinjection, although at the end of the follow-up the BCVA and CMT values were improved persistently when compared to the baseline values. This cyclic trend may be due to a reduced release of the drug over time. Thus, one can hypothesize that the gradual decrease of the efficacy may be due to reduced concentrations of dexamethasone in the vitreous. Alternatively, it is possible that the chronic nature of this illness may limit the efficacy of the implant over time. Other studies are necessary to elucidate this mechanisms^[29].

Nonetheless, despite this effect, our data support the notion that intravitreal corticosteroids may represent an effective treatment for DME, not only to prevent visual loss, but also to recover of visual acuity^[18,30]. These agents have anti-inflammatory and anti-angiogenic properties stabilizing the inner blood-retina barrier and act on all inflammatory mediators. Corticosteroids modulate their effects by interacting with specific nuclear steroid-hormone-receptors. These receptors mainly reside in the cytoplasm in an inactive form until steroid binding, receptor activation and translocation to the nucleus^[31]. Although corticosteroids

predominantly act by increasing gene transcription, there are well-documented examples showing that glucocorticoids decrease gene transcription^[7]. Previous study^[6] has shown that intravitreal injection of dexamethasone improves DME by inhibiting leukostasis and decreasing synthesis and expression of ICAM-1. In addition, corticosteroids may exert some of their immediate effects by non-genomic mechanisms^[32]. Moreover, it has been shown that activation of glucocorticoid receptor protects the retinal photoreceptors and has anti-apoptotic action^[33].

The greater efficacy of dexamethasone in DME patients resistant to anti-VEGF therapy may be due to the characteristic of the implant that, unlike anti-VEGFs, allows a stable release of 0.7 mg of preservative-free dexamethasone into the vitreal chamber^[19,21,25,27]. The administration route is essential for the therapeutic efficacy of steroids. In fact, oral steroid administration may cause systemic side effects and, above all, the concentration of steroid in the vitreous is very low^[14]. Instead, the use of drugs administered directly into the vitreous allows achieving appropriate concentration at the site of disease, with minor systemic side effects^[5,34].

Interestingly we observed that repeated injections of dexamethasone did not induce serious side effects, a finding in line with other studies^[17,19,22,27-28,35]. None of our patients had uncontrolled hypertension, hyperlipidemia, renal disease, or other comorbidities during the follow-up period. An increase in IOP that occurred in 15% ($n=5$) of patients was easily handled with an antiglaucomatous mono-therapy. Dexamethasone implant has also lower incidence of cataract and glaucoma than other steroids^[17].

In conclusion, our findings demonstrate that Intravitreal Dexamethasone Implant (0.7 mg) improves BCVA and has a safety profile consistent with previous data^[20,36] in DME patients resistant to anti-VEGF therapy. Our data also show that the use of drugs administered directly into the vitreous allows achieving appropriate and long-lasting concentration at the site of disease without systemic side effects, with the final aim to improve therapeutic response and reduce the rate for re-treatment. The use of steroids in DME patients represents an alternative therapeutic strategy in cases where other therapies (laser or anti-VEGF) have failed^[24,37-39]. Nonetheless, other studies are necessary to confirm these data.

ACKNOWLEDGEMENTS

Conflicts of Interest: Pacella F, None; Romano MR, None; Turchetti P, None; Tarquini G, None; Carnovale A, None; Mollicone A, None; Mastromatteo A, None; Pacella E, None.

REFERENCES

1 Patelli F, Radice P, Giacomotti E. Diabetic macular edema. *Dev Ophthalmol* 2014;54:164–173.

- 2 Zhang C, Wang H, Nie J, Wang F. Protective factors in diabetic retinopathy: focus on blood-retinal barrier. *Discov Med* 2014;18 (98): 105-112.
- 3 Zandbergen AA, Vogt L, de Zeeuw D, Lamberts SW, Ouwendijk RJ, Baggen MG, Bootsma AH. Change in albuminuria is predictive of cardiovascular outcome in normotensive patients with type 2 diabetes and microalbuminuria. *Diabetes Care* 2007;30(12):3119-3121.
- 4 Sørensen VR, Mathiesen ER, Watt T, Bjørner JB, Andersen MV, Feldt-Rasmussen B. Diabetic patients treated with dialysis: complications and quality of life. *Diabetologia* 2007;50(11):2254-2262.
- 5 Bhagat N, Grigorian RA, Tutela A, Zarbin MA. Diabetic macular edema: pathogenesis and treatment. *Surv Ophthalmol* 2009;54(1):1-32.
- 6 Funatsu H, Yamashita H, Noma H, Mimura T, Yamashita T, Hori S. Increased levels of vascular endothelial growth factor and interleukin-6 in the aqueous humor of diabetics with macular edema. *Am J Ophthalmol* 2002;133(1):70-77.
- 7 Noma H, Funatsu H, Mimura T, Harino S, Hori S. Vitreous levels of interleukin-6 and vascular endothelial growth factor in macular edema with central retinal vein occlusion. *Ophthalmology* 2009;116(1):87-93.
- 8 Agarwal A, Afridi R, Hassan M, Sadiq MA, Sepah YJ, Do DV, Nguyen QD. Novel therapies in development for diabetic macular edema. *Curr Diab Rep* 2015;15(10):75.
- 9 Adelman R, Parnes A, Michalewska Z, Parolini B, Boscher C, Ducournau D. Strategy for the management of diabetic macular edema: the European vitreo-retinal society macular edema study. *Biomed Res Int* 2015;2015: 352487.
- 10 Owen LA, Hartnett ME. Soluble mediators of diabetic macular edema: the diagnostic role of aqueous VEGF and cytokine levels in diabetic macular edema. *Curr Diab Rep* 2013;13(4):476-480.
- 11 Bandello F, Preziosa C, Querques G, Lattanzio R. Update of intravitreal steroids for the treatment of diabetic macular edema. *Ophthalmic Res* 2014;52(2):89-96.
- 12 Saraiya NV, Goldstein DA. Dexamethasone for ocular inflammation. *Expert Opin Pharmacother* 2011;12(7):1127-1131.
- 13 Bhagat R, Zhang J, Farooq S, Li XY. Comparison of the release profile and pharmacokinetics of intact and fragmented dexamethasone intravitreal implants in rabbit eyes. *J Ocul Pharmacol Ther* 2014;30(10):854-858.
- 14 Kim H, Lee JM, Park JS, Jo SA, Kim YO, Kim CW, Jo I. Dexamethasone coordinately regulates angiopoietin-1 and VEGF: a mechanism of glucocorticoid-induced stabilization of blood-brain barrier. *Biochem Biophys Res Commun* 2008;372(1):243-248.
- 15 Tamura H, Miyamoto K, Kiryu J, Miyahara S, Katsuta H, Hirose F, Musashi K, Yoshimura N. Intravitreal injection of corticosteroid attenuates leukostasis and vascular leakage in experimental diabetic retina. *Invest Ophthalmol Vis Sci* 2005;46(4):1440-1444.
- 16 Edelman JL. Differentiating intraocular glucocorticoids. *Ophthalmologica* 2010;224(Suppl 1):25-30.
- 17 Haller JA, Bandello F, Belfort R Jr, Blumenkranz MS, Gillies M, Heier J, Loewenstein A, Yoon YH, Jacques ML, Jiao J, Li XY, Whitcup SM; OZURDEX GENEVA Study Group. Randomized, sham-controlled trial of dexamethasone intravitreal implant in patients with macular edema due to retinal vein occlusion. *Ophthalmology* 2010;117(6):1134-1146.
- 18 Stewart MW. Corticosteroid use for diabetic macular edema: old fad or new trend? *Curr Diab Rep* 2012;12(4):364-375.
- 19 Sorokin N, Loewenstein A, Habot-Wilner Z, Goldstein M. Intravitreal Dexamethasone Implant in patients with persistent macular edema of variable etiologies. *Ophthalmologica* 2014;232(2):83-91.
- 20 Sharareh B, Gallemore R, Taban M, Onishi S, Wallsh J. Recalcitrant macular edema after intravitreal bevacizumab is responsive to an Intravitreal Dexamethasone Implant in retinal vein occlusion. *Retina* 2013; 33(6):1227-1231.
- 21 Haller JA, Kuppermann BD, Blumenkranz MS, Williams GA, Weinberg DV, Chou C, Whitcup SM; Dexamethasone DDS Phase II Study Group. Randomized controlled trial of an intravitreal dexamethasone drug delivery system in patients with diabetic macular edema. *Arch Ophthalmol* 2010;128(3):289-296.
- 22 Mastropasqua R, Toto L, Borrelli E, Di Antonio L, De Nicola C, Mastrocola A, Di Nicola M, Carpineto P. Morphology and function over a one-year follow up period after Intravitreal Dexamethasone Implant (Ozurdex) in patients with diabetic macular edema. *PLoS One* 2015;10(12): e0145663.
- 23 Pacella F, Ferraresi AF, Turchetti P, Lenzi T, Giustolisi R, Bottone A, Fameli V, Romano MR, Pacella E. Intravitreal injection of Ozurdex (®) implant in patients with persistent diabetic macular edema, with six-month follow-up. *Ophthalmol Eye Dis* 2016;8:11-16.
- 24 Lazic R, Lukic M, Boras I, Draca N, Vlastic M, Gabric N, Tomic Z. Treatment of anti-vascular endothelial growth factor-resistant diabetic macular edema with dexamethasone intravitreal implant. *Retina* 2014;34 (4):719-724.
- 25 Querques G, Lattanzio R, Querques L, Triolo G, Cascavilla ML, Cavallero E, Del Turco C, Casalino G, Bandello F. Impact of Intravitreal Dexamethasone Implant (Ozurdex) on macular morphology and function. *Retina* 2014;34(2):330-341.
- 26 Rishi P, Rishi E, Kuniyal L, Mathur G. Short-term results of Intravitreal Dexamethasone Implant (OZURDEX®) in the treatment of recalcitrant diabetic macular edema: a case series. *Oman J Ophthalmol* 2012;5 (2): 79-82.
- 27 Pacella E, Vestri AR, Muscella R, Carbotti MR, Castellucci M, Coi L, Turchetti P, Pacella F. Preliminary results of an Intravitreal Dexamethasone Implant (Ozurdex) in patients with persistent diabetic macular edema. *Clin Ophthalmol* 2013;7:1423-1428.
- 28 Zalewski D, Raczyńska D, Raczyńska K. Five-month observation of persistent diabetic macular edema after intravitreal injection of Ozurdex implant. *Mediators Inflamm* 2014;2014:364143.
- 29 Pacella E, La Torre G, Turchetti P, Merisola C, Lenzi T, Mazzeo F, Lucchetti P, Casale S, Pacella F. Evaluation of efficacy dexamethasone intravitreal implant compared to treatment with anti-VEGF in the treatment of diabetic macular edema. *Senses Sci* 2014;1:164-168.
- 30 Gillies MC, Simpson JM, Gaston C, Hunt G, Ali H, Zhu M, Sutter F. Five-year results of a randomized trial with open-label extension of triamcinolone acetonide for refractory diabetic macular edema. *Ophthalmology* 2009;116(11):2182-2187.
- 31 Campochiaro PA, Brown DM, Pearson A, Ciulla T, Boyer D, Holz FG, Tolentino M, Gupta A, Duarte L, Madreperla S, Gonder J, Kapik B, Billman K, Kane FE; FAME Study Group. Long-term benefit of sustained-delivery fluocinolone acetonide vitreous inserts for diabetic macular edema. *Ophthalmology* 2011;118(4):626-635.
- 32 Stahn C, Buttgerit F. Genomic and nongenomic effects of glucocorticoids. *Nat Clin Pract Rheumatol* 2008;4(10):525-533.
- 33 Campochiaro PA, Brown DM, Pearson A, Chen S, Boyer D, Ruiz-Moreno J, Garretson B, Gupta A, Hariprasad SM, Bailey C, Reichel E, Soubrane G, Kapik B, Billman K, Kane FE, Green K; FAME Study Group. Sustained delivery fluocinolone acetonide vitreous inserts provide benefit for at least 3 years in patients with diabetic macular edema. *Ophthalmology* 2012;119(10):2125-2132.

Intravitreal dexamethasone in DME for 18mo

- 34 Bandello F, Battaglia Parodi M, Tremolada G, Lattanzio R, De Benedetto U, Iacono P. Steroids as part of combination treatment: the future for the management of macular edema? *Ophthalmologica* 2010;224 (suppl 1): 41–45.
- 35 Kuppermann BD, Blumenkranz MS, Haller JA, Williams GA, Weinberg DV, Chou C, Whitcup SM; Dexamethasone DDS Phase II Study Group. Randomized controlled study of an intravitreal dexamethasone drug delivery system in patients with persistent macular edema. *Arch Ophthalmol* 2007;125(3):309–317.
- 36 Boyer DS, Yoon YH, Belfort R Jr, Bandello F, Maturi RK, Augustin AJ, Li XY, Cui H, Hashad Y, Whitcup SM; Ozurdex MEAD Study Group. Three-year, randomized, sham-controlled trial of dexamethasone intravitreal implant in patients with diabetic macular edema. *Ophthalmology* 2014;121(10):1904–1914.
- 37 Bandello F, Zarbin MA, Lattanzio R, Zucchiatti I. *Clinical strategies in the management of diabetic retinopathy: a step-by-step guide for ophthalmologists*. Berlin: Springer; 2013.
- 38 Panozzo G, Gusson E, Panozzo G, Dalla Mura G. Dexamethasone intravitreal implant for diabetic macular edema. indications for a PRN regimen of treatment. *Eur J Ophthalmol* 2015;25(4):347–351.
- 39 Querques G, Darvizeh F, Querques L, Capuano V, Bandello F, Souied EH. Assessment of the real-life usage of intravitreal dexamethasone implant in the treatment of chronic diabetic macular edema in France. *J Ocul Pharmacol Ther* 2016;32(6):383–389.