

*Jurnal Sains Kesihatan Malaysia* 15(2) 2017: 121-125  
DOI : <http://dx.doi.org/10.17576/JSKM-2017-1502-17>

### Artikel Asli/Original Articles

## Feasibility Accuracy of Three-Dimensional Echocardiography Colour Flow Measurement on Duct Pulmonary Dependent Circulation (Ketepatan Kebolehlaksanaan Pengiraan Aliran Warna Tiga-Dimensi Ekokardiografi dalam Salur Bergantung Pengaliran Pulmonari)

ABDUL MUHAIMIN, MAZLYFARINA MOHAMAD, HAIFA ABDUL LATIF & MAZENI ALWI

#### ABSTRACT

*The assessment for patient with duct-dependent pulmonary circulation (DDPC) during the inter-stage intervals before first stage palliation commonly includes imaging of the heart with multiple imaging modalities. Recently, three-dimensional echocardiography (3DE) was found with the ability to delineate cardiac structure that is able to do 360° rotation. Therefore, this study aimed at identifying the accuracy of 3DE colour flow in measuring PDA size compared to computer tomography angiography (CTA). This study involves randomly selected 26 patients with DDPC undergoing CTA for palliation treatment in one year. The mean patient age is  $1.6 \pm 0.261$  months with mean weight of  $3.65 \pm 0.82$  kg. The full-volume 3DE colour flow acquisition was performed and analysed offline using Q-lab software. The PDA diameters at the origin as well as the insertion site were measured. The data obtained by 3DE colour flow data were compared to the CTA, which was taken as the gold standard. Results showed that the offline analysis of PDA size was feasible in all patients (100%) with the mean diameter of PDA at the origin on 3DE colour flow and CTA of  $0.51 \text{ mm} \pm 0.14$  and  $0.52 \text{ mm} \pm 0.11$ , respectively ( $p = 0.92$ ). The PDA diameter at insertion site on 3DE colour flow and CTA was  $0.29 \text{ mm} \pm 0.08$  and  $0.27 \text{ mm} \pm 0.97$  respectively ( $p = 0.5$ ). Meanwhile, the measurement of 3DE colour flow is comparable to CTA in measurement PDA size. However, the use of 3DE colour flow in infants with rapid heart rate is yet challenging to 3DE colour flow acquisitions.*

*Keywords: Duct dependent pulmonary circulation; patent ductus arteriosus; three-dimensional colour flow echocardiography; computer tomography; angiography*

#### ABSTRACT

*Penilaian untuk pesakit salur bergantung pengaliran pulmonari (DDPC) semasa selang fasa sebelum fasa paliatif pertama biasanya melibatkan pengimejan jantung dengan pelbagai modaliti pengimejan. Terbaru, tiga dimensi ekokardiografi (3DE) telah dikenal pasti mempunyai kelebihan untuk menggariskan struktur jantung di mana boleh berputar 360°. Oleh demikian itu, kajian ini bertujuan mengenal pasti ketepatan aliran warna 3DE dalam mengukur saiz PDA dibandingkan dengan tomografi berkomputer angiografi (CTA). Kajian ini melibatkan 26 pesakit DDPC dipilih secara rawak yang menjalani CTA untuk rawatan paliatif dalam masa setahun. Min umur pesakit adalah  $1.6 \pm 0.261$  bulan dengan berat pesakit min  $3.65 \pm 0.82$  kg. Pemerolehan isi padu penuh aliran warna 3DE telah dilakukan dan analisis secara luar talian dengan menggunakan perisian Q-lab. Diameter PDA di kawasan asalan serta kawasan kemasukan diambil kira. Data aliran warna 3DE akan dibandingkan dengan CTA yang dianggap sebagai penanda aras. Hasil kajian menunjukkan analisis luar talian saiz PDA boleh dilaksanakan dalam semua pesakit (100%) dengan min diameter PDA kawasan asalan pada aliran warna 3DE dan CTA adalah  $0.51 \text{ mm} \pm 0.14$  dan  $0.52 \text{ mm} \pm 0.11$  masing-masing ( $p = 0.92$ ). PDA diameter kawasan kemasukan pada aliran warna 3DE and CTA adalah  $0.29 \text{ mm} \pm 0.08$  dan  $0.27 \text{ mm} \pm 0.97$  masing-masing ( $p = 0.5$ ). Sementara itu, pengiraan aliran warna 3DE adalah sebanding dengan CTA dalam pengiraan saiz PDA. Walau bagaimanapun, penggunaan aliran warna 3DE dalam bayi dengan kadar denyutan jantung yang laju adalah cabaran kepada pemerolehan aliran warna 3DE.*

*Kata kunci: Salur bergantung peredaran pulmonari; duktus arteriosus terbuka; ekokardiografi aliran warna tiga-dimensi; tomografi berkomputer; angiografi*

#### INTRODUCTION

Cyanotic congenital heart disease (CHCD) with present duct-dependent pulmonary circulation (DDPC) is a life-threatening emergency born normally at birth. Its

circulation is maintained through flow in patent ductus arteriosus (PDA). Patients with this disease survive through maintained duct patency before they can proceed to staged cardiac repair. Early intervention in patients is often required including Blalock–Taussig (BT) shunt

operation for first stage palliation procedure. However, surgical interventions at the early stage of life have been found to be associated with significant mortality and morbidity in neonates (Sivakumar et al. 2001; Mazeni et al. 2004). Stenting of PDA was seen as an alternative palliation for maintaining pulmonary circulation, which is less invasive for the first stage palliation (Mazeni 2008; Hussain et al. 2008). The approach and outcome for ductal stenting are basically based on size, length, tortuosity, ductal morphology, how ductal arises from the aorta and its insertion into the pulmonary artery (PA). The evaluation of PDA morphology is standardised using two-dimensional (2D) angiography image. However, the accuracy measurement of the whole PDA with complex tortuosity on angiography is difficult, thus leading to the underestimation of PDA length. Computer Tomography Angiography (CTA) scan has been proposed to delineate PDA morphology in pulmonary duct dependent lesions to assess its suitability in PDA stenting (Ying et al. 2010). Its function is to rotate 360° operator to delineate the PDA tortuosity without overlapping of aortic image. However, the use of contrast and radiation in CTA towards infant may cause harmful effects.

Recently, three-dimensional echocardiography (3DE) has been introduced as an advance ultrasound imaging modality for congenital cardiac anomalies. In 3DE application software, multiplanar review mode (MPR) allows the operator to view the 3DE data set simultaneously in three orthogonal windows and to review the image in infinite planes by moving each of the three planes through the data set. This imaging modality has been shown to add valuable information as a part of comprehensive echocardiographic imaging modality including colour flow imaging in several previous studies (Soriano et al. 2008; Seliem et al. 2006; Nii et al. 2006). With this advance imaging technique, it might be possible to define accuracy of 3DE colour flow in determining PDA size by comparing it with CTA from this study.

## MATERIALS AND METHODS

This study was approved by National Heart Institute of Malaysia (IJN) review board and informed consent was obtained from the parent of all the infants enrolled in the study. Between January 2014 and December 2014, 26 consecutive patients with DDPC who underwent CTA and potential candidates for first stage palliation were randomly selected. The inclusion criteria for 3DE colour flow are as follow: (1) neonate with DDPC, (2) duration time delay between CTA with 3DE colour flow within 24 hours, (3) neonate in intubation setting (deep sedation) during 3DE colour flow study. The CTA finding report was blinded from 3DE colour flow study and operator.

## FULL VOLUME OF THREE DIMENSIONAL ECHOCARDIOGRAPHY (3DE) COLOUR FLOW

All patients under intubate setting have underwent full 3DE colour flow study using a pediatric matrix probe X7-2 with IE33 Philips machine and image acquisition is adjusted in accordance with the “Practical Guide for Three Dimensional Transthoracic Echocardiography” (Yang et al. 2008) by single operator. ECG gated colour acquisition is selected to assess the flow across PDA and into the pulmonary artery. Generally, the 3DE colour flow acquisition stitches seven consecutive cycles. Thus, the colour gain and version setting are changed to allow the best display and most flexible post-processing manipulation. The PDA flow is acquired from the suprasternal long-axis view together with aortic arch flow or from infraclavicular view (Figure 1). Raw data are analysed by offline Q-LAB and measurement of PDA size is calculated by MPR mode as shown in Figure 2.

## COMPUTER TOMOGRAM ANGIOGRAPHY (CTA)

CTA is performed with 64-MDCT scanner (Siemens Somatom, Germany) and intravenous access is established by inserting a 22-gauge intravenous cannula into peripheral vein. The patients are sedated with oral chloral hydrate (50 mg/kg, maximal dose 2000 mg). The examination is done limited to the apex of lung until abdominal level. The scanning parameters comprised 80 kV tube voltage, tube current adjustment of 20 mAs, 0.1 pitch, 0.4 second scanner rotation, 1 mm slice thickness, 0.7 mm reconstruction interval and field of view of 13 cm. Prior scanning, a care bolus is injected via mechanical power injector with rate of 0.7 ml/sec and nonionic iso-osmolar contrast material (iomeron, BRACCO) was given at a dosage of 3 ml/kg at the same rate and subsequent saline flushing. Automatic triggering is applied by putting a circular region of interest at the left ventricular apex with a threshold level of 100HU. After that, 6 seconds delay time of scanning from the apex of lung to abdominal is performed. The raw data were then immediately transferred to a workstation (Siemens Syngo CT, Germany) for post-processing (figure 3). CTA scan data are blinded to 3DE colour flow scanning and CTA scan data are verified by paediatric imaging cardiologist.

## STATISTICAL ANALYSIS

Data are coded and analysed using the SPSS programme version 21.0 (Statistical Package for Social Sciences). Qualitative data are presented related percentage, whereas quantitative data are presented using mean and standard deviation. The variables are evaluated using descriptive statistic. The data proceeded with parametric analysis statistic; paired T-test and P-value is chosen as the level of significance.

## RESULTS

This study involved 26 DDPC patients with the mean age of  $1.6 \pm 0.261$  months. The weight of patients ranged from 2.89 to 5.8 kg with a mean of  $3.65 \pm 0.82$  kg and the body surface of 0.18 to 0.3 m<sup>2</sup> with a mean of  $0.22 \pm 0.3$  m<sup>2</sup>.

Result from the 3DE colour flow Q lab analysis depicted that the PDA can be visualised and feasible in 26 patients (100%). The following measurements were obtained: The pulmonary end ranging from 0.19 to 0.52 cm with a mean of  $0.29 \pm 0.08$  cm and ampulla PDA ranging from 0.34 to 0.83 cm with a mean of  $0.52 \pm 0.11$  cm. Meanwhile, Result from CTA displayed the measurement of pulmonary end of duct that ranges from 0.10 – 0.5 cm (mean  $0.27 \pm 0.97$  cm) with ampulla PDA ranged from 0.37 to 0.9 cm (mean  $0.51 \pm 0.13$  cm). There are no significant differences between the pulmonary end and ampulla measured by 3DE colour flow and CTA using paired t-test (Table 1 and 2).

TABLE 1. The comparison between the pulmonary end measurement by 3DE color flow and CTA

	PDA pulmonary end/cm		Paired test	
	Range	Mean $\pm$ SD	<i>t</i>	<i>p</i>
CTA	0.10 – 0.5	$0.27 \pm 0.97$		
3DE color flow	0.19 – 0.52	$0.29 \pm 0.08$	0.67	0.50

TABLE 2. The comparison between the ampulla measurement by 3DE color flow and CTA

	PDA ampulla/cm		Paired test	
	Range	Mean $\pm$ SD	<i>t</i>	<i>p</i>
CTA	0.37 – 0.90	$0.51 \pm 0.14$		
3DE color flow	0.34 – 0.83	$0.52 \pm 0.11$	0.102	0.92

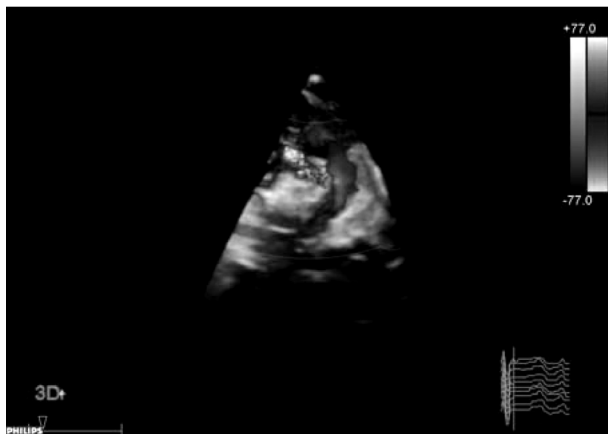

FIGURE 1. 3DE color flow acquisition from the suprasternal long-axis showing left aortic arch flow

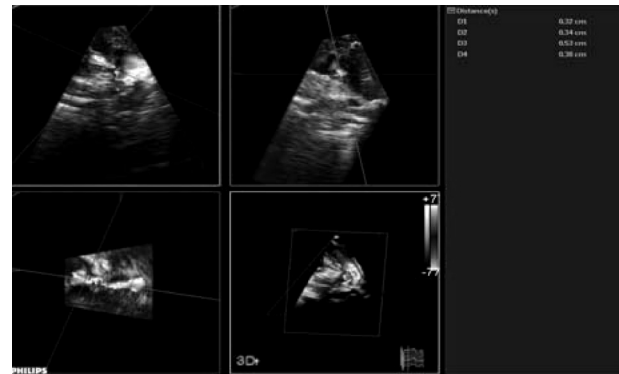

FIGURE 2. By using MPR mode: Right upper sector (sagittal view which measurement end pulmonary end PDA is taken), left upper sector showing PDA end pulmonary in ovule shape

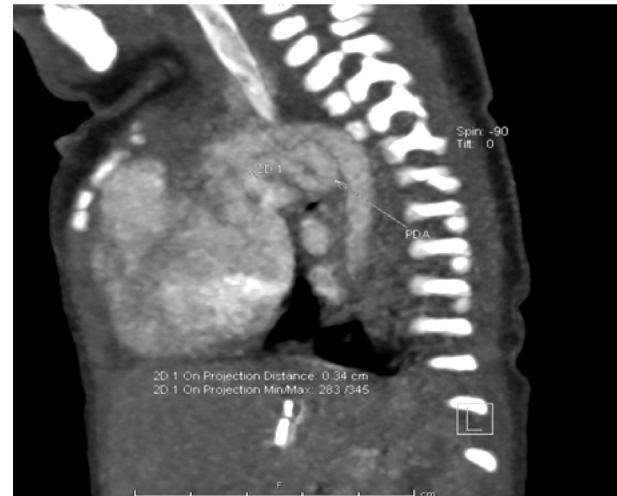


FIGURE 3. CTA: By using workstation (Siemens Syngo CT), the saggittal view is showing the end point measurement of end pulmonary PDA

## DISCUSSION

The evaluation of ultrasound development has recently improved two-dimensional ultrasound into three-dimensional ultrasound. Nonetheless, three-dimensional ultrasound is yet to be revolutionised at phase adaptation in clinical management. In congenital heart lesion, several studies on intra-cardiac shunt especially septal defect have documented the role of three-dimensional echocardiography in diagnosis assessment. The present study is designed to assess the role of 3DE colour flow in assessing extra cardiac structures especially the PDA size. The accurate assessment of the size, morphology, origin, associated branch pulmonary artery stenosis and insertion type is a crucial step towards choosing a suitable treatment without any significant complication in post outcome treatment. PDA morphology is usually evaluated using two dimensional angiography; however, the length

and tortuosity of PDA may be shortened by angiography due to superimposition of PDA with aorta (Ying et al. 2010).

In the present study, the data obtained for 3DE colour flow in determining the PDA size of DDPC patient are compared with CTA findings. Commonly, the PDA morphology is prone to tortuous morphology in patients with DDPC, which sometime unable to understand the morphology shape based on two dimensional image. The ability of 3D echocardiography to accurately view the anatomic details of PDA has been published by Vasquez et al. (2006). However, their study only included 11 patients from 21 patients for 3DE after percutaneous closure to assess the spatial relation of the studied device to surrounding anatomic structures. Furthermore, another recent 3DE studies in evaluating PDA have only involved patients with diagnosis PDA alone (Ahmed et al. 2014; Alaa et al. 2012) and were compared with angiography as gold standard. The measurement of end pulmonary PDA by 3DE in previous studies has shown significant overestimation of  $p < 0.05$  when compared with angiography. The finding on PDA size compared with angiography may have influenced the overlapping of aorta image showed in Ying et al. (2010) study, which stated that the measurement on length and tortuosity of PDA in DDPC may be shortened by angiography due to superimposition of PDA versus CTA compared with the outcome of PDA stenting. The CTA demonstrated the measurement of tortuous duct length, whereas the angiogram showed the partial obliteration due to overlapping aorta when CTA is rotated by 360° in offline system.

The analysis of the duct in this study is done using Q offline analysis, which include MPR mode and cropping and 3DE colour flow across the duct adequately visualised from suprasternal view. In Marasini et al. (2003) study has reported higher incidence of detection additional sub aortic abnormalities by MPR. MPR has additional benefit that allows the operator to check each plane against the other two plane being simultaneously viewed. This ensures that the operator never get lost in detection abnormalities in the dataset as each structure can be referenced in three different planes simultaneously. The MPR mode is used to measure the PDA pulmonary end and PDA ampulla. The shape of pulmonary end and ampulla of PDA is found with round or ovule shape. This rounded shape might explain why previous studies have shown significant overestimation in measurement when comparing 3DE with angiography. The pulmonary end PDA and ampulla PDA measurement are taken at sagittal view at MPR mode while the lumen of PDA is filled with colour flow. In previous study, two-dimensional echocardiography (2DE) colour doppler was found to significantly overestimate the minimum size of pulmonary end PDA in comparing angiography (Hamid et al., 2010). The angulation of single view 2DE PDA may influence the measurement such that shown by the study of Xiao et al. (2012) showing that the suprasternal view may be more accurate than other views. Beside the influence

of single view, the overlapping of aorta in angiography may contribute to the underestimation in measurement if PDA morphology is prone to tortuous shape (Ying et al. 2010). Nevertheless, the present study has shown that the measurement of end pulmonary PDA and ampulla PDA using 3DE colour flow is not significantly overestimated in comparing the measurement by CTA findings. This is because the 3DE colour flow has the ability to rotate 360°, which is similar to that of CTA that is able to measure size without overlapping image. Thus, 3DE is proved to have no influence, unlike that of geometry assumption in previous study, which stated that 3DE is able to visualise and analyse left ventricular volume (Lissa et al. 006)

## CONCLUSION

3DE colour flow was compared with CTA in determining PDA size, which offers an alternative mode of assessing PDA without exposure to radiation. Nevertheless, the use of 3DE colour flow in infants with rapid heart rate and fast respiration is still a challenge to 3DE colour flow acquisition.

## LIMITATION

In this study, sample size was too small since the frequency of patient diagnosis DDPC underwent CTA is low. This is because the CTA can give high radiation and contrast to infants, which may cause renal failure.

## ACKNOWLEDGEMENT

This work is supported by the National Heart of Institute (IJN). The authors are grateful to the children and parents for their commitment to the project. Not to be forgotten the IJN senior cardiac radiographer Abdul Arif Azri Abdul Rahman for helping in CTA methodology and IJN PCHC NCL deputy manager Hanif Osman for his aid in machine setting.

## REFERENCES

- Ahmed, Z., Darweish, Mohamed, E., Hazem, K. & Raghda, G.E. 2014. Comparative study between real time three dimensional echocardiogram and angiography in evaluation of patent ductus arteriosus, single center experience *Journal of the Saudi Heart Association* 26: 204–211.
- Alaa, R., Azza, E.F. & Dina, E.E.D. 2012. Visualization of patent ductus arteriosus using real-time three-dimensional echocardiogram: Comparative study with 2D echocardiogram and angiography. *Journal of the Saudi Heart Association* 24: 177–186.
- Hamid, A., Manochehr, S. & Siros, C. 2010. Estimation of patent ductus arteriosus diameter by colour doppler echocardiography in children. *Cardiology in the Young* 20: 648-653.



- Hussain, A., Zharani, S., Muhammed, A.A., Al-Ata, J. & Galal, O.M. 2008. Midterm outcome of stent dilatation of patent ductus arteriosus in ductal dependent pulmonary circulation. *Congenital Heart Disease* 3: 241-249.
- Lissa, S., Victor, M.A., Lynn, W., Johannes, N., Christian, E., Regina, S.M., Frank, S., Christian, G., Georg, S., Roberto, M.L. & Hans, J.N. 2006. Quantitative Assessment of Left Ventricular Size and Function Side-by-Side Comparison of Real-Time Three-Dimensional Echocardiography and Computed Tomography with Magnetic Resonance Reference. *Circulation* 114: 654-661.
- Mazeni A. 2008. Stenting the ductus arteriosus: case selection, technique and possible complications. *Annals of Paediatric Cardiology* 1(1): 38-45.
- Mazeni, A., K.K. Choo., Haifa, A.L., Geetha, K., Hasri, S. & Mulyadi. 2004. Initial result and medium term follow up of stent implantation of patent ductus arteriosus in duct dependent pulmonary circulation. *Journal of the American College of Cardiology* 44(2): 438-45.
- Marasini, M., Zannini, L., Ussia, G.P., Pinto, R., Moretti, R., Lerzo, F. & Pongiglione, G. 2003. Discrete subaortic stenosis: incidence, morphology and surgical impact of associated subaortic anomalies. *Annals of Thoracic Surgery* 75: 1763-1768
- Nii, M., Guerra, V., Roman, K.S., Macgowan, C.K. & Smallhorn, J.F. 2006. Three-dimensional tricuspid annular function provides insight into the mechanisms of tricuspid valve regurgitation in classic hypoplastic left heart syndrome. *Journal of the American Society of Echocardiography* 19: 391-402.
- Seliem, M., Fedec, A., Cohen, M., Ewing, S., Farrell, P., Rychik, J., Schutz, A., Gaynor, J. & Spray T. 2006. Real-time three-dimensional echocardiographic imaging of congenital heart disease using matrix-array technology: freehand real-time scanning adds instant morphologic details not well delineated by conventional 2-dimensional imaging. *Journal of the American Society of Echocardiography* 19: 121-129.
- Sivakumar, K., Shivaprakasha, K., Rao, S.G. & Krisha, K.R. 2001. Operative outcome and intermediate term follow up of neonatal Blalock-Taussig shunts. *Indian Heart Journal* 53: 66-70.
- Soriano, B.D., Hoch, M., Ithuralde, A., Geva T., Powell, A.J., Kussman, B.D., Graham, D.A., Tworetzky, W. & Marx G.R. 2008. Matrix-array 3-dimensional echocardiographic assessment of volumes, mass, and ejection fraction in young pediatric patients with a functional single ventricle: a comparison study with cardiac magnetic resonance. *Circulation* 117: 1842-8.
- Vazquez, A.C.A., Erdmenger, J.R. & Viesca, L.R. 2006. Three-dimensional (3D) echocardiography in evaluation of PDA before and after percutaneous closure. *European Journal of Echocardiography* 7 (Suppl.1): S146-147.
- Xiao, Y.Z., Tie, S.C., Li, J.Y., Jie, L. & Yun, Y.D. 2012. Value of the echocardiographic suprasternal view for diagnosis of patent ductus arteriosus subtypes. *Journal of Ultrasound in Medicine* 31: 1421-1427.
- Yang, H.S., Bansal, R.C., Mookadam, F., Khandheria, B.K., Tajik, A.J. & Chandrasekaran, K. 2008. Practical guide for three dimensional transthoracic echocardiography using a fully sampled matrix array transducer *Journal of the American Society of Echocardiography* 21: 979-989.
- Ying, J.L., Chi, D.L., Chih, Y.F., Hon, K.Y., Shu, H.N. & Sheung, F.K. 2010. Multidetector-row ct evaluation of tortuous ductus arteriosus for stent implantation in neonates with duct dependent pulmonary circulation: preliminary experience in 4 cases. *Acta Cardiologica Sinica* 26: 111-118.

Abdul Muhaimin  
Mazlyfarina Mohamad  
Diagnostic Imaging & Radiotherapy Program  
School of Diagnostic & Applied Health Sciences  
Faculty of Health Sciences  
Universiti Kebangsaan Malaysia  
50300 Jalan Raja Muda Abdul Aziz  
Kuala Lumpur

Abdul Muhaimin  
Haifa Abdul Latif  
Mazeni Alwi  
National Heart Institute of Malaysia (IJN)  
No 145 Jalan Tun Razak  
50400 Kuala Lumpur

Corresponding author: Mazlyfarina Mohamad  
Email: [mazlyfarina@ukm.edu.my](mailto:mazlyfarina@ukm.edu.my)

Tel: +603 9289 7293  
Fax: +603 2692 9032

Received: August 2016  
Accepted for publication: March 2017

