

Artikel Asli/Original Articles**Functional MRI Characteristics in Visual Cortex (BA 17, 18 and 19) Corresponding to the Visual Field of Normal, Glaucoma Suspect (GS) and Primary Open Angle Glaucoma (POAG) Patients**

(Ciri MRI Kefungsian dalam Korteks Visual (BA 17, 18 dan 19) yang Berpadanan dengan Medan Penglihatan bagi Subjek Normal, Disyaki Glaukoma (GS) dan Glaukoma Sudut Terbuka Primer (POAG))

NURUL HANIM NASARUDDIN, AHMAD NAZLIM YUSOFF & SHARANJEET-KAUR

ABSTRACT

The purpose of this study was to characterize, differentiate and correlate visual field and brain activation in visual cortex for normal, glaucoma suspect (GS) and primary open angle glaucoma (POAG) participants using Standard Automated Perimetry (SAP) and functional Magnetic Resonance Imaging (fMRI) respectively. The fMRI scans and SAP test were both carried out in Pusat Perubatan Universiti Kebangsaan Malaysia (PPUKM). Two types of black-and-white checkerboard pattern were displayed to the participants during the fMRI scans. The fMRI data were analyzed using WFU pickatlas toolbox targeting visual cortex area. The results showed that there was no significant difference in number of activated voxel between the three groups in visual cortex (BA 17, 18 and 19) while viewing all the given stimuli ($p > 0.05$). The pattern standard deviation (PSD) of SAP for visual field also revealed no significant differences ($p > 0.05$) in all groups of participants. However, negative correlation between PSD and fMRI activation was observed. The PSD values increased with a decrease in fMRI activation. With reference to visual field analysis, the results suggest that glaucomatous neuropathy of POAG patients has led to a gradual decrease in visual cortex activation and a gradual increase in PSD.

Keywords: fMRI; statistical parametric mapping; brain activation; standard automated perimetry; visual cortex

ABSTRAK

Tujuan kajian ini adalah untuk mencirikan, membezakan dan mengaitkan antara medan penglihatan dan pengaktifan otak dalam korteks penglihatan individu normal, suspek glaukoma (GS) dan glaukoma sudut terbuka primer (POAG) masing-masing menggunakan automasi perimetri piawai (SAP) dan pengimejan resonans magnet kefungsi (fMRI). Imbasan fMRI dan ujian SAP dilakukan di Pusat Perubatan Universiti Kebangsaan Malaysia (PPUKM). Dua jenis rangsangan penglihatan corak dam hitam dan putih ditayangkan kepada peserta semasa imbasan fMRI. Data fMRI dianalisis menggunakan kotak peralatan WFU Pickatlas mensasarkan kawasan korteks penglihatan. Hasil kajian menunjukkan terdapat perbezaan yang tidak signifikan dalam bilangan voxel aktif antara tiga kumpulan kajian semasa melihat semua jenis rangsangan tersebut ($p > 0.05$). Sisihan piawai corak (PSD) SAP bagi keputusan medan penglihatan juga mendedahkan perbezaan yang tidak signifikan ($p > 0.05$) dalam semua kumpulan peserta. Terdapat korelasi negatif antara PSD dan bilangan voksel aktif fMRI. Nilai PSD meningkat dengan pengurangan pengaktifan fMRI. Berdasarkan analisis medan penglihatan, neuropati glaukoma pesakit POAG membawa kepada penurunan secara beransur-ansur pengaktifan di korteks penglihatan dan peningkatan PSD secara beransur-ansur.

Kata kunci: fMRI; pemetaan statistik berparameter; pengaktifan otak; automasi perimetri piawai; korteks penglihatan

INTRODUCTION

POAG is a disease of the optic nerve and is associated with an increase in intraocular pressure (IOP). A person with POAG has an open anterior chamber angle, cupping as well as atrophy of the optic disc with loss of optic nerve fibres. An increase in IOP is a strong risk factor for glaucoma. Clinical diagnosis of POAG and its monitoring of progression are made possible through the evaluation of its functional deficit (such as visual field), structural

deficit (such as optic nerve head) and retinal nerve fibre layer (Litwak 2001). While GS participant can be defined as a person with one or more risk factors that might lead to glaucoma, this individual however, does not have a definite glaucomatous optic nerve damage or visual field defect (Shingleton et al. 1999).

A common consequence of glaucoma is glaucomatous optic neuropathy. Yagci et al. (2005) stated that even though high IOP is a major risk factor for glaucoma, it is not the only existing factor. However, IOP and aqueous humour dynamics pressure control is important for the

understanding of glaucoma, not only because they are the most commonly known risk factors for glaucoma, but also because they are factors that can be controlled to prevent glaucomatous optic neuropathy progression.

The detection (or diagnosis) and the ability to classify people suspected with glaucoma is important for the purpose of prevention and treatment. Thus, researchers conduct studies using functional magnetic resonance imaging (fMRI) to assist in the diagnosis and monitoring of POAG and GS.

The fMRI technique has been widely used for brain imaging since 1990. It has been used to monitor glaucomatous changes in human brain morphology (Duncan et al. 2007). Results from an fMRI study have also showed a distinct decrease of visual area of the optic nerve, lateral geniculate nucleus (LGN) and primary visual cortex (V1) in glaucoma subjects. (Boucard et al. 2009). However, changes in activity in visual cortex region can only be found in limited number of glaucoma studies conducted using fMRI (Duncan et al. 2007; Qing et al. 2010).

In a previous fMRI study (Duncan et al. 2007), the results demonstrated that V1 responded with a visual field loss as quantified by a standard automated perimetry (SAP). The results have made the fMRI technique an appropriate tool for the study of pathophysiology in the visual pathway. To date, no studies have been conducted to correlate the visual field changes with visual field activation in glaucoma suspects.

Therefore this study was conducted to determine the relationship between the fMRI visual cortex activation and pattern standard deviation (PSD) of visual field for normal, GS and POAG patients.

EXPERIMENTAL METHODS

A total of 46 participants were recruited for this study. They were divided into 3 groups; normal control group ($n = 16$), GS group ($n = 15$) and POAG group ($n = 15$). Participants' ages were above 40 years old. It has been reported that an individual whose age is greater than 40 years old is at risk for glaucoma (Bonomi et al. 2000).

This study was approved by the Institutional Ethics Committee (IEC) – Reference number NN-073-2011. All participants were given written information sheets, consent forms and screening forms. All given information was verbally explained to participants. Participants understood the examination procedures and agreed to participate, by signing the consent form. All participants were required to undergo comprehensive vision tests at the Ophthalmology Clinic, Pusat Perubatan Universiti Kebangsaan Malaysia (PPUKM) and Hospital Selayang. The POAG and GS patients were diagnosed by ophthalmologist in these two hospitals. The tests which were conducted by a qualified optometrist consisted of family history, entrance test, refraction, anterior and posterior segment assessment and SAP Humphrey's visual field test. Fundus examination

was conducted by the ophthalmologist using an indirect ophthalmoscope during which optic disc parameters were recorded. These were done to screen the participants whether they are normal, POAG or GS.

All participants should have the acuity better than 6/12 with or without full refractive correction. However, the participants who were claustrophobic or had implant or metal in the body were not be recruited into the study. Additionally, participants were excluded if they have ocular or systemic disorder, neurological disease or had undergone ocular surgery and taking medication that would affect the sensitivity of the visual field. The inclusion criteria for normal participants were that, they must be in good health, free from neurological, systemic or ocular problems. The exclusion criteria for normal participants was having congenital color vision defects, undergone intraocular surgery and have a family history of glaucoma. POAG participants must have intra-ocular pressure (IOP) exceeding 21 mmHg with MD between -6 to 12 dB in SAP test which show disk abnormalities such as digging, thinning of the rim, retinal nerve fiber layer defect with papillae or atrophy and taking anti-glaucoma medication. For GS participants, the intraocular pressure must be greater than 21 mmHg, cup to disc ratio less than 0.5 and has a normal field of vision as shown by the HFA tests.

Details of fMRI data acquisition and analysis can be found in our previous studies (Nasaruddin et al. 2014; Nasaruddin et al. 2015) but are also given here in brief. The fMRI scans were conducted using a 3-T Siemens Magnetom Verio scanner at the Department of Radiology, PPUKM. A standard blood oxygenation level dependent or BOLD imaging protocol with gradient echo planar imaging (EPI) pulse sequence was used with imaging parameters as follows: acquisition time (TA) = 3000 ms, echo time (TE) = 50 ms, field of view (FOV) = 192×192 mm, flip angle (α) = 90° , matrix size = $3 \times 3 \times 3$ and slice thickness = 3 mm. The acquisition time (TA) is 2s with an interval of 1s ($TR = 2\text{ s} + 1\text{ s} = 3\text{ s}$). There are 8 measurement cycles in one fMRI session. The imaging time for the entire session is 12 minutes.

Measurement setup is shown in Figure 1. Visual stimuli generated by a computer were projected onto the translucent screen via a liquid crystal display (LCD) projector. The non-metallic screen was fixed inside the magnet room while both the projector and the computer were placed at the control panel outside the magnet room. The participants viewed the stimuli on the screen via a mirror that was attached to the head coil. Two types of stimuli were used in this study; quadrant arc (E and F) and checkerboard pattern (G), (Figure 2) and (Nasaruddin et al. 2015). All stimuli have black-and-white checkerboard pattern. Stimulus E and F has an element of movement but stimulus G is static. Stimulus E and F were sequentially flipped when displayed to the participants. Participants were instructed to focus at a particular spot at the edge of the stimulus (Figure 2).

The E and F stimuli are partial contrast reversing checkerboard patterns with a subtended angle of 2.1° . Participants were instructed to focus on a point with a subtended angle of 0.24° at a corner of the screen. The G stimulus is a full contrast-reversing checkerboard pattern with each square subtended at 0.9° .

All the T2*- and T1-weighted images were analyzed at the Diagnostic Imaging & Radiotherapy Program, Faculty of Health Sciences, UKM Kuala Lumpur. Image analyses were performed using a personal computer. Matlab (7.6 R2010a Mathworks Inc., Natick, MA, USA) -based Statistical Parametric Mapping (SPM12) (Functional Imaging Laboratory, Wellcome Department of Imaging Neuroscience, Institute of Neurology, University College of London) was used in the analysis. The T1 and T2*-weighted images which were initially in DICOM (.dcm) formats were transformed into Analyze (.hdr, .img) format using SPM. Functional images from each measurement were realigned using the 6-parameter affine transformation translationally (x , y and z) and rotationally (pitch, roll and

yaw) to reduce artefacts from participant movement and to make within- and between-participant comparisons meaningful. Following realignment, a mean image of the series was used to estimate some warping parameters that mapped it onto a template that conformed to a standard anatomical space, i.e., EPI template provided by the Montreal Neurological Institute (MNI). The normalization procedure used a 12-parameter affine transformation, where the parameters constituted a spatial transformation matrix. The images were then smoothed using a 6-mm full-width-at-half-maximum Gaussian kernel. The activated voxels were identified by the general linear model approach by estimating the parameters of the model and deriving the appropriate test statistic (t statistic) for every voxel. Statistical inferences were finally obtained based on Gaussian random field theory. The Wake Forest University (WFU) Pick Atlas toolbox (Maldjian et al. 2003) was used in order to identify the region of interest (ROI) which are Brodmann's Area (BA) 17, 18 and 19.

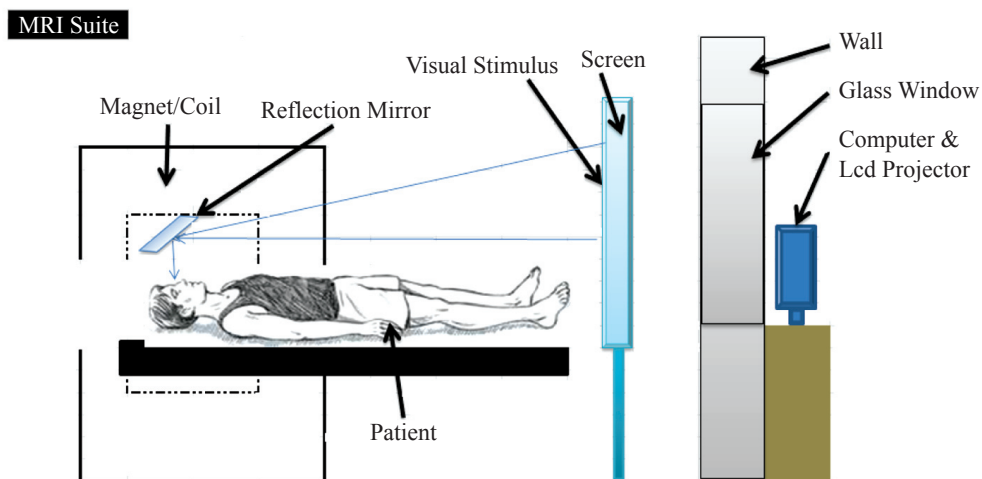


FIGURE 1. Patient's setup in MRI scanning room

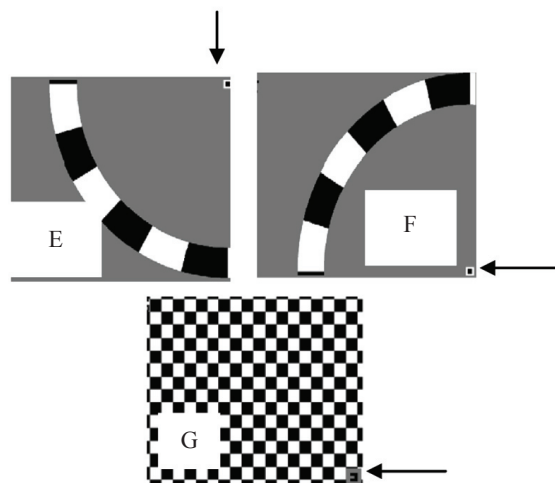


FIGURE 2. Visual stimuli. Participants were instructed to focus on a small dot indicated by arrows during the fMRI scans

RESULTS

Table 1 shows the average number of activated voxel (NOV) for normal, GS and POAG participants. The activation in the visual cortex demonstrates that NOV is higher in normal as compared to GS and POAG participants for the

TABLE 1. Average number of activated voxels (NOV) with their standard deviation obtained from the fMRI data analysis

Stimulus	E and F	G
Normal	640.9 ± 941.4	400.8 ± 378.2
GS	546.7 ± 857.0	341.5 ± 368.9
POAG	335.2 ± 476.4	187.4 ± 333.7

E, F and G stimuli (Figure 3). The NOV obtained from E and F stimuli is significantly ($p < 0.05$) higher than G for all groups. NOV for normal participants was found to be insignificantly different ($p > 0.05$) for GS and POAG participants respectively. Likewise, no significant different ($p > 0.05$) in NOV was found when the data were compared between GS and POAG groups.

On the other hand, SAP Humphrey's visual field test results were presented as pattern standard deviation (PSD), see Table 2. In contrast to NOV, highest PSD value was observed for POAG participants followed by GS and normal participants (Figure 4). Similar to NOV, the PSD values between groups were not significantly different from each other ($p > 0.05$).

TABLE 2. Statistical results obtained from ANOVA in comparing the PSD between normal, GS and POAG patients

Source of Variation	SS	df	MS	F	P-value	F crit
Between Groups	2.049296	2	1.024648	0.088407	0.915643	3.340386
Within Groups	324.5227	28	11.5901			
Total	326.572	30				

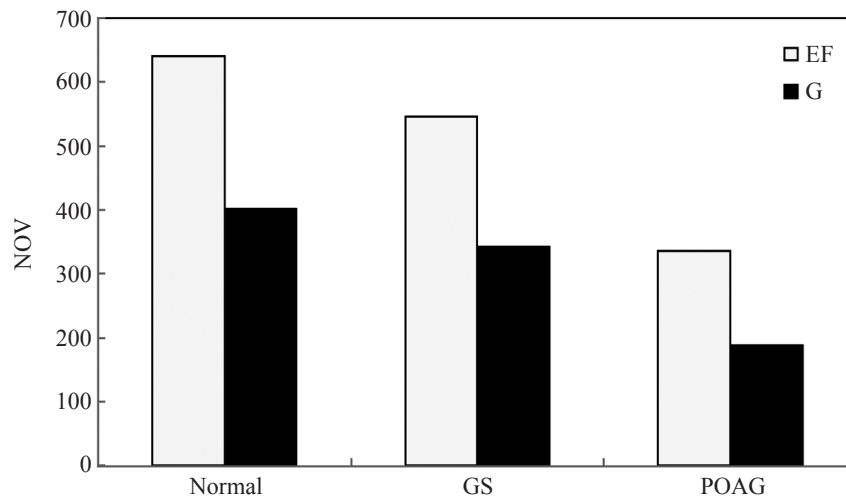


FIGURE 3. Average number of activated voxels obtained from EF and G stimuli for all groups

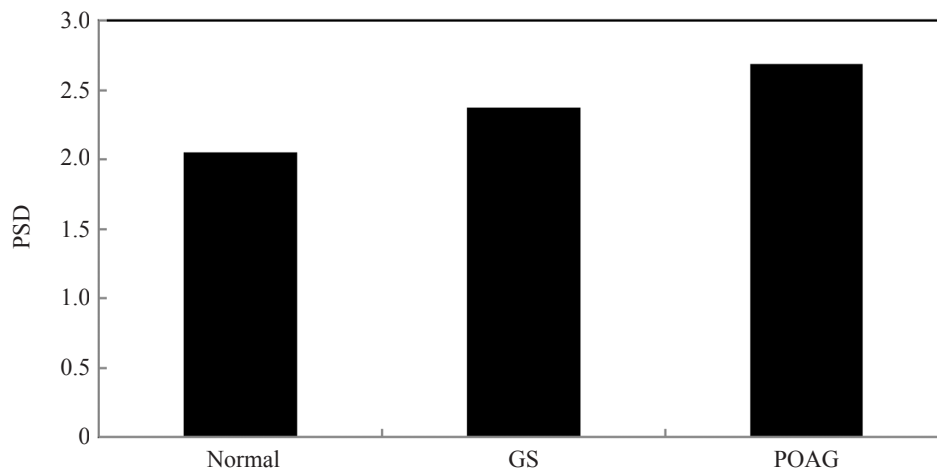


FIGURE 4. Average PSD values for all groups

DISCUSSION

The decrease in NOV in visual cortex for GS and POAG participants as compared to the normal, on the one hand, clearly indicates a reduction in the functionality of visual cortex in relation to visual field stimuli (Lešták et al. 2011). On the contrary, the difference in NOV between GS and POAG participants could be due to the indistinguishable functionality of visual cortex of the participants in both groups, in particular when visualizing visual field stimuli, given that GS participants are those who are in the early stage of POAG. The differences are however not significant which could probably be due to insufficient number of participants for comparisons (Qing et al. 2010).

In a previous study (Qing et al. 2010), it has been determined that the activated voxels (2086 ± 1063) in visual cortex obtained from participants that visualized the stimuli using their glaucomatous eye did not differ ($p = 0.428$) from activated voxels (1813 ± 1239) obtained from participants with normal vision. Further investigation indicated that all glaucomatous participants visualizing using their glaucomatous eye evoked a smaller BOLD response as compared to visualizing through their fellow eye. Despite the less number of participants, there is a consistent trend demonstrated by the participants. Compared to normal and GS eyes, the POAG glaucomatous eyes prove a decline BOLD response in visual cortex. The decrease of BOLD response evoked by the glaucomatous eyes may be due either to a flow-on effect of early perceptual loss or to cortical abnormalities. (Qing et al. 2010). Thus, the POAG patients may face a complexity in their daily visual tasks.

BOLD responses in the primary visual cortex decrease in postretinal neuropathy patients. Glaucomatous neuropathy involves the whole visual pathway and neural activity relies on regulation of blood vessels (Qing et al. 2010). Therefore, the decreasing trend in the activated voxels in POAG patients can be assumed to be resulted from BOLD signal which was interrupted by cerebral vascular activity in POAG. Changes in cerebral blood flow were directly controlled by neurons and neuronal atrophy whereby postretinal visual pathway in POAG patients may affect the neuron-vascular coupling which would lead to the reduction of BOLD signal (Qing et al. 2010) and consequently less fMRI activation. Other researchers also reported that the neuronal degeneration and activity of V1 and LGN greatly reduced the metabolic activity within V1 in glaucoma patients. (Brooks et al. 2004).

Previous study (Qing et al. 2010) demonstrated that the NOV in the visual cortex was related to the parameter of a visual field analysis which involved PSD. They found a negative correlation between PSD and fMRI activation with $R = -0.745$. The PSD values were found to increase with the reciprocal of fMRI activation. The results obtained from our study were in good agreement with that of (Qing et al. 2010) whereby, for normal participants, PSD was lowest and the number of activated voxel was highest. In another study (Lešták et al. 2011), it was found that the

decreasing fMRI activation was associated with oxygen extraction in neurovascular link due to the reduction in the number of surviving neurons. The negative correlation means that the PSD of visual field values increases while the fMRI activation decreases. The finding was explained by (Duncan et al. 2007) as trans-synaptic degeneration. The larger the intraocular PSD difference in visual field defects, the smaller the BOLD response. The decreasing number of activated voxels evoked by the glaucomatous eye in POAG participants was assumed to be due to the perceptual loss and cortical abnormalities.

A noticeable limitation in our study was during the fMRI experiment in which the participants were given an explanation of what they were required to do but no training on how to perform the task in the scanner was given. This should be included in future studies so that a consistent understanding by the participants about how the experiment works is achieved.

CONCLUSION

The lower NOV with lower BOLD responses in the visual cortex for POAG participants as compared to normal participants was possibly due to glaucomatous neuropathy that may lead to the gradual decrease in visual cortex cortical activation and the gradual increase in PSD. It is suggested that with the increase in PSD values, the risk for attaining glaucoma will be augmented. Even though there are not many studies employing fMRI in early glaucoma, those studies conducted confirmed that there are changes in visual cortex region. This study supports previous experiments that fMRI is suitable in detecting early glaucoma for GS patients.

ACKNOWLEDGEMENT

This work was supported by UKM-GUP-2011-125 research grant, the Ministry of Education of Malaysia. The author (NHN) expresses her gratitude to Asia Metropolitan University, Selangor for their support. A special gratitude to Jemaima Che Hamzah for her expertise in diagnosing GS and POAG patients in Ophthalmology Clinic, Hospital Canselor Tuanku Muhriz and Haireen Kamaruddin from Hospital Selayang respectively. An appreciation to Sa'don Samian for the assistance in the use of MRI facility in the Department of Radiology, Hospital Canselor Tuanku Muhriz.

REFERENCES

- Bonomi, L., Marchini, G., Marraffa, M., Bernardi, P., Morbio, R. & Varotto, A. 2000. Vascular risk factors for primary open angle glaucoma: the Egna-Neumarkt Study. *Ophthalmology* 107(7): 1287-1293.
- Boucard, C.C., Hernowo, A.T., Maguire, R.P., Jansonius, N.M., Roerdink, J.B., Hooymans, J.M. & Cornelissen, F.W. 2009.

- Changes in cortical grey matter density associated with long-standing retinal visual field defects. *Brain*: 119.
- Brooks, D.E., Källberg, M.E., Cannon, R.L., Komáromy, A.M., Ollivier, F.J., Malakhova, O.E., Dawson, W.W., Sherwood, M.B., Kuekerichkina, E.E. & Lambrou, G.N. 2004. Functional and structural analysis of the visual system in the rhesus monkey model of optic nerve head ischemia. *Investigative Ophthalmology & Visual Science* 45(6): 1830-1840.
- Desmond, J.E. & Glover, H.O. 2002. Estimating sample size in functional MRI (fMRI) neuroimaging studies: Statistical power analyses. *Journal of Neuroscience Methods* 118(2): 115-128.
- Duncan, R.O., Sample, P.A., Bowd, C., Weinreb, R.N. & Zangwill, L.M. 2012. Arterial spin labeling fMRI measurements of decreased blood flow in primary visual cortex correlates with decreased visual function in human glaucoma. *Vision Res.* 60: 51-60.
- Duncan, R.O., Sample, P.A., Weinreb, R.N., Bowd, C. & Zangwill, L.M. 2007. Retinotopic organization of primary visual cortex in glaucoma: Comparing fMRI measurements of cortical function with visual field loss. *Progress in Retinal and Eye Research* 26(1): 38-56.
- Duncan, R.O., Sample, P.A., Weinreb, R.N., Bowd, C. & Zangwill, L.M. 2007. Retinotopic organization of primary visual cortex in glaucoma: Comparing fMRI measurements of cortical function with visual field loss. *Prog. Retin. Eye Res.* 26(1): 38-56.
- Lešťák, J., Tintera, J., Kyncl, M., Svata, Z. & Obenberger, J. 2011. Changes in the visual cortex in patients with high-tension glaucoma. *J. Clinic Experiment Ophthalmol.* 54.
- Maldjian, J.A., Laurienti, P.J., Kraft, R.A. & Burdette, J.H. 2003. An automated method for neuroanatomic and cytoarchitectonic atlas-based interrogation of fMRI data sets. *Neuroimage* 19(3): 1233-1239.
- Maldjian, J.A., Laurienti, P.J., Kraft, R.A. & Burdette, J.H. 2003. An automated method for neuroanatomic and cytoarchitectonic atlas-based interrogation of fMRI data sets. *Neuroimage* 19(3): 1233-1239.
- Nasaruddin, N.H., Yusoff, A.N. & Kaur, S. 2014. Brain activation in response to randomized visual stimulation as obtained from conjunction and differential analysis: An fMRI study. *Journal of Physics: Conference Series* 546(1).
- Nasaruddin, N.H., Yusoff, A.N., Kaur, S., Nasrudin, N.F. & Muda, S. 2015. Brain activation due to various visual stimuli: a pilot study using fixed-effects analysis on healthy participants. *Malaysian Journal of Health Sciences* 13(1): 57-68.
- Qing, G., Zhang, S., Wang, B. & Wang, N. 2010. Functional MRI signal changes in primary visual cortex corresponding to the central normal visual field of patients with primary open-angle glaucoma. *Investigative Ophthalmology & Visual Science* 51(9): 4627-4634.
- Shingleton, B.J., Gamell, L.S., O'Donoghue, M.W., Baylus, S.L. & King, R. 1999. Long-term changes in intraocular pressure after clear corneal phacoemulsification: normal patients versus glaucoma suspect and glaucoma patients. *J. Cataract Refract Surg.* 25(7): 885-890.
- Yagci, R., Eksioğlu, U., Midillioglu, I., Yalvac, I., Altıparmak, E. & Duman, S. 2005. Central corneal thickness in primary open angle glaucoma, pseudoexfoliate glaucoma, ocular hypertension and normal population. *European Journal of Ophthalmology* 15(3): 324-328.

Nurul Hanim Nasaruddin
Universiti Metropolitan Asia
Cheras, Selangor, 43200
Malaysia

Nurul Hanim Nasaruddin
Ahmad Nazlim Yusoff
Diagnostic Imaging & Radiotherapy Program
School of Diagnostic & Applied Health Sciences
Faculty of Health Sciences, Universiti Kebangsaan Malaysia
Jalan Raja Muda Abdul Aziz, 50300 Kuala Lumpur
Malaysia

Sharanjeet Kaur
Optometry & Vision Science Program
School of Healthcare Sciences
Faculty of Health Sciences, Universiti Kebangsaan Malaysia
Jalan Raja Muda Abdul Aziz, 50300 Kuala Lumpur
Malaysia

Corresponding author: Ahmad Nazlim Yusoff
Email: nazlimtrw@ukm.edu.my
Tel: +603-92897295/8029
Fax: +603-92899032

Received: September 2015
Accepted for publication: February 2016