



DIGITAL ACCESS TO  
SCHOLARSHIP AT HARVARD  
DASH.HARVARD.EDU



HARVARD LIBRARY  
Office for Scholarly Communication

# Revision Acromioclavicular- Coracoclavicular Reconstruction: Use of Precontoured Button and 2 Allografts

The Harvard community has made this  
article openly available. [Please share](#) how  
this access benefits you. Your story matters

Citation	Haber, Daniel B., Robert C. Spang, George Sanchez, Anthony Sanchez, Márcio B. Ferrari, and Matthew T. Provencher. 2017. "Revision Acromioclavicular-Coracoclavicular Reconstruction: Use of Precontoured Button and 2 Allografts." <i>Arthroscopy Techniques</i> 6 (6): e2283-e2288. doi:10.1016/j.eats.2017.08.039. <a href="http://dx.doi.org/10.1016/j.eats.2017.08.039">http://dx.doi.org/10.1016/j.eats.2017.08.039</a> .
Published Version	<a href="https://doi.org/10.1016/j.eats.2017.08.039">doi:10.1016/j.eats.2017.08.039</a>
Citable link	<a href="http://nrs.harvard.edu/urn-3:HUL.InstRepos:34868787">http://nrs.harvard.edu/urn-3:HUL.InstRepos:34868787</a>
Terms of Use	This article was downloaded from Harvard University's DASH repository, and is made available under the terms and conditions applicable to Other Posted Material, as set forth at <a href="http://nrs.harvard.edu/urn-3:HUL.InstRepos:dash.current.terms-of-use#LAA">http://nrs.harvard.edu/urn-3:HUL.InstRepos:dash.current.terms-of-use#LAA</a>



# Revision Acromioclavicular-Coracoclavicular Reconstruction: Use of Precontoured Button and 2 Allografts

Daniel B. Haber, M.D., Robert C. Spang, M.D., George Sanchez, B.S.,  
Anthony Sanchez, B.S., Márcio B. Ferrari, M.D., and  
CAPT Matthew T. Provencher, M.D., M.C., U.S.N.R.

---

**Abstract:** Injuries to the acromioclavicular (AC) joint are common, particularly in the young and active population. Approximately 9% of all shoulder girdle injuries involve the AC joint, and AC joint dislocations represent approximately 8% of all joint dislocations throughout the body. AC joint injuries are graded as type I through type VI according to the Rockwood classification. Type I and II injuries are typically treated nonoperatively, whereas type IV, V, and VI injuries are most often treated surgically. A variety of surgical techniques have been described, including anatomic and nonanatomic reconstruction. However, up to 80% of patients go on to lose radiographic reduction, and between 20% and 30% have complications leading to reoperation. Therefore, the objective of this Technical Note is to describe our preferred technique for the treatment of AC joint instability in the revision setting. This technique uses a Dog Bone Button (Arthrex, Naples, FL) and 2 allografts.

---

Injuries to the acromioclavicular (AC) joint are common, particularly in the young and active population. Approximately 9% of all shoulder girdle injuries involve the AC joint, and almost half of AC joint injuries occur in patients aged in their 20s, with a 5:1 male-female ratio.<sup>1</sup> AC joint dislocations represent approximately 8% of all joint dislocations throughout the body and are associated with coracoacromial (CA) as well as coracoclavicular (CC) ligament injuries.<sup>2</sup> Injuries are classified as type I through type

VI according to the Rockwood criteria. Type I and II injuries are typically treated nonoperatively, whereas type IV, V, and VI injuries are most often treated surgically because of extensive soft-tissue disruption and significant morbidity from persistent instability.<sup>1</sup> On the other hand, the treatment of type III injuries remains controversial.

Because AC joint injuries are prevalent, complications of operative and nonoperative treatment have been described. In a systematic review, Beitzel et al.<sup>3</sup> found 120 studies describing 162 different techniques for operative AC joint reconstruction, underscoring that no gold-standard technique has emerged. Millett et al.<sup>4</sup> reported 2-year outcomes after primary anatomic CC ligament reconstruction in 31 shoulders. A complication occurred in 7 patients (22.6%) necessitating a subsequent surgical procedure. Issues included graft rupture and/or attenuation (2), clavicle fracture (2), distal clavicle hypertrophy (2), and adhesive capsulitis (1). Clavert et al.<sup>5</sup> similarly reported an overall complication rate of 22.4% in a series of 116 primary arthroscopic CC ligament reconstructions using Endo-Button fixation (Smith & Nephew Endoscopy). These included hardware failure and loss of reduction (11), coracoid fracture (1), adhesive capsulitis (7), local infection (2), and hardware pain (5).

With such a diverse surgical approach to these common injuries, complications encountered both during

---

*From the Harvard Combined Orthopaedic Residency, Massachusetts General Hospital (D.B.H., R.C.S.), Boston, Massachusetts; Geisel School of Medicine at Dartmouth (G.S.), Hanover, New Hampshire; Steadman Philippon Research Institute (A.S., M.B.F., M.T.P.); and The Steadman Clinic (M.T.P.), Vail, Colorado, U.S.A.*

*The authors report the following potential conflict of interest or source of funding: M.T.P. receives support from Arthrex, JRF Ortho. Consultant. Patent numbers (issued): 9226743, 20150164498, 20150150594, 20110040339. Arthrex, SLACK. Publishing royalties. Full ICMJE author disclosure forms are available for this article online, as [supplementary material](#).*

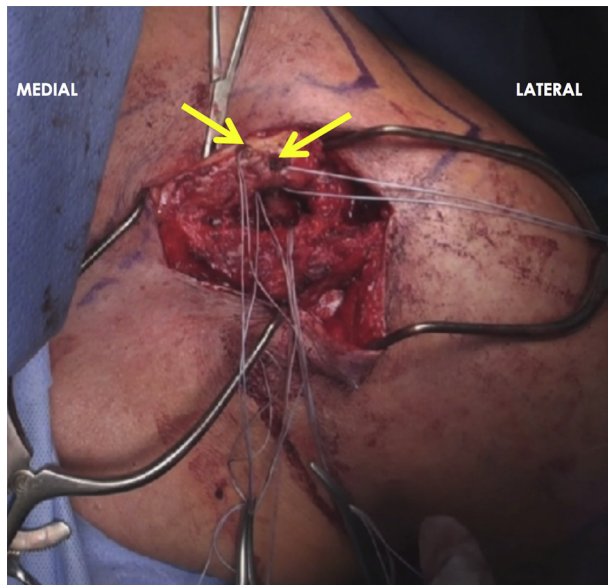
*Received March 30, 2017; accepted August 25, 2017.*

*Address correspondence to CAPT Matthew T. Provencher, M.D., M.C., U.S.N.R., Steadman Philippon Research Institute, 181 W Meadow Dr, Ste 1000, Vail, CO 81657, U.S.A. E-mail: [mprovencher@thesteadmanclinic.com](mailto:mprovencher@thesteadmanclinic.com)*

*© 2017 Published by Elsevier on behalf of the Arthroscopy Association of North America. This is an open access article under the CC BY-NC-ND license (<http://creativecommons.org/licenses/by-nc-nd/4.0/>).*

*2212-6287/17443*

*<https://doi.org/10.1016/j.eats.2017.08.039>*



**Fig 1.** After the exposure of the lateral third of the clavicle in the left shoulder, 2 tunnels (arrows) in an anterior-to-posterior direction are drilled to anatomically reconstruct the coracoclavicular ligaments. In a revision setting of an anatomic procedure, the previously formed tunnels must be identified. Then, by use of electrocautery, the fibrotic tissue and graft inside these tunnels must be removed.

and after AC joint reconstruction are common and varied. As such, treating AC joint injuries in the revision setting presents unique challenges. A thorough understanding of diagnosis and reasons for failure, as well as intraoperative “bailouts” and pitfalls, is important for a successful operative outcome. Ultimately, the objective of this Technical Note is to describe our preferred technique for the treatment of AC joint instability in the revision setting.

## Surgical Technique

A narrated video with demonstration of the surgical technique described in this report may be reviewed ([Video 1](#)).

### Patient Positioning and Anesthesia

The procedure is performed with the patient under general anesthesia, supplemented by a regional interscalene block for postoperative analgesia. The patient is positioned in the beach-chair position. The knees are placed in slight flexion, with a soft pad under the popliteal fossa. Care must be taken to ensure that all bony prominences are well padded and that the head is secured on the table.

### Surgical Approach

The previous incision from the patient’s primary reconstruction is generally used ([Video 1](#)). All relevant bony structures are identified through palpation and

marked with a surgical pen. It is often necessary to extend the previous incision for adequate exposure. The incision should be centered approximately 2 to 3 cm medial to the AC joint and made curvilinear along the Langer lines toward the coracoid process. The incision should measure approximately 8 cm.

Dissection down to the deltotrachezial fascia is carried out with a combination of Metzenbaum scissors and needle-tip Bovie device (Bovie Medical). Meticulous hemostasis is maintained. Once the deltotrachezial fascia is identified, it is incised longitudinally along the midline of the clavicle and continued across the AC joint to the acromion. Full-thickness flaps, including the periosteum, are made from the midline of the clavicle, both posteriorly and anteriorly, achieved skeletonization of the bone. The full-thickness flaps are preserved for imbrication and closure.

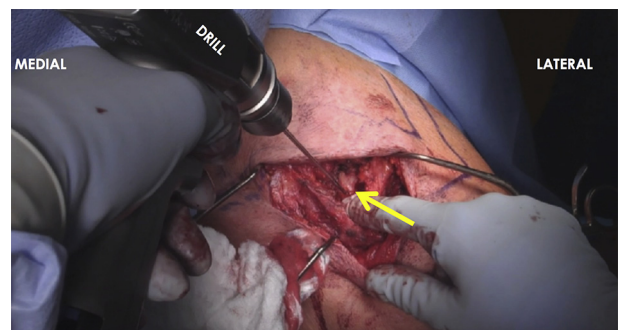
As suture and hardware are identified during the surgical approach, they are removed. Scar tissue may also be debrided for full exposure of the distal clavicle, AC joint, and coracoid. Dissection medial to the coracoid should be minimized to avoid injury to the musculocutaneous nerve.

### Graft Preparation

While the initial exposure is performed, an assistant may prepare the 2 anterior tibialis allografts to be used for reconstruction of the joint. Depending on surgeon preference, semitendinosus allograft or autograft or anterior tibialis allograft may be used. Each graft should be whipstitched on both ends with a goal diameter of 5 to 7 mm.

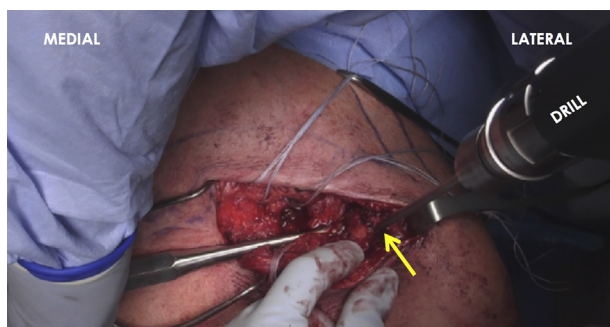
### Bone Tunnels in Clavicle

Once adequate exposure is achieved, attention is turned to the clavicle. Once all previous hardware is removed, the old bone tunnels may be evaluated for their position. Two tunnels are required in the



**Fig 2.** The coracoid tunnel must be drilled with a 2.4- or 3-mm drill, approximately 25 to 30 mm posterior to the anterior tip of the coracoid (arrow) in the left shoulder. We find that this distance from the tip of the coracoid decreases the risk of fracture and maintains the anatomic position of the coracoclavicular ligament insertion on the coracoid.



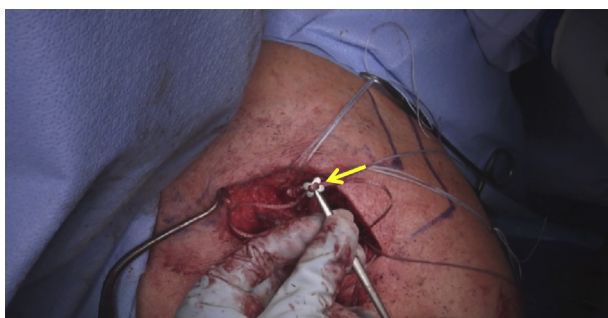


**Fig 3.** Once the tunnels in the clavicle and coracoid are drilled, attention is turned to the acromion in the left shoulder. The first tunnel (arrow) is drilled approximately 7 to 10 mm lateral to the acromioclavicular joint on the anterior aspect of the acromion. This tunnel will accommodate the Dog Bone Button construct with FiberTape and suture anchor to secure the graft to the acromion.

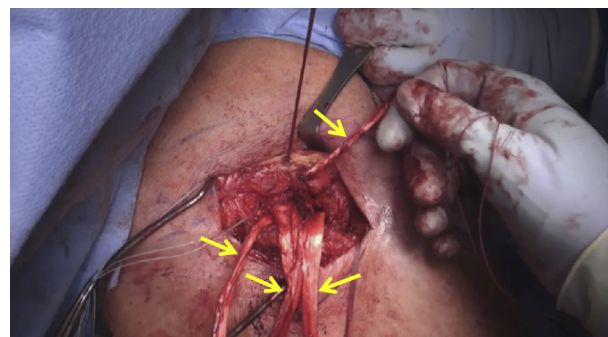
clavicle—one to reconstruct the conoid ligament using a Dog Bone Button (Arthrex, Naples, FL) and the other for the trapezoid ligament using an anterior tibialis allograft (Fig 1). The bone tunnels should be in as accurate a position as possible to re-create the anatomic positioning of these ligaments. The conoid process tunnel should be roughly 30 to 45 mm medial to the distal end of the clavicle and positioned posteriorly. If a tunnel is being drilled, a 2.4- or 3-mm drill is used with a retractor placed along the inferior aspect of the clavicle to prevent damage to the adjacent neurovascular structures. Next, a bone tunnel is drilled for the trapezoid ligament, approximately 15 mm lateral to the center of the conoid tunnel and more anteriorly. The diameter of the tunnel should match the diameter of the prepared allograft (approximately 5 mm). Passing sutures are then passed through both tunnels. A passing suture is also passed around the clavicle.

#### Bone Tunnel in Coracoid

If a previous bone tunnel is present in the coracoid, its location is identified. A 2.4- or 3-mm bone tunnel is



**Fig 4.** The Dog Bone Button (arrow) used to fix the FiberTape in the coracoid and posterior clavicle (i.e., conoid ligament) tunnels during anatomic reconstruction of the acromioclavicular and coracoclavicular ligaments is shown in the left shoulder.



**Fig 5.** After preparation of the tunnels in the clavicle, acromion, and coracoid process, attention is turned to the passage of the 2 anterior tibialis grafts (arrows) in the left shoulder. For grafts, we suggest using a semitendinosus allograft or autograft or anterior tibialis allograft.

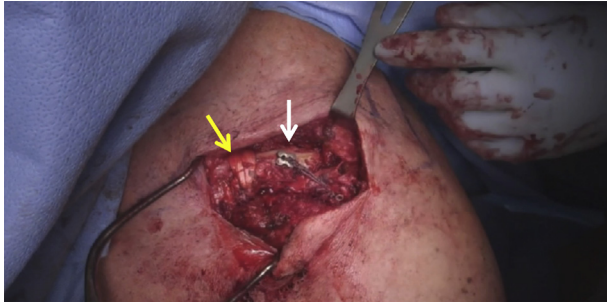
drilled approximately 25 to 30 mm posterior to the anterior tip of the coracoid, in the anatomic area of the CC ligament insertion. If the previous tunnel is there, it may be used if structurally sound. If drilling a tunnel (Fig 2), the surgeon should ensure that the previous tunnel is not in proximity to prevent coracoid fracture. A passing suture is passed through this tunnel. An additional suture is passed around the inferior aspect of the coracoid to facilitate passage of the 2 grafts at a later time.

#### Bone Tunnels in Acromion

Any remaining graft tissue in the AC joint is debrided to ensure full AC joint reduction. The acromion requires 2 bone tunnels. One of these bone tunnels is located approximately 7 to 10 mm lateral to the AC joint on the anterior aspect of the acromion (Fig 3). This tunnel will later accommodate the FiberTape (Arthrex) passed through the Dog Bone Button construct. The second tunnel is 7 to 10 mm lateral to the AC joint but 15 to 20 mm posterior to the first acromion tunnel. This should be drilled to match the diameter of the graft, which will also be passed through the more lateral clavicular (trapezoid) tunnel, approximately 5 to 7 mm in diameter. During drilling, a retractor or malleable should be placed on the undersurface of the acromion to protect the rotator cuff.

#### Fixation

The Dog Bone Button construct with FiberTape (Fig 4) is then passed through the coracoid tunnel, from inferiorly to superiorly, and pulled tight. The FiberTape passing through the Dog Bone Button construct is snapped and set aside. The 2 anterior tibialis allografts are passed around the inferior aspect of the coracoid. After this, the tendon strands are set aside. The free end of the FiberTape passing through the Dog Bone Button construct is then passed through the more medial, posterior clavicle tunnel (conoid ligament tunnel) from inferiorly to



**Fig 6.** The completed anatomic reconstruction of the coracoclavicular and acromioclavicular ligaments is shown in the left shoulder. The Dog Bone Button is seen on the superior aspect of the clavicle (white arrow) while graft passage (yellow arrow) medial to the Dog Bone Button, located on the clavicle, is visualized.

superiorly. Again, the free ends are snapped and set aside. One end of allograft (matching the diameter of the previously drilled lateral clavicular trapezoid tunnel) is passed from inferiorly to superiorly through the lateral clavicular tunnel; this will be called “graft 1.” The other allograft, which will be called “graft 2,” is then wrapped around the clavicle, just medial to the Dog Bone Button. One strand of graft 2 should come around anteriorly and the other posteriorly, with the strands crossing on the superior surface of the clavicle. These strands are then snapped and set aside. The graft placement before fixation is shown in [Figure 5](#).

The AC and CC joints are then reduced manually. Fluoroscopy may be used to confirm reduction. Once adequate reduction is achieved, the FiberTape belonging to the Dog Bone Button construct, now traveling out the superior aspect of the more medial clavicular tunnel, is tightened and secured. The Dog Bone Button suture strands are not cut but instead are set aside.

Graft 1 is positioned so that 66% to 75% of its length is out the top of the lateral clavicular tunnel. A 4.75-mm PEEK (polyether ether ketone) Tenodesis Screw (Arthrex) is placed from superiorly to inferiorly to secure graft 1 in the clavicle. The long end of graft 1 is then passed through the posterior acromion tunnel from inferiorly to superiorly. Graft 1 is tensioned, thereby reducing the AC joint.

Graft 2 is then tensioned across the top of the clavicle ([Fig 6](#)), just medial to the Dog Bone Button construct. One strand is crossed over the other, and both strands are sutured together with FiberWire suture (Arthrex). The remnant limbs of the FiberWire suture, as well as one limb of graft 2, are cut and discarded.

The remaining limbs of graft 1, one exiting the posterior acromion tunnel and the other found around the coracoid, are crossed, tensioned, and sutured together with FiberWire. The remnant limbs of the FiberWire, as well as one limb of graft 1, are then cut and discarded.

Afterward, the remaining limbs of grafts 1 and 2 are crossed, tensioned, and sutured together with FiberWire. The remnant limbs of the FiberWire, as well as

**Table 1.** Pearls and Pitfalls

Pearls	Pitfalls
The surgeon should carefully analyze old bone tunnels and drill holes for positioning, size, and lysis. If lysis is present or the tunnel is poorly positioned, a tunnel should be drilled. If no space is available for a tunnel or if the old tunnels are too large or have propagated, larger screw fixation or “cuff links” (plastic hole savers placed into the drill holes) may be used.	Coracoid fracture may occur if the old drill hole and current drill hole are too close. The surgeon must ensure that they are spaced out appropriately. If a coracoid fracture occurs, it may be reduced with Kirschner wires and fixed with a single 3.5-mm cortical screw.
Anatomic placement of bone tunnels is important for anatomic coracoclavicular reconstruction. The conoid (medial-most) tunnel for the Dog Bone Button should be 30-45 mm medial from the AC joint and on the posterior aspect of the clavicle. The trapezoid (lateral-most) tunnel for graft 1 should be positioned 15 mm lateral from and more anteriorly to the conoid tunnel. This will improve the stability and strength of the construct.	Injury to the musculocutaneous nerve may occur while dissection or retraction is being performed medial to the coracoid. If needed, this should be performed with caution.
Fluoroscopy should be used to confirm adequate reduction of the AC joint.	Placing a reduction clamp medial to the coracoid may cause injury to the musculocutaneous nerve.
Before fixing graft 1 to the lateral clavicle with the tenodesis screw, the surgeon should ensure that 75% of the graft is passed through the clavicle first. Otherwise, the graft will not have sufficient length to travel through the posterior acromion tunnel and back to be sutured to itself.	Injury to the neurovascular structures may occur if the drill plunges deep to the clavicle and coracoid. A retractor should always be placed on the undersurface of the clavicle and coracoid while drilling.
The AC joint should be over-reduced during initial fixation because of an inevitable amount of creep in the tendon graft. Grafts may be tensioned to help minimize creep.	Injury to the rotator cuff or humeral head articular surface may occur if the drill plunges deep to the acromion. A retractor should always be placed on the undersurface of the acromion while drilling.

AC, acromioclavicular.

the remaining limbs of graft 1 and graft 2, are then cut and discarded.

Once all graft limbs have been cut and discarded, the free ends of the FiberTape emanating from the Dog Bone Button construct are passed through the anterior acromion tunnel and secured to the tunnel through use of a 4.75-mm PEEK Tenodesis Screw to create an internal brace construct. The remaining limbs of the FiberTape are then cut and discarded.

### Closure

The shoulder is checked for impingement and stability as it is taken through a full arc of motion. The wound is irrigated, and closure is begun. The full-thickness deltotrapezoidal fascia flaps are closed with a nonabsorbable suture in a pants-over-vest fashion. The deep dermal layer is closed, followed by the skin layer. A sterile dressing is applied, and the patient is placed in a padded abduction sling with elbow support. The pearls and pitfalls associated with the technique are listed in [Table 1](#).

### Postoperative Rehabilitation

The patient will remain in the padded abduction sling with elbow support for a total of 6 weeks. Gentle passive range of motion of the elbow and wrist is encouraged during this time. At 4 weeks, the patient is referred to physical therapy for pendulum exercises and passive shoulder motion. Active and active-assisted motion exercises commence after the sixth week. Strengthening is delayed until 3 months. Full activities and sports may be resumed at 5 to 6 months.

### Discussion

AC joint injuries are commonly seen in young active patients, especially those who participate in contact sports. The AC joint is a diarthrodial joint, with stability maintained by the CA and CC (trapezoid and conoid) ligaments, in addition to the capsule, deltoid, and trapezius. Although most AC joint injuries can be successfully treated nonoperatively, types IV, V, and VI are generally treated surgically to address persistent instability and pain.<sup>6,7</sup> However, up to 80% of patients go on to lose radiographic reduction, and between 20% and 30% of patients treated surgically have complications leading to reoperation.<sup>4,5</sup>

Complications from AC joint reconstruction are varied and may be unique to the implant and fixation method used during the index procedure. The ability to understand the index procedure construct, fixation method, and reasons for failure makes revision surgery more likely to be successful. Although there are many reasons for AC joint reconstruction failure, our described technique may be used in most situations.

The Weaver-Dunn procedure, which includes distal clavicle excision and transfer of the CA ligament to reconstruct the CC ligament, may fail, in part, because the CA ligament is only 20% as strong as the native CC ligament.<sup>8</sup> Modifications of this procedure include using a variety of materials to supplement the CC ligament construct. Failures of the Weaver-Dunn procedure generally leave the clavicle and coracoid intact, making these failures especially amenable to our described technique.

Anatomic reconstruction and other techniques using drill holes through the coracoid and clavicle may fail because of fracture or cutout. Our technique uses a single tunnel in the coracoid for the Dog Bone Button, acting as an internal brace, although our construct does not solely rely on this for maintenance of reduction. When coracoid cutout or fracture is present, it is essential to either fix the fracture or carefully place the bone tunnel away from the previous area of cutout. For our technique to be successful, the coracoid must be intact to allow passage of allograft around the inferior portion of the coracoid. In cases of clavicle fracture, the fracture should be reduced and fixed before reconstruction of the AC joint. In cases of clavicular cutout, spacing out tunnels is important to prevent future fracture while still attempting to anatomically reconstruct the joint. In many cases, old drill holes may be used, if positioned correctly, to pass the allograft.

Although several surgical reconstruction techniques have been described, both in the primary setting and in the revision setting, our revision technique uses an anatomic reconstruction. With an anatomic reconstruction, the native biomechanics of the joint are more properly restored, with some studies suggesting greater strength and a lower risk of recurrent instability.<sup>9</sup> We also prefer biological over synthetic grafts because biological grafts are reported to have superior clinical and radiographic outcomes.<sup>10</sup> Furthermore, we believe that the use of Dog Bone Buttons through the coracoid and clavicular bone tunnels reinforces the reconstruction and further minimizes the risk of loss of reduction and subsequent instability. Although we suggest using our surgical technique for the treatment of AC joint instability in the revision setting, future studies with long-term follow-up are needed to assess outcomes.

### References

1. Rockwood CA Jr, Young DC. Disorders of the acromioclavicular joint. In: Rockwood CA Jr, Matsen FA Hi, eds. *The Shoulder*. Philadelphia: WB Saunders; 1990;413-476.
2. Rieser GR, Edwards K, Gould GC, Markert RJ, Goswami T, Rubino LJ. Distal-third clavicle fracture

- fixation: A biomechanical evaluation of fixation. *J Shoulder Elbow Surg* 2013;22:848-855.
3. Beitzel K, Cote MP, Apostolakis J, et al. Current concepts in the treatment of acromioclavicular joint dislocations. *Arthroscopy* 2013;29:387-397.
  4. Millett PJ, Horan MP, Warth RJ. Two-year outcomes after primary anatomic coracoclavicular ligament reconstruction. *Arthroscopy* 2015;31:1962-1973.
  5. Clavert P, Meyer A, Boyer P, et al. Complication rates and types of failure after arthroscopic acute acromioclavicular dislocation fixation. Prospective multicenter study of 116 cases. *Orthop Traumatol Surg Res* 2015;101:S313-S316 (suppl).
  6. Korsten K, Gunning AC, Leenen LPH. Operative or conservative treatment in patients with Rockwood type III acromioclavicular dislocation: A systematic review and update of current literature. *Int Orthop* 2014;38:831-838.
  7. Wojtys EM, Nelson G. Conservative treatment of grade III acromioclavicular dislocations. *Clin Orthop Relat Res* 1991;(268):112-119.
  8. Weaver JK, Dunn HK. Treatment of acromioclavicular injuries, especially complete acromioclavicular separation. *J Bone Joint Surg Am* 1972;54:1187-1194.
  9. Lee S, Bedi A. Shoulder acromioclavicular joint reconstruction options and outcomes. *Curr Rev Musculoskelet Med* 2016;9:368-377.
  10. Fauci F, Merolla G, Paladini P, Campi F, Porcellini G. Surgical treatment of chronic acromioclavicular dislocation with biologic graft vs synthetic ligament: A prospective randomized comparative study. *J Orthop Traumatol* 2013;14:283-290.