



DIGITAL ACCESS TO
SCHOLARSHIP AT HARVARD
DASH.HARVARD.EDU



HARVARD LIBRARY
Office for Scholarly Communication

Effects of Topical and Subconjunctival Bevacizumab in High-Risk Corneal Transplant Survival

The Harvard community has made this
article openly available. [Please share](#) how
this access benefits you. Your story matters

Citation	Dastjerdi, Mohammad H., Daniel R. Saban, Andre Okanobo, Nambi Nallasamy, Zahra Sadrai, Sunil K. Chauhan, Amir R. Hajrasouliha, and Reza Dana. 2010. "Effects of Topical and Subconjunctival Bevacizumab in High-Risk Corneal Transplant Survival." <i>Investigative Ophthalmology & Visual Science</i> 51 (5) (May 1): 2411. doi:10.1167/iovs.09-3745.
Published Version	doi:10.1167/iovs.09-3745
Citable link	http://nrs.harvard.edu/urn-3:HUL.InstRepos:34787803
Terms of Use	This article was downloaded from Harvard University's DASH repository, and is made available under the terms and conditions applicable to Other Posted Material, as set forth at http://nrs.harvard.edu/urn-3:HUL.InstRepos:dash.current.terms-of-use#LAA

Effects of Topical and Subconjunctival Bevacizumab in High-Risk Corneal Transplant Survival

Mobammad H. Dastjerdi,^{1,2,3,4} Daniel R. Saban,^{1,2,4} Andre Okanobo,^{1,2,3} Nambi Nallasamy,^{1,2} Zakra Sadrai,^{1,2} Sunil K. Chauban,^{1,2} Amir R. Hajrasouliha,^{1,2} and Reza Dana^{1,2,3}

PURPOSE. To investigate whether corneal graft survival could be improved by topical or subconjunctival bevacizumab in a murine model of vascularized high-risk corneal transplantation.

METHODS. Before corneal transplantation, intrastromal sutures were placed for 2 weeks in the corneas of BALB/c mice, inducing intense angiogenesis. Allogeneic corneal transplantation was performed using C57BL/6 donor mice. Topical bevacizumab (2.5%) was delivered 3 times a day for 3 weeks in one treatment group, and 0.02 mL (0.5 mg) bevacizumab was injected subconjunctivally at days 0, 4, 8, and 15 after transplantation in the other treatment group. The control group received no treatment. Grafts were examined twice a week for 8 weeks by slit-lamp microscopy and were photographed once a week by slit-lamp digital camera and scored for opacity. For assessment of corneal neovascularization (NV), a quantitative method was used to measure three primary metrics including neovascular area, vessel caliber, and neovessel invasion area.

RESULTS. Both topical and subconjunctival bevacizumab treatment reduced neovascular area and vessel caliber; however, the regression of corneal NV was more profound when treated subconjunctivally. The mean percentage reduction of neovascular area was 55% ($P < 0.05$) by week 8 in the subconjunctival treatment group and 33% ($P = 0.15$) in the topical group. Only subconjunctival bevacizumab treatment resulted in significant regression of neovessel invasion area ($P < 0.05$). All corneal transplants in both the control and the topical groups were rejected by 4 weeks after transplantation. However, in the subconjunctival treatment group, 33% of corneal grafts survived ($P < 0.01$).

CONCLUSIONS. Subconjunctival bevacizumab may offer an adjunctive measure to conventional therapies in preventing graft

rejection in high-risk corneal transplantation. (*Invest Ophthalmol Vis Sci.* 2010;51:2411–2417) DOI:10.1167/iov.09-3745

Allograft rejection is a leading cause of corneal graft failure and thus a leading indication for repeat penetrating keratoplasty.¹ Indeed, repeat grafting as a result of previous failure has become the second leading indication for corneal transplantation, as reported.² It has been known for many decades that the presence of preexisting blood vessels is a strong risk factor for corneal graft immune rejection.^{3–5} Grafting into vascularized corneal beds, or so-called high-risk corneal transplantations, leads to a rate of immune rejection of greater than 50%, even with a strict regimen of topical and systemic immunosuppressive drugs.⁶ In fact, stratification of risk factors for immunologic rejection in penetrating keratoplasty has identified recipient vascularization as a critical proximal cause for earlier and more fulminant rejection episodes.^{4,5,7,8}

Targeting angiogenesis to modulate immune responses after corneal transplantation has been the core area of interest for many investigators.^{9–13} Why the relative immunologic quiescence of the eye, which is a central facet of its immunoprivileged state, is disturbed in patients with corneal neovascularization (NV) is not fully understood.¹⁴ However, experimental evidence strongly suggests that molecular factors such as the local immunosuppressive cytokine milieu (transforming growth factor- β , α -melanocyte-stimulating hormone) and functional attributes (anterior chamber-associated immune deviation), which play a critical role in maintaining the physiologic quiescence in the anterior segment, are subverted in the presence of corneal NV.¹⁴ In addition to blood vessels in vascularized high-risk corneas, lymphatic neovessels can ingrow in parallel with hemangiogenesis, facilitating effective access of donor and host antigen-presenting cells and antigenic material to regional lymph nodes, where accelerated sensitization to graft antigens occurs.^{15,16} Thus, treatment of corneal NV after corneal transplantation can potentially limit both the afferent (sensitization) and efferent (rejection) arms of alloimmunity and, hence, reduce the propensity for immunoinflammatory reactions that can jeopardize graft survival.¹⁴

Vascular endothelial growth factor (VEGF) is thought to be a key mechanistic mediator of NV.¹⁷ The prominent role of VEGF in the pathophysiology of corneal NV has been demonstrated in experimental models of corneal angiogenesis.¹⁸ It has been shown that VEGF is upregulated in inflamed and vascularized corneas in humans and in animal models.¹⁹ VEGF inhibitors, including pegaptanib sodium, ranibizumab, and bevacizumab, are used for the treatment of neovascular age-related macular degeneration.²⁰ Recently, there has been growing interest in using topical and subconjunctival anti-VEGF for the treatment of corneal NV.^{21–26} Our data in a prospective clinical study have demonstrated a significant reduction in the severity of corneal NV in response to topical bevacizumab

From the ¹Schepens Eye Research Institute, Boston, Massachusetts; the ²Department of Ophthalmology, Harvard Medical School, Boston, Massachusetts; and the ³Massachusetts Eye and Ear Infirmary, Boston, Massachusetts.

⁴These authors contributed equally to the work presented here and should therefore be regarded as equivalent authors.

Presented in part at the Cornea Society/Eye Bank Association of America Fall Educational Symposium, November 2008, Atlanta, Georgia.

Supported by National Institutes of Health/National Eye Institute Grants K24 EY019098 and RO1 EY12963 and by an Eye Bank Association of America Scientific Research Grant.

Submitted for publication March 22, 2009; revised June 4 and July 25, 2009; accepted September 14, 2009.

Disclosure: **M.H. Dastjerdi**, None; **D.R. Saban**, None; **A. Okanobo**, None; **N. Nallasamy**, None; **Z. Sadrai**, None; **S.K. Chauban**, None; **A.R. Hajrasouliha**, None; **R. Dana**, None

Corresponding author: Reza Dana, Schepens Eye Research Institute, 20 Staniford Street, Boston, MA 02114; reza.dana@schepens.harvard.edu.

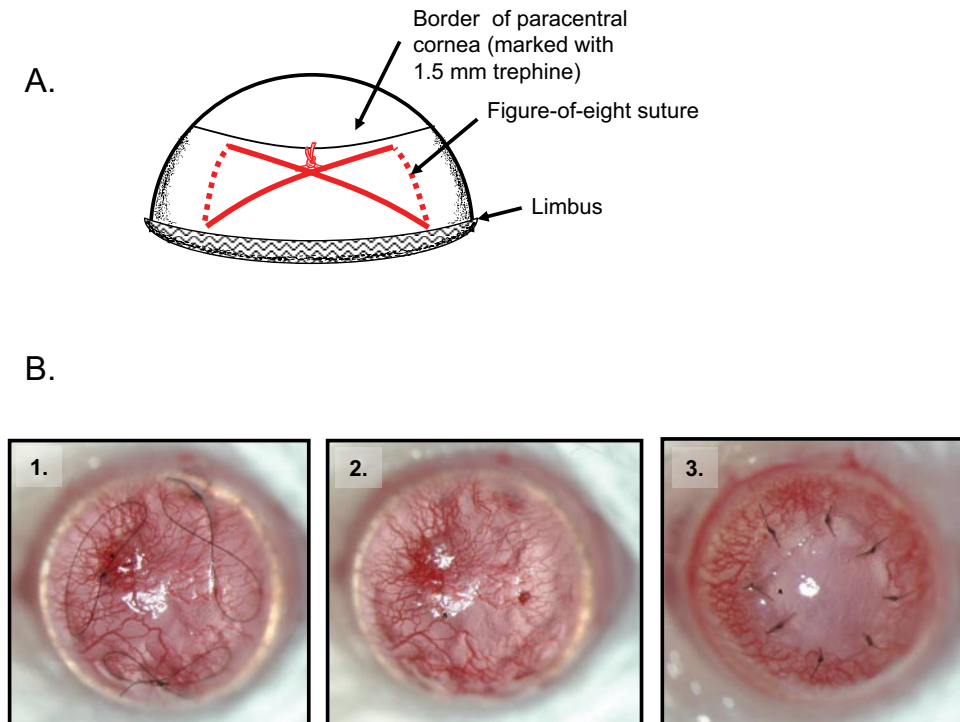


FIGURE 1. Preparation of robust high-risk graft beds for orthotopic corneal transplantation. (A) Schematic depiction of the figure-eight knot used created with two intrastromal incisions, each extending from slightly above the limbus to the circumference of the paracentral cornea, which was marked with a 1.5-mm trephine. Three of these suture knots were placed in BALB/c mice to stimulate robust corneal neovascularization (B1). After 14 days the sutures were removed (B2), and penetrating corneal transplantation was performed using age-matched C57BL/6 donors (B3).

therapy in patients with stable corneal NV.²⁷ In an animal model of high-risk corneal transplantation, it has also been shown that intraperitoneal (systemic) injection of a VEGF-neutralizing cytokine trap can improve corneal graft survival.¹² These reports suggest that treatment with topical or locally injected anti-VEGF could offer an adjunctive measure to conventional therapies (e.g., corticosteroids) to curb the inciting factors of graft rejection in the setting of vascularized high-risk corneal transplantation. Therefore, we sought to evaluate whether corneal graft survival in vascularized high-risk corneal transplantation can be improved by initiating local (topical or subconjunctival) bevacizumab treatment in a murine model. To make a thorough and comprehensive assessment of corneal NV, a quantitative method was implemented to measure three primary metrics—neovascular area, vessel caliber, and neovessel invasion area. Our results indicate that while both topical and subconjunctival bevacizumab therapy inhibit corneal NV after high-risk transplantation, only the subconjunctival route is significantly effective in improving graft survival.

METHODS

Animals and Anesthesia

Eight- to 12-week-old C57BL/6 and BALB/c male mice were obtained from Taconic Farms (Germantown, NY). Mice were housed in a specific pathogen-free environment at the Schepens Eye Research Institute animal facility. All animals were treated according to guidelines established by the ARVO Statement for the Use of Animals in Ophthalmic and Vision Research and the Public Health Policy on Humane Care and Use of Laboratory Animals (US Public Health Review), and all procedures were approved by the Institutional Animal Care and Use Committee. Anesthesia was administered intraperitoneally by ketamine/xylazine solution at a dose of 120 mg/kg body weight and 20 mg/kg body weight, respectively.

High-Risk Graft Bed Preparation

Aspects of this procedure were adapted and modified from Cursiefen et al.²⁸ to enhance corneal NV. First a 1.5-mm trephine was used to

mark the central corneas of BALB/c mice. A figure-of-eight suture knot was then placed with two intrastromal incisions approximately 120° apart, and each incision extended apically from slightly above the limbus to the trephine demarcation (Fig. 1A). Three interrupted figure-of-eight suture knots were placed using 11-0 nylon sutures (Sharp; Vanguard, Houston, TX) for 14 days, after which graft beds exhibited extensive neovascularization. At this time, the sutures were removed, and penetrating corneal transplantation was performed using age-matched C57BL/6 donors.

Corneal Transplantation

This procedure has been detailed elsewhere.²⁹ Briefly, the central cornea (2-mm diameter) was excised from a donor mouse using scissors (Vannas; Storz Instruments, San Dimas, CA) and was placed on ice in corneal preservation media (Optisol-GS; Bausch and Lomb, Rochester, NY). The graft bed was prepared by excising a 1.5-mm site in the central cornea of a recipient mouse. A donor button was then placed onto the recipient bed and was secured with eight interrupted 11-0 nylon sutures (Sharp; Reading, PA) (Fig. 1B). Graft survival was evaluated regularly twice a week using a slit-lamp biomicroscope over the course of 8 weeks. We used a standardized opacity-grading (range, 0–5+) scheme to identify rejection,²⁹ defined as a score of $\geq 3+$ for two consecutive examinations.

Bevacizumab Treatment

Topical bevacizumab 2.5% (25 mg/mL; Avastin; Genentech, South San Francisco, CA) was applied three times a day for 3 weeks in one treatment group ($n = 10$). For the subconjunctival group ($n = 10$), a volume of 0.02 mL bevacizumab 2.5% (0.5 mg) was injected at days 0, 4, 8, and 15 after transplantation. The control group ($n = 10$) received no treatment.

Quantification of Corneal Neovascularization

We developed a method to objectively quantify corneal NV for application of this study. This method consists of first capturing a series of digital slit-lamp images of corneas and then, using graphics editing software (Photoshop CS2; Adobe Systems Inc., Mountain View, CA) to digitally trace the blood vessels in a corneal image to

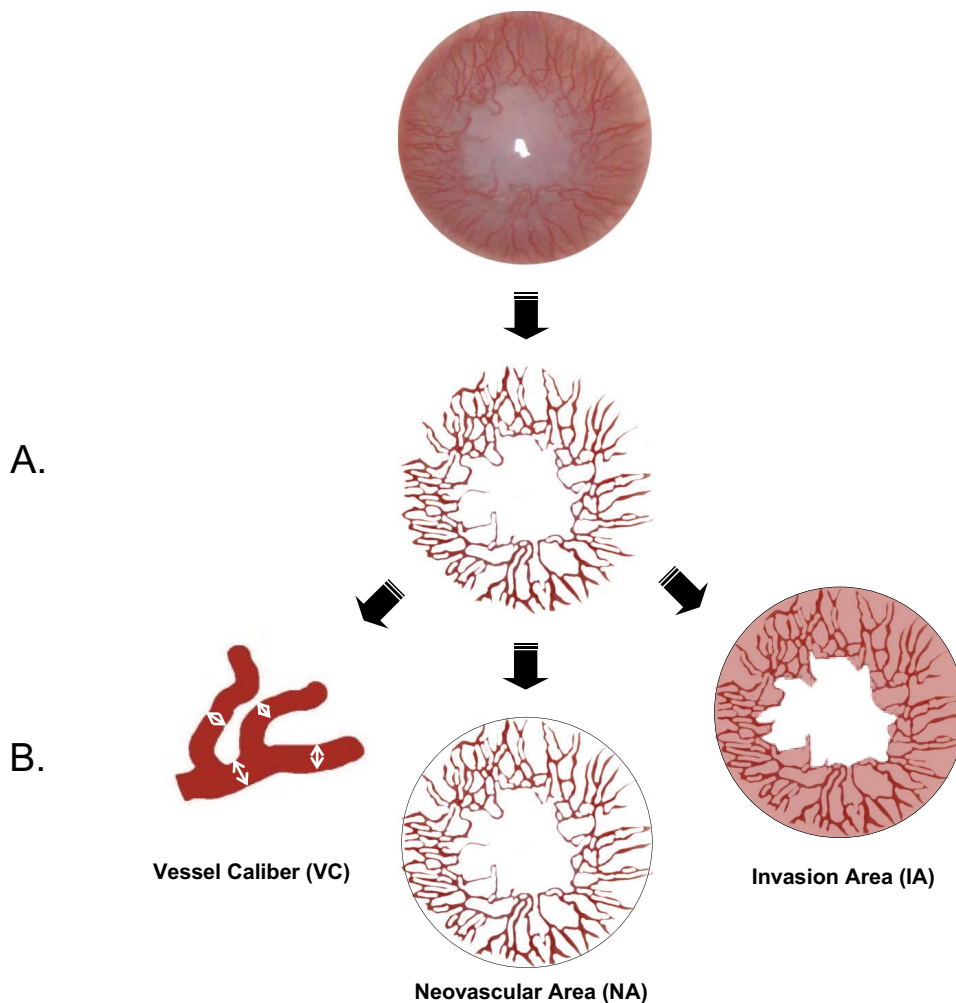


FIGURE 2. Quantification of corneal neovascularization. Digital slit-lamp corneal pictures were analyzed using graphics editing software and a mathematical program. After the total corneal area was outlined, the blood vessels were enhanced and traced by using different graphics editing tools and filters. By setting a threshold level, the nonvessel area was erased, and the remaining neovascular area was then pixelized and measured. Three metrics were computed using a mathematical script: NA, which measures the area of the corneal vessels themselves; VC, which determines an approximate mean diameter of the corneal vessels; and IA, which measures the fraction of corneal area in which vessels are present.

remove the background of nonvessel areas (Fig. 2A). This method yields a very clear picture with which to qualitatively evaluate corneal NV levels in vivo (Fig. 3A) and, importantly, allows each individual mouse to be followed at various time points throughout the study (Fig. 3B). In this regard, this method is different from other quantitative image analyses that have been designed for immunohistologic assessment of corneal lymphangiogenesis and hemangiogenesis.^{30,31} Three primary metrics for corneal NV were considered (Fig. 2B). The first, referred to as the *neovascular area* (NA), involves measuring the area of the corneal vessels when projected onto the plane of a photograph. The second metric, referred to as *vessel caliber* (VC), involves determining an approximate mean diameter of the corneal vessels. The third metric, referred to as *invasion area* (IA), measures the fraction of corneal area in which vessels are present. We analyzed all the corneal images quantitatively using a mathematical software program (MathLab; MathWorks Inc., Natick, MA) written specifically to calculate these corneal NV parameters. After the blood vessels were enhanced and traced by using different graphics editing (Photoshop CS2; Adobe Systems Inc.) tools and filters, by setting a threshold level, the nonvessel area was erased, and the remaining neovascular area was pixelized and measured. The calculated blood vessel area was normalized to the whole corneal area to obtain the NA score for each corneal picture. VC was also estimated by using a computational technique to measure the largest diameter circle centered at each pixel inside a blood vessel. The mean value across all pixels within blood vessels was taken as an estimate of the mean VC for a given image. Last, the IA was quantified, and the ends of all vascular sprouts were marked. By connecting all these marks, the contour of

the IA was traced and the measured area was again normalized to the whole corneal area (Fig. 2B).

Statistical Analysis

Error bars displayed in the figures were calculated from the SEM. Statistical analyses, including Student's *t*-tests, were performed throughout the study, as indicated in the respective figure captions. Kaplan-Meier analysis constructed survival curves and respective log rank tests compared with rates of corneal graft survival. $P < 0.05$ was considered significant.

RESULTS

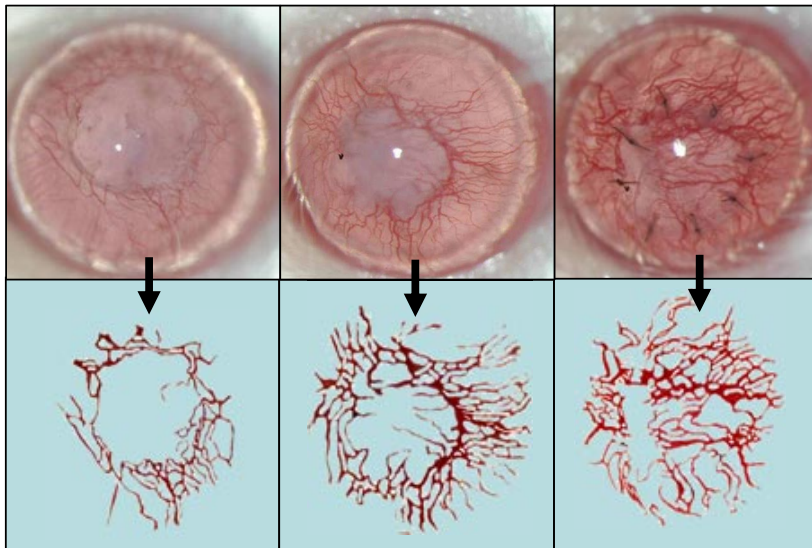
Comparison of Topical versus Subconjunctival Bevacizumab Treatment on Corneal NV

We first compared the effects of topical versus subconjunctival bevacizumab treatment in suppressing corneal NV after high-risk corneal transplantation. We found that though both topical and subconjunctival delivery of bevacizumab inhibited corneal NV after high-risk transplantation, subconjunctival treatment was clearly more effective to this end (Fig. 3B). This was the case for early time points (e.g., week 1) and late time points (e.g., weeks 4 and 8) after transplantation (Fig. 3B).

Neovascular Area

At baseline, there was no statistically significant difference in the mean NA among the three study groups. Although NA

A.



B.

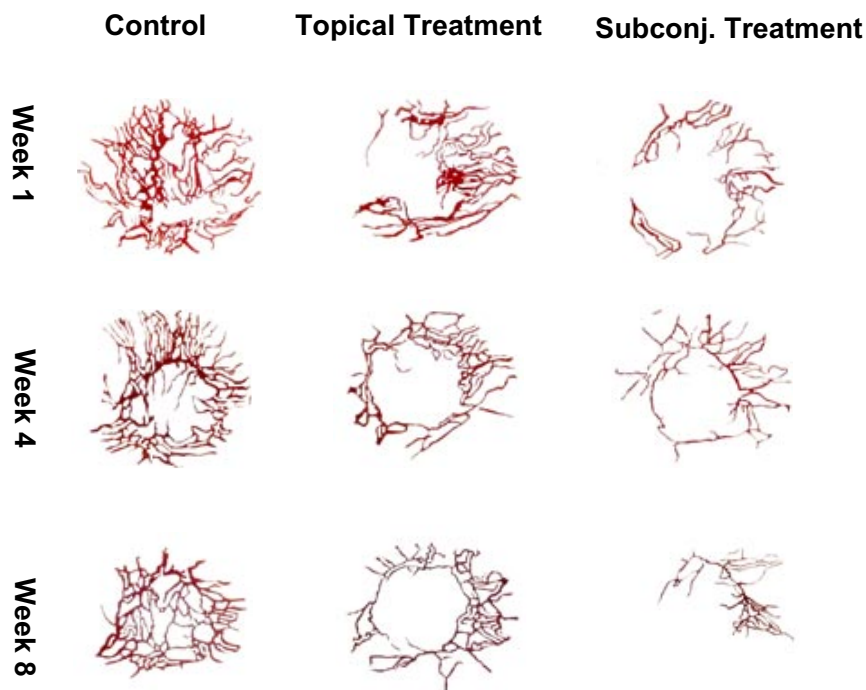


FIGURE 3. Comparison of topical and subconjunctival bevacizumab on corneal neovascularization in high-risk corneal transplantation. **(A)** High accuracy of digital tracing of blood vessels to evaluate corneal neovascularization. Representative slit-lamp images of high-risk corneal transplantation and their respective traces of corneal neovessel patterns demonstrate the accuracy of this technique. **(B)** Enhanced efficacy of subconjunctival bevacizumab treatment for inhibiting corneal neovascularization in high-risk transplantation. Representative images of corneal neovessel patterns are presented at the various times after transplantation of mice treated either topically ($n = 10$) or subconjunctivally ($n = 10$) with bevacizumab or left untreated as controls ($n = 10$).

values in all three groups decreased, by the week 4 time point it became clear that the subconjunctival route of bevacizumab was considerably more effective than the topical route in reducing NA (Fig. 4A) because the subconjunctival values were significantly and markedly lower than control at weeks 4 ($P < 0.05$), 6 ($P < 0.05$), and 8 ($P < 0.05$). The mean percentage reduction of NA in the topical group was 15% at week 2, 39% at week 4, 13% at week 6, and 33% at week 8, whereas these values in the subconjunctival group were 33% at week 2, 51% at week 4, 50% at week 6, and 55% at week 8. In the control group, the mean percentage reductions of NA were 27%, 26%, 19%, and 13% in weeks 2, 4, 6, and 8, respectively.

Vessel Caliber

Estimation of VC using a computational technique showed that values for the three groups were not statistically different at baseline. These values dropped in all three groups to the same level by week 2 and remained relatively stable until week 6. However, control values then rose substantially by week 8, but subconjunctival treatment group remained statistically lower than in the control group ($P = 0.03$). Topical bevacizumab treatment group showed a very marginal statistical significant difference from the control group in reduction of VC at week 8 ($P = 0.05$) (Fig. 4B).

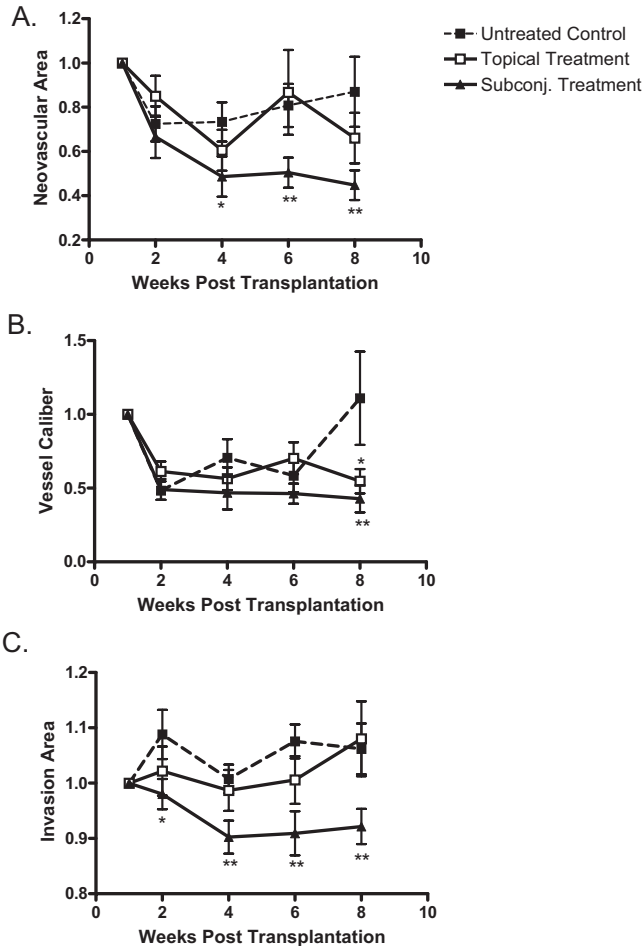


FIGURE 4. Analysis of topical versus subconjunctival bevacizumab on the corneal NA, VC, and IA. High-risk graft beds in BALB/c mice were transplanted with C57BL/6 cornea, and mice were left untreated ($n = 10$) or were treated topically ($n = 10$) or subconjunctivally ($n = 10$) with bevacizumab. (A) Total area of blood vessels in each cornea was calculated and normalized to the baseline to yield the mean NA at the indicated time points to 8 weeks after transplantation. Although topical bevacizumab treatment mildly reduced NA in high-risk corneal transplantation, subconjunctival treatment resulted in a significant and markedly reduced NA at weeks 4, 6, and 8. (B) Normalized mean values for estimated blood vessel caliber at the indicated times to 8 weeks after transplantation. Although the subconjunctival treatment group significantly reduced VC at week 8 ($P = 0.03$), topical bevacizumab appeared to have a marginal statistical difference from the control group ($P = 0.05$). (C) The total area of each given cornea invaded by blood vessels was calculated and normalized to yield the mean IA at the indicated times to 8 weeks after transplantation. Subconjunctival bevacizumab treatment appeared to be the only effective method to reduce IA. Student's t -test was performed to evaluate statistical significance (* $P \leq 0.05$; ** $P < 0.01$).

Invasion Area

As for the other two metrics, no statistically significant difference in neovessel IA was shown any at baseline between the different study groups. Control and topical groups showed increases rather than significant declines in their IA values (Fig. 4C). The mean percentage reduction values for IA were -8% , -1% , -8% , and -6% in the control group and -2% , 1% , -1% , and -8% in the topical group by weeks 2, 4, 6, and 8, respectively. Interestingly, subconjunctival treatment appeared to be the only effective method for reduce IA (Fig. 4C) because those values remained significantly lower than in the control group at

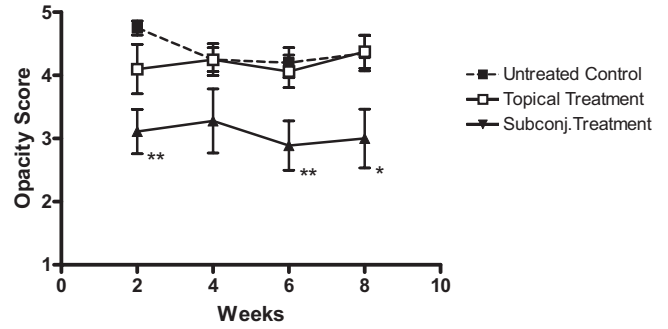


FIGURE 5. Subconjunctival delivery of bevacizumab diminishes opacity of corneal allografts in the high-risk setting. High-risk graft beds in BALB/c mice were transplanted with C57BL/6 cornea, and mice were left untreated ($n = 10$) or were treated topically ($n = 10$) or subconjunctivally ($n = 10$) with bevacizumab. Corneal allografts were examined regularly to 8 weeks after transplantation by slit lamp, and graft opacity was scored using a standard grading scheme. Student's t -test was performed to evaluate statistical significance (* $P < 0.05$; ** $P < 0.01$).

weeks 4 ($P < 0.01$), 6 ($P < 0.01$), and 8 ($P < 0.025$). Mean percentage reductions for IA in the subconjunctival group were 2%, 10%, 9%, and 8% at weeks 2, 4, 6, and 8, respectively.

Increased Efficacy of Subconjunctival versus Topical Bevacizumab on High-Risk Corneal Allograft Survival

To test whether treatment with topical or subconjunctival bevacizumab could promote allograft survival in the high-risk setting, the opacity of transplanted corneal grafts was examined and scored regularly to 8 weeks after transplantation by slit-lamp examination. We found that mice treated topically with bevacizumab did not exhibit a reduced mean opacity score (Fig. 5) or a statistical difference from the mean score of the untreated controls ($P > 0.05$). In contrast, mice treated subconjunctivally with bevacizumab exhibited a reduced mean opacity score (Fig. 5) that was significantly lower than that of the untreated controls at weeks 2 ($P < 0.01$), 6 ($P < 0.01$), and 8 ($P < 0.05$). Furthermore, Kaplan-Meier survival curve analysis demonstrated that subconjunctival treatment improved survival rates to greater than 30% ($P = 0.008$), whereas 0% survival was observed among the untreated controls (Fig. 6). Topical bevacizumab treatment also demonstrated 0% survival

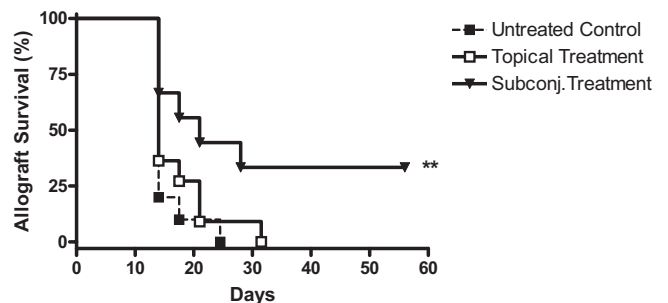


FIGURE 6. Subconjunctival bevacizumab promotes corneal allograft survival in the high-risk setting. High-risk graft beds in BALB/c mice were transplanted with C57BL/6 cornea, and mice were left untreated ($n = 10$) or were treated topically ($n = 10$) or subconjunctivally ($n = 10$) with bevacizumab. Kaplan-Meier curves were plotted to evaluate the effect of topical versus subconjunctival bevacizumab treatment on graft survival. Log rank test was performed to evaluate statistical significance (** $P = 0.008$).

(Fig. 6), though rejection was delayed relative to the untreated controls ($P > 0.05$).

DISCUSSION

Corneal NV has long been established as an important risk factor for immune rejection after corneal transplantation, yet an effective treatment has remained elusive. The data from our experiments using a mouse model of high-risk keratoplasty suggest that both topical and subconjunctival bevacizumab treatment can diminish the severity of corneal NV. However, only subconjunctival bevacizumab treatment results in a significant regression of all neovessel metrics, including NA, VC, and IA. Moreover, only subconjunctival bevacizumab treatment significantly promotes graft survival in the high-risk setting. Although topical administration of bevacizumab results in a mild to moderate decrease in the severity of corneal NV, topical bevacizumab shows little impact on graft survival in the experimental model of high-risk transplantation described here. These findings strongly suggest that topical application of bevacizumab may not be able to provide adequate anti-VEGF activity to impact graft survival compared with the subconjunctival route.

It is likely that the limited efficacy of topical bevacizumab results, at least in part, from a lack of adequate penetration through the corneal epithelium. Healthy corneal epithelium contains several layers of cells connected by tight junctions, thus acting as an effective barrier for large molecules.³² Full-length immunoglobulins, including bevacizumab, with molecular weights of 149 kDa likely have limited capacity to penetrate the intact cornea. Nonetheless, conditions such as inflammation have a significant effect on the corneal epithelium; indeed, it is known that patients with, for example, ocular surface disease have an incompetent barrier function.³³ Moreover, the clinical efficacy of topical bevacizumab in the treatment of corneal NV has been shown by our group²⁷ and by other investigators,^{21,23–25,34} indirectly suggesting that topical bevacizumab may penetrate the epithelial barrier in patients with corneal inflammatory NV. This is also supported by our work in a mouse model of corneal NV that has clearly demonstrated bevacizumab can penetrate the neovascularized cornea after topical application (Sadrai Z, et al. *IOVS* 2008;49:ARVO E-Abstract 1488). Taken together, however, it is apparent that the level of corneal penetration by topical application of bevacizumab is insufficient in markedly improving corneal NV and significantly promoting allograft survival in high-risk graft beds. In contrast, subconjunctival injection of bevacizumab can bypass the ocular surface epithelial barrier and can produce high corneal levels of drug that lead to a significant suppression of corneal NV, hence promoting graft survival in high-risk settings.

Although our results with subconjunctival bevacizumab were highly significant, the inhibition of corneal NV was far from complete for several possible reasons. First, it is possible that the dosage and duration of treatment were insufficient to effectively antagonize all VEGF activity. Because of concern regarding the potential adverse effects of bevacizumab in treating corneal NV,²⁴ we sought to limit our treatment of bevacizumab to the first few weeks after transplantation. Similarly, bevacizumab is a humanized monoclonal antibody, and thus its potency in murine models could be significantly impaired.^{35,36} Second, preexisting “stable” or “mature” vessels in the recipient bed may not be as susceptible as developing vessels to anti-VEGF treatment.³⁷ Third, it is clear that other relevant proangiogenic factors (including FGF, IL-1, TNF- α , and IFN- γ) are also upregulated during wound healing and inflammation.^{38–40} Fourth, even in relation to VEGFR2-mediated signal-

ing, it is notable that bevacizumab is a specific antibody for VEGF-A only; other ligands to VEGFR2 (e.g., VEGF-C) are not directly suppressed by bevacizumab.

Corneal NV is almost invariably associated with higher graft rejection rates, and blood vessel levels at the time of transplantation are significantly correlated with graft survival.^{41,42} Khoadadoust⁴³ reported that endothelial rejection occurred in 3.5% of avascular cases, 13.3% of mildly vascular cases, 28% of moderately vascular cases, and 65% of heavily vascular cases. In the present study, significant and marked regression of all three metrics collectively, which occurred only with subconjunctival treatment, has demonstrated a clear association with improved graft survival rate. Although topical treatment with bevacizumab resulted in a limited decrease in the severity of corneal NV, it could not increase graft survival. These findings could further underscore the significant relationship between size and extent of corneal blood vessels and chance of graft rejection. Corneal blood vessels allow an influx of immune effector cells to the corneal matrix. Therefore, the extent and size of corneal NV, including neovessel area, the caliber of neovessels, and the corneal area invaded by neovessels, particularly the portion of NV that crosses into the graft, may well be crucial for the efferent arm of immunity (facilitating delivery of alloreactive T cells), which is detrimental to corneal graft survival.¹⁴

To conclude, subconjunctival administration of bevacizumab is more effective than topical administration in treating corneal NV and promoting corneal graft survival in a mouse model of high-risk transplantation. Subconjunctival bevacizumab could potentially offer an adjunctive measure to conventional therapies in preventing graft rejection in vascularized high-risk corneal transplantation. More research, however, is needed to define the optimal dosage and frequency of administration to achieve the best clinical outcomes. Moreover, given our previous clinical results with topical bevacizumab in decreasing corneal NV²⁷ and our data in this study (using a humanized antibody in a mouse model of corneal NV), topical bevacizumab, which clearly is efficacious in suppressing corneal NV, may also (particularly at higher dosing regimens than the one used in this study) be efficacious in preventing graft rejection in high-risk corneal transplantation, warranting further study.

References

1. Coster DJ, Williams KA. The impact of corneal allograft rejection on the long-term outcome of corneal transplantation. *Am J Ophthalmol.* 2005;140(6):1112–1122.
2. *2007 Eye Banking Statistical Report.* Washington, DC: Eye Bank Association of America; 2007.
3. Collaborative Corneal Transplantation Studies Research Group. The collaborative corneal transplantation studies (CCTS): effectiveness of histocompatibility matching in high-risk corneal transplantation. *Arch Ophthalmol.* 1992;110(10):1392–1403.
4. Maguire MG, Stark WJ, Gottsch JD, et al. Risk factors for corneal graft failure and rejection in the collaborative corneal transplantation studies: Collaborative Corneal Transplantation Studies Research Group. *Ophthalmology.* 1994;101(9):1536–1547.
5. Williams KA, Roder D, Esterman A, et al. Factors predictive of corneal graft survival: report from the Australian Corneal Graft Registry. *Ophthalmology.* 1992;99(3):403–414.
6. Williams KA, Esterman AJ, Bartlett C, et al. How effective is penetrating corneal transplantation? Factors influencing long-term outcome in multivariate analysis. *Transplantation.* 2006;81(6):896–901.
7. Hamrah P, Djalilian A, Stulting R. Immunologically high-risk penetrating keratoplasty. In: Krachmer JH, Mannis MJ, Holland EJ, eds. *Cornea.* 2nd ed. Philadelphia: Elsevier Mosby; 2005.

8. Volker-Dieben HJ, D'Amaro J, Kok-van Alphen CC. Hierarchy of prognostic factors for corneal allograft survival. *Aust N Z J Ophthalmol*. 1987;15(1):11-18.
9. Yatoh S, Kawakami Y, Imai M, et al. Effect of a topically applied neutralizing antibody against vascular endothelial growth factor on corneal allograft rejection of rat. *Transplantation*. 1998;66(11):1519-1524.
10. Cursiefen C, Cao J, Chen L, et al. Inhibition of hemangiogenesis and lymphangiogenesis after normal-risk corneal transplantation by neutralizing VEGF promotes graft survival. *Invest Ophthalmol Vis Sci*. 2004;45(8):2666-2673.
11. Shi W, Gao H, Xie L, Wang S. Sustained intraocular rapamycin delivery effectively prevents high-risk corneal allograft rejection and neovascularization in rabbits. *Invest Ophthalmol Vis Sci*. 2006;47(8):3339-3344.
12. Bachmann BO, Bock F, Wiegand SJ, et al. Promotion of graft survival by vascular endothelial growth factor neutralization after high-risk corneal transplantation. *Arch Ophthalmol*. 2008;126(1):71-77.
13. Bachmann BO, Luetjen-Drecoll E, Bock F, et al. Transient postoperative VEGF-neutralisation improves graft survival in corneas with partly regressed inflammatory neovascularisation. *Br J Ophthalmol*. 2009;93(8):1075-1080.
14. Dana MR, Streilein JW. Loss and restoration of immune privilege in eyes with corneal neovascularization. *Invest Ophthalmol Vis Sci*. 1996;37(12):2485-2494.
15. Cursiefen C, Chen L, Borges LP, et al. VEGF-A stimulates lymphangiogenesis and hemangiogenesis in inflammatory neovascularization via macrophage recruitment. *J Clin Invest*. 2004;113(7):1040-1050.
16. Maruyama K, Ii M, Cursiefen C, et al. Inflammation-induced lymphangiogenesis in the cornea arises from CD11b-positive macrophages. *J Clin Invest*. 2005;115(9):2363-2372.
17. Folkman J. Angiogenesis in cancer, vascular, rheumatoid and other disease. *Nat Med*. 1995;1(1):27-31.
18. Amano S, Rohan R, Kuroki M, et al. Requirement for vascular endothelial growth factor in wound- and inflammation-related corneal neovascularization. *Invest Ophthalmol Vis Sci*. 1998;39(1):18-22.
19. Philipp W, Speicher L, Humpel C. Expression of vascular endothelial growth factor and its receptors in inflamed and vascularized human corneas. *Invest Ophthalmol Vis Sci*. 2000;41(9):2514-2522.
20. Pieramici DJ, Rabena MD. Anti-VEGF therapy: comparison of current and future agents. *Eye*. 2008;22(10):1330-1336.
21. Uy HS, Chan PS, Ang RE. Topical bevacizumab and ocular surface neovascularization in patients with Stevens-Johnson syndrome. *Cornea*. 2008;27(1):70-73.
22. Kim TI, Kim SW, Kim S, et al. Inhibition of experimental corneal neovascularization by using subconjunctival injection of bevacizumab (Avastin). *Cornea*. 2008;27(3):349-352.
23. Manzano RP, Peyman GA, Khan P, et al. Inhibition of experimental corneal neovascularisation by bevacizumab (Avastin). *Br J Ophthalmol*. 2007;91(6):804-807.
24. Kim SW, Ha BJ, Kim EK, et al. The effect of topical bevacizumab on corneal neovascularization. *Ophthalmology*. 2008;115(6):e33-e38.
25. DeStafeno JJ, Kim T. Topical bevacizumab therapy for corneal neovascularization. *Arch Ophthalmol*. 2007;125(6):834-836.
26. Bahar I, Kaiserman I, McAllum P, et al. Subconjunctival bevacizumab injection for corneal neovascularization. *Cornea*. 2008;27(2):142-147.
27. Dastjerdi MH, Al-Arfaj KM, Nallasamy N, et al. Topical bevacizumab in the treatment of corneal neovascularization: results of a prospective, open-label, non-comparative study. *Arch Ophthalmol*. 2009;127(4):381-389.
28. Cursiefen C, Masli S, Ng TF, et al. Roles of thrombospondin-1 and -2 in regulating corneal and iris angiogenesis. *Invest Ophthalmol Vis Sci*. 2004;45(4):1117-1124.
29. Sonoda Y, Streilein JW. Orthotopic corneal transplantation in mice—evidence that the immunogenetic rules of rejection do not apply. *Transplantation*. 1992;54(4):694-704.
30. Bock F, Onderka J, Hos D, et al. Improved semiautomatic method for morphometry of angiogenesis and lymphangiogenesis in corneal flatmounts. *Exp Eye Res*. 2008;87(5):462-470.
31. Blacher S, Detry B, Bruyere F, et al. Additional parameters for the morphometry of angiogenesis and lymphangiogenesis in corneal flat mounts. *Exp Eye Res*. 2009;89(2):274-276.
32. Prausnitz MR, Noonan JS. Permeability of cornea, sclera, and conjunctiva: a literature analysis for drug delivery to the eye. *J Pharm Sci*. 1998;87(12):1479-1488.
33. Huang AJ, Watson BD, Hernandez E, Tseng SC. Induction of conjunctival transdifferentiation on vascularized corneas by phot thrombotic occlusion of corneal neovascularization. *Ophthalmology*. 1988;95(2):228-235.
34. Yoeruek E, Ziemssen F, Henke-Fahle S, et al. Safety, penetration and efficacy of topically applied bevacizumab: evaluation of eye-drops in corneal neovascularization after chemical burn. *Acta Ophthalmol*. 2008;86(3):322-328.
35. Bock F, Onderka J, Dietrich T, et al. Bevacizumab as a potent inhibitor of inflammatory corneal angiogenesis and lymphangiogenesis. *Invest Ophthalmol Vis Sci*. 2007;48(6):2545-2552.
36. Yu L, Wu X, Cheng Z, et al. Interaction between bevacizumab and murine VEGF-A: a reassessment. *Invest Ophthalmol Vis Sci*. 2008;49(2):522-527.
37. Papatheassiou M, Theodossiadis PG, Liarakos VS, et al. Inhibition of corneal neovascularization by subconjunctival bevacizumab in an animal model. *Am J Ophthalmol*. 2008;145(3):424-431.
38. Chang JH, Gabison EE, Kato T, Azar DT. Corneal neovascularization. *Curr Opin Ophthalmol*. 2001;12(4):242-249.
39. Azar DT. Corneal angiogenic privilege: angiogenic and antiangiogenic factors in corneal avascularity, vasculogenesis, and wound healing (an American Ophthalmological Society thesis). *Trans Am Ophthalmol Soc* 2006;104:264-302.
40. Dana MR, Zhu SN, Yamada J. Topical modulation of interleukin-1 activity in corneal neovascularization. *Cornea*. 1998;17(4):403-409.
41. *The Australian Corneal Graft Registry 2007 Report*. Adelaide, South Australia: Flinders University Press; 2007.
42. Hill JC. The relative importance of risk factors used to define high-risk keratoplasty. *Ger J Ophthalmol*. 1996;5(1):36-41.
43. Khodadoust AA. The allograft rejection: the leading cause of late graft failure of clinical corneal grafts. In: Porter R, Knight J, eds. *Corneal Graft Failure*. Amsterdam: Elsevier; 1973.