



DIGITAL ACCESS TO
SCHOLARSHIP AT HARVARD
DASH.HARVARD.EDU



HARVARD LIBRARY
Office for Scholarly Communication

Resolution of Primary Lymphedema: A Case Report

The Harvard community has made this article openly available. [Please share](#) how this access benefits you. Your story matters

Citation	Goss, Jeremy A., Reid A. Maclellan, Usha E. A. Beijnen, and Arin K. Greene. 2017. "Resolution of Primary Lymphedema: A Case Report." <i>Plastic and Reconstructive Surgery Global Open</i> 5 (2): e1223. doi:10.1097/GOX.0000000000001223. http://dx.doi.org/10.1097/GOX.0000000000001223 .
Published Version	doi:10.1097/GOX.0000000000001223
Citable link	http://nrs.harvard.edu/urn-3:HUL.InstRepos:32072216
Terms of Use	This article was downloaded from Harvard University's DASH repository, and is made available under the terms and conditions applicable to Other Posted Material, as set forth at http://nrs.harvard.edu/urn-3:HUL.InstRepos:dash.current.terms-of-use#LAA

Resolution of Primary Lymphedema: A Case Report

Jeremy A. Goss, MD
Reid A. Maclellan, MD, MMSc
Usha E. A. Beijnen, BS
Arin K. Greene, MD, MMSc

Summary: Primary lymphedema is a rare, progressive disease that typically affects the lower extremity. The condition is not curable, and the limb enlarges over time because of subcutaneous fibroadipose deposition. We present a patient with clinical and radiographical evidence of resolution of primary lymphedema. This observation may provide greater insight into the pathophysiology of the disease. (*Plast Reconstr Surg Glob Open* 2017;5:e1223; doi: 10.1097/GOX.0000000000001223; Published online 13 February 2017.)

Lymphedema is the progressive swelling of tissue due to inadequate lymphatic function; the lymphatic system either develops abnormally (primary) or there is an injury to the lymph nodes and vessels (secondary). Primary lymphedema is rare, affecting 1 in 100,000 persons, and 92% of cases involve the lower extremities.¹ Primary lymphedema is a progressive, incurable disease. Over time, the extremities enlarge because of subcutaneous fibroadipose deposition. We present an unusual patient who, without treatment, had resolution of primary lymphedema clinically and confirmed by lymphoscintigraphy.

CASE PRESENTATION

A 5-year-old male twin conceived via in vitro fertilization presented at 3 months of age with right foot swelling. There was no family history of lymphedema. On physical examination, the right foot had pitting edema and a positive Stemmer's sign (inability to pinch the skin of the dorsum of the foot). The left foot was normal. The child was thought to have infant-onset primary lymphedema, and a lymphoscintigram was performed to confirm the diagnosis (Fig. 1). The study showed abnormal lymphatic function in the right lower extremity confirming lymphedema.

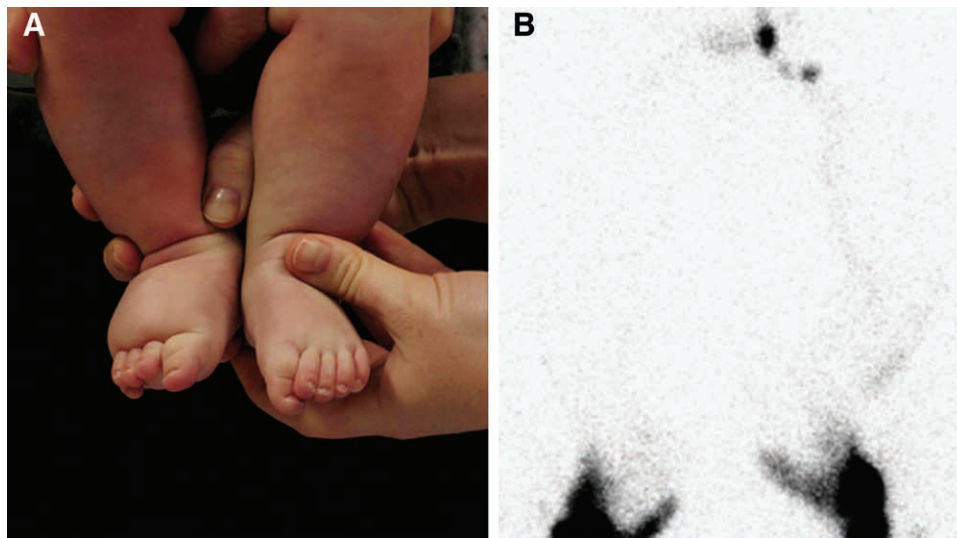


Fig. 1. A, Patient's appearance at 3 months of age showing swelling of the right foot. B, Lymphoscintigram image 30 minutes after the injection of radiolabeled tracer into the feet illustrates the absence of tracer uptake in the right inguinal nodes indicating lymphatic dysfunction.

From the Department of Plastic and Oral Surgery, Boston Children's Hospital, Harvard Medical School, Boston, Mass.

Received for publication November 10, 2016; accepted December 14, 2016.

Copyright © 2017 The Authors. Published by Wolters Kluwer Health, Inc. on behalf of The American Society of Plastic Surgeons. This is an open-access article distributed under the terms of the Creative Commons Attribution-Non Commercial-No Derivatives License 4.0 (CCBY-NC-ND), where it is permissible to download

and share the work provided it is properly cited. The work cannot be changed in any way or used commercially without permission from the journal.

DOI: 10.1097/GOX.0000000000001223

Disclosure: The authors have no financial interest to declare in relation to the content of this article. The Article Processing Charge was paid for by the authors.

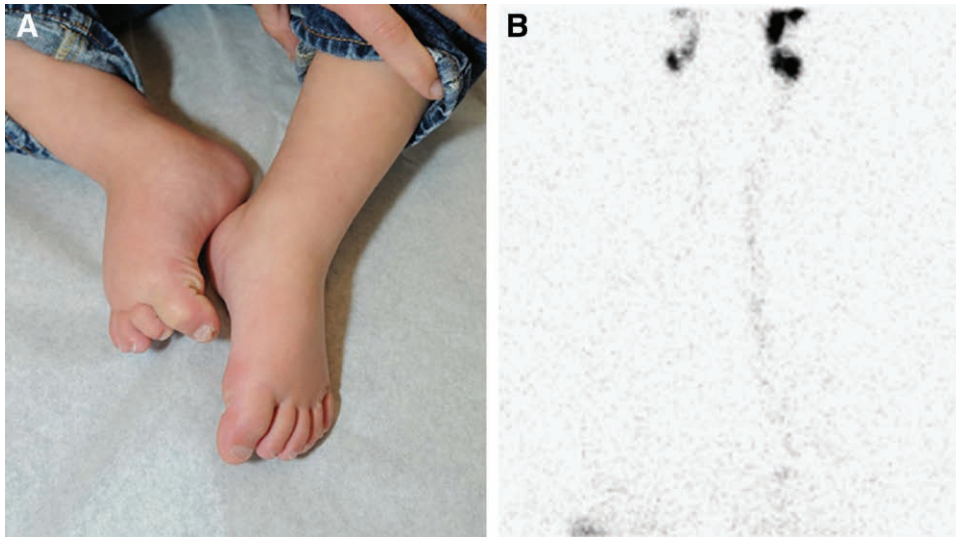


Fig. 2. A, Resolution of right foot swelling at 12 months of age. B, Lymphoscintigram image 30 minutes after injection of radiolabeled tracer into the feet showing tracer uptake in the right inguinal nodes consistent with normal lymphatic dysfunction.

Because the child was an infant, compression treatment was not prescribed, and the patient was re-evaluated at 12 months of age. At that time, his mother noted that the right foot was improved, which was corroborated on physical examination. Repeat lower extremity lymphoscintigraphy showed normal lymphatic function in the right leg (Fig. 2). The findings confirmed the clinical impression that his lymphedema had resolved.

DISCUSSION

Primary lymphedema is a rare, progressive disease of the lymphatic vasculature for which there is no known cure.¹ Over time, the extremities enlarge because of fibroadipose deposition.² We present the first patient with primary lymphedema in our experience of 303 to have spontaneous resolution of the condition. In our literature search, we could only find one other potential case of primary lymphedema that improved; a Pakistani family with a high degree of consanguinity from which 25 subjects, across 5 generations, exhibited congenital-onset, progressive lymphedema confined to the lower limbs, which resolves by 40 to 45 years of age.³ However, these patients did not have lymphoscintigraphy confirming either the presence of lymphedema or its improvement.³

The mechanism for our patient's disease resolution is unclear. He did not receive compression treatment because of his young age, and thus, the lack of compression may have enabled an environment for his lymphatic function to improve. Lymph flow is based on load and clear-

ance. Perhaps the child had normal lymphatic channels, but his lymph production in early infancy overwhelmed his lymphatic system causing an abnormal lymphoscintigram result. As the child grew older, his lymph production may have decreased resulting in a normal repeated study. Alternatively, the patient may have had consistent load but developed increased lymphatic vessel function by lymphangiogenesis or another mechanism. The observation that primary lymphedema has the rare ability to improve during infancy has implications for patient care and provides a potential clue into the pathogenesis of the disease.

Arin K. Greene MD, MMSc

Department of Plastic and Oral Surgery
Boston Children's Hospital
300 Longwood Ave.
Boston, MA 02115

E-mail: arin.greene@childrens.harvard.edu

REFERENCES

1. Schook CC, Mulliken JB, Fishman SJ, Grant FD, Zurakowski D, Greene AK. Primary lymphedema: clinical features and management in 138 pediatric patients. *Plast Reconstr Surg.* 2011;127:2419–31.
2. Brorson H, Ohlin K, Olsson G, et al. Adipose tissue dominates chronic arm lymphedema following breast cancer: an analysis using volume rendered CT images. *Lymphat Res Biol.* 2006;4:199–210.
3. Malik S, Grzeschik KH. Congenital, low penetrance lymphedema of lower limbs maps to chromosome 6q16.2-q22.1 in an inbred Pakistani family. *Hum Genet.* 2008;123:197–205.