



DIGITAL ACCESS TO
SCHOLARSHIP AT HARVARD
DASH.HARVARD.EDU



HARVARD LIBRARY
Office for Scholarly Communication

Pseudomembranous Collagenous Colitis: A Case of Not-so-Microscopic Colitis

The Harvard community has made this
article openly available. [Please share](#) how
this access benefits you. Your story matters

Citation	Grunwald, Douglas, Manisha Mehta, and Sunil G. Sheth. 2016. "Pseudomembranous Collagenous Colitis: A Case of Not-so-Microscopic Colitis." <i>ACG Case Reports Journal</i> 3 (4): e187. doi:10.14309/crj.2016.160. http://dx.doi.org/10.14309/crj.2016.160 .
Published Version	doi:10.14309/crj.2016.160
Citable link	http://nrs.harvard.edu/urn-3:HUL.InstRepos:30371060
Terms of Use	This article was downloaded from Harvard University's DASH repository, and is made available under the terms and conditions applicable to Other Posted Material, as set forth at http://nrs.harvard.edu/urn-3:HUL.InstRepos:dash.current.terms-of-use#LAA

Pseudomembranous Collagenous Colitis: A Case of Not-so-Microscopic Colitis

Douglas Grunwald, MD¹, Manisha Mehta, MD², and Sunil G. Sheth, MD¹

¹Department of Medicine, Division of Gastroenterology, Beth Israel Deaconess Medical Center, Harvard Medical School, Boston, MA

²Department of Pathology, Beth Israel Deaconess Medical Center, Harvard Medical School, Boston, MA

ABSTRACT

We present a 72-year-old male who developed progressive, watery diarrhea despite anti-motility agents. On colonoscopy, the mucosa was inflamed and covered with an exudate. Stool studies for *Clostridium difficile* and *Escherichia coli* were negative. Biopsies revealed pseudomembranous collagenous colitis, a rare form of microscopic colitis. His symptoms improved dramatically with budesonide therapy.

INTRODUCTION

The microscopic colitides are comprised of lymphocytic and collagenous subtypes. Classically, these conditions are associated with normal endoscopic findings. On the other hand, toxin release from *Clostridium difficile* infection, *Escherichia coli* infection, or colonic ischemia can lead to mucosal inflammation and pseudomembrane formation. In rare instances, pseudomembranes may accompany microscopic colitis even in the absence of infection or ischemia. This entity, coined pseudomembranous microscopic colitis, has only been described a handful of times in recent literature.

CASE REPORT

A 72-year-old male presented to our clinic with a chief complaint of diarrhea. We had previously followed him for constipation-predominant irritable bowel syndrome (IBS). His diarrhea began after consumption of seafood, which included raw oysters. About 24 hours after the meal, he experienced forceful, watery, and non-bloody diarrhea associated with mild abdominal cramping, urgency, and flatulence. He was having up to 4 bowel movements each day. He denied nausea, vomiting, fevers, chills, or nocturnal bowel movements. He had no recent travel. He tried taking loperamide, which minimally decreased the frequency of diarrhea.

The patient had a past medical history of IBS, hypothyroidism, and primary progressive multiple sclerosis. He was taking levothyroxine, oxcarbazepine, and aspirin. He had no family history of gastrointestinal illness, colon cancer, or autoimmune disorders. He did not use tobacco, but he did consume 1–2 vodka drinks per day. His diet contained a large amount of fiber from fruits and vegetables.

He had normal vital signs and an abdomen that had normal bowel sounds, was non-tender, non-distended, and tympanic to percussion. Recent labs revealed a normal thyroid-stimulating hormone, complete blood count, electrolytes, lipase, B12, folate, and vitamin D. He had a colonoscopy 1 year prior, which revealed an adenoma. Stool studies for *C. difficile*, *Salmonella*, *Shigella*, *Campylobacter*, *Vibrio*, and ova/parasites were negative. He was given a diagnosis of postinfectious IBS and tried on an anti-motility agent, probiotics, and simethicone gel caps.

ACG Case Rep J 2016;3(4):e187. doi:10.14309/crj.2016.160. Published online: December 21, 2016.

Correspondence: Douglas Grunwald, Division of Gastroenterology, Beth Israel Deaconess Medical Center, 330 Brookline Avenue, Boston, MA 02215-5400 (dgrunwal@bidmc.harvard.edu).



Copyright: © 2016 Grunwald et al. This work is licensed under a Creative Commons Attribution-NonCommercial-NoDerivatives 4.0 International License. To view a copy of this license, visit <http://creativecommons.org/licenses/by-nc-nd/4.0>.

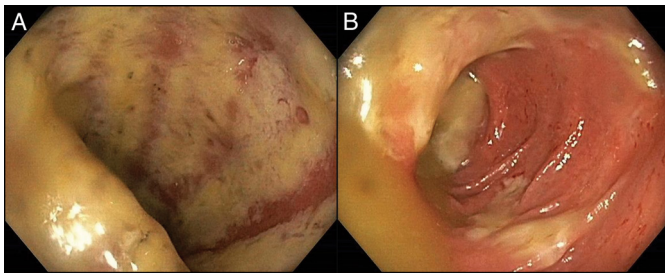


Figure 1. Colonoscopy showing diffuse mucosal erythema, ulceration, and friability with adherent fibrino-purulent exudate.

Despite conservative therapy for 1 month, the patient continued to have watery diarrhea. He took a 2-week course of rifaximin, but this did not provide any relief. About 3 months after his initial presentation, his symptoms worsened, with up to 10 watery stools per day, nocturnal symptoms, and weight loss. He underwent a colonoscopy.

The colonoscopy revealed adherent white exudate and mucus throughout the colon with mildly erythematous underlying mucosa but no ulceration (Figure 1). Multiple biopsy specimens were collected. The biopsies revealed granulation tissue with acute inflammation. Additionally, the mucosa contained a large fibrous band consistent with collagenous colitis (Figure 2). According to the pathologist, the changes were very extensive with considerable loss of surface epithelium and a markedly increased lamina propria inflammatory infiltrate (Figure 3). Due to the fibrinopurulent exudate, repeat stool cultures were sent including *C. difficile*, which again returned negative.

Our patient's symptoms did not respond to anti-diarrheal medications including loperamide. He was started on 9 mg of oral budesonide. Within 2 weeks, his diarrhea had resolved.

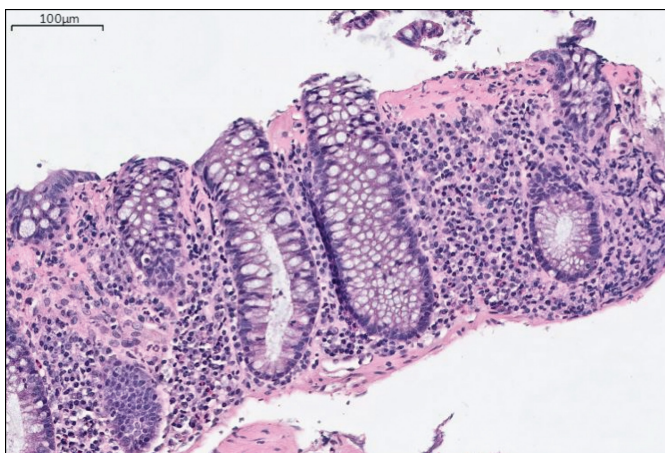


Figure 2. Random colon biopsy showing colonic mucosa with underlying collagen deposition and lymphoplasmacytic infiltration in the lamina propria (hematoxylin and eosin stain, magnification: 100X).

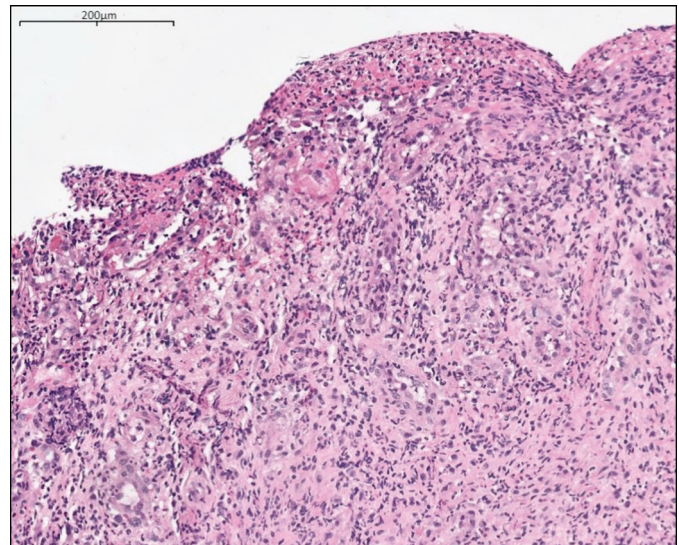


Figure 3. Sigmoid colon tissue fragment showing complete loss of overlying epithelium, and underlying acute and chronic inflammation with granulation tissue (hematoxylin and eosin stain, magnification: 100X).

Over the next 3 months, he was tapered off the budesonide therapy without recurrence of his symptoms.

DISCUSSION

Our patient was diagnosed with a rare variant of microscopic colitis called pseudomembranous collagenous colitis. The classic form of microscopic colitis does not exhibit endoscopic mucosal changes. However, microscopic colitis can have features of acute inflammation, including scattered intraepithelial neutrophils, crypt abscesses, and, rarely, pseudomembranous changes.¹ The endoscopic appearance of collagenous colitis can also show mucosal vascular changes, mucosal abnormalities with red spots, nodularity, and textural alterations, and a continuum of mucosal breaks or defects. These findings have been documented in about 20–34% of patients with microscopic colitis.²

One case series looked at 10 patients with pseudomembranous collagenous colitis. Most patients were middle-aged females who presented with chronic, watery diarrhea. Endoscopically, the colonic mucosa was described as erythematous, granular, and inflamed, suggestive of IBD. The biopsy specimens, however, showed a thickened collagen band underlying pseudomembranes of necrotic debris, fibrin, and detached epithelium.³

Our case shows that active inflammation, including pseudomembrane formation, does not preclude the diagnosis of microscopic colitis. Pseudomembranes are a pattern of injury and may be due to infection, ischemia, and, rarely, collagenous

colitis.⁴ A thorough history, stool studies, and biopsy may be needed to arrive at the correct diagnosis. There is no evidence to suggest that this variant of microscopic colitis is more resistant to standard therapy.^{5,6} Therefore, the recent American Gastroenterological Association guidelines for the treatment of symptomatic microscopic colitis with early budesonide therapy should still be followed.⁷

DISCLOSURES

Author contributions: All authors contributed to the literature search. D. Grunwald wrote the manuscript and is the article guarantor. M. Mehta provided the pathology slides and reviewed the manuscript. S. Sheth edited the manuscript and provided clinical guidance.

Financial disclosure: None to report.

Informed consent was obtained for this case report.

Received May 11, 2016; Accepted September 2, 2016

REFERENCES

1. Buchman AL, Rao S. Pseudomembranous collagenous colitis. *Dig Dis Sci*. 2004;49(11-12):1763-7.
2. Koulaouzidis A, Saeed AA. Distinct colonoscopy findings of microscopic colitis: Not so microscopic after all? *World J Gastroenterol*. 2011;17(37):4157-65.
3. Yuan S, Reyes V, Bronner MP. Pseudomembranous collagenous colitis. *Am J Surg Pathol*. 2003;27(10):1375-9.
4. Tang DM, Urrunaga NH, de Groot H, von Rosenvinge EC, Xie G, Ghazi LJ. Pseudomembranous colitis: Not always caused by clostridium difficile. *Case Rep Med*. 2014;2014:812704.
5. Harpaz N, Fiel MI, Zhang D. Pseudomembranous variant of collagenous colitis. *Dig Endosc*. 2015;27(7):793-4.
6. Khan-Kheil AM, Disney B, Ruban E, Wood G. Pseudomembranous collagenous colitis: An unusual cause of chronic diarrhoea. *BMJ Case Rep*. 2014;2014.
7. Nguyen GC, Smalley WE, Vege SS, Carrasco-labra A. American Gastroenterological Association institute guideline on the medical management of microscopic colitis. *Gastroenterology*. 2016;150(1):242-6.