



DIGITAL ACCESS TO  
SCHOLARSHIP AT HARVARD  
DASH.HARVARD.EDU



HARVARD LIBRARY  
Office for Scholarly Communication

# Evaluation and Treatment of a Ureterosciatic Hernia Causing Hydronephrosis and Renal Colic

The Harvard community has made this article openly available. [Please share](#) how this access benefits you. Your story matters

Citation	Salari, Keyan, Emily M. Yura, Mukesh Harisinghani, and Brian H. Eisner. 2015. "Evaluation and Treatment of a Ureterosciatic Hernia Causing Hydronephrosis and Renal Colic." <i>Journal of Endourology Case Reports</i> 1 (1): 1-2. doi:10.1089/cren.2015.29005.sal. <a href="http://dx.doi.org/10.1089/cren.2015.29005.sal">http://dx.doi.org/10.1089/cren.2015.29005.sal</a> .
Published Version	<a href="https://doi.org/10.1089/cren.2015.29005.sal">doi:10.1089/cren.2015.29005.sal</a>
Citable link	<a href="http://nrs.harvard.edu/urn-3:HUL.InstRepos:29002406">http://nrs.harvard.edu/urn-3:HUL.InstRepos:29002406</a>
Terms of Use	This article was downloaded from Harvard University's DASH repository, and is made available under the terms and conditions applicable to Other Posted Material, as set forth at <a href="http://nrs.harvard.edu/urn-3:HUL.InstRepos:dash.current.terms-of-use#LAA">http://nrs.harvard.edu/urn-3:HUL.InstRepos:dash.current.terms-of-use#LAA</a>

## Evaluation and Treatment of a Ureterosciatic Hernia Causing Hydronephrosis and Renal Colic

Keyan Salari, MD, Emily M. Yura, MD, Mukesh Harisinghani, MD, and Brian H. Eisner, MD

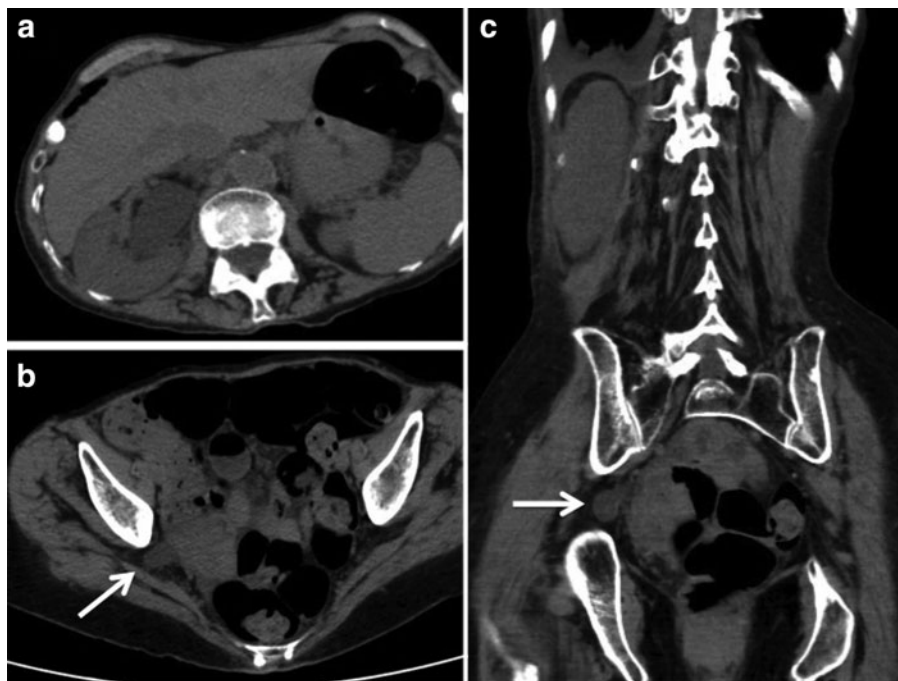
### Abstract

An 87-year-old female presented with complaints of intermittent severe right renal colic. CT imaging demonstrated a ureterosciatic hernia and moderate hydronephrosis proximal to the portion of the ureter that was herniated through the sciatic foramen. A retrograde pyelogram demonstrated a transition point in the ureter at the location of the hernia. A ureteral stent was placed resulting in straightening of the ureter, resolution of hydronephrosis, and complete resolution of the patient's symptoms.

### Clinical History and Physical Examination

URETERAL HERNIATION IS a rare cause of ureteral obstruction and typically involves the inguinal, femoral, and obturator regions.<sup>1</sup> Ureterosciatic hernia (USH) is the rarest form of ureteral herniation, with fewer than 30 cases reported in the literature since 1947.<sup>2</sup> The greater sciatic for-

men is a potential space mostly occupied by the piriformis muscle, and sciatic hernias are thought to principally result from a defect in the parietal pelvic fascia or atrophy of the piriformis muscle. An 87-year-old woman presented with intermittent bothersome right renal colic. The bouts of pain occurred weekly over the 4 months before evaluation and typically lasted 2 to 3 days in duration. Pertinent history included a hysterectomy at

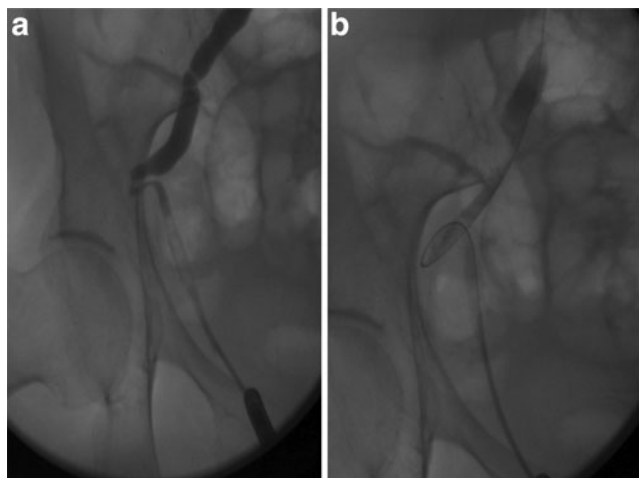


**FIG. 1.** CT scan demonstrating hydronephrosis secondary to herniation of the right ureter into the greater sciatic foramen. (a) Shows hydronephrotic renal pelvis and collecting system and (b, c) demonstrate the dilated ureter within the greater sciatic foramen (marked by *arrow*).

Department of Urology, Massachusetts General Hospital, Harvard Medical School, Boston, Massachusetts.

© Keyan Salari *et al.* 2015; Published by Mary Ann Liebert, Inc. This Open Access article is distributed under the terms of the Creative Commons License (<http://creativecommons.org/licenses/by/4.0>), which permits unrestricted use, distribution, and reproduction in any medium, provided the original work is properly credited.



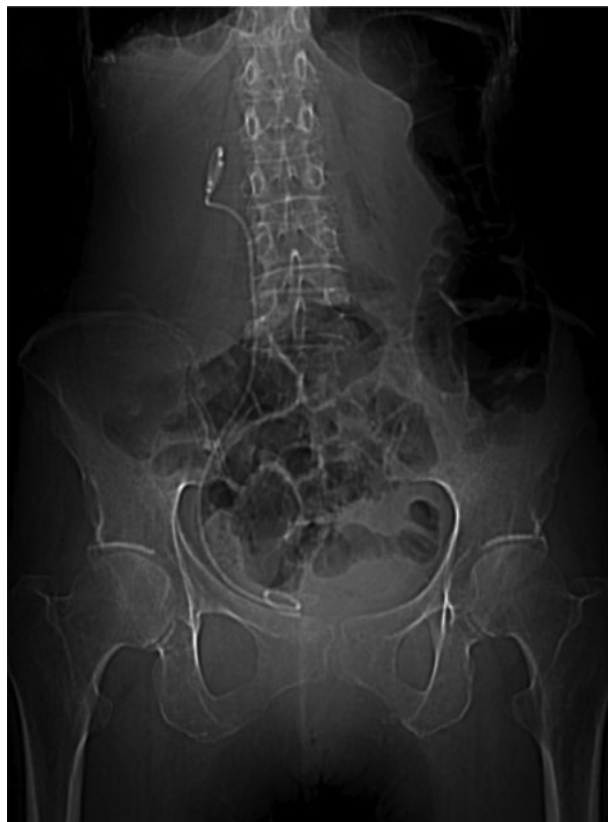

**FIG. 2.** Retrograde pyelogram demonstrating dilation of the ureter proximal to the area of herniation (a) and guidewire bypassing the obstruction and passed into the proximal ureter (b).

age 63 and an exploratory laparotomy with lysis of adhesions for the treatment of a small bowel obstruction at age 84. Physical examination was notable for a body mass index of 14.4 kg/m<sup>2</sup> and was otherwise unremarkable.

#### Diagnostic Studies

Serum electrolytes were normal, and the estimated glomerular filtration rate was >60 mL/minute. A CT scan demonstrated hydronephrosis extending from the portion of the ureter



**FIG. 3.** Plain abdominal radiograph demonstrating a right ureteral stent in proper position and a straightened ureter.

that was herniated through the greater sciatic foramen and extending to the proximal ureter and kidney. Axial and coronal CT images are shown in Figure 1, demonstrating hydronephrosis (Fig. 1a), and a dilated ureter herniated through the greater sciatic foramen marked with a white arrow (Fig. 1b, c).

#### Intervention and Outcome

A retrograde pyelogram was performed in the operating room and a ureteral stent was placed, which straightened the ureter in the hopes of relieving the intermittent obstruction. Retrograde pyelography demonstrating the position of the USH and proximal hydroureteronephrosis is shown in Figure 2a, and placement of a guidewire is shown in Figure 2b. The patient was seen 1 month after stent placement and reported complete resolution of her symptoms. Figure 3 is a plain abdominal radiograph, which demonstrates that ureteral stent placement straightened the ureter and likely has moved the ureter into a more typical position medial to the sciatic foramen. The patient was offered minimally invasive surgical correction, but has chosen to defer definitive treatment in favor of serial stent changes. To date, she has been followed for 1 year since the first stent placement, with two additional stent changes and no recurrence of symptoms.

#### Disclosure Statement

The authors report no conflicts of interest associated with the publication of this case report. B.H.E. is a consultant for Boston Scientific, Bard, Olympus, Cook, Allena Pharmaceuticals, and Retrophin and the owner of the Ravine Group.

#### References

1. Losanoff JE, Basson MD, Gruber SA, Weaver DW. Sciatic hernia: A comprehensive review of the world literature (1900–2008). *Am J Surg* 2010;199:52–59.
2. Loffroy R, Bry J, Guiu B, Dubruille T, Michel F, Cercueil JP, Krause D. Ureterosciatic hernia: A rare cause of ureteral obstruction visualized by multislice helical computed tomography. *Urology* 2007;69:385.e381–383.

Address correspondence to:  
Brian H. Eisner, MD  
Department of Urology  
Massachusetts General Hospital  
Harvard Medical School  
GRB 1102  
55 Fruit Street  
Boston, MA 02114  
E-mail: beisner@partners.org

#### Abbreviations Used

CT = computed tomography  
USH = ureterosciatic hernia

**Cite this article as:** Salari K, Yura EM, Harisinghani M, Eisner BH (2015) Evaluation and treatment of a ureterosciatic hernia causing hydronephrosis and renal colic, *Journal of Endourology Case Reports* 1:1, 1–2, DOI: 10.1089/cren.2015.29005.sal.

