



DIGITAL ACCESS TO
SCHOLARSHIP AT HARVARD
DASH.HARVARD.EDU



HARVARD LIBRARY
Office for Scholarly Communication

Leaflet Area as a Determinant of Tricuspid Regurgitation Severity in Patients With Pulmonary Hypertension

The Harvard community has made this article openly available. [Please share](#) how this access benefits you. Your story matters

Citation	Afilalo, J., J. Grapsa, P. Nihoyannopoulos, J. Beaudoin, J. S. R. Gibbs, R. N. Channick, D. Langleben, et al. 2015. "Leaflet Area as a Determinant of Tricuspid Regurgitation Severity in Patients With Pulmonary Hypertension." <i>Circulation: Cardiovascular Imaging</i> 8 (5) (May 14): e002714–e002714. doi:10.1161/circimaging.114.002714.
Published Version	doi:10.1161/CIRCIMAGING.114.002714
Citable link	http://nrs.harvard.edu/urn-3:HUL.InstRepos:29048898
Terms of Use	This article was downloaded from Harvard University's DASH repository, and is made available under the terms and conditions applicable to Open Access Policy Articles, as set forth at http://nrs.harvard.edu/urn-3:HUL.InstRepos:dash.current.terms-of-use#OAP



Published in final edited form as:

Circ Cardiovasc Imaging. 2015 May ; 8(5): . doi:10.1161/CIRCIMAGING.114.002714.

Leaflet Area as a Determinant of Tricuspid Regurgitation Severity in Patients with Pulmonary Hypertension

Jonathan Afilalo, MD, MSc^{1,5}, Julia Grapsa, MD², Petros Nihoyannopoulos, MD², Jonathan Beaudoin, MD⁵, J. Simon R. Gibbs, MD³, Richard N. Channick, MD⁴, David Langleben, MD¹, Lawrence G. Rudski, MD¹, Lanqi Hua, RDCS⁵, Mark D. Handschumacher, BS⁵, Michael H. Picard, MD⁵, and Robert A. Levine, MD⁵

¹Division of Cardiology, Jewish General Hospital, McGill University, Montreal, Canada

²Cardiac Ultrasound Laboratory, Division of Cardiology, Hammersmith Hospital, Imperial College Healthcare NHS Trust, London, UK

³National Pulmonary Hypertension Service, Division of Cardiology, Hammersmith Hospital, Imperial College Healthcare NHS Trust, London, UK

⁴Pulmonary Hypertension and Thromboendarterectomy Program, Division of Pulmonary and Critical Care Medicine, Massachusetts General Hospital, Harvard University, Boston, MA

⁵Cardiac Ultrasound Laboratory, Division of Cardiology, Massachusetts General Hospital, Harvard University, Boston, MA

Abstract

Background—Tricuspid regurgitation (TR) is a risk factor for mortality in pulmonary hypertension (PH). TR severity varies among patients with comparable degrees of PH and right ventricular (RV) remodeling. The contribution of leaflet adaptation to the pathophysiology of TR has yet to be examined. We hypothesized that tricuspid leaflet area (TLA) is increased in PH, and that its size relative to RV remodeling determines TR severity.

Methods and Results—A prospective cohort of 255 patients with PH from pre- and post-capillary etiologies was assembled from two centers. Patients underwent a 3-D echocardiogram focused on the tricuspid apparatus. TLA was measured with the Omni custom software package. Compared with normal controls, PH patients had a twofold increase in RV volumes, 62% increase in annulus area, and 49% increase in TLA. Those with severe TR demonstrated inadequate increase in TLA relative to the closure area, such that the ratio of TLA-to-closure area <1.78 was highly predictive of severe TR (odds ratio 68.7; 95% CI 16.2, 292.7). The median vena contracta width was 8.5 mm in the group with small TLA and large closure area as opposed to 4.8 mm in the group with large TLA and large closure area.

Correspondence to Jonathan Afilalo MD MSc FASE FACC FRCPC 3755 Cote Ste Catherine, E-222 Montreal, QC H3T 1E2 Phone: (514) 340-8283 Fax: (514) 221-3785 jonathan.afilalo@mcgill.ca

Disclosures

The authors have no conflicts of interest to disclose. They had full access to all the data in the study and take responsibility for the integrity of the data and the accuracy of the analysis.

Conclusions—TLA plays a significant role in determining which patients with PH develop severe functional TR. The ratio of TLA-to-closure area, reflecting the balance between leaflet adaptation vs. annular dilation and tethering forces, is an indicator of TR severity that may identify which patients stand to benefit from leaflet augmentation during tricuspid valve repair.

Keywords

tricuspid regurgitation; pulmonary hypertension; echocardiography

Severe tricuspid regurgitation (TR) develops in 10-30% of patients with pulmonary hypertension (PH) and presages death in 1/3 such patients within one year¹⁻³. Predicting and averting the development of severe TR is problematic since there is substantial variability in who develops severe TR, even after adjusting for pulmonary artery pressure and size of the tricuspid annulus and right ventricle (RV). This uncertainty has been attributed in part to an incomplete understanding of the pathophysiology at hand⁴.

Functional TR, which represents 90% of cases⁵, results from geometric distortions in any of four inter-related components: (1) tricuspid valve leaflets, (2) tricuspid annulus, (3) papillary muscles and chordae, and (4) right ventricular size and shape, including the interventricular septum and left ventricular interactions. To date, the emphasis has primarily been on tricuspid annulus dilation, and secondarily on right ventricular remodeling with papillary muscle displacement leading to tethering⁶.

The contribution of the tricuspid leaflets to the pathophysiology of functional TR has largely been neglected, perhaps owing to the concept that the leaflets should be “normal” in functional valvulopathies, or to inherent challenges in quantitatively measuring leaflet tissue. In prior work, our group developed and validated a technique to measure mitral leaflet area and demonstrated that ventricular dilation was accompanied by mitral leaflet growth so that mitral regurgitation developed when leaflet growth was inadequate to cover the valve closure area⁷.

By defining the 3-D changes in leaflet, annular, ventricular, and tethering geometry using our previously validated approach, the objective of this study was to determine whether tricuspid leaflet surface area (TLA) was correlated with functional TR in a cohort of patients with PH. We hypothesized that TLA is increased in PH, and that its adequacy relative to RV remodeling is a strong determinant of TR severity.

This hypothesis, if correct, would provide the justification and context to investigate the mechanisms of leaflet adaptation⁸ and the use of leaflet augmentation as a therapeutic procedure for functional TR, which is currently a topic of ongoing debate⁹. Although not yet proven, patients with inadequate leaflet adaptation would be expected to benefit more from leaflet augmentation. Echocardiographic research¹⁰ has been instrumental in guiding therapy for TR, leading to: (i) a redesigned tricuspid annuloplasty ring that mimics the natural 3-dimensional saddle-shape of the annulus (MC3, Edwards, Irvine, CA), (ii) guideline recommendations to repair functional TR if the annular dilation exceeds 40 mm^{11,12}, and in some centers, (iii) an adopted practice to perform leaflet augmentation if the tenting distance exceeds 8 mm^{13,14}.

Methods

Study Design

A prospective two-center cohort of patients with PH was assembled. Patients underwent a standardized 2-D and 3-D echocardiographic assessment, with a specific focus on the right heart and tricuspid valve. The dependent variable was severity of TR quantified according to the vena contracta (VC) width¹⁵. TLA was measured offline using the Omni 4D custom software package. The independent variable of interest was the ratio of TLA divided by tricuspid closure area, which reflects the adaptation (i.e. growth) of the valve leaflets to cover the distended and tented systolic closure area and thus maintain valvular competency. Each center's institutional review committee approved the study and patients provided informed consent to be included.

Setting

Patients were identified and recruited from the pulmonary hypertension programs at the Massachusetts General Hospital (Boston, MA) and Hammersmith Hospital (London, UK), both of which are tertiary referral centers for patients with PH. Recruitment at the Massachusetts General Hospital occurred between May 2012 and March 2013. Recruitment at the Hammersmith Hospital occurred between January 2012 and April 2013. Echocardiograms were performed and analyzed in the cardiac ultrasound facilities of the respective hospitals, using the Philips IE33 machine and Xcelera/QLAB workstation (Philips Medical Systems, Andover, MA) at the former, and the GE Vivid 7 machine and EchoPAC workstation (GE, Milwaukee, WI) at the latter.

Participants

Inclusion criteria were: (1) TR velocity ≥ 3.5 meters/second, corresponding to an estimated pulmonary artery systolic pressure (PASP) of ≥ 50 mm Hg, (2) diagnosis of PH confirmed by a cardiologist or pulmonologist within the pulmonary hypertension program. The majority of patients had undergone diagnostic right heart catheterization as part of their initial clinical investigations. Invasive PASP was not re-measured for the purposes of this study, therefore noninvasive PASP was used to identify eligible patients, and those with insufficient TR jet signal to obtain a noninvasive PASP were excluded. Other exclusion criteria were: atrial fibrillation at the time of the echocardiogram, inadequate image quality to visualize the right heart and/or tricuspid valve, pacemaker, and organic TR etiology. All types of PH were eligible, including pre-capillary (pulmonary arterial hypertension, chronic thromboembolic PH) and post-capillary (PH due to left-heart diseases). In addition, measurements of TLA and closure area were obtained in a group of 34 normal controls free of structural heart disease who were referred to the echocardiography lab.

Echocardiographic Protocol

A comprehensive echocardiogram was performed, with special attention to optimize the right heart acquisitions. The RV was imaged from multiple views, including but not limited to the RV inflow view, RV-focused and RV-modified apical 4-chamber views. The TR jet was imaged by color Doppler in the parasternal RV inflow view, parasternal short axis view,

apical 4-chamber view, and subcostal view. In each of these views, the color Doppler baseline was lowered to 28 ± 8 cm/s to optimize the VC appearance. 2-D measures of RV size and function were made according to the American Society of Echocardiography guidelines for the echocardiographic assessment of the right heart¹⁶. All measurements were made at held end-expiration.

The 3-D echocardiographic protocol consisted of 4-beat full volume acquisitions in the RV-focused apical 4-chamber view and the parasternal RV inflow view, and in a subset of patients, 6-beat full volume color Doppler acquisitions in the same two views. A single-beat 3-D zoom was also obtained. The sector depth, sector width, and elevation width were adjusted to focus on the tricuspid valve leaflets throughout the cardiac cycle. For full volume color Doppler acquisitions, a minimum frame rate of 12 per second was required; the number of beats in the full volume acquisition could be increased to obtain a higher frame rate if the R-R intervals were regular. QLAB's multi-plane reconstruction (Philips Medical Systems, Andover, MA) was used to measure VC area, and TomTec's 4-D RV Function (TomTec, Munich, Germany) was used to measure RV volumes.

Measurement of TR Severity

The VC width was measured in duplicate or triplicate (i.e. in 2-3 successive beats) with held end-expiration from the apical 4-chamber and parasternal RV inflow views. To account for the possibility of nonsymmetrical orifices, biplane VC width was calculated by averaging the VC widths from these two roughly orthogonal views. This biplane VC approach has been validated in mitral regurgitation and shown to be closely correlated with regurgitant volume for both circular and elliptical orifices¹⁷. VC width was preserved as a continuous variable, with the exception of descriptive comparisons for which TR by VC width was grouped as mild (<4 mm), moderate (4-7 mm), or severe (≥ 7 mm). The echocardiography specialist's (all level III trained) semi-quantitative assessment of TR severity based on color Doppler jet appearance and hepatic vein reversal was also abstracted from the clinical report. Lastly, TR was assessed by 3-D VC area in a subset of 33 patients during the latter part of the study when a routine full volume color Doppler acquisition was added to the echocardiographic protocol.

3-D VC area was measured as follows: the 3-D full volume color Doppler dataset was opened in the multi-planar reconstruction application, the two orthogonal long-axis planes were aligned parallel to the direction of the proximal TR jet, the short axis plane was aligned perpendicular to the VC (the narrowest neck of the proximal TR jet just below the flow convergence zone), and the resulting short-axis image of the VC was traced to yield VC area. As for the measurements of 2-D VC width, the measurements of 3-D VC area were repeated and averaged in 2-3 successive beats and in both the apical and parasternal datasets.

Measurement of TLA

The 3-D full volume dataset was imported into the Omni custom software package. The open tricuspid leaflets were traced in mid-diastole in multiple planes and reconstructed to obtain the TLA, as previously validated on the mitral valve⁷ (due to overlap of leaflet tissue at the coaptation point, tracing in systole is less accurate, and is affected by systolic leaflet

stretch). The tricuspid closure area was traced in mid-systole as the leaflet area separating the RV and RA necessary to occlude the tricuspid orifice, as required by annular and ventricular tethering. The tricuspid annular area (projected onto its least-squares plane) was also traced in mid-systole. The ratio of TLA divided by tricuspid closure area was the primary predictor variable. A reduction in this ratio represents small valve leaflets relative to a larger annulus and more tented closure area, leading to valvular insufficiency. The observers underwent training sessions for the Omni software at the study onset and were blinded to the TR severity parameters when making leaflet measurements to ensure accuracy and prevent bias. Leaflet measurements were made by a second independent observer in a random subset of patients to calculate the intraclass coefficients (ICC).

Statistical Methods

Continuous variables were presented as medians with their 25th percentile (Q1) and 75th percentile (Q3). Nonparametric Wilcoxon rank-sum tests and Spearman correlations were used for univariate analyses. Linear regression was used for multivariable analysis, testing the primary hypothesis that the ratio of TLA-to-closure area would be inversely related to the TR VC (log transformed due to skewed distribution) after adjusting for covariates. A receiver operating characteristics (ROC) curve was also constructed to identify the optimal cutoff for the ratio of TLA-to-closure area to predict severe TR. No previous studies on TLA were available to guide sample size calculation; however, our previous studies on mitral leaflet adaptation were adequately powered with samples sizes of 80-90 patients^{7,18} such that the projected recruitment of 250 patients over a 1-year span was expected to be sufficient to test this hypothesis. All analyses were performed with the STATA 13 statistical software package (College Station, TX).

Results

The cohort consisted of 164 males and 91 females with a median age of 43.0 years (Q1 36.0, Q3 53.0). The median PASP was 79.0 mm Hg (Q1 65.8, Q3 94.6) and the etiology of PH was evenly distributed between pre-capillary (N=134, 52.5%) and post-capillary causes (N=121, 47.5%). Baseline characteristics stratified by severe vs. non-severe TR are shown in Table 1.

TR severity classified according to the VC width was: mild in 116 (45.5%), moderate in 86 (33.7%), and severe in 53 (20.8%). The distribution was internally consistent with the clinical echocardiographer's report that was: mild in 130 (51.0%), moderate in 76 (29.8%), and severe in 49 (19.2%). Echocardiographic parameters stratified by severity of TR are shown in Table 2. Patients with severe TR were more likely to have increased right atrial volume, increased RV volumes, decreased RV and LV ejection fractions (despite a similar proportion of post-capillary PH etiology). The median PASP did not vary according to the severity of TR.

Compared with healthy controls, patients with PH had a 112% increase in RV enddiastolic volume (median 190.0 mL vs. 89.5 mL, $P<0.001$), a 62% increase in tricuspid annulus area (median 11.2 cm² vs. 6.9 cm², $P<0.001$), and a 49% increase in TLA (median 21.4 cm² vs.

14.4 cm², P<0.001). Those with PH and severe TR had an incremental increase in RV volumes, annulus area, and tenting volume (Figure 1).

Despite the increase in RV volumes and annulus area with worsening TR, there was a slight decrease in TLA from 22.5 cm² in patients with mild TR to 20.6 cm² in patients with severe TR. The ratio of TLA-to-closure area was inversely correlated with the VC width (Figure 2). Specifically, the ratio of TLA-to-closure area was 2.09, 1.87, and 1.34 in patients with mild, moderate, and severe TR, respectively (Spearman's R -0.66, P<0.0001). The area under the ROC curve was 0.93 for the ratio of TLA-to-closure area to predict severe TR, and the optimal cutoff for this ratio was <1.78 (OR 68.7, 95% CI 16.2, 292.7) (Figure 3).

To further define the interplay between closure area and TLA, patients were divided into 4 groups based on the presence of large vs. small (> vs. < median) closure area and TLA (Figure 4). Patients with large closure area (>11.7 cm²) and small TLA (<21.4 cm²) had a markedly greater likelihood of severe TR: median VC width was 8.5 mm in the large closure area-small TLA group (N=48), 4.8 mm in the large closure area-large TLA group (N=83), 3.3 mm in the small closure area-small TLA group (N=76), and 3.0 mm in the small closure area-large TLA group (N=48) (Figure 5).

To determine the independent predictors of TR severity, multivariable linear regression was performed with log transformed VC width as the dependent variable and the following covariates: TLA, closure area, tenting volume, RV end-diastolic volume, PASP, PH etiology, age and sex. As shown in Table 3, the independent predictors of greater TR severity were smaller TLA (coefficient -0.028, 95% CI -0.041, -0.014), larger closure area (coefficient 0.088, 95% CI 0.055, 0.120), larger tenting volume (coefficient 0.298, 95% CI 0.207, 0.390), and pre-capillary etiology (coefficient 0.100, 95% CI 0.038, 0.162).

In the subset of patients with available 3-D VC area, there was a strong correlation between 2-D VC width and 3-D VC area (Spearman R=0.75, P<0.001). Severe TR defined by 2-D VC width \geq 7 mm was discriminated with a high degree of accuracy by 3-D VC area (c-statistic 0.97). Adding treating center as a covariate in the multivariable model did not affect the results. Inter-rater reliability was shown by ICCs of 0.88 and 0.84 for tricuspid leaflet area and closure area, respectively.

Discussion

While previous studies have explored annular and subvalvular geometry as determinants of functional TR, this study now shows that TLA plays a significant role in the pathophysiology. In this prospective cohort of PH patients, RV pressure overload and remodeling was associated with a 49% increase in TLA compared with healthy controls. When TLA was inadequate to cover the closure area, a graded increase in TR severity was observed. The ratio of TLA-to-closure area, reflecting the balance between leaflet adaptation versus annular dilation and tethering geometry, proved to be a strong indicator of functional TR severity.

The pathophysiology of functional TR has been an area of active research over the past 30 years, starting with the finding that annular dilatation was a critical component in its

development¹⁹. Subsequently, it was found that valvular tethering played a major role in the development of functional TR²⁰. The factors leading to valvular tethering were reported in a series of studies: RV spherical remodeling²¹, interventricular septal shift²², left ventricular interactions²³, and RV papillary muscle displacement^{24,25}. This study has added a novel mechanistic component – TLA – to our understanding of the pathophysiology of functional TR.

The current finding is consistent with recent work on leaflet adaptation in functional mitral regurgitation. Compared with normal controls, patients with dilated cardiomyopathy or inferior wall motion abnormality had a 35% increase in mitral leaflet area; however, they often had a greater relative increase in closure area, such that functional mitral regurgitation developed⁷. A ratio of mitral leaflet area to closure area <1.7 predicted significant valvular incompetence, similar to the ratio of <1.78 found in this series of TR. Patients with dilated left ventricles in the context of aortic regurgitation were also found to have a 31% increase in mitral leaflet area, albeit a preserved ratio of mitral leaflet area to closure area such that significant functional mitral regurgitation was very rare¹⁸. Interestingly, the biological mechanism for increased leaflet area was shown in a sheep model in which mechanical leaflet tethering/stress caused by papillary muscle retraction reactivated embryonic pathways for leaflet growth⁸.

Beyond the mechanistic implications, our findings have clinical significance for repair of functional TR (most commonly performed for post-capillary PH etiologies). Despite contemporary practice of tricuspid valve repair with ring annuloplasty, the incidence of residual moderate-to-severe TR is 15-22% within the first month^{26,27} and up to 44% in long-term follow-up²⁸. Since ring annuloplasty only addresses one facet of the problem, annular dilation, it is not surprising to observe that other facets such as RV spherical remodeling and left-sided dysfunction and their resultant tethering effects are the main predictors of recurrent TR. Our findings indicate that inadequate TLA relative to the demand for closure area imparted by tethering may be another important predictor of recurrent TR. Surgical RV reduction by plication of the lateral free wall significantly has been used to address this issue at the subvalvular level in a case-series of 17 patients from Germany²⁹. Tricuspid leaflet augmentation by autologous pericardial patch at the time of tricuspid ring annuloplasty has been used by multiple groups and achieved recurrent TR rates as low as 2%^{13,14,30,31}. Newer patch materials using extracellular matrix scaffolds are also under development for this purpose³². Our approach to quantify leaflet area may be applied to identify which patients could derive the greatest benefit from a leaflet augmentation procedure.

Limitations and future directions. Total TLA was measured, not differential adaptation of individual leaflets. Clinically, however, leaflet augmentation procedures empirically achieve good results targeting the anterior leaflet and sometimes the anterior portion of the posterior leaflet, so this may not alter practice. The Omni custom software package uniquely provides total open TLA independent of systolic stretch; commercial vendors have developed similar products to measure closed leaflet parameters (e.g. QLAB MVQ, Philips Medical Systems, Andover, MA), and could in principle provide open area as well. TR severity was measured at a single point in time; longitudinal progression in TR severity as a function of leaflet adaptation would be of interest in future studies. VC width may vary when the orifice shape

is elliptical³³; to minimize the potential error of using single-plane VC width, biplane VC was measured in orthogonal views¹⁷, and furthermore, validated against 3-D VC area. Lastly, there is significant inherent variability in tricuspid valve anatomy, including but not limited to the leaflets and subvalvular apparatus, such that the mechanism of functional TR is often multifactorial and difficult to predict.

In conclusion, TLA is an important contributor to the development of functional TR. Strengths of this study include a prospective two-center design, measurement of 3-D leaflet area using a specialized software tool which has been validated against explanted valves⁷ and computed tomography³⁴, and gradation of TR severity according to VC, which has been shown to be more accurate and reproducible compared to jet area or visual assessment^{15,35} and the most prognostic indicator of TR severity³⁶. By integrating TLA with annulus area and tenting volume, a more complete understanding of the pathophysiology of functional TR is obtained. Fundamentally, this is represented by a simple ratio of TLA-to-closure area, in which closure area reflects both annular area and tenting. Future studies may advance the utility of these leaflet parameters by demonstrating their ability to select patients in need of patch augmentation or other ancillary procedures at the time of tricuspid valve ring annuloplasty, and correlating the observed changes in TLA with the biological pathways responsible for leaflet proliferation.

Supplementary Material

Refer to Web version on PubMed Central for supplementary material.

Acknowledgments

We would like to thank the cardiac sonographers at the Hammersmith Hospital and Massachusetts General Hospital for their excellence in acquiring the echocardiographic images that made this study possible.

Sources of Funding

Dr. Afilalo holds a Clinical Research Scholars Junior I Career Award from the Fonds de la Recherche en Santé du Québec (FRSQ).

References

1. Nath J, Foster E, Heidenreich PA. Impact of tricuspid regurgitation on long-term survival. *J Am Coll Cardiol*. 2004; 43:405–409. [PubMed: 15013122]
2. Koelling TM, Aaronson KD, Cody RJ, Bach DS, Armstrong WF. Prognostic significance of mitral regurgitation and tricuspid regurgitation in patients with left ventricular systolic dysfunction. *Am Heart J*. 2002; 144:524–529. [PubMed: 12228791]
3. Mutlak D, Aronson D, Lessick J, Reisner SA, Dabbah S, Agmon Y. Functional tricuspid regurgitation in patients with pulmonary hypertension: is pulmonary artery pressure the only determinant of regurgitation severity? *Chest*. 2009; 135:115–121. [PubMed: 18719061]
4. Silver MD, Lam JH, Ranganathan N, Wigle ED. Morphology of the human tricuspid valve. *Circulation*. 1971; 43:333–348. [PubMed: 5544987]
5. Mutlak D, Lessick J, Reisner SA, Aronson D, Dabbah S, Agmon Y. Echocardiography-based spectrum of severe tricuspid regurgitation: the frequency of apparently idiopathic tricuspid regurgitation. *J Am Soc Echocardiogr*. 2007; 20:405–408. [PubMed: 17400120]
6. Topilsky Y, Khanna A, Le Tourneau T, Park S, Michelena H, Suri R, Mahoney DW, Enriquez-Sarano M. Clinical Context and Mechanism of Functional Tricuspid Regurgitation in Patients With

and Without Pulmonary Hypertension. *Circ Cardiovasc Imaging*. 2012; 5:314–323. [PubMed: 22447806]

7. Chaput M, Handschumacher MD, Tournoux F, Hua L, Guerrero JL, Vlahakes GJ, Levine RA. Mitral leaflet adaptation to ventricular remodeling: occurrence and adequacy in patients with functional mitral regurgitation. *Circulation*. 2008; 118:845–852. [PubMed: 18678770]
8. Dal-Bianco JP, Aikawa E, Bischoff J, Guerrero JL, Handschumacher MD, Sullivan S, Johnson B, Titus JS, Iwamoto Y, Wylie-Sears J, Levine RA, Carpentier A. Active adaptation of the tethered mitral valve: insights into a compensatory mechanism for functional mitral regurgitation. *Circulation*. 2009; 120:334–342. [PubMed: 19597052]
9. Shinn SH, Schaff HV. Evidence-based surgical management of acquired tricuspid valve disease. *Nat Rev Cardiol*. 2013; 10:190–203. [PubMed: 23399976]
10. Badano LP, Agricola E, Perez de Isla L, Gianfagna P, Zamorano JL. Evaluation of the tricuspid valve morphology and function by transthoracic real-time three-dimensional echocardiography. *Eur J Echocardiogr*. 2009; 10:477–484. [PubMed: 19482963]
11. Vahanian A, Alfieri O, Andreotti F, Antunes MJ, Barón-Esquivias G, Baumgartner H, Borger MA, Carrel TP, De Bonis M, Evangelista A, Falk V, Iung B, Lancellotti P, Piérard L, Price S, Schäfers H-J, Schuler G, Stepinska J, Swedberg K, Takkenberg J, Opell Von UO, Windecker S, Zamorano JL, Zembala M, ESC Committee for Practice Guidelines (CPG); Bax JJ, Ceconi C, Dean V, Deaton C, Fagard R, Funck-Brentano C, Hasdai D, Hoes A, Kirchhof P, Knuuti J, Kolh P, McDonagh T, Moulin C, Popescu BA, Reiner Z, Sechtem U, Sirnes PA, Tendera M, Torbicki A, Document Reviewers. Segesser Von L, Badano LP, Bunc M, Claeys MJ, Drinkovic N, Filippatos G, Habig G, Kappetein AP, Kassab R, Lip GYH, Moat N, Nickenig G, Otto CM, Pepper J, Piazza N, Pieper PG, Rosenhek R, Shuka N, Schwammenthal E, Schwitter J, Mas PT, Trindade PT, Walther T. Guidelines on the management of valvular heart disease. *Eur Heart J*. 2012; 33:2451–2496. [PubMed: 22922415]
12. Nishimura RA, Otto CM, Bonow RO, Carabello BA, Erwin JP, Guyton RA, O'Gara PT, Ruiz CE, Skubas NJ, Sorajja P, Sundt TM, Thomas JD. 2014 AHA/ACC Guideline for the Management of Patients With Valvular Heart Disease: A Report of the American College of Cardiology/American Heart Association Task Force on Practice Guidelines. *Circulation*. 2014; 129:e521–643. [PubMed: 24589853]
13. Dreyfus GD, Raja SG, John Chan KM. Tricuspid leaflet augmentation to address severe tethering in functional tricuspid regurgitation. *Eur J Cardiothorac Surg*. 2008; 34:908–910. [PubMed: 18693032]
14. Roshanali F, Saidi B, Mandegar MH, Yousefnia MA, Alaeddini F. Echocardiographic approach to the decision-making process for tricuspid valve repair. *J Thorac Cardiovasc Surg*. 2010; 139:1483–1487. [PubMed: 19909984]
15. Tribouilloy CM, Enriquez-Sarano M, Bailey KR, Tajik AJ, Seward JB. Quantification of tricuspid regurgitation by measuring the width of the vena contracta with Doppler color flow imaging: a clinical study. *J Am Coll Cardiol*. 2000; 36:472–478. [PubMed: 10933360]
16. Rudski LG, Lai WW, Afilalo J, Hua L, Handschumacher MD, Chandrasekaran K, Solomon SD, Louie EK, Schiller NB. Guidelines for the echocardiographic assessment of the right heart in adults. *J Am Soc Echocardiogr*. 2010; 23:685–713. quiz 786–8. [PubMed: 20620859]
17. Hall SA, Brickner ME, Willett DL, Irani WN, Afridi I, Grayburn PA. Assessment of mitral regurgitation severity by Doppler color flow mapping of the vena contracta. *Circulation*. 1997; 95:636–642. [PubMed: 9024151]
18. Beaudoin J, Handschumacher MD, Zeng X, Hung J, Morris EL, Levine RA, Schwammenthal E. Mitral valve enlargement in chronic aortic regurgitation as a compensatory mechanism to prevent functional mitral regurgitation in the dilated left ventricle. *J Am Coll Cardiol*. 2013; 61:1809–1816. [PubMed: 23500248]
19. Ubago JL, Figueroa A, Ochoteco A, Colman T, Duran RM, Duran CG. Analysis of the amount of tricuspid valve anular dilatation required to produce functional tricuspid regurgitation. *Am J Cardiol*. 1983; 52:155–158. [PubMed: 6858904]
20. Schwammenthal E, Vazquez de Prada JA, Weyman AE, Levine RA. Determinants of functional tricuspid regurgitation in incomplete tricuspid valve closure: Doppler color flow study of 109 patients. *J Am Coll Cardiol*. 1994; 24:446–453. [PubMed: 8034882]

21. Kim H-K, Kim Y-J, Park J-S, Kim KH, Kim K-B, Ahn H, Sohn D-W, Oh B-H, Park Y-B, Choi Y-S. Determinants of the severity of functional tricuspid regurgitation. *Am J Cardiol.* 2006; 98:236–242. [PubMed: 16828600]
22. Marcus JT, Gan CT-J, Zwanenburg JJM, Boonstra A, Allaart CP, Götte MJW, Vonk-Noordegraaf A. Interventricular mechanical asynchrony in pulmonary arterial hypertension: left-to-right delay in peak shortening is related to right ventricular overload and left ventricular underfilling. *J Am Coll Cardiol.* 2008; 51:750–757. [PubMed: 18279740]
23. Fukuda S, Gillinov AM, Song J-M, Daimon M, Kongsarepong V, Thomas JD, Shiota T. Echocardiographic insights into atrial and ventricular mechanisms of functional tricuspid regurgitation. *Am Heart J.* 2006; 152:1208–1214. [PubMed: 17161077]
24. Spinner EM, Shannon P, Buice D, Jimenez JH, Veledar E, del Nido PJ, Adams DH, Yoganathan AP. In vitro characterization of the mechanisms responsible for functional tricuspid regurgitation. *Circulation.* 2011; 124:920–929. [PubMed: 21810662]
25. Spinner EM, Lerakis S, Higginson J, Pernetz M, Howell S, Veledar E, Yoganathan AP. Correlates of tricuspid regurgitation as determined by 3D echocardiography: pulmonary arterial pressure, ventricle geometry, annular dilatation, and papillary muscle displacement. *Circ Cardiovasc Imaging.* 2012; 5:43–50. [PubMed: 22109981]
26. McCarthy PM, Bhudia SK, Rajeswaran J, Hoercher KJ, Lytle BW, Cosgrove DM, Blackstone EH. Tricuspid valve repair: durability and risk factors for failure. *J Thorac Cardiovasc Surg.* 2004; 127:674–685. [PubMed: 15001895]
27. Fukuda S, Song J-M, Gillinov AM, McCarthy PM, Daimon M, Kongsarepong V, Thomas JD, Shiota T. Tricuspid valve tethering predicts residual tricuspid regurgitation after tricuspid annuloplasty. *Circulation.* 2005; 111:975–979. [PubMed: 15710756]
28. Matsunaga A, Duran CMG. Progression of tricuspid regurgitation after repaired functional ischemic mitral regurgitation. *Circulation.* 2005; 112:1453–7. [PubMed: 16159862]
29. Ouda A, Matschke K, Ghazy T, Speiser U, Alexiou K, Tugtekin S-M, Schoen S, Kappert U. Right ventricular reduction for repair of functional tricuspid valve regurgitation: one-year follow up. *J Heart Valve Dis.* 2013; 22:754–761. [PubMed: 24383394]
30. Choi JB, Kim NY, Kim KH, Kim MH, Jo JK. Tricuspid leaflet augmentation to eliminate residual regurgitation in severe functional tricuspid regurgitation. *Ann Thorac Surg.* 2011; 92:e131–3. [PubMed: 22115272]
31. Solinas M, Bianchi G, Glauber M. An easy and reproducible technique to address tricuspid valve regurgitation with patch augmentation. *J Card Surg.* 2013; 28:638–640. [PubMed: 23844626]
32. Myers PO, Kalangos A. Patch augmentation for tricuspid valve tethering. *J Card Surg.* 2013; 28:730. [PubMed: 24102944]
33. Song J-M, Jang M-K, Choi Y-S, Kim Y-J, Min S-Y, Kim D-H, Kang D-H, Song J-K. The vena contracta in functional tricuspid regurgitation: a real-time three-dimensional color Doppler echocardiography study. *J Am Soc Echocardiogr.* 2011; 24:663–670. [PubMed: 21324644]
34. Beaudoin J, Thai W-E, Wai B, Handschumacher MD, Levine RA, Truong QA. Assessment of mitral valve adaptation with gated cardiac computed tomography: validation with three-dimensional echocardiography and mechanistic insight to functional mitral regurgitation. *Circ Cardiovasc Imaging.* 2013; 6:784–789. [PubMed: 23873402]
35. Topilsky Y, Tribouilloy C, Michelena HI, Pislaru S, Mahoney DW, Enriquez-Sarano M. Pathophysiology of tricuspid regurgitation: quantitative Doppler echocardiographic assessment of respiratory dependence. *Circulation.* 2010; 122:1505–1513. [PubMed: 20876436]
36. Yang W-I, Shim C-Y, Kang M-K, Chang H-J, Chung N, Cho S-Y, Ha J-W. Vena contracta width as a predictor of adverse outcomes in patients with severe isolated tricuspid regurgitation. *J Am Soc Echocardiogr.* 2011; 24:1013–1019. [PubMed: 21820277]

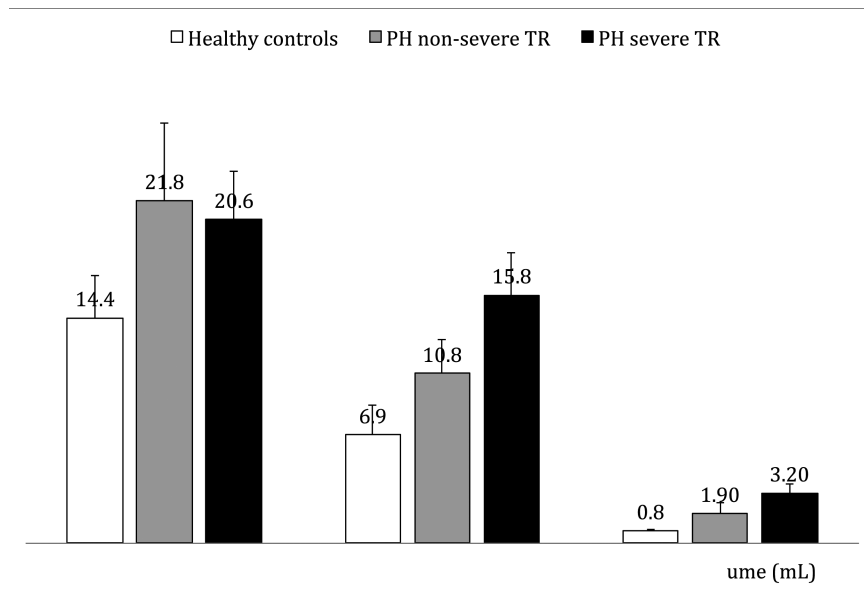


Figure 1. Tricuspid Leaflet Area, Annulus Area, and Tenting Volume in Three Groups Compared with healthy controls, PH patients had greater median tricuspid leaflet area (TLA), annulus area, and tenting volume. Although TLA was similar in PH patients with severe TR and non-severe TR, annulus area was significantly larger in those with severe TR such that the ratio of TLA-to-annulus area was insufficient to maintain valvular competency. Sensitivity analysis showed that these results were not unduly influenced by outlier values.

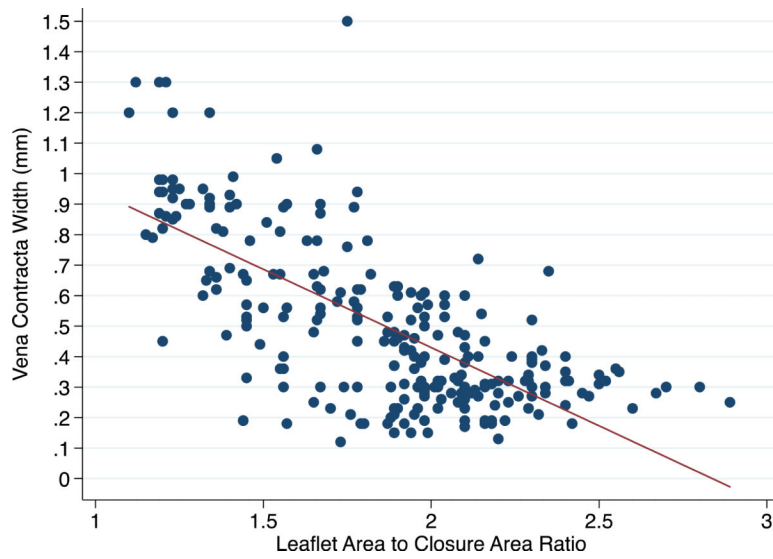


Figure 2. Leaflet Area-to-Closure Area Ratio Is Correlated with Severity of TR
The tricuspid leaflet area (TLA)-to-annulus area ratio was found to be inversely correlated with the severity of TR as measured by vena contracta width ($R=-0.66$, $P<0.0001$).

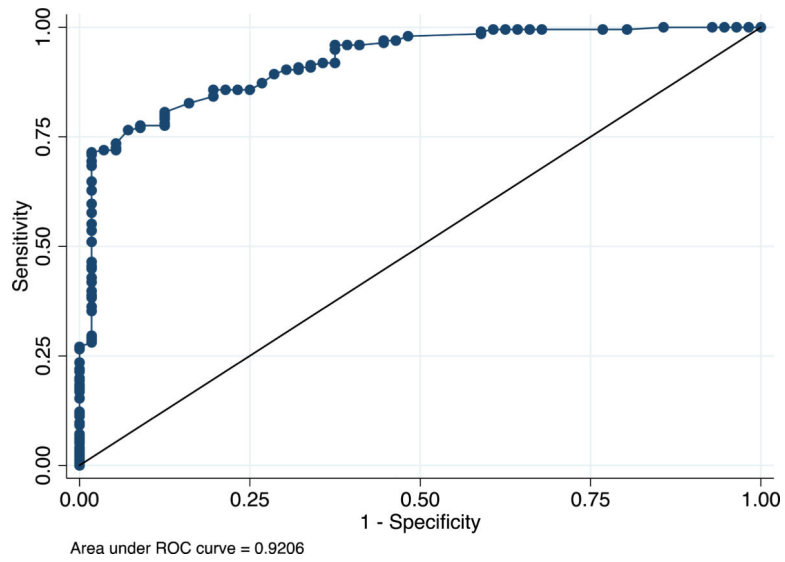


Figure 3. Leaflet Area-to-Closure Area Ratio Discriminates Severe TR (ROC Curve)
Receiver operating characteristic (ROC) analysis showing that the tricuspid leaflet area (TLA)-to-annulus area ratio discriminated between PH patients with vs. without severe TR (odds ratio 68.7, 95% confidence interval 16.2, 292.7), with an area under the ROC curve of 0.9206 and an optimal cutoff value of 1.78.

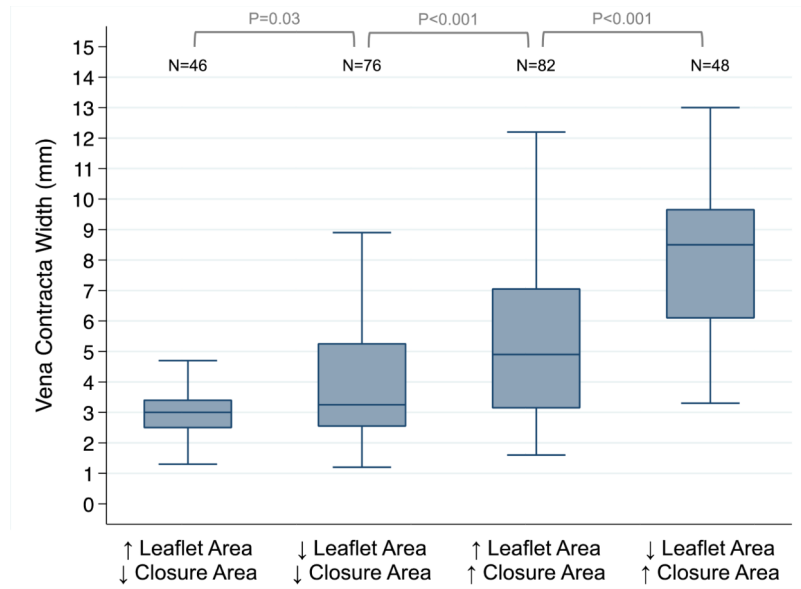


Figure 4. TR Severity as a Function of Leaflet Area and Closure Area < or > Median
 PH patients with large tricuspid leaflet area (TLA) and small closure area had the least TR (far left), while those with small TLA and large closure area had the most TR (far right).

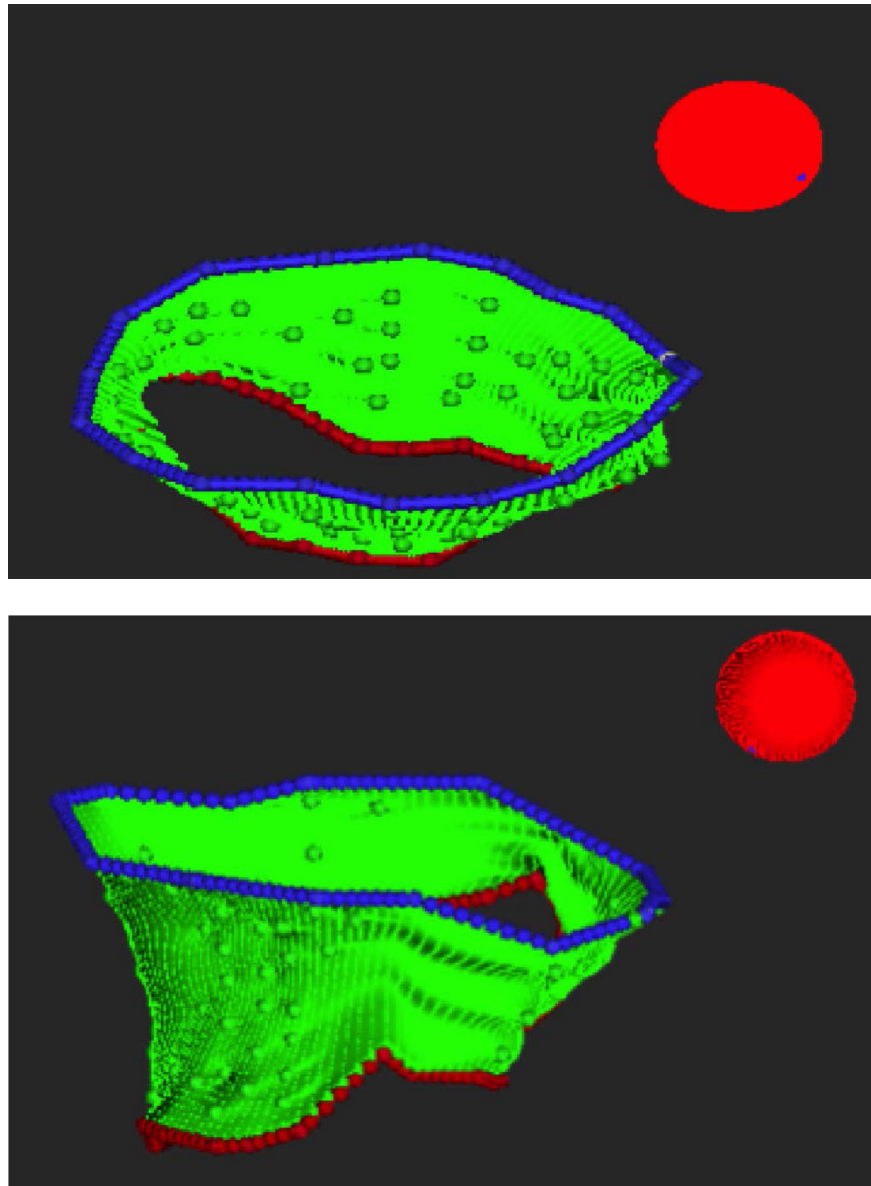


Figure 5. Three-Dimensional Renderings of Open Tricuspid Leaflet Area

Demonstrative renderings of the tricuspid leaflet complex used to calculate tricuspid leaflet area (TAL). To generate these 3-D models, the tricuspid leaflets were manually traced in the open position on successive rotational long-axis planes and then reconstructed using the Omni4D statistical software package.

Table 1

Clinical Characteristics of PH Patients

	Severe TR (n=53)	Non-severe TR (n=202)	P-value
Age, median (Q1, Q3)	45.0 (34.0, 58.0)	43.0 (37.0, 52.0)	0.84
Female sex	17 (32.1)	74 (36.6)	0.63
Coronary artery disease	6 (11.3)	12 (5.9)	0.22
Diabetes	13 (24.5)	43 (21.3)	0.58
Pulmonary embolism	6 (10.3)	11 (5.5)	0.13
Chronic kidney disease	5 (9.4)	16 (7.9)	0.78
NYHA III-IV	45 (84.9)	149 (73.8)	0.24
PH etiology			0.09
Pre-capillary	33 (62.3)	101 (50.0)	
Post-capillary	20 (37.7)	101 (50.0)	
PH therapy			0.50
None	7 (13.2)	22 (10.9)	
PDE5 inhibitor	15 (28.3)	51 (25.3)	
Endothelin antagonist	15 (28.3)	79 (39.1)	
Prostacyclin	16 (30.2)	50 (24.8)	

Abbreviations: Q1, quartile 1; Q3, quartile 3; TR, tricuspid regurgitation; NYHA, New York Heart Association; PH, pulmonary hypertension; PDE5, phosphodiesterase-5. Severe TR defined as average vena contracta width ≥ 7 mm, non-severe TR defined as <7 mm.

Table 2

Echocardiography Parameters of PH Patients

	Severe TR (n=53)	Non-severe TR (n=202)	P-value
2-D vena contracta width, mm	9.0 (8.4, 9.8)	3.4 (2.7, 5.2)	<0.001
3-D vena contracta area, cm ²	0.67 (0.59, 0.85)	0.28 (0.20, 0.41)	<0.001
PASP, mm Hg	79.0 (69.0, 94.0)	80.0 (64.8, 94.6)	0.81
RA volume, mL	183.5 (132.5, 220.0)	135.0 (98.0, 187.0)	0.001
RV end-diastolic volume, mL	205.0 (189.0, 256.0)	187.0 (152.0, 218.5)	0.001
RV end-systolic volume, mL	146.0 (123.0, 189.0)	122.0 (89.5, 166.5)	<0.001
RV stroke volume, mL	57.5 (50.0, 69.0)	57.0 (43.5, 72.0)	0.56
RV ejection fraction, %	27.5 (23.0, 34.5)	32.0 (23.0, 41.0)	0.07
LV ejection fraction, %	48.0 (33.0, 64.0)	68.5 (62.0, 74.0)	0.04
Leaflet area, cm	20.6 (18.9, 23.1)	21.8 (18.4, 25.4)	0.17
Closure area, cm	15.6 (13.5, 16.8)	10.9 (9.8, 12.4)	<0.001
Annulus area, cm	15.8 (13.2, 16.8)	10.8 (9.4, 12.1)	<0.001
Leaflet area-to-closure area ratio	1.34 (1.22, 1.56)	1.98 (1.78, 2.16)	<0.001
Leaflet area-to-annular area ratio	1.36 (1.24, 1.60)	2.04 (1.70, 2.36)	<0.001
Tenting volume, cm ³	3.2 (2.9, 3.4)	1.9 (1.5, 2.3)	<0.001

Abbreviations: TR, tricuspid regurgitation; PISA, proximal isovelocity surface area; ERO, effective regurgitant orifice; PASP, pulmonary artery systolic pressure; RA, right atrium RV, right ventricle; LV, left ventricle. Severe TR defined as average vena contracta width \geq 7 mm, non-severe TR defined as $<$ 7 mm.

Table 3

Linear Regression to Predict TR Vena Contracta (Log)

	Univariable Analysis			Multivariable Analysis		
	Coefficient	95% CI	P-value	Coefficient	95% CI	P-value
Leaflet area, per cm	-0.010	(-0.025, 0.005)	0.18	-0.036	(-0.048, -0.024)	<0.001
Closure area, per cm	0.117	(0.097, 0.137)	<0.001	0.116	(0.208, 0.389)	<0.001
Tenting volume, per cm	0.384	(0.314, 0.453)	<0.001	0.298	(-0.001, 0.000)	<0.001
RV end-diastolic volume, per mL	0.002	(0.0004, 0.003)	0.01	-0.0003	(-0.001, 0.003)	0.41
PASP, per mm Hg	0.002	(-0.001, 0.005)	0.30	0.0008	(-0.219, -0.049)	0.42
Age, per year	-0.001	(-0.006, 0.003)	0.57	-0.003	(0.092, 0.141)	0.14
Female	-0.030	(-0.170, 0.111)	0.68	-0.026	(-0.006, 0.001)	0.57
Pre-capillary etiology	0.315	(0.260, 0.370)	<0.001	0.134	(-0.116, 0.064)	0.002

Abbreviations: PASP, pulmonary artery systolic pressure; RV, right ventricle.