



Is Varicella Zoster Virus an Etiologic Factor in Kawasaki Disease? A Case Report and Review of the Literature

The Harvard community has made this article openly available. [Please share](#) how this access benefits you. Your story matters

Citation	Toprak, Demet, Özge Serçe, Özden Türel, Serkan Atici, Ahmet Soysal, and Mustafa Bakir. 2015. "Is Varicella Zoster Virus an Etiologic Factor in Kawasaki Disease? A Case Report and Review of the Literature." <i>Global Pediatric Health</i> 2 (1): 2333794X14567194. doi:10.1177/2333794X14567194. http://dx.doi.org/10.1177/2333794X14567194 .
Published Version	doi:10.1177/2333794X14567194
Citable link	http://nrs.harvard.edu/urn-3:HUL.InstRepos:27662189
Terms of Use	This article was downloaded from Harvard University's DASH repository, and is made available under the terms and conditions applicable to Other Posted Material, as set forth at http://nrs.harvard.edu/urn-3:HUL.InstRepos:dash.current.terms-of-use#LAA

Is Varicella Zoster Virus an Etiologic Factor in Kawasaki Disease? A Case Report and Review of the Literature

Global Pediatric Health
January-December 2015: 1–2
© The Author(s) 2015
DOI: 10.1177/2333794X14567194
gph.sagepub.com
SAGE

Demet Toprak, MD¹, Özge Serçe, MD², Özden Türel, MD³, Serkan Atici, MD⁴, Ahmet Soysal, MD⁴, and Mustafa Bakir, MD⁴

Introduction

Kawasaki disease (KD), also known as mucocutaneous lymph node syndrome, was first described by Tomisaki Kawasaki in 1967.¹ KD is markedly more prevalent in Japan and in children of Japanese ancestry, with an annual incidence of ~112 cases per 100 000 children less than 5 years of age. In the United States, 4248 hospitalizations associated with KD occurred in 2000, with a median age of 2 years. KD is more common during the winter and early spring months, and 76% of children are <5 years old.

Infectious agents may be implicated either as triggering causes or as additional factors that could aggravate the immune response. Further investigation of infectious agents such as varicella zoster virus could provide a useful clue for the etiology of KD, although the mechanisms of pathogenesis are still unclear.

Herein we report a pediatric case who developed KD and fulfilled all the criteria for the diagnosis of KD. The diagnosis of varicella infection was made by serological and pathological evidence.

Case Report

We present a 2-year-old girl with a 5-day history of high fever and a 2-day history of maculopapular rash on the flexors of bilateral hands and feet. Physical exam of the girl revealed unilateral cervical lymphadenopathy, dry red lips, a red strawberry tongue, enlarged tonsils with exudates, and bilateral bulbar conjunctivitis (Figure 1). Her parents also described vesiculopustular lesions for presumed chickenpox approximately 3 to 4 weeks prior to this presentation, which had healed at the time of presentation.

The patient was consulted to Pediatric Infectious Diseases for a differential of her clinical presentation. Workup revealed erythrocyte sedimentation rate (ESR) of 106 mm/h, C-reactive protein (CRP) 77 mg/L (0–5 mg/L), white blood count of 17 800/mm³, normal hemoglobin and thrombocyte count, alanine aminotransferase 179 IU/L, aspartate aminotransferase 92 IU/L. Group A

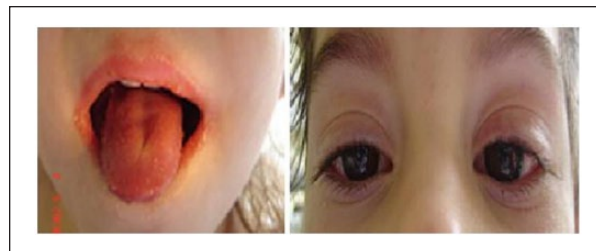


Figure 1. Strawberry tongue, injected fissured lips, and bulbar conjunctivitis all secondary to Kawasaki disease in the patient.

beta-hemolytic *Streptococcus* was negative on her throat culture. Anti-cytomegalovirus IgM and monospot tests were negative, whereas varicella IgM was found to be positive. The echocardiogram of the cardiac coronary vessels was normal.

Since our patient fulfilled all the criteria for KD, she received a single dose of intravenous immunoglobulin (IVIG; 2 g/kg) and was started on oral acetylsalicylic acid at 100 mg/kg/day. She became afebrile after the first dose of IVIG, and fever did not recur. She was discharged home on the fifth day of hospital admission. Desquamation of the fingers and toes began in the periungual region within 2 weeks after the onset of fever. Her follow-up laboratory values were as follows on the third week after the onset of fever: alanine aminotransferase 31 IU/L, aspartate aminotransferase 51 IU/L,

¹Department of Medicine, Harvard Medical School, Boston Children's Hospital, Boston, MA, USA

²Department of Pediatrics, Izmit Seka Hospital, Kocaeli, Turkey

³Department of Pediatrics, Bezmialem Vakif University, Istanbul, Turkey

⁴School of Medicine, Department of Pediatrics, Division of Pediatric Infectious Diseases, Marmara University, Istanbul, Turkey

Corresponding Author:

Demet Toprak, Boston Children's Hospital, 300 Longwood Avenue, Boston, MA 02115, USA.

Email: Demet.Toprak@childrens.harvard.edu; demettoprak@yahoo.com



white cell count $10\ 800/\text{mm}^3$, thrombocyte count $926\ 000/\text{mm}^3$, ESR 65 mm/h, and CRP was negative.

Discussion

The diagnosis of KD is confirmed by the presence of fever for at least 5 days, lack of another known disease process to explain the illness, and of 4 or more criteria of the followings²:

1. Bilateral bulbar conjunctivitis
2. Changes of the mucous membranes and the upper respiratory tract such as injected pharynx, injected fissured lips, strawberry tongue
3. Polymorphous rash
4. Changes of the extremities such as peripheral edema, peripheral erythema, periungual desquamation
5. Cervical adenopathy

The etiology of KD is still unknown, although an infectious agent is suspected because of the associated symptoms. The hypothesis that infectious toxins acting as superantigens could trigger the cascade of events that lead to KD has been widely debated.² Some studies support the suspicion that an infectious agent such as varicella zoster virus can be a trigger in genetically susceptible individuals and cause KD. Studies assessing a more comprehensive range of environmental exposures are in progress.³ Many of the clinical features may show similarity to those of other infectious diseases, such as adenovirus and scarlet fever.⁴ Many infectious and environmental agents have been described in association with KD, including mumps, *streptococci*, *Propionibacterium acnes*, adenovirus, retroviruses, rickettsiae, and dust mites, but none of these have been consistent in children.^{4,5} Between 1998 and 2010, a total of 5 studies were published in the PubMed database for KD associated with varicella infection.⁵⁻⁹ Ogboli et al⁵ and Kuijpers et al⁶ described the association of KD with varicella zoster virus infection with a concomitant presentation. Lee and Huang⁷ reported KD in 2 siblings soon after a primary infection by varicella zoster virus, which resembled our case. Kossiva et al⁸ described KD

in a patient who manifested with chicken pox and myocardial infarction. Besides these, Turkay et al⁹ also reported the association of KD with varicella zoster and Epstein–Barr virus.

Declaration of Conflicting Interests

The author(s) declared no potential conflicts of interest with respect to the research, authorship, and/or publication of this article.

Funding

The author(s) received no financial support for the research, authorship, and/or publication of this article.

References

1. Newburger JW, Takahashi M, Gerber MA, et al. Diagnosis, treatment and long-term management of Kawasaki disease: a statement for health professionals from the Committee on Rheumatic Fever, Endocarditis, and Kawasaki Disease, Council on Cardiovascular Disease in the Young, American Heart Association. *Pediatrics*. 2004;114:1708-1733.
2. Burns JC, Glode Mary P. Kawasaki syndrome. *Lancet*. 2004;364:533-544.
3. Masood S, Manlhiot C, Chahal C, Yeung R, McCrindle B. Environmental exposures and Kawasaki disease: the infectious trigger hypothesis. *Pediatr Int*. 2012;54(P-6):63-135.
4. Jaggi P, Leber A, Ramilo O, Mejias A. Can adenovirus (AdV) PCR values help distinguish acute adenoviral disease from Kawasaki disease (KD) with AdV infection? *Pediatr Int*. 2012;54(P-110):63-135.
5. Ogboli MI, Parslew R, Verbow J, Smyth R. Kawasaki disease associated with varicella: a rare association. *Br J Dermatol*. 1999;141:1145-1146.
6. Kuijpers TW, Tija KL, de Jager F, Peters M, Lam J. A boy with chickenpox whose fingers peeled. *Lancet*. 1998;351:1782.
7. Lee DH, Huang HP. Kawasaki disease associated with chickenpox: report of two sibling cases. *Acta Paediatr Taiwan*. 2004;45(2):94-96.
8. Kossiva L, Papadopoulos M, Lagona E, Papadopoulou S G, Athanassaki C. Myocardial infarction in a 35-day-old infant with incomplete Kawasaki disease and chicken pox. *Cardiol Young*. 2010;20:567-570.
9. Turkay S, Odemis E, Karadag A. Kawasaki disease onset during concomitant infections with varicella zoster and Epstein–Barr virus. *J Natl Med Assoc*. 2006;98:1350-1352.