



DIGITAL ACCESS TO
SCHOLARSHIP AT HARVARD
DASH.HARVARD.EDU



HARVARD LIBRARY
Office for Scholarly Communication

Genetic contributions to changes of fiber tracts of ventral visual stream in 22q11.2 deletion syndrome

The Harvard community has made this article openly available. [Please share](#) how this access benefits you. Your story matters

Citation	Kikinis, Zora, Nikos Makris, Christine T. Finn, Sylvain Bouix, Diandra Lucia, Michael J. Coleman, Erica Tworog-Dube, et al. 2013. "Genetic Contributions to Changes of Fiber Tracts of Ventral Visual Stream in 22q11.2 Deletion Syndrome." <i>Brain Imaging and Behavior</i> 7 (3) (April 24): 316–325. doi:10.1007/s11682-013-9232-5.
Published Version	doi:10.1007/s11682-013-9232-5
Citable link	http://nrs.harvard.edu/urn-3:HUL.InstRepos:28539566
Terms of Use	This article was downloaded from Harvard University's DASH repository, and is made available under the terms and conditions applicable to Other Posted Material, as set forth at http://nrs.harvard.edu/urn-3:HUL.InstRepos:dash.current.terms-of-use#LAA



Published in final edited form as:

Brain Imaging Behav. 2013 September ; 7(3): . doi:10.1007/s11682-013-9232-5.

Genetic Contributions to Changes of Fiber Tracts of Ventral Visual Stream in 22q11.2 Deletion Syndrome

Zora Kikinis^{1,*}, Nikos Makris^{1,2}, Christine T. Finn³, Sylvain Bouix¹, Diandra Lucia¹, Michael J. Coleman¹, Erica Tworog-Dube⁴, Ron Kikinis⁵, Raju Kucherlapati⁶, Martha E. Shenton^{1,5,7}, and Marek Kubicki^{1,7}

¹Psychiatry Neuroimaging Laboratory, Department of Psychiatry, Brigham and Women's Hospital, Harvard Medical School, Boston, MA

²Psychiatry and Neurology Departments, Massachusetts General Hospital, Harvard Medical School, Boston, MA

³Department of Psychiatry, Dartmouth Hitchcock Medical Center, Lebanon, NH

⁴Department of Medicine, Brigham and Women's Hospital, Harvard Medical School, Boston, MA

⁵Surgical Planning Laboratory, Department of Radiology, Brigham and Women's Hospital, Harvard Medical School, Boston, MA

⁶Department of Genetics, Harvard Medical School, Boston, MA

⁷Clinical Neuroscience Division, Laboratory of Neuroscience, Department of Psychiatry, VA Boston Healthcare System, Harvard Medical School Brockton, MA

Abstract

Patients with 22q11.2 deletion syndrome (22q11.2DS) represent a population at high risk for developing schizophrenia, as well as learning disabilities. Deficits in visuo-spatial memory are thought to underlie some of the cognitive disabilities. Neuronal substrates of visuo-spatial memory include the inferior fronto-occipital fasciculus (IFOF) and the inferior longitudinal fasciculus (ILF), two tracts that comprise the ventral visual stream. Diffusion Tensor Magnetic Resonance Imaging (DT-MRI) is an established method to evaluate white matter (WM) connections *in vivo*.

DT-MRI scans of nine 22q11.2DS young adults and nine matched healthy subjects were acquired. Tractography of the IFOF and the ILF was performed. DT-MRI indices, including Fractional anisotropy (FA) (measure of WM changes), axial diffusivity (AD, measure of axonal changes) and radial diffusivity (RD, measure of myelin changes) of each of the tracts and each group were measured and compared.

The 22q11.2DS group showed statistically significant reductions of FA in IFOF in the left hemisphere. Additionally, reductions of AD were found in the IFOF and the ILF in both hemispheres. These findings might be the consequence of axonal changes, which is possibly due to fewer, thinner, or less organized fibers. No changes in RD were detected in any of the tracts delineated, which is in contrast to findings in schizophrenia patients where increases in RD are believed to be indicative of demyelination.

* to whom correspondence should be addressed to: Psychiatry Neuroimaging Laboratory, Department of Psychiatry, Brigham and Women's Hospital, 1249 Boylston Street, Boston, MA 02115; phone: +1-617-525-6116, FAX : +1-617-525-6150, zora@bwh.harvard.edu.

Conflict of interest

The authors declare that they have no conflict of interest.

We conclude that reduced axonal changes may be key to understanding the underlying pathology of WM leading to the visuo-spatial phenotype in 22q11.2DS.

Keywords

22q11.2 deletion syndrome (22q11.2DS,CFS); Diffusion Tensor MRI (DT-MRI); fractional anisotropy (FA); axial diffusivity (AD); inferior fronto-occipital fasciculus (IFOF); inferior longitudinal fasciculus (ILF); high-risk schizophrenia

1. Introduction

22q11.2 DS, also known as velo-cardio-facial syndrome (VCFS) or DiGeorge syndrome (Shprintzen, 2008), is one of the most prominent developmental genetic human syndromes. It is characterized by a deletion of 30–45 genes on one of the arms of chromosome 22 (Driscoll et al., 1992; Scambler et al., 1992). Cognitive deficits figure prominently in patients with 22q11.2DS, and, in particular, impaired visuo-spatial abilities (Bearden et al., 2001) are one of the most frequent abnormalities observed in this syndrome.

In healthy human once visual stimuli activate primary visual cortex, located in the proximity of the calcarine sulcus in the occipital cortex, information is immediately distributed within the occipital lobe, and into other areas of neocortex. While the morphologic organization of this distribution in humans is not entirely understood, it has been established that this organization includes connections between the occipital and the frontal lobes (and other areas), routed either through the temporal lobe (the ventral visual stream), or through the parietal lobe (the dorsal visual stream) (Ungerleider & Haxby, 1994). Findings suggest that visuo-spatial dysfunction in 22q11.2DS patients might be related to impaired visual stream processing.

Each of these streams has been associated with specific functionality. For example, the ventral stream, the ‘what’ pathway, is important for the identification of objects, whereas the dorsal stream, the ‘where’ pathway, is important for locating objects (Mishkin & Ungerleider, 1982). **Deficits in visuo-spatial working memory (the dorsal visual stream) were observed in 22q11.2DS, while the object-based memory (ventral visual stream) was relatively preserved** (Bearden, Wang, & Simon, 2002; Bearden, et al., 2001), **which implicates selective impairment of the dorsal visual stream in 22q11.2DS. However, two other studies support deficits of the ventral visual pathway in 22q11.2DS subjects. The first study reported dysfunctionality of the ‘face perception’ area using functional MRI** (van Amelsvoort et al., 2006). **The second study used the Test of Memory and Learning (TOMAL) to explore functionality of the dorsal and the ventral visual pathways. Young adults with 22q11.2DS and their siblings showed a relatively preserved functionality of the dorsal stream, whereas subjects with 22q11.2DS demonstrated impairment of the facial memory task, which is attributed to the ventral visual stream** (Lajiness-O’Neill et al., 2005). **The inconsistency of the findings might mean that either both visual processing systems are affected or that dependent on the sample of patients either the dorsal or the ventral visual stream is more affected.**

While the exact anatomical structures (fiber tracts) that form the visual streams have not been extensively studied in humans, neuroanatomical correlates established in studies in non-human primates demonstrated that the ventral visual stream consists of the inferior longitudinal fasciculus (ILF), an association fiber connecting the occipital lobe to the temporal lobe, and the inferior fronto-occipital fasciculus (IFOF), an association fiber connecting the occipital lobe with the frontal lobe (Macko et al., 1982; Tusa & Ungerleider,

1985). Studies of ILF and IFOF in humans support the neuroanatomical presence of visual stream pathways (Catani & Thiebaut de Schotten, 2008; Makris et al., 1999; Sarubbo, De Benedictis, Maldonado, Basso, & Duffau, 2011; Schmahmann, 2006).

Established imaging methods now make possible not only the delineation of the fibers of interest in humans, but also an analysis of the tract's changes in patients and in healthy control subjects. Of note here, Diffusion Tensor Magnetic Resonance Imaging (DT-MRI) is a non-invasive imaging method that allows *in vivo* analysis of the organization of white matter (WM) in the brain. The underlying principle is the detection of directed diffusion of water molecules in anisotropic tissues, such as myelinated neuronal fibers, which can be found in the highly organized tracts of the brain WM (Basser, Mattiello, & LeBihan, 1994). These specialized MR diffusion sensitive measurements can be post-processed to compute an estimate of the diffusion tensor. Most quantitative DT-MRI studies rely on the analysis of Fractional Anisotropy (FA), a scalar value describing the directionality of water diffusion. FA is the ratio between the long axis and the two perpendicular axes of the diffusion tensor, scaled to values between 0 and 1. FA is indirectly related to tissue properties, corresponding to degree of coherence, organization, and density of fiber tracts (Beaulieu, 2002). Thus changes in FA may reflect pathological abnormalities of WM. FA is also used in guiding fiber tractography (Basser, Pajevic, Pierpaoli, Duda, & Aldroubi, 2000), where streamlines are computed based on the analysis of diffusion tensor image and which makes the reconstruction of fiber bundles possible. In addition to FA, there are two other indices derived from DT-MRI that are more specific to underlying micro pathologies of the neuron: Axial Diffusivity (AD), which captures diffusion along the longest axis of the ellipsoid, and Radial Diffusivity (RD), which captures diffusivity perpendicular to the long axis of the diffusion tensor. These measures were introduced in animal experiments, and were shown to be more sensitive than FA alone as markers of axonal (AD) and myelin (RD) changes (Song et al., 2003; Song et al., 2005). In a recently published study, we have compared 22q11.2DS patients to control subjects using TBSS, a voxel-based whole brain WM analysis. We found localized, **statistically significant** reductions of FA and **slightly** more extended, **statistically significant** reductions of AD in WM of the **inferior parietal lobe in the left hemisphere** in the patients group. Interestingly, several white matter tracts intersect in this region, including ILF and IFOF, the tracts of the ventral visual stream (Kikinis et al., 2012).

Considering the reported **deficits** in visual **postprocessing** in 22q11.2DS patients (Lajiness-O'Neill, et al., 2005) and our findings of abnormalities in WM of the **inferior parietal lobe** (Kikinis, et al., 2012), the aim of this study is to investigate the hypothesis that fibers of the ventral visual stream will be abnormal in 22q11.2DS subjects. We used DT-MRI scans of adult 22q11.2DS patients and healthy controls and performed tractography of the IFOF and the ILF in order to explore the changes of this anatomical substrate of the ventral visual stream. It was our goal to better understand the biological features of tract abnormalities observed in the 22q11.2DS group by measuring FA, AD, and RD along IFOF and ILF.

2. Methods

2.1 Subjects

Subjects participating in this study were described previously (Kikinis, et al., 2012). In short, nine subjects with 22q11.2DS were recruited from Boston area hospitals, and from responders to an advertisement on 22q11.2DS related websites. The deletion of the chromosomal region 22q11.2 was reconfirmed by Fluorescent In Situ Hybridization (FISH). DSM-IV diagnosis was conducted by a psychiatrist (CTF) and based on diagnostic SCID-P interviews and medical charts (First, 2002). None of the 22q11.2DS patients was diagnosed with schizophrenia at the time of the scan. Nine healthy subjects were recruited through local newspaper advertisements. Healthy subjects were screened using the Structured

Clinical Interview (SCID non-patient edition) (Spitzer, 1990) and none had an Axis I psychiatric disorder or a first-degree relative with a reported Axis I psychiatric disorder. The control subjects were group matched to the patients on age, gender, handedness and PSES (parental socioeconomic status). All subjects were age of 18 years or older. The demographic and clinical characteristics of the study groups are summarized in Table 1.

This study was approved by the Institutional Review Boards. All subject signed informed consent prior to study participation, which was consistent with the principles outlined in an internationally recognized standard for the ethical conduct of human research.

2.2 Data acquisition

The subjects received diffusion weighted scans using a line scan diffusion imaging (LSDI) (Gudbjartsson et al., 1996) technique on a 1.5 Tesla System GE Echospeed scanner. The scanning protocol is described in detail elsewhere (Kubicki et al., 2004). Briefly, LSDI scans were acquired of the whole brain in the coronal direction, perpendicular to both the AC-PC line and interhemispheric fissure. For each line, six images with high (1000 s/mm^2) diffusion weighting along six non-collinear directions and two images with low (5 s/mm^2) diffusion weighting were collected. The following scan parameters were used: Field of view $220\text{mm}\times 165\text{mm}$; scan matrix 128×128 (image matrix 256×256); slice thickness 4 mm; interslice distance 1 mm; TE=64 ms; effective TR=2592 ms; scan time 60 s/slice.

2.3 Data preprocessing

DICOM data were converted to NRRD format and masked to remove the head and neck structures. Tensors were estimated using least squares method (Basser & Jones, 2002) implemented in 3DSlicer software version 2.8. (<http://www.slicer.org/>).

2.4 Data Analysis

ROI (Region-Of-Interest) based streamline tractography of the IFOF and the ILF were performed using 3DSlicer software. Voxels defined by ROIs were used as seeds for streamline tractography. Streamline tractography followed the direction of the major eigenvector, based on the Runge-Kutta protocol (Basser & Jones, 2002) with a fixed step size 0.5 mm, a stopping criterion of FA <0.15 and minimal length 600 mm. Individual ROIs for each tract were selected based on WM atlases (Wakana, Jiang, Nagae-Poetscher, van Zijl, & Mori, 2004),(Catani & Thiebaut de Schotten, 2008). Our standard model for seeding and reconstructing each WM tract was defined by an anterior ROI, a posterior ROI, and, specific for each tract, either additional inclusion or exclusion ROIs, explained in more details in our previous publication (Rosenberger et al., 2008). All ROIs were drawn manually on color by orientation FA labelmaps. The ROIs were over-inclusive to avoid the size of the ROI being the determining factor of the tractography analysis. The obtained tracts were reconstructed in 3-dimensional view, and checked for consistency with respect to neuroanatomy by a trained neuroanatomist (NM). The final output of the tractography analysis of each tract was the mean value of FA, AD or RD, averaged over the entire extension of the tract.

The drawing of the ROIs for each of the tracts was performed by two investigators (DL, AH), both blind to diagnosis. Interrater reliability was calculated using an intraclass correlation coefficient (ICC) for the drawings by the two raters for 10 cases, which were selected randomly. ICC was 0.98 and 0.85 for the left and for the right IFOF, respectively; and 0.95 and 0.91 for the left and for the right ILF, respectively.

2.5 Statistical Analysis

We used the Statistical Package for Social Sciences (PASW, version 17.0; SPSS Inc., Chicago, IL, USA) for data analysis. Socio-demographic data were analyzed by t-test (Table 1) and diffusivities by a two-way repeated-measures analysis of variance (ANOVA) performed for each of the main outcomes. The between subjects factor was diagnostic group (patients versus controls). The within-subjects factor was hemisphere (left versus right), and we tested the interaction. The main outcomes for the IFOF tract and the ILF tract included FA, AD and RD. To address the relatively small sample size of the study, effect size was calculated using Cohen's *d* (Cohen, 1988) based on the means and the standard deviations of FA and AD for each of the two tracts. Power was calculated based on an alpha error probability of 0.05 using G*Power3 software (Faul, Erdfelder, Buchner, & Lang, 2009).

3. Results

3.1 Demographics

Patients and control subjects did not differ in age ($p=0.973$), gender, or PSES ($p=0.300$) (Table 1 and Supplementary Material Figure S1). 22q11.2DS subjects had a fewer years of education ($p=0.029$) and a significantly lower SES ($p=0.001$) than controls. Lower education of 22q11.2DS patients might be explained by cognitive deficits, a below average IQ of 75, with the latter being consonant with a diagnosis of mental retardation associated with the syndrome (Gerdes et al., 1999; Moss et al., 1999; Swillen et al., 1997; Woodin et al., 2001).

3.2 Tractography

Both tracts, the IFOF and ILF, were successfully delineated (Figure 1) in both the 22q11.2DS and the control group.

ANOVA was performed for each of the tracts and for each of the DT-MRI measures: FA, AD and RD. All significant interactions and effects with corresponding *p* values of 0.05 and below are reported in Table 2. In summary, we found for IFOF statistically significant effects between the patients and control group for FA and for AD; and a significant interaction between group and hemisphere for RD. ANOVA for the second tract, the ILF, and AD showed a significant effect between patients and controls.

The results of a post hoc analysis using Independent *t*-Test are shown in Figure 2. In summary, the 22q11.2DS group showed reduced FA for IFOF in the left hemisphere and reduced AD in both hemispheres, whereas ILF showed reduced FA only at trend level in the left hemisphere, but statistically significant reduction in AD in both hemispheres. No group differences were observed for RD in any of the tracts studied.

The tight distribution of the values and the absence of outliers were reconfirmed visually by plotting the intensities of FA and axial diffusivity of both of the tracts (Figure 2).

The dorsal part of the cingulum bundle was delineated as control tract for the method. We have chosen the dorsal part of cingulum based on similarities in shape and appearance of cingulum and IFOF and on the results from our previously published TBSS analysis (Kikinis et al 2012). According to the TBSS analysis, no changes in FA or AD were expected in dorsal cingulum. Indeed, the tractography of the dorsal part of the cingulum has shown no statistically significant group differences (independent *t*-test, left hemisphere: FA [$t=-0.8$, $p=0.4$], AD [$t=0.7$, $p=0.5$], RD [$t=1.9$, $p=0.07$], right hemisphere: FA [$t=-0.5$, $p=0.6$], AD [$t=1.3$, $p=0.2$], RD [$t=1.6$, $p=0.14$]) and demonstrates the specificity of our tractography results.

We also explored effect size and power. The effect size for IFOF was: FA Cohen's $d = 1.70$, effect size $r = 0.65$; AD left: Cohen's $d = 1.34$, effect size $r = 0.38$; AD right: Cohen's $d = 1.44$, effect size $r = 0.58$, and for ILF was: AD left: Cohen's $d = 1.63$, effect size $r = 0.63$; AD right: Cohen's $d = 1.35$, effect size $r = 0.56$. These findings reflect moderate to large effect sizes. Power was higher than 85% for all measures, indicating that this small sample size is sufficient to demonstrate differences in IFOF and ILF based on measures of diffusivity, such as FA or AD.

Lastly, FA and AD values were not associated with any of the demographic measures **or comorbid disorders**. That is, there were no statistically significant correlations found for FA with age, sex, years of education, SES, PSES, or handedness in the 22q11.2DS or in the control group. **Six patients had also a diagnosis of anxiety and phobia. To make sure that our findings were not confounded by comorbid diagnosis, correlations between the DTI measures and the comorbid disorders were performed. FA and AD of either tract did not correlate with the comorbid diagnosis of anxiety and phobia in 22q11.2DS subjects. Other frequent comorbid diagnoses of autism or attention deficit were not present among our subjects.**

4. Discussion

The aim of this study was to investigate neural components of the ventral visual stream in patients with 22q11.2DS and normal controls. To the best of our knowledge this is the first study to analyze the ventral visual stream in patients with 22q11.2DS using quantitative measures derived from tractography. We found statistically significant group differences in both of tracts studied. As summarized in Figure 2, a reduction of FA was found in the IFOF in the left hemisphere in 22q11.2DS patients, and a reduction of AD was found in both IFOF and ILF, bilaterally, in 22q11.2DS. While FA is sensitive, it is a non-specific measure of WM microstructure. AD, in contrast, is more specific and our findings show that AD is altered in 22q11.2DS compared with controls, suggesting that axonal alterations may be important in the WM pathology of this population.

Interestingly, AD has rarely been explored in studies of 22q11.2DS subjects. Only two published studies have investigated AD and both reported reductions in AD to be more prominent than reductions in FA. In the first study, recently published by our team, whole brain WM in 22q11DS subjects were compared to controls using TBSS and **statistically significant** reductions in both FA and AD were reported in a region of **inferior** parietal WM that includes ILF and IFOF fiber tracts (Kikinis, et al., 2012). In the current study we followed up on this finding by performing tractography measures on these tracts **and were able to reconfirm the significant changes in FA and AD in both tracts**. The other study compared 22q11.2DS patients to their siblings using a WM parcellation based on a WM atlas analysis (Radoeva et al., 2012). In this study, Radoeva et al. reported statistically significant reductions in AD in multiple tracts, including IFOF. **The results of two published studies are concordant and complementary in respect to changes in AD, although the two studies investigated different populations considering parameters such as age, number of participants and severity of symptoms and used different methods of analysis. All three studies reconfirm the importance of the AD measures in WM analyses in 22q11.2DS.**

Reductions of FA and AD have been experimentally associated with underlying histopathologies in animal studies, including thinner neurons, lower number of neurons, and less ordered axons (Harsan et al., 2006; Song, et al., 2003). Such anomalies have been proposed for 22q11.2DS in a transgenic mouse model and by human histopathological studies. The LgDel mouse is a transgenic animal model with haploinsufficiency of several

genes of the 22q11.2 chromosomal region. This insufficiency leads to changes in neuronal migration, morphogenesis, neurogenesis, and, in general, to a lower number of neurons. (Meechan, Maynard, Tucker, & Lamantia, 2010; Meechan, Tucker, Maynard, & LaMantia, 2009). In a post-mortem histological study of brains of 22q11.2DS patients, Kiehl et al. found less-ordered WM and ectopic neurons scattered throughout the WM. The presence of displaced neurons were interpreted as the result of abnormal neuronal migration during brain development (Kiehl, Chow, Mikulis, George, & Bassett, 2009). In general, developmental abnormalities in 22q11.2DS have been assumed because the physical manifestation of 22q11.2DS often includes dysmorphology of the heart, face, brain, and limbs, which is likely affected by abnormal development of cells of the neural crest (Kirby, Gale, & Stewart, 1983). It is conceivable that the reduction of AD and FA in WM of 22q11.2DS is also a consequence of neurodevelopmental abnormalities.

Several previous imaging reports suggest abnormal connectivity in the brain regions involved in processing visual stimuli in 22q11.2DS patients and are in line with our findings. Deficits in visual processing were demonstrated in functional studies, including fMRI (Debbane et al., 2012; van Amelsvoort, et al., 2006) and ERP (Magnee, Lamme, de Sain-van der Velden, Vorstman, & Kemner, 2011). DT-MRI studies, using voxel-based whole brain techniques, such as SPM or TBSS, reported localized clusters of voxels of WM changes along fronto-parietal, tempo-parietal and occipital connections (Barnea-Goraly et al., 2003; da Silva Alves et al., 2011; Kikinis, et al., 2012; Simon et al., 2008; Sundram et al., 2010). A SPM study on young children with 22q11DS syndrome reported changes in FA that correlated negatively with performance on visuo-spatial cognitive tasks (Simon, et al., 2008). Similarly, an atlas-based WM analysis of 22q11.2DS patients and their siblings showed positive correlations of AD in IFOF with scores on the Visual Span Test, indicating that changes in WM are associated with visuo-spatial performance (Radoeva, et al., 2012). Lastly, structural MRI studies have reported volumetric reductions in gray matter of regions involved in the post-processing of visual stimuli, including the occipital lobe (Bearden et al., 2007; Campbell et al., 2006; Kates et al., 2001), frontal brain regions (Gothelf, Penniman, Gu, Eliez, & Reiss, 2007) and gray and WM of the temporal lobes (Gothelf, et al., 2007). To the best of our knowledge, our study is the first to use tractography. Using tractography we were able to achieve improved localization of WM abnormalities in 22q11.2DS. As results of this improved localization, we were able to replicate the results reported previously about the existence of WM abnormalities within the IFOF. The higher sensitivity of this method allowed us to also detect previously unreported bilateral abnormalities in the other neuroanatomical substrate of the ventral visual stream, the ILF.

Deficits of ventral visual stream are being reported more recently (along with deficits in the dorsal stream) in a number of other developmental disorders, such as autism spectrum disorder, anxiety disorder, William's syndrome and Fragile X (Bishop, 2007; Walter, Mazaika, & Reiss, 2009). Some of those disorders are comorbid with 22q11.2DS and deserve to be mentioned here as a possible source to confound our findings. As for the case of the anxiety disorder, it was reported that elevated state of anxiety was associated with increased activity of the amygdala and, of interest to this study, strong inputs from the temporal lobe and projections back to the visual cortices modulate the activity of the amygdala and suggest the involvement of the ventral visual pathway (Bishop, 2007). Several patients were diagnosed with anxiety and phobia disorders, but the comorbidity of these disorders did not correlate with the DT-MRI measures of either of the tract, which suggest that our findings in IFOF and ILF are specific to 22q11.2DS.

Even though no other DT-MRI studies in 22q11.2DS have focused on the ventral visual stream, several studies have looked at these structures in schizophrenia. These studies are relevant because there is a 30% incidence of schizophrenia in 22q11.2DS patients (Bassett et

al., 2005) and because deficits in visuo-spatial memory, such as face processing, is not limited just to 22q11.2DS syndrome, but is also prevalent in patients diagnosed with schizophrenia (Whittaker, Deakin, & Tomenson, 2001). Tractography studies in schizophrenia have focused on ILF and IFOF, and report reduced FA in these structures (Ashtari et al., 2007; Cheung et al., 2011; Rosenberger, et al., 2008; Seal et al., 2008). Reported reductions in FA in schizophrenia, however, are usually associated with increases in RD, but not reductions in AD (Ashtari, et al., 2007; Seal, et al., 2008). Further, they are generally interpreted as being the consequence of myelin related pathology (Davis et al., 2003; Hakak et al., 2001; Tkachev et al., 2003; Uranova et al., 2001). The difference in reported findings for schizophrenia studies and this study on 22q11.2DS suggests possible differences in underlying histopathology, i.e., myelin disruption in schizophrenia and axonal pathology in 22q11.2DS patients. Such findings suggest developmental abnormalities in 22q11.2DS and more likely degenerative abnormalities in schizophrenia. The existence of distinct pathologies between 22q11.2DS and schizophrenia patients raises the question of whether increases of RD in WM might possibly be seen in 22q11.2DS patients diagnosed with schizophrenia. The findings of reduced FA and AD, without changes in RD, may be specific to the phenotype of 22q11.2DS as the participants of our study are young adult 22q11.2DS patients without the diagnosis of schizophrenia. Future MR-DTI studies in 22q11.2DS patients with schizophrenia exploring not just FA, but also AD and RD indices might provide answers to this question about microstructural changes in WM in these diseases.

The small number of subjects is an obvious limitation of our study. However, the power of our findings is relatively high (> 85%), suggesting robustness despite the small sample size. A further limitation might be that patients and controls, as in most other studies of 22q11.2DS, were not matched for IQ. Nevertheless, deficits in visual spatial abilities are reported to be present independent of intellectual performance (Vicari et al., 2012). Additionally, since this is a cross sectional study, and because no follow up data are available, we cannot say how changes in IFOF and ILF might develop over time. **A further limitation of this study was that cognitive testing was not carried out in this population. Finally, we focused on the ventral visual stream only. Recently published neuropsychological 22q11.2DS studies redefine the deficits in visuo-spatial memory as visuo-motor and visual attentional deficits (Baker & Vorstman, 2012; Howley, Prasad, Pender, & Murphy, 2012). It is very likely, that IFOF and ILF are part of these systems, but future studies might also include the tracts of the dorsal stream.**

In summary, we explored the neuroanatomical substrates of the ventral visual stream in patients with 22Q11.2DS and find that specific tracts, such as IFOF and ILF, show changes in DT-MRI measures. We suggest that reduction of FA, and especially AD, is a specific feature of 22q11.2DS, as opposed to reductions in FA and increases in RD, which are more commonly observed in schizophrenia. Further, based on observations in mice (Harsan, et al., 2006; Song, et al., 2003) it is plausible that reductions in AD, along with reductions in FA, and no changes in RD measures, are indicative of impaired axonal changes rather than myelin changes. The observed changes in IFOF and ILF could help to explain impaired ventral visual stream and performance deficits in visual memory tasks, which have been widely reported in patients with 22q11.2DS.

Supplementary Material

Refer to Web version on PubMed Central for supplementary material.

Acknowledgments

We thank Dr. F. Jolesz to fund the scans, Andrew Hyatt for drawing ROIs for the purpose of reliability measurements for the tractography method and the BWH Center for Clinical Investigation for statistical consultation.

Funding

This work was supported by a Brain and Behavior Research Foundation (formerly called NARSAD) (Young Investigator Award to ZK); by the US Department of Veterans Affairs (Merit Awards to MES), (Schizophrenia Center to MES); and by National Institute of Health (Career Reentry Supplement to ZK on MH 50740 to MES), (MH 070047 to MES), (MH 080272 to MES and to MK), (RO1 MH082918 to SB)(U54 EB005149 to RK, to MK, to MES); (NAC P41 RR 13218 to RK).

References

- Ashtari M, Cottone J, Ardekani BA, Cervellione K, Szeszko PR, Wu J, Kumra S. Disruption of white matter integrity in the inferior longitudinal fasciculus in adolescents with schizophrenia as revealed by fiber tractography. *Arch Gen Psychiatry*. 2007; 64(11):1270–1280. [PubMed: 17984396]
- Baker K, Vorstman JA. Is there a core neuropsychiatric phenotype in 22q11.2 deletion syndrome? *Current opinion in neurology*. 2012; 25(2):131–137. [Research Support, Non-U.S. Gov't Review]. [PubMed: 22395003]
- Barnea-Goraly N, Menon V, Krasnow B, Ko A, Reiss A, Eliez S. Investigation of white matter structure in velocardiofacial syndrome: a diffusion tensor imaging study. *Am J Psychiatry*. 2003; 160(10):1863–1869. [PubMed: 14514502]
- Basser PJ, Jones DK. Diffusion-tensor MRI: theory, experimental design and data analysis - a technical review. *NMR Biomed*. 2002; 15(7–8):456–467. [Research Support, Non-U.S. Gov't Review]. [PubMed: 12489095]
- Basser PJ, Mattiello J, LeBihan D. MR diffusion tensor spectroscopy and imaging. *Biophysical journal*. 1994; 66(1):259–267. [PubMed: 8130344]
- Basser PJ, Pajevic S, Pierpaoli C, Duda J, Aldroubi A. In vivo fiber tractography using DT-MRI data. *Magnetic resonance in medicine : official journal of the Society of Magnetic Resonance in Medicine / Society of Magnetic Resonance in Medicine*. 2000; 44(4):625–632. [Research Support, U.S. Gov't, Non-P.H.S.]. [PubMed: 11025519]
- Bassett AS, Chow EW, Husted J, Weksberg R, Caluseriu O, Webb GD, Gatzoulis MA. Clinical features of 78 adults with 22q11 Deletion Syndrome. *Am J Med Genet A*. 2005; 138(4):307–313. [PubMed: 16208694]
- Bearden CE, van Erp TG, Dutton RA, Tran H, Zimmermann L, Sun D, Thompson PM. Mapping cortical thickness in children with 22q11.2 deletions. *Cereb Cortex*. 2007; 17(8):1889–1898. [PubMed: 17056649]
- Bearden CE, Wang PP, Simon TJ. Williams syndrome cognitive profile also characterizes Velocardiofacial/DiGeorge syndrome. *Am J Med Genet A*. 2002; 114(6):689–692. [Letter Research Support, U.S. Gov't, P.H.S.].
- Bearden CE, Woodin MF, Wang PP, Moss E, McDonald-McGinn D, Zackai E, Cannon TD. The neurocognitive phenotype of the 22q11.2 deletion syndrome: selective deficit in visual-spatial memory. *Journal of clinical and experimental neuropsychology*. 2001; 23(4):447–464. [Research Support, U.S. Gov't, P.H.S.]. [PubMed: 11780945]
- Beaulieu C. The basis of anisotropic water diffusion in the nervous system - a technical review. *NMR Biomed*. 2002; 15(7–8):435–455. [Research Support, Non-U.S. Gov't Review]. [PubMed: 12489094]
- Bishop SJ. Neurocognitive mechanisms of anxiety: an integrative account. *Trends in cognitive sciences*. 2007; 11(7):307–316. [Research Support, Non-U.S. Gov't Review]. [PubMed: 17553730]
- Campbell LE, Daly E, Toal F, Stevens A, Azuma R, Catani M, Murphy KC. Brain and behaviour in children with 22q11.2 deletion syndrome: a volumetric and voxel-based morphometry MRI study.

- Brain : a journal of neurology. 2006; 129(Pt 5):1218–1228. [Research Support, Non-U.S. Gov't]. [PubMed: 16569671]
- Catani M, Thiebaut de Schotten M. A diffusion tensor imaging tractography atlas for virtual in vivo dissections. *Cortex*. 2008; 44(8):1105–1132. [Research Support, Non-U.S. Gov't]. [PubMed: 18619589]
- Cheung V, Chiu CP, Law CW, Cheung C, Hui CL, Chan KK, Chen E. Positive symptoms and white matter microstructure in never-medicated first episode schizophrenia. *Psychological medicine*. 2011; 41(8):1709–1719. [Research Support, Non-U.S. Gov't]. [PubMed: 20809999]
- Cohen, J. *Statistical Power Analysis for the Behavioral Sciences*. 2nd ed.. New Jersey: Lawrence Erlbaum Associates; 1988.
- da Silva Alves F, Schmitz N, Bloemen O, van der Meer J, Meijer J, Boot E, van Amelsvoort T. White matter abnormalities in adults with 22q11 deletion syndrome with and without schizophrenia. *Schizophr Res*. 2011; 132(1):75–83. [Research Support, Non-U.S. Gov't]. [PubMed: 21831603]
- Davis KL, Stewart DG, Friedman JI, Buchsbaum M, Harvey PD, Hof PR, Haroutunian V. White matter changes in schizophrenia: evidence for myelin-related dysfunction. *Arch Gen Psychiatry*. 2003; 60(5):443–456. [PubMed: 12742865]
- Debbane M, Lazouret M, Lagioia A, Schneider M, Van De Ville D, Eliez S. Resting-state networks in adolescents with 22q11.2 deletion syndrome: Associations with prodromal symptoms and executive functions. *Schizophr Res*. 2012; 139(1–3):33–39. [PubMed: 22704643]
- Driscoll DA, Spinner NB, Budarf ML, McDonald-McGinn DM, Zackai EH, Goldberg RB, et al. Deletions and microdeletions of 22q11.2 in velo-cardio-facial syndrome. *Am J Med Genet A*. 1992; 44(2):261–268. [Comparative Study Research Support, Non-U.S. Gov't Research Support, U.S. Gov't, P.H.S.].
- Faul F, Erdfelder E, Buchner A, Lang AG. Statistical power analyses using G*Power 3.1: tests for correlation and regression analyses. *Behav Res Methods*. 2009; 41(4):1149–1160. [PubMed: 19897823]
- First, MB.; Spitzer, RL.; Gibbon, M.; Williams, JBW. *Structured Clinical Interview for DSM-IV-TR Axis I Disorders*. New York: Biometrics Research, New York State Psychiatric Institute; 2002. Research Version, Patient Edition. (SCID-I/P).
- Gerdes M, Solut C, Wang PP, Moss E, LaRossa D, Randall P, Zackai EH. Cognitive and behavior profile of preschool children with chromosome 22q11.2 deletion. *Am J Med Genet*. 1999; 85(2):127–133. [PubMed: 10406665]
- Gothelf D, Penniman L, Gu E, Eliez S, Reiss AL. Developmental trajectories of brain structure in adolescents with 22q11.2 deletion syndrome: a longitudinal study. *Schizophr Res*. 2007; 96(1–3):72–81. [PubMed: 17804201]
- Gudbjartsson H, Maier SE, Mulkern RV, Morocz IA, Patz S, Jolesz FA. Line scan diffusion imaging. *Magn Reson Med*. 1996; 36(4):509–519. [PubMed: 8892201]
- Hakay Y, Walker JR, Li C, Wong WH, Davis KL, Buxbaum JD, Fienberg AA. Genome-wide expression analysis reveals dysregulation of myelination-related genes in chronic schizophrenia. *Proc Natl Acad Sci U S A*. 2001; 98(8):4746–4751. [PubMed: 11296301]
- Harsan LA, Poulet P, Guignard B, Steibel J, Parizel N, de Sousa PL, Ghandour MS. Brain dysmyelination and recovery assessment by noninvasive in vivo diffusion tensor magnetic resonance imaging. *Journal of neuroscience research*. 2006; 83(3):392–402. [Comparative Study Research Support, Non-U.S. Gov't]. [PubMed: 16397901]
- Hollingshead, A. *Two factor index of social position*. New Haven, CT: Yale University Press; 1965.
- Howley SA, Prasad SE, Pender NP, Murphy KC. Relationship between reaction time, fine motor control, and visual-spatial perception on vigilance and visual-motor tasks in 22q11.2 Deletion Syndrome. *Res Dev Disabil*. 2012; 33(5):1495–1502. doi: 10.1016/j.ridd.2012.03.023. [PubMed: 22522207]
- Kates WR, Burnette CP, Jabs EW, Rutberg J, Murphy AM, Grados M, Pearlson GD. Regional cortical white matter reductions in velocardiocardiofacial syndrome: a volumetric MRI analysis. *Biol Psychiatry*. 2001; 49(8):677–684. [PubMed: 11313035]
- Kiehl TR, Chow EW, Mikulis DJ, George SR, Bassett AS. Neuropathologic features in adults with 22q11.2 deletion syndrome. *Cereb Cortex*. 2009; 19(1):153–164. [PubMed: 18483005]

- Kikinis Z, Asami T, Bouix S, Finn CT, Ballinger T, Tworog-Dube E, Kubicki M. Reduced fractional anisotropy and axial diffusivity in white matter in 22q11.2 deletion syndrome: A pilot study. *Schizophr Res.* 2012; 141(1):35–39. doi: 10.1016/j.schres.2012.06.032. [PubMed: 22863550]
- Kirby ML, Gale TF, Stewart DE. Neural crest cells contribute to normal aorticopulmonary septation. *Science.* 1983; 220(4601):1059–1061. [PubMed: 6844926]
- Kubicki M, Maier SE, Westin CF, Mamata H, Ersner-Hersfield H, Estepar R, Shenton ME. Comparison of single-shot echo-planar and line scan protocols for diffusion tensor imaging. *Acad Radiol.* 2004; 11(2):224–232. [PubMed: 14974598]
- Lajiness-O'Neill RR, Beaulieu I, Titus JB, Asamoah A, Bigler ED, Bawle EV, Pollack R. Memory and learning in children with 22q11.2 deletion syndrome: evidence for ventral and dorsal stream disruption? *Child neuropsychology : a journal on normal and abnormal development in childhood and adolescence.* 2005; 11(1):55–71. [Research Support, N.I.H., Extramural Research Support, Non-U.S. Gov't Research Support, U.S. Gov't, P.H.S.]. [PubMed: 15823983]
- Macko KA, Jarvis CD, Kennedy C, Miyaoka M, Shinohara M, Sololoff L, Mishkin M. Mapping the primate visual system with [2–14C]deoxyglucose. *Science.* 1982; 218(4570):394–397. [PubMed: 7123241]
- Magnee MJ, Lamme VA, de Sain-van der Velden MG, Vorstman JA, Kemner C. Proline and COMT status affect visual connectivity in children with 22q11.2 deletion syndrome. *PLoS One.* 2011; 6(10):e25882. [Research Support, Non-U.S. Gov't]. [PubMed: 21998713]
- Makris N, Meyer JW, Bates JF, Yeterian EH, Kennedy DN, Caviness VS. MRI-Based topographic parcellation of human cerebral white matter and nuclei II. Rationale and applications with systematics of cerebral connectivity. *Neuroimage.* 1999; 9(1):18–45. [Research Support, Non-U.S. Gov't Research Support, U.S. Gov't, P.H.S.]. [PubMed: 9918726]
- Meechan DW, Maynard TM, Tucker ES, Lamantia AS. Three phases of DiGeorge/22q11 deletion syndrome pathogenesis during brain development: Patterning, proliferation, and mitochondrial functions of 22q11 genes. *Int J Dev Neurosci.* 2010
- Meechan DW, Tucker ES, Maynard TM, LaMantia AS. Diminished dosage of 22q11 genes disrupts neurogenesis and cortical development in a mouse model of 22q11 deletion/DiGeorge syndrome. *Proc Natl Acad Sci U S A.* 2009; 106(38):16434–16445. [PubMed: 19805316]
- Mishkin M, Ungerleider LG. Contribution of striate inputs to the visuospatial functions of parieto-preoccipital cortex in monkeys. *Behavioural brain research.* 1982; 6(1):57–77. [PubMed: 7126325]
- Moss EM, Batshaw ML, Solot CB, Gerdes M, McDonald-McGinn DM, Driscoll DA, Wang PP. Psychoeducational profile of the 22q11.2 microdeletion: A complex pattern. *J Pediatr.* 1999; 134(2):193–198. [PubMed: 9931529]
- Oldfield RC. The assessment and analysis of handedness: the Edinburgh inventory. *Neuropsychologia.* 1971; 9(1):97–113. [PubMed: 5146491]
- Radoeva PD, Coman IL, Antshel KM, Fremont W, McCarthy CS, Kotkar A, Kates WR. Atlas-based white matter analysis in individuals with velo-cardio-facial syndrome (22q11.2 deletion syndrome) and unaffected siblings. *Behavioral and brain functions : BBF.* 2012; 8(1):38. [PubMed: 22853778]
- Rosenberger G, Kubicki M, Nestor PG, Connor E, Bushell GB, Markant D, Shenton ME. Age-related deficits in fronto-temporal connections in schizophrenia: a diffusion tensor imaging study. *Schizophr Res.* 2008; 102(1–3):181–188. [Comparative Study Research Support, N.I.H., Extramural Research Support, Non-U.S. Gov't]. [PubMed: 18504117]
- Sarubbo S, De Benedictis A, Maldonado IL, Basso G, Duffau H. Frontal terminations for the inferior fronto-occipital fascicle: anatomical dissection, DTI study and functional considerations on a multi-component bundle. *Brain structure & function.* 2011
- Scambler PJ, Kelly D, Lindsay E, Williamson R, Goldberg R, Shprintzen R, Burn J. Velo-cardio-facial syndrome associated with chromosome 22 deletions encompassing the DiGeorge locus. *Lancet.* 1992; 339(8802):1138–1139. [Research Support, Non-U.S. Gov't]. [PubMed: 1349369]
- Schmahmann, JD.; Pandya, DN. *Fiber Pathways of the Brain.* Oxford University Press; 2006.

- Seal ML, Yucel M, Fornito A, Wood SJ, Harrison BJ, Walterfang M, Pantelis C. Abnormal white matter microstructure in schizophrenia: a voxelwise analysis of axial and radial diffusivity. *Schizophr Res*. 2008; 101(1–3):106–110. [PubMed: 18262770]
- Shprintzen RJ. Velo-cardio-facial syndrome: 30 Years of study. *Dev Disabil Res Rev*. 2008; 14(1):3–10. [PubMed: 18636631]
- Simon TJ, Wu Z, Avants B, Zhang H, Gee JC, Stebbins GT. Atypical cortical connectivity and visuospatial cognitive impairments are related in children with chromosome 22q11.2 deletion syndrome. *Behav Brain Funct*. 2008; 4:25. [PubMed: 18559106]
- Song SK, Sun SW, Ju WK, Lin SJ, Cross AH, Neufeld AH. Diffusion tensor imaging detects and differentiates axon and myelin degeneration in mouse optic nerve after retinal ischemia. *Neuroimage*. 2003; 20(3):1714–1722. [PubMed: 14642481]
- Song SK, Yoshino J, Le TQ, Lin SJ, Sun SW, Cross AH, Armstrong RC. Demyelination increases radial diffusivity in corpus callosum of mouse brain. *Neuroimage*. 2005; 26(1):132–140. [PubMed: 15862213]
- Spitzer, R.; Williams, JBW.; Gibbon, M.; First, M., editors. The structured clinical interview for DSM-III-R-non-patient edition (SCID-NP). Washington, DC: American Psychiatric Association; 1990.
- Sundram F, Campbell LE, Azuma R, Daly E, Bloemen OJ, Barker GJ, Murphy DG. White matter microstructure in 22q11 deletion syndrome: a pilot diffusion tensor imaging and voxel-based morphometry study of children and adolescents. *Journal of neurodevelopmental disorders*. 2010; 2(2):77–92. [PubMed: 22127856]
- Swillen A, Devriendt K, Legius E, Eyskens B, Dumoulin M, Gewillig M, Fryns JP. Intelligence and psychosocial adjustment in velocardiofacial syndrome: a study of 37 children and adolescents with VCFS. *J Med Genet*. 1997; 34(6):453–458. [PubMed: 9192263]
- Tkachev D, Mimmack ML, Ryan MM, Wayland M, Freeman T, Jones PB, Bahn S. Oligodendrocyte dysfunction in schizophrenia and bipolar disorder. *Lancet*. 2003; 362(9386):798–805. [PubMed: 13678875]
- Tusa RJ, Ungerleider LG. The inferior longitudinal fasciculus: a reexamination in humans and monkeys. *Annals of neurology*. 1985; 18(5):583–591. [Research Support, U.S. Gov't, P.H.S.]. [PubMed: 4073852]
- Ungerleider LG, Haxby JV. 'What' and 'where' in the human brain. *Current opinion in neurobiology*. 1994; 4(2):157–165. [Review]. [PubMed: 8038571]
- Uranova N, Orlovskaya D, Vikhрева O, Zimina I, Kolomeets N, Vostrikov V, Rachmanova V. Electron microscopy of oligodendroglia in severe mental illness. *Brain Res Bull*. 2001; 55(5):597–610. [PubMed: 11576756]
- van Amelsvoort T, Schmitz N, Daly E, Deeley Q, Critchley H, Henry J, Murphy DG. Processing facial emotions in adults with velo-cardio-facial syndrome: functional magnetic resonance imaging. *The British journal of psychiatry : the journal of mental science*. 2006; 189:560–561. [Research Support, Non-U.S. Gov't]. [PubMed: 17139043]
- Vicari S, Mantovan M, Addona F, Costanzo F, Verucci L, Menghini D. Neuropsychological profile of Italian children and adolescents with 22q11.2 deletion syndrome with and without intellectual disability. *Behavior genetics*. 2012; 42(2):287–298. doi: 10.1007/s10519-011-9499-5. [PubMed: 21870177]
- Wakana S, Jiang H, Nagae-Poetscher LM, van Zijl PC, Mori S. Fiber tract-based atlas of human white matter anatomy. *Radiology*. 2004; 230(1):77–87. [Research Support, U.S. Gov't, P.H.S.]. [PubMed: 14645885]
- Walter E, Mazaika PK, Reiss AL. Insights into brain development from neurogenetic syndromes: evidence from fragile X syndrome, Williams syndrome, Turner syndrome and velocardiofacial syndrome. *Neuroscience*. 2009; 164(1):257–271. [Research Support, N.I.H., Extramural Review]. [PubMed: 19376197]
- Whittaker JF, Deakin JF, Tomenson B. Face processing in schizophrenia: defining the deficit. *Psychological medicine*. 2001; 31(3):499–507. [Research Support, Non-U.S. Gov't]. [PubMed: 11305858]

Woodin M, Wang PP, Aleman D, McDonald-McGinn D, Zackai E, Moss E. Neuropsychological profile of children and adolescents with the 22q11.2 microdeletion. *Genet Med.* 2001; 3(1):34–39. [PubMed: 11339375]




Fig. 1. Tractography of IFOF and ILF

Delineated IFOF (blue) and ILF (red) are presented over whole brain tractography (orange) to show the tracts extension from occipital lobe to frontal (via temporal WM), respectively to temporal lobe. The tractography of the whole brain was seeded thin to allow visualization of the tract of interest.

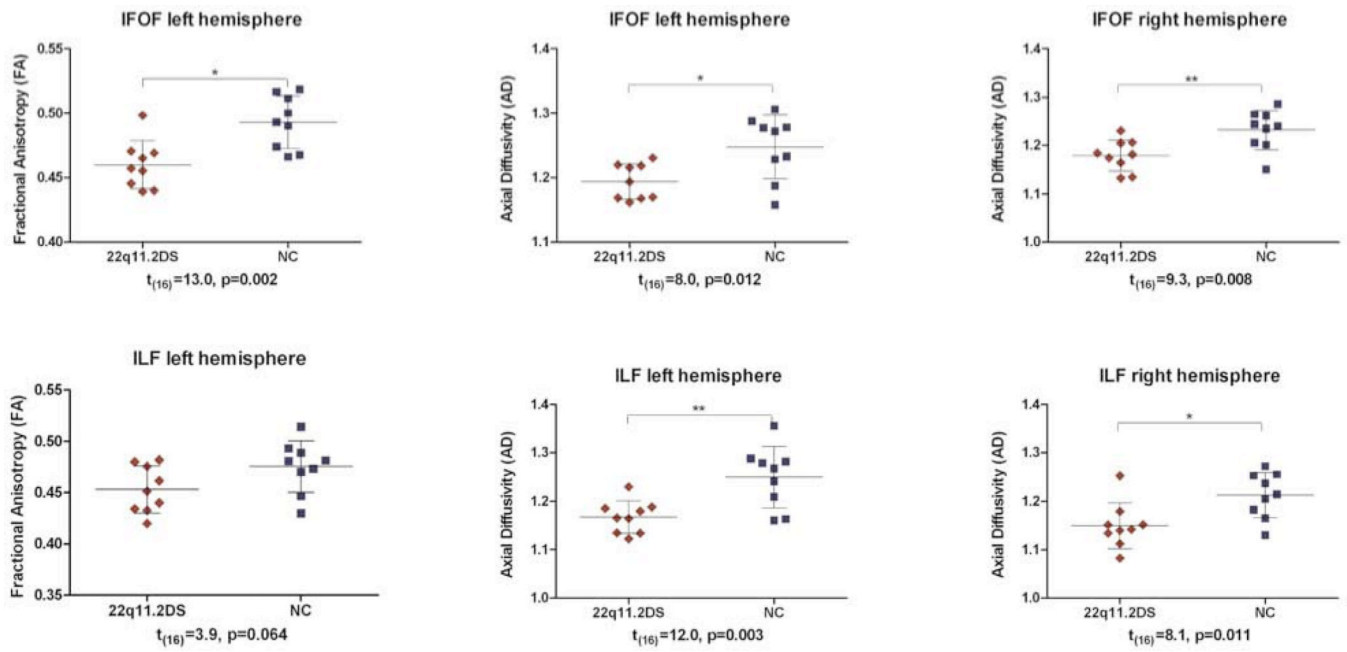


Fig. 2. Comparison of MR-DTI measures in IFOF and ILF

The value of mean fractional anisotropy (FA) ranges between 0 (isotropic diffusivity) and 1 (anisotropic diffusivity). The value of axial diffusivity (AD) is expressed in $\times 10^{-3} \text{ mm}^2/\text{s}$. The black bars indicate the means. The probabilities t and p are from ANOVA test.

Table 1

Demographic and clinical characteristics of participants

Variable	Subjects	Mean(SD)	n	p
Age (in years)	22q11.2DS	27.3 (7.1)	9	0.973
	Controls	27.2 (6.9)	9	
Gender (females; males)	22q11.2DS		7;2	1.000
	Controls		7;2	
Handedness ^a	22q11.2DS		7	
	Controls	0.76(0.25)	9	
Socioeconomic status ^b				
Subject's own	22q11.2DS	4.1 (1.3)	8	0.001 **
	Controls	2.1(0.6)	8	
Parental	22q11.2DS	3 (1.2)	4	0.300
	Controls	2.2 (1.2)	9	
Education (school years)	22q11.2DS	13 (1.2)	9	0.029*
	Controls	15 (2.2)	9	
Antipsychotic medication	22q11.2DS	low dose	2	
Schizophrenia	22q11.2DS		0	

^a based on Edinburgh inventory (Oldfield, 1971) in controls, handedness in patients based on stated and observed preferences;

^b Hollingshead scale (Hollingshead, 1965);

* 2-tailed significance on t-test significant at $p < 0.05$

** statistically significant at $p < 0.01$.

Table 2

ANOVA

tract	interactions and effects	F _(1,16)	p
IFOF	group effect for FA	9.0	0.010
	group effect for AD	10.4	0.005
	interaction between group and hemisphere for RD	5.4	0.030
ILF	group effect for AD	16.6	0.001

IFOF: inferior fronto-occipital fasciculus, ILF: inferior longitudinal fasciculus, FA: fractional anisotropy, AD: axial diffusivity, RD: radial diffusivity, F: degrees of freedom, p: statistical significance