

Imaging assessment of portal venous system: pictorial essay of normal anatomy, anatomic variants and congenital anomalies

A. GUERRA¹, A.M. DE GAETANO¹, A. INFANTE¹, C. MELE², M.G. MARINI¹, E. RINNINELLA³, R. INCHINGOLO⁴, L. BONOMO¹

¹Area Diagnostica per Immagini, UOC Radiologia, University Hospital Foundation "A. Gemelli", Catholic University of the Sacred Heart, Rome, Italy

²Area Chirurgica Addominale, UOC Chirurgia Generale ed Epatobiliare, University Hospital Foundation "A. Gemelli", Catholic University of the Sacred Heart, Rome, Italy

³Area Gastroenterologia, UOC Medicina Interna, Gastroenterologia e Malattie del Fegato, University Hospital Foundation "A. Gemelli", Catholic University of the Sacred Heart, Rome, Italy

⁴UOC Radiologia Diagnostica ed Interventistica, "Madonna delle Grazie" Hospital, Matera, Italy

Abstract. – OBJECTIVE: The purpose of this pictorial essay is to describe anatomic variants and congenital anomalies of portal venous system and related liver parenchymal alterations.

The imaging findings of some of these entities have been previously described in other articles, however this work encompasses all congenital anomalies of portal venous system with attention to their features on various imaging modalities; in particular we illustrated with detailed pictures all the main portal vein variants, congenital extra- and intra-hepatic porto-systemic venous shunts and portal vein aneurysm.

Variants of portal branches and intrahepatic portosystemic shunts are quite uncommon, however, when present, they should be recognized before performing surgery or interventional procedures. Congenital absence of the portal vein is an important finding as the complete loss of portal perfusion predisposes the liver to focal or diffuse hyperplastic or dysplastic changes. Portal vein aneurysm is a rare clinical entity that can affect intra- and extra-hepatic portal branches; although usually asymptomatic, thrombosis can occur.

Awareness of congenital variants of portal venous system among radiologists should allow a more confident diagnosis and permit an accurate planning of surgical procedures and percutaneous interventions; identification of portal system anomalies also suggest an accurate evaluation of associated hepatic parenchymal anomalies such as nodular regenerative hyperplasia, focal nodular hyperplasia (FNH), and adenomas with high risk of malignant transformation.

Key Words:

Portal vein variants, Portosystemic shunt, Portal vein aneurysm.

Introduction

Knowledge of congenital anomalies of the portal venous system is essential for proper diagnosis and awareness of anatomic variants is crucial for adequate planning of surgical and interventional procedures and may also prevent significant complications.

Variants of portal branches and intrahepatic portosystemic shunts are quite uncommon; however, when present, they should be recognized before performing surgery or interventional procedures. Congenital absence of the portal vein is an important finding as the complete loss of portal perfusion predisposes the liver to focal or diffuse hyperplastic or dysplastic changes. Portal vein aneurysm is a rare clinical entity that can affect intra- and extra-hepatic portal branches; although usually asymptomatic, thrombosis can occur.

Computed Tomography (CT) or Magnetic Resonance Imaging (MRI) combined with Doppler Ultrasonography (US) permits a comprehensive evaluation of morphologic and functional abnormalities of the portal system.

Angiography has got nowadays a diagnostic value only for a pathophysiological evaluation for hepatic and portal vein pressure measurement; while its role remains important in cases in which treatment is considered necessary such as TIPS positioning and portal vein embolization.

Normal Portal Anatomy

The portal vein arises from the confluence of the superior mesenteric, inferior mesente-

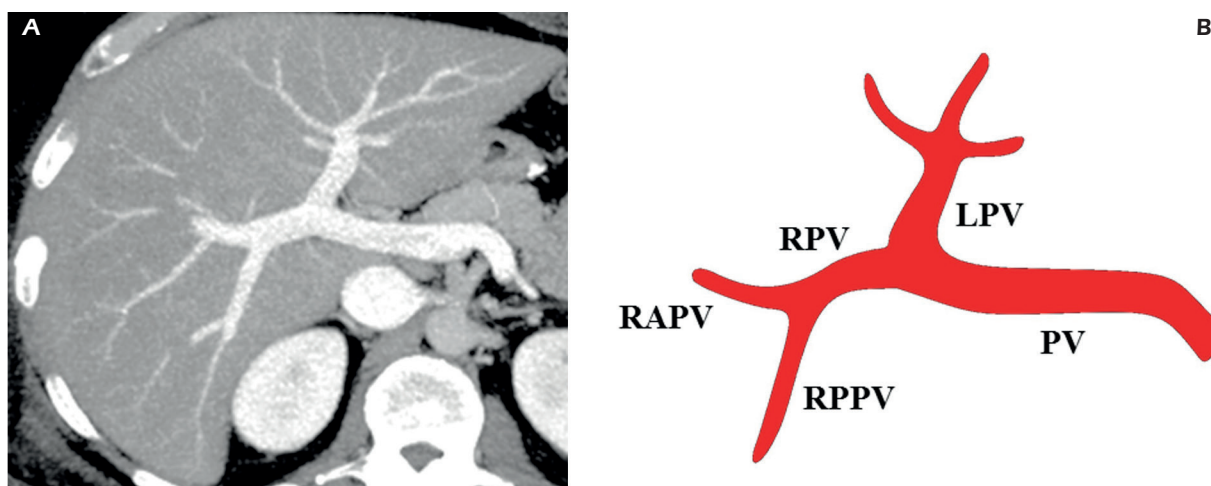


Figure 1. Normal portal anatomy. **A**, Contrast-enhanced CT on portal venous phase - axial MIP reconstruction. The portal trunk divides into a left and a right portal vein that subsequently divides in an anterior branch feeding segments V and VIII and a posterior branch feeding segments VI and VII. **B**, PV: portal vein; LPV: left portal vein; RPV: right portal vein; RAPV: right anterior portal vein; RPPV: right posterior portal vein.

ric and splenic vein posterior to the neck of the pancreas. The *portal trunk divides* in the liver hilum into two branches: left portal vein branch (LPV) and right portal vein branch (RPV). LPV courses medially to the umbilical fissure, supplies segments II, III and IV and provides also a caudate branch. RPV subsequently divides in an anterior branch (RAPV), feeding segments V and VIII, and a posterior branch (RPPV), feeding segments VI and VII (Figure 1). Normal anatomy is encountered in 65 to 80% in the studies using multidetector CT. Any deviation from this anatomy is considered an anatomical variant¹⁻³.

Portal Vein Variants

Portal vein variants are quite frequent and easy to recognize with 3D reconstructions of CT or MR images, with a reported incidence of 27 and 35%.

These variations have a considerable impact on liver surgery and radiological interventional procedures and should be precisely described; in particular, a reliable preoperative imaging of vascular anatomy is mandatory relating to recent developments in liver surgery, with living donor transplantation or complex hepatectomy¹, and in interventional radiology with portal vein embolization.

Portal vein variants are associated with a significantly higher number of biliary anatomic variations, in particular the presence of portal vein variants increases the risk of bile duct hilar anatomical variation.

We describe four main types of portal vein variants:

Type 1: is the so called “*portal vein trifurcation*”, with a reported occurrence of 9-11%, where main portal vein divides into three branches: left portal vein (LPV), right anterior portal vein (RAPV), and right posterior portal vein (RPPV) (Figure 2).

Type 2: right posterior portal vein (RPPV) originates as the first branch of portal vein (PV), with a reported occurrence of 9.7-23% (Figure 3).

Type 3: right anterior portal vein (RAPV) originates from the left portal vein (LPV) (Figure 4).

Type 4: this portal vein variant is less common (< 2%) and is characterized by the *absence of portal vein bifurcation* (the portal vein gives only a single right portal branch in the liver hilum) and by the presence of a large vein coming from segment VIII and entering the distal segment of the left portal vein (Figure 5)^{2,4,5,6}.

Congenital Portosystemic Venous Shunts (PSVS)

The first report of these malformations known as “Abernethy Syndrome” was made in 1973 by a London surgeon, John Abernethy who described a post-mortem examination of a 10-month-old girl, which showed termination of the portal vein in the inferior vena cava (IVC) at the level of the renal veins⁷.

Congenital portosystemic venous shunts (PSVS) are rare and have been explained by al-

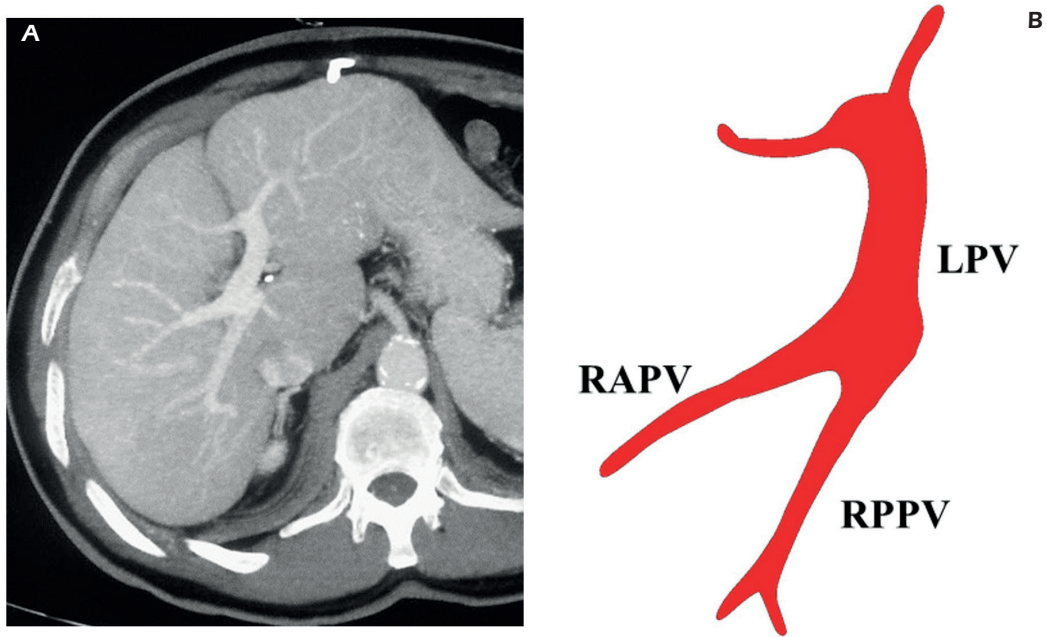


Figure 2. Portal vein variants – type 1: portal vein trifurcation. **A**, Contrast-enhanced CT on portal venous phase – axial MIP reconstruction. The main portal vein divides into three branches: the left portal vein, the right anterior portal vein, and the right posterior portal vein. **B**, LPV: left portal vein; RAPV: right anterior portal vein; RPPV: right posterior portal vein.

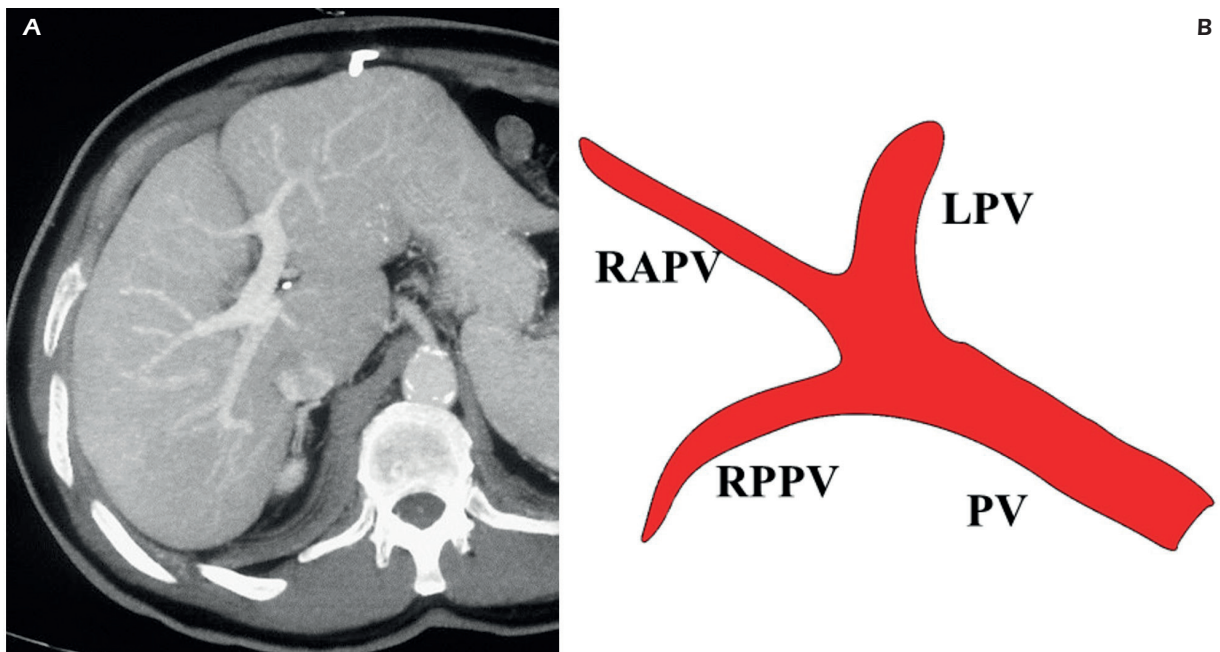


Figure 3. Portal vein variants – type 2. **A**, Contrast-enhanced MRI on portal venous phase - coronal MIP reconstruction. The right posterior portal vein originates as the first branch of the portal vein. **B**, PV: portal vein; RPPV: right posterior portal vein; RAPV: right anterior portal vein; LPV: left portal vein.

terations in the embryological development of the portal system and IVC, with abnormal involution of the vitelline veins (Figure 6), that occur between the 4th and 10th weeks of embryonic life

and can be associated with additional congenital malformations⁸.

According to the site of the shunt, PSVS are classified as:

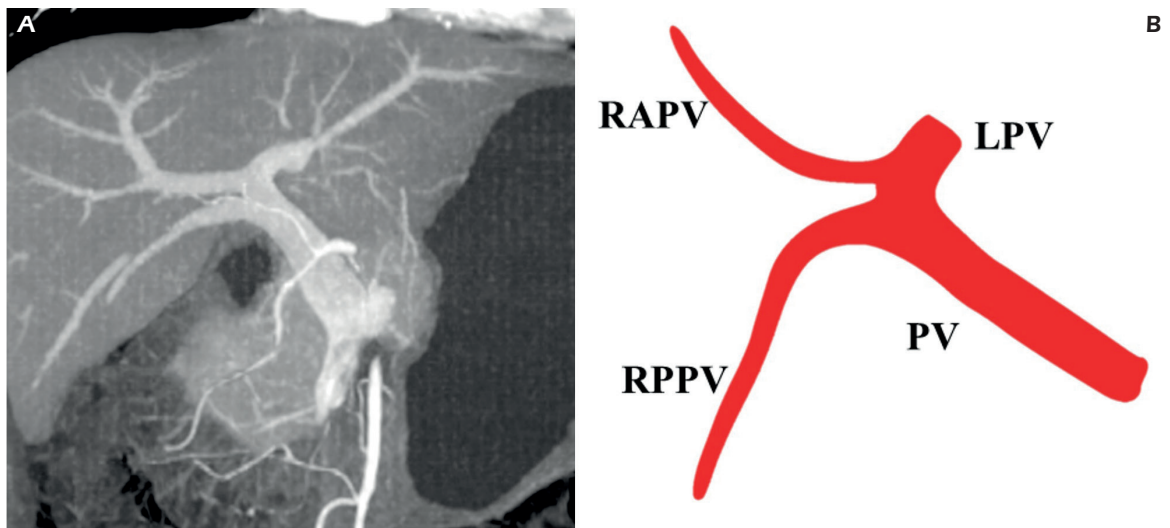


Figure 4. Portal vein variants – type 3. *A*, Contrast-enhanced CT on portal venous phase - coronal MIP reconstruction. The right anterior portal vein originates from the left portal vein. *B*, PV: portal vein; RPPV: right posterior portal vein; LPV: left portal vein; RAPV: right anterior portal vein.

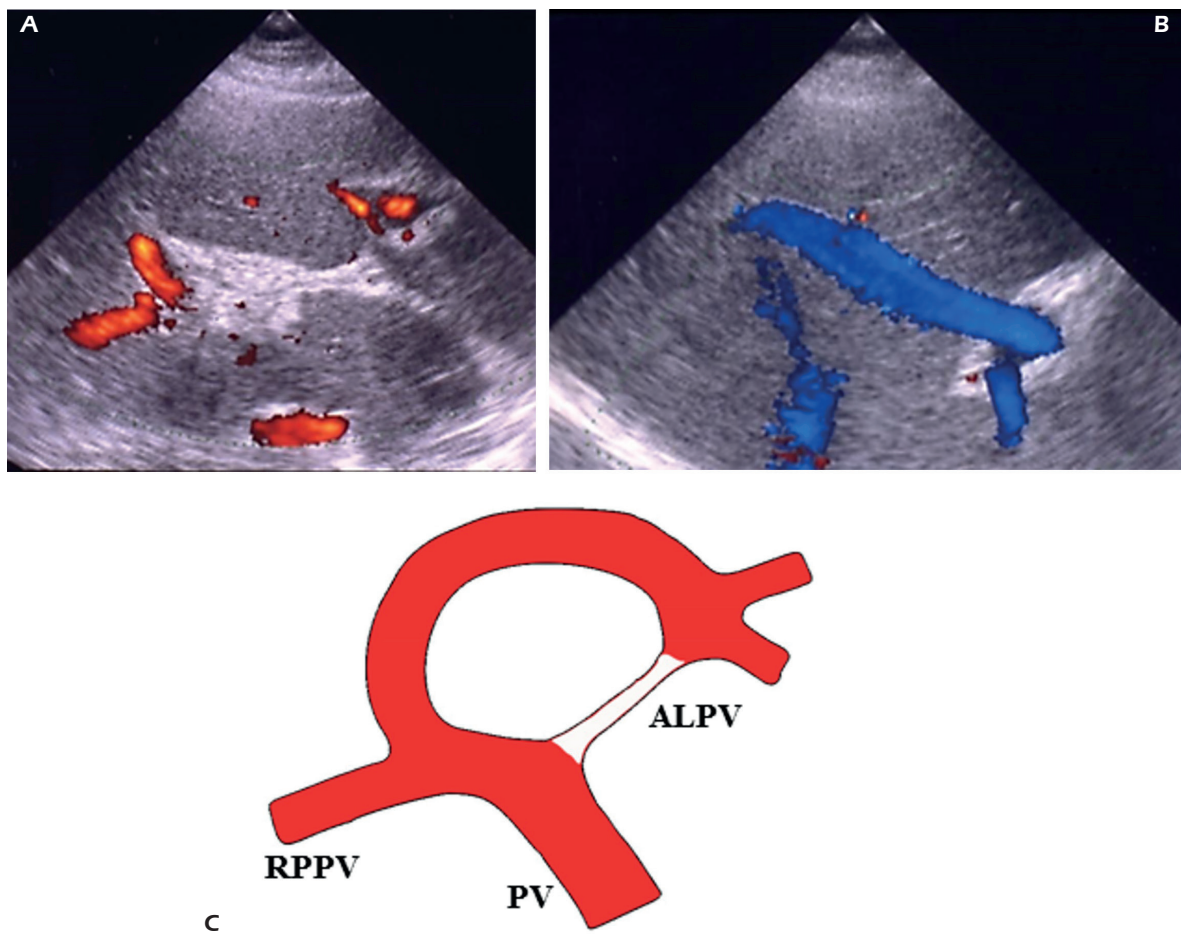


Figure 5. Portal vein variants – type 4: absence of portal vein bifurcation. *A*, Color Doppler sonography shows absence of portal vein bifurcation. *B*, Color Doppler shows a large vein coming from segment VIII and entering the distal segment of the left portal vein. *C*, PV: portal vein; RPPV: right posterior portal vein; ALPV: absent left portal vein.

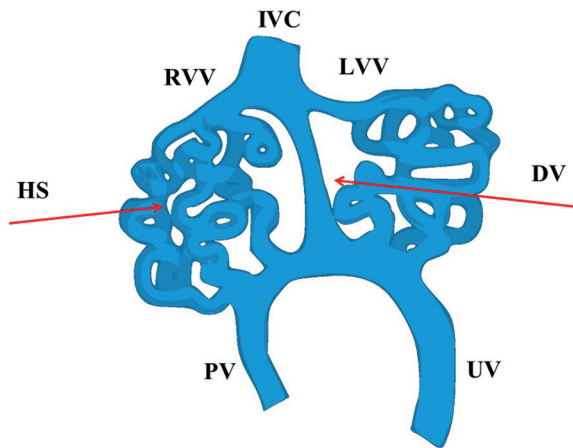


Figure 6. Embryological development of the portal system and inferior vena cava. IVC: inferior vena cava; RVV: right vitelline vein; LVV: left vitelline vein; DV: ductus venosus; HS: hepatic sinusoids; UV: umbilical vein; PV: portal vein.

- Extrahepatic (EPSVS)
- Intrahepatic (IPSVS)

According to the perfusion anomalies PSVS are subdivided into:

Type 1: liver is not perfused with portal blood because of complete shunt of portal blood flow into systemic circulation. Liver transplantation is the only effective treatment in critical cases.

Type 2: a partial shunt is present with residual portal blood flow into liver parenchyma. In this case persistent portal circulation allows shunt surgical closure or embolization^{9,10}.

Congenital Extrahepatic Portosystemic Venous Shunt – EPSVS

Two types of EPSVS have been described: complete portosystemic shunts without portal perfusion to the liver are defined as type I, whereas partial shunts with a remaining degree of portal blood flow to the liver are defined as type II.

In type I portal vein is absent or atresic; type I shunts are further classified into those in which the splenic vein (SV) and superior mesenteric vein (SMV) drain separately into a systemic vein (type 1a) and those in which the SV and SMV drain together after joining to form a common trunk (type 1b), without supplying the liver (Figure 7). In type II portal vein is normal or hypoplastic (Figure 8).

Congenital extrahepatic portosystemic shunts with abnormal venous drainage into a systemic vein other than the inferior vena cava (IVC) are classified as subtypes of type 1 or 2; recipient systemic vein may be left renal vein (Figure 9), right renal vein or azygos vein; more rarely, a few cases of a direct communication between inferior mesenteric vein (or its superior rectal tributaries) and common or internal iliac veins have been described.

At CT and MRI, portal vein may be absent, hypoplastic, or of normal size. When portal vein is atresic, hepatic artery often becomes enlarged and is the only vessel seen within the hepatoduodenal ligament (Figure 10)¹¹⁻¹³.

Moreover, EPSVS, especially type 1a, is associated with additional malformations, more often development anomalies of the spleen (poly-

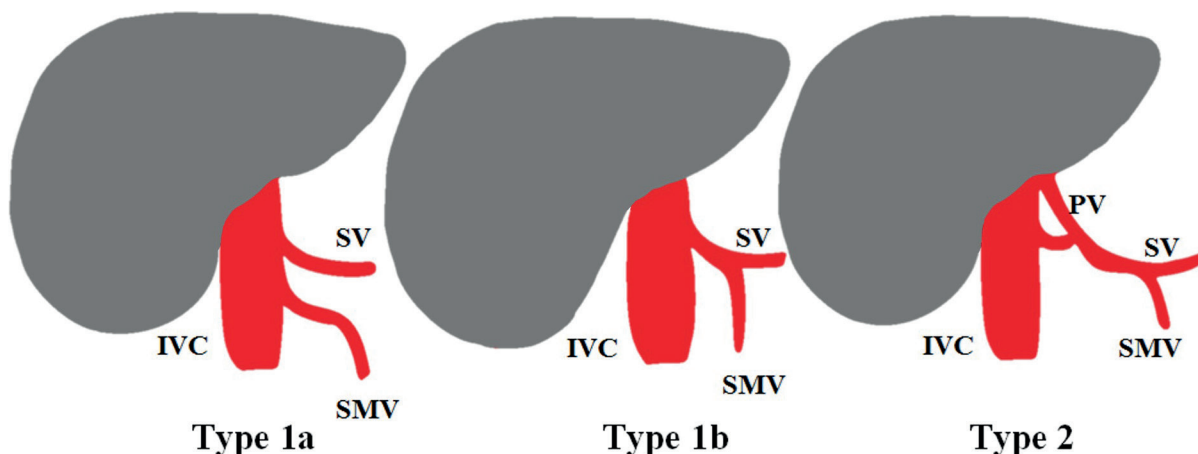


Figure 7. Classification of congenital extrahepatic portosystemic shunts. *Type 1a:* splenic vein (SV) and superior mesenteric vein (SMV) drain separately into inferior vena cava (IVC). *Type 1b:* the SV and SMV drain together after joining to form a common trunk without supplying the liver. *Type 2:* the liver is perfused with portal blood in the presence of a partial shunt; the portal vein (PV) is normal or hypoplastic

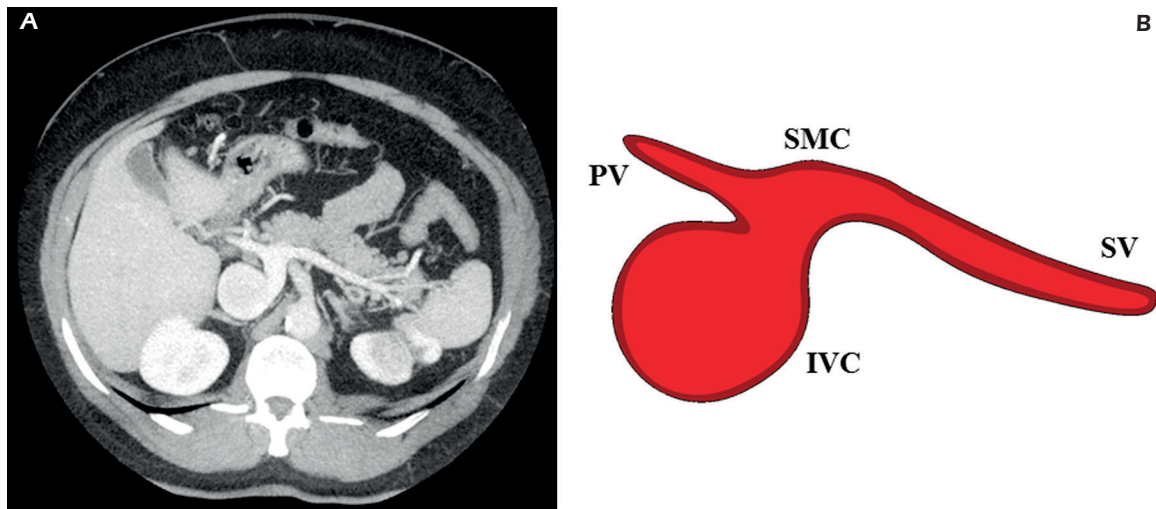


Figure 8. Congenital extrahepatic portosystemic shunts – type 2. **A**, Contrast-enhanced CT on portal venous phase and axial MIP reconstructions show the presence of a congenital shunt connecting the splenic vein and the splenomesenteric confluence to the inferior vena cava. The liver is perfused with portal blood in the presence of a partial shunt. The portal vein is hypoplastic. **B**, SV: splenic vein; SMC: splenomesenteric confluence; IVC: inferior vena cava; PV: portal vein.

splenia), heart circulatory system (septal defects, patent ductus arteriosus, and tetralogy of Fallot), biliary system (congenital biliary atresia, choledochal cyst), genitourinary system (cystic dysplasia of kidneys), and skeletal system (radial hypoplasia). Acquired shunts due to portal hypertension are common.

EPSVS are often asymptomatic, especially patients with partial shunt (type 2). When present, symptoms are related to the abnormal liver development, to the portosystemic shunt, and to other

congenital malformations eventually associated.

Patients with EPSVS are also prone to develop intrahepatic tumors such as nodular regenerative hyperplasia, focal nodular hyperplasia (FNH), and adenomas with high risk of malignant transformation. Because of reduction or complete loss of hepatic portal perfusion the arterial flow increases. The development of tumors may be a consequence of excessive arterIALIZATION of the liver, lack of portal blood flow, increased circulating levels of hepatic growth factors (e.g., insulin,

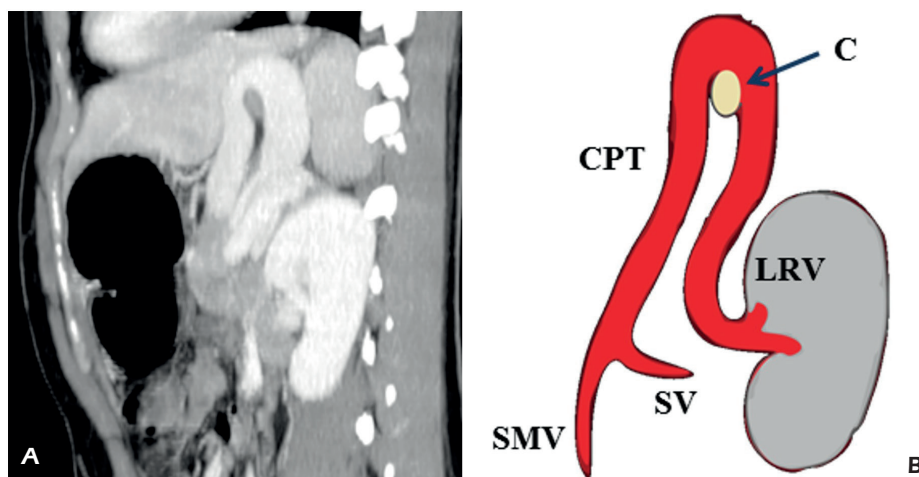


Figure 9. Congenital extrahepatic portosystemic shunts – type 1b: abnormal venous drainage into left renal vein. **A**, Contrast-enhanced TC – MIP reconstructions. A common portal trunk formed by the confluence of the splenic and the superior mesenteric vein courses upward parallel to the aorta, describes a loop over the cardias and then runs caudally to join the left renal vein. **B**, SV; splenic vein; SMV: superior mesenteric vein; CPT: common portal trunk; C: cardias; LRV: left renal vein

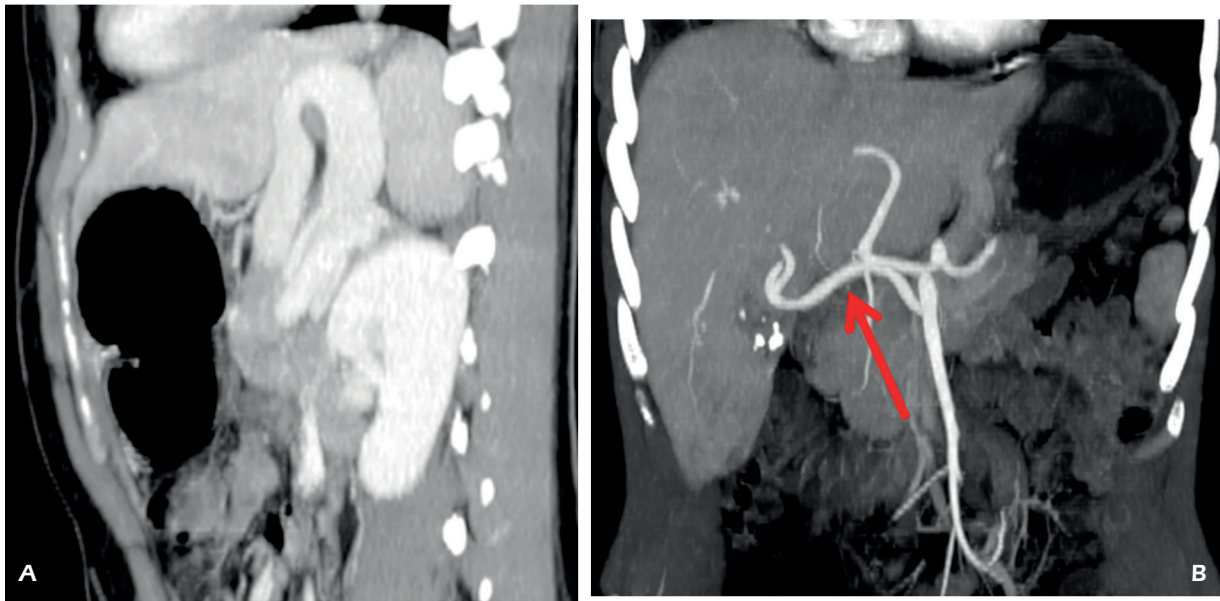


Figure 10. Congenital extrahepatic portosystemic shunts type 1b causing arterial hypertrophy. *A*, Axial contrast-enhanced CT shows absence of portal bifurcation and of intrahepatic portal branches. *B*, Coronal MIP reconstruction shows arterial hypertrophy, because of the complete loss of hepatic portal perfusion. A right hepatic artery from the superior mesenteric artery is present (*arrow*).

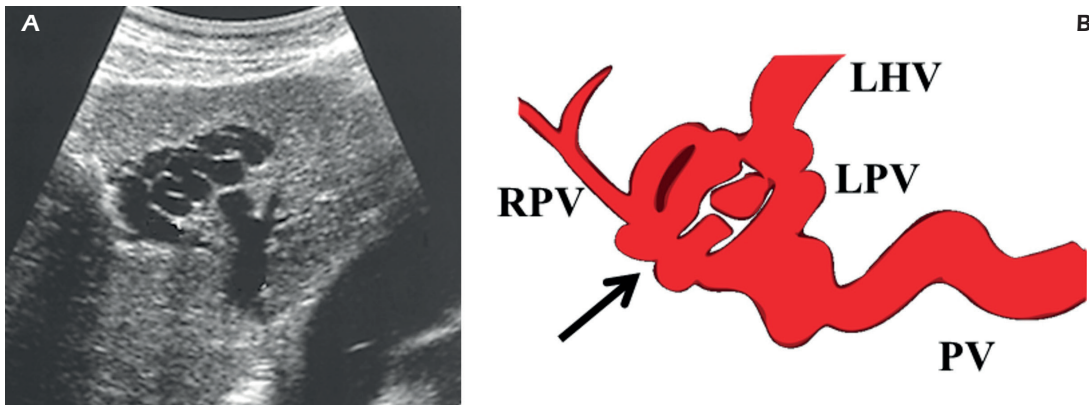


Figure 11. Acquired IPSVS in a Patient with liver cirrhosis and portal hypertension. *A*, US shows multiple serpiginous vessels at the III hepatic segment between the left portal branch and the left hepatic vein which is enlarged. *B*, PV: portal vein; LPV: left portal vein; LHV: left hepatic vein; RPV: right portal vein.

glucagon, hepatocyte growth factor) or a combination of all these factors¹⁴.

In patients with large portosystemic shunts hepatic encephalopathy may develop¹⁵.

Liver transplantation is the only effective treatment for symptomatic type I EPSVS. A therapeutic approach for type II could be surgical closure of the shunt or embolization.

Nevertheless, the high rates of association with liver tumor and other malformations suggest the need for thorough search for other anomalies and

a straight surveillance of liver lesions for concurrent malignancy.

Congenital Intrahepatic Portosystemic Venous Shunt – IPSVS

Intrahepatic portosystemic venous shunts (IPSVS) are defined as anomalous communications between intrahepatic portal vein and systemic veins, that are at least partly located inside the liver.

The etiology of IPSVS may be either congeni-

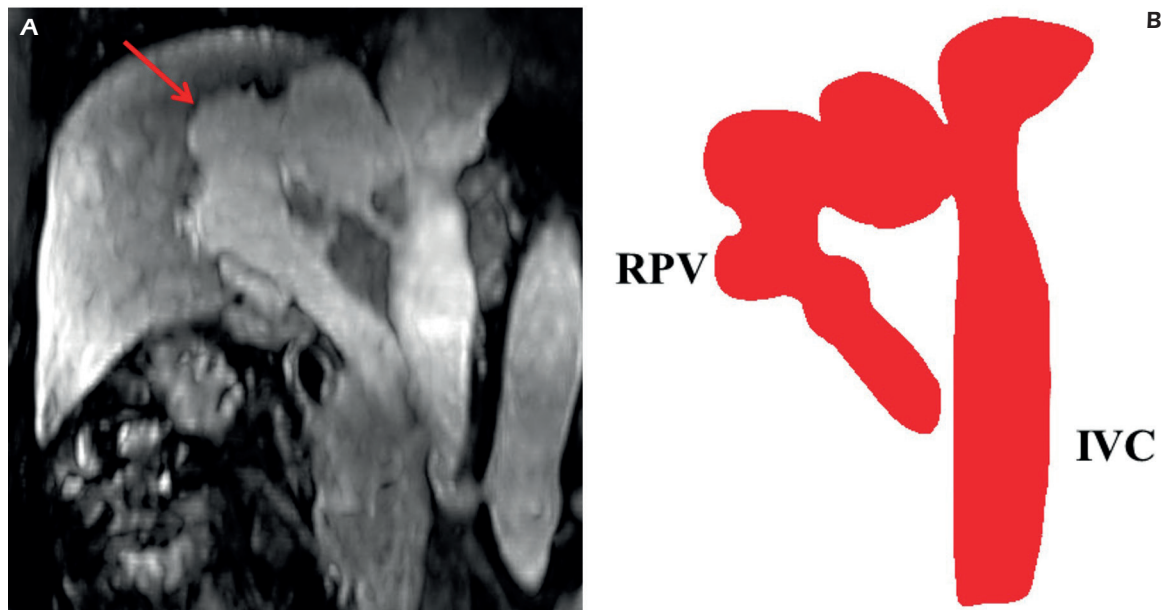


Figure 12. Congenital intrahepatic portosystemic shunts - type 1. **A**, Contrast-enhanced MRI – coronal MIP reconstruction. A single large vessel (*arrow*) runs from the right branch of the portal vein to the posterior surface of the liver and turns medially to enter the inferior vena cava just below the insertions of the hepatic veins. **B**, RPV: right portal vein; IVC: inferior vena cava.

tal or acquired, developing in response to portal hypertension (Figure 11).

A morphological classification of IPSVS was proposed by Park et al in 1990¹⁶:

Type 1: a single vessel runs from the right branch of portal vein to the posterior surface of the liver and enters inferior vena cava (Figure 12).

Type 2: is a localized peripheral shunt in which single or multiple communications are found

between peripheral portal and hepatic veins in one hepatic segment (Figure 13).

Type 3: is an aneurismal communication with peripheral portal and hepatic veins connected through an aneurysm (Figure 14).

Type 4: multiple communications between peripheral portal and hepatic veins are present in both hepatic lobes.

The first two varieties are the most common. Embolization or surgery is performed if the shunt is symptomatic.

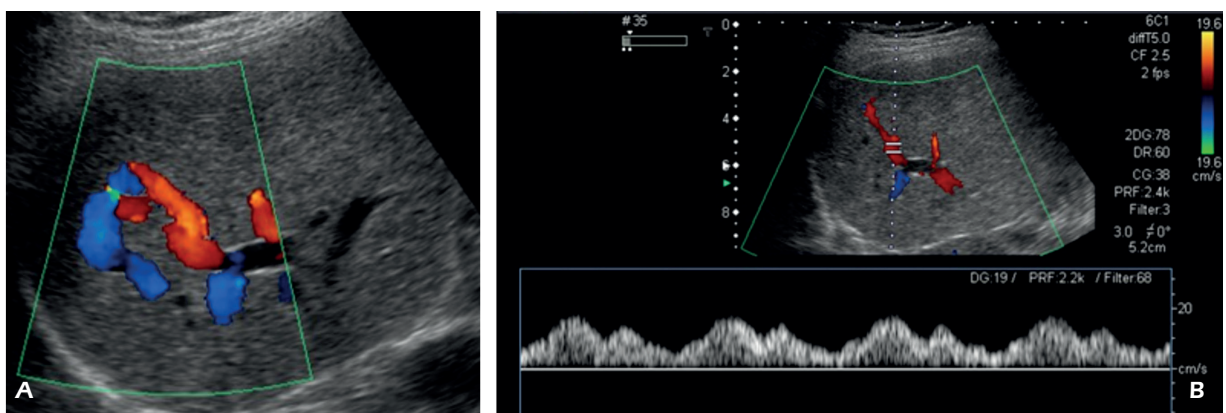


Figure 13. Congenital intrahepatic portosystemic shunts - type 2. **A**, Color Doppler US shows a communication between peripheral portal and hepatic veins in segment VII. **B**, The Doppler waveform of the portal vein is abnormal and shows cardiac modulation due to the direct communication with the central venous system

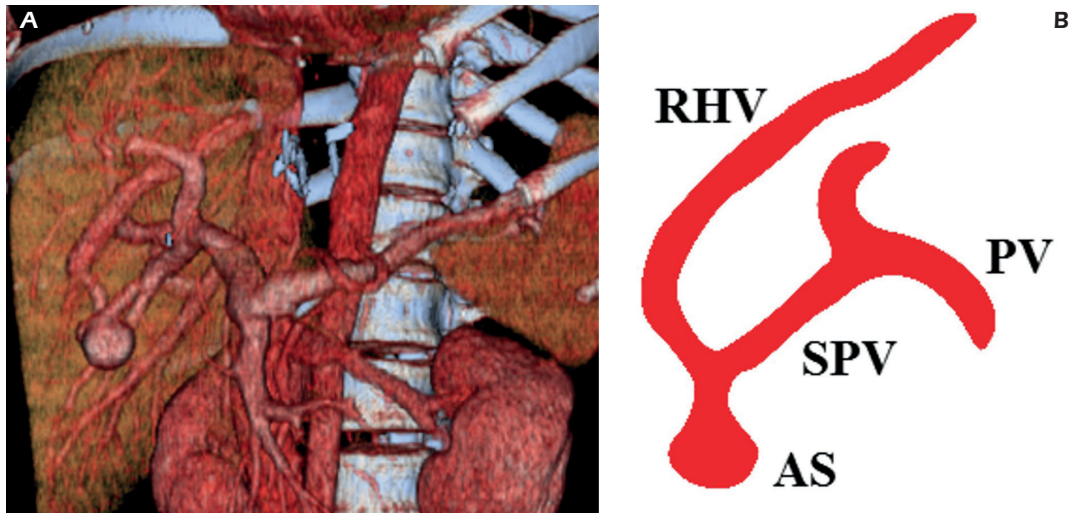

Figure 14. Intrahepatic portosystemic shunts - type 3. **A**, CT shows an aneurismal shunt in the VI hepatic segment in a subcapsular location. Volume rendering 3D reconstruction shows the afferent portal branch and efferent hepatic vein drainage of the aneurismal intrahepatic portosystemic venous shunt. **B**, PV: portal vein; SPV: segmental portal vein; RHV: right hepatic vein; AS: aneurismal shunt

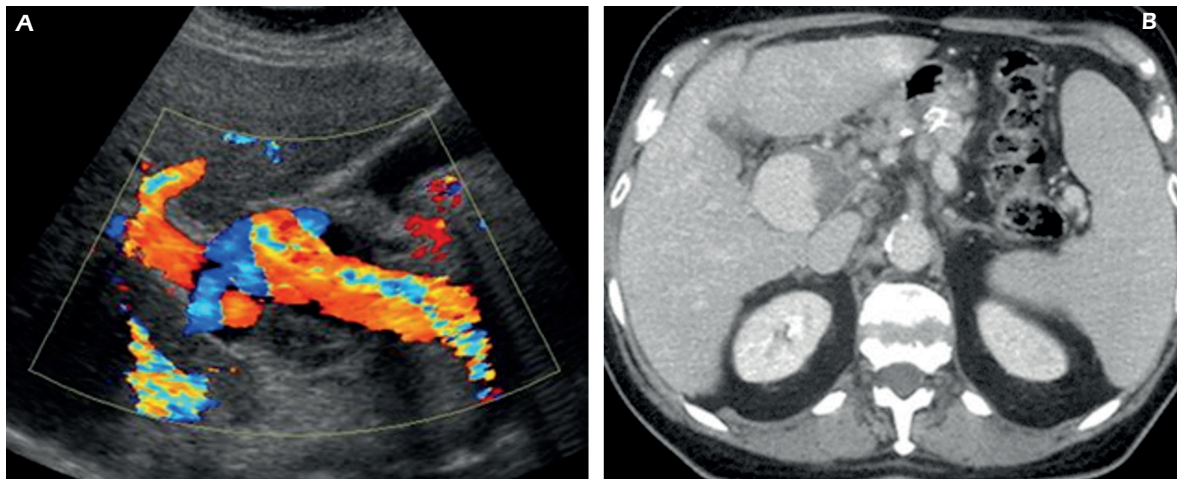


Figure 15. Portal vein aneurysm (PVA). **A**, Color Doppler Ultrasonography shows an aneurysm of the main portal vein with thrombotic mural apposition and turbulent flow within. **B**, Contrast-enhanced CT scan at the level of the hepatic hilum confirms the PVA with partial mural thrombosis.

Patent Ductus Venosus

Patent ductus venosus (PDV) is a rare form of congenital portosystemic shunt. Fewer than 20 cases of PDV in adults have been reported in the literature.

In the fetus, the ductus venosus shunts approximately half of the blood flow of the umbilical vein directly to the inferior vena cava. Thus, it allows oxygenated blood from the placenta to bypass the liver.

PDV is categorized as type 2 IPSVS, in which intrahepatic portal venous supply is preserved.

Symptoms of this disorder include encephalopathy, hyperammonemia, jaundice and liver dysfunction.

Portal Vein Aneurysm – PVA

Portal vein aneurysm (PVA) is a rare clinical entity that has been described as a focal dilatation that can affect both intra- and extrahepatic branches (Figure 15). Two major etiologies, acquired and congenital, have been proposed. Portal hypertension and chronic liver disease have been identified as the major causes of acquired aneurysm. Congenital aneurysm can be related to weakness in the portal vein wall.

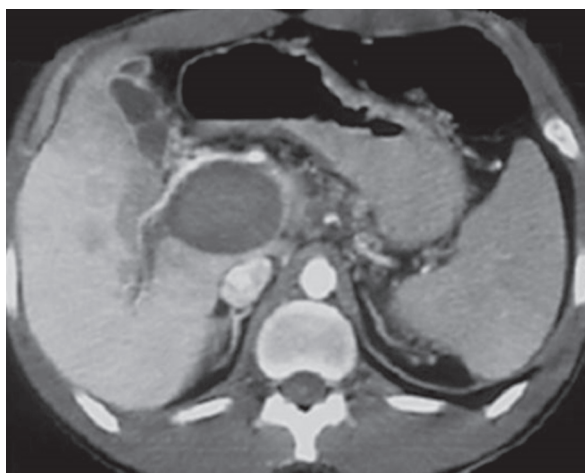


Figure 16. Thrombosed portal vein aneurysm. Contrast-enhanced CT scan at the level of the hepatic hilum shows an aneurysm of the main portal vein with complete thrombosis.

PVA are usually asymptomatic, unless a complication occurs. Complications of PVA include thrombosis, aneurysmal rupture, portosystemic shunts, and compression on adjacent viscera (Figure 16)¹⁷.

Conclusions

A reliable preoperative imaging of vascular anatomy is mandatory relating to recent developments in liver surgery and in interventional radiology, including portal vein embolization, anatomic resection and transplantation. It is a fact that in this group of patients the portal vein is almost always depicted on preoperative cross-sectional imaging, and critical attention to portal vein anatomy may prevent significant complications.

Ultrasonography can assess portal venous anatomy, anatomic variants and congenital anomalies of the portal vein; Color and Power Doppler showing the presence and the direction of flow are essential for proper diagnosis; spectral tracings and velocity measurements can evaluate hemodynamic changes in liver perfusion.

CT or MR imaging provide proper anatomical information and an overall picture of splanchnic vascularization and three-dimensional (3D) reformation make portal vein variants easier to recognize. Angiography is reserved only in cases in which treatment is considered necessary.

Conflict of interest

The authors declare no conflicts of interest.

References

- 1) GIULIANTE F, ARDITO F, VELLONE M, NUZZO G. Liver resections for hilar cholangiocarcinoma. *Eur Rev Med Pharmacol Sci* 2010; 14: 368-370.
- 2) SCHMIDT S, DEMARTINES N, SOLER L, SCHNYDER P, DENYS A. Portal vein normal anatomy and variants: implication for liver surgery and portal vein embolization. *Semin Intervent Radiol* 2008; 25: 86-91.
- 3) GIUGA M, DE GAETANO AM, GUERRA A, INFANTE A, IEZZI R, SPINELLI I, SICILIANO M, GRIECO A, RAPACCINI GL, GASBARRINI A, POMPII M, BONOMO L. An update on clinical applications of hepatospecific contrast media in magnetic resonance imaging of liver parenchyma. *Eur Rev Med Pharmacol Sci* 2016; 20: 2515-2525.
- 4) ÖZBÜLBÜL Nİ. Congenital and acquired abnormalities of the portal venous system: multidetector CT appearances. *Diagn Interv Radiol* 2011; 17: 135-142.
- 5) ATASOY C, OZYÜREK E. Prevalence and types of main and right portal vein branching variations on MDCT. *AJR Am J Roentgenol* 2006; 187: 676-681.
- 6) KOÇ Z, ULUSAN S, OĐUZKURT L, TOKMAK N. Venous variants and anomalies on routine abdominal multidetector row CT. *Eur J Radiol* 2007; 61: 267-278.
- 7) Abernethy J. Account of two instances of uncommon formation in the viscera of the human body. *Philos Trans R Soc Lond* 1793; 17: 292-299.
- 8) BHARGAVA P, VAIDYA S, KOLOKYTHAS O, KATZ DS, DIGHE M. Hepatic vascular shunts: embryology and imaging appearances. *Br J Radiol* 2011; 84: 1142-1152.
- 9) HU GH, SHEN LG, YANG J, MEI JH, ZHU YF. Insight into congenital absence of the portal vein: is it rare? *World J Gastroenterol* 2008; 14: 5969-5979.
- 10) STRINGER MD. The clinical anatomy of congenital portosystemic venous shunts. *Clin Anat* 2008; 21: 147-157.
- 11) ALONSO-GAMARRA E, PARRÓN M, PÉREZ A, PRIETO C, HIERRO L, LÓPEZ-SANTAMARÍA M. Clinical and radiologic manifestations of congenital extrahepatic portosystemic shunts: a comprehensive review. *Radiographics* 2011; 31: 707-722.
- 12) SHINKAI M, OHHAMA Y, NISHI T, YAMAMOTO H, FUJITA S, TAKE H, ADACHI M, TACHIBANA K, AIDA N, KATO K, TANAKA Y, TAKEMIYA S. Congenital absence of the portal vein and role of liver transplantation in children. *J Pediatr Surg* 2001; 36: 1026-1031.
- 13) MURRAY CP, YOO SJ, BABYN PS. Congenital extrahepatic portosystemic shunts. *Pediatr Radiol* 2003; 33: 614-620.
- 14) GRAZIOLI L, ALBERTI D, OLIVETTI L, RIGAMONTI W, CODAZZI F, MATRICARDI L, FUGAZZOLA C, CHIESA A. Congenital absence of portal vein with nodular regenerative hyperplasia of the liver. *Eur Radiol* 2000; 10: 820-825.
- 15) AKAHOSHI T, NISHIZAKI T, WAKASUGI K. Portal-systemic encephalopathy due to a congenital extrahepatic portosystemic shunt: three cases and literature review. *Hepatogastroenterology* 2000; 47: 1113-1116.
- 16) PARK JH, CHA SH, HAN JK, HAN MC. Intrahepatic portosystemic venous shunt. *AJR Am J Roentgenol* 1990; 155: 527-528.
- 17) LAU H, CHEW DK, BELKIN M. Extrahepatic portal vein aneurysm: a case report and review of the literature. *Cardiovasc Surg* 2002; 10: 58-61.