



Short note [Nota corta]
SHEEP FETAL GOITER: STUDY CASE IN MEXICO¹

[BOCIO FETAL OVINO: ESTUDIO DE CASO EN MÉXICO]

Ignacio Arturo Domínguez-Vara^{1*}, Félix Salazar-García¹,
Roberto Montes de Oca-Jimenez², Imelda Medina-Torres²,
Jorge Genaro Vicente-Martínez³ and Juan Manuel Pinos-Rodríguez³

¹Departamento de Nutrición Animal; ²Centro de Investigación y Estudios Avanzados en Salud Animal

Facultad de Medicina Veterinaria y Zootecnia, Universidad Autónoma del Estado de México, 50090, Toluca, México

³Facultad de Medicina Veterinaria y Zootecnia, Universidad Veracruzana, Veracruz, México. E-mail: igy92@hotmail.com

*Corresponding author

SUMMARY

In a small-scale sheep flock located in the State of Mexico with eight ewes and one stud, four ewes had clinical signs of endemic goiter, two aborted fetuses were used for a diagnostic study. In fetuses, thyroid gland samples were used for histopathological evaluation, and liver, heart, kidney and skeletal muscle samples were used to measure selenium. In the ewes the blood serum profile of thyroid hormones was measured by ELISA test. In fetuses there was an increment of thyroid gland size (6-8 cm), firm consistency and red intense color, as well as scarce fleece and subcutaneous edema; there were hyperplasia and hypertrophy of follicular cells of thyroid, with cube-like aspect, diffuse expanded, irregular shape and distension with presence of vacuoles and abundant eosinophilic colloid. The selenium concentrations in liver and kidney of fetuses were low (0.25 and 0.90 ppm). In ewes, the thyroxin (T₄) and triiodothyronine (T₃) contents were deficient (0.48±0.08 and 4.14±0.29 µg dL⁻¹) and the ratio (T₄:T₃) was very broad (1:8.6 µg dL⁻¹). It is concluded that the lambs suffered from colloidal goiter; thyroid hormones concentrations in ewes were low and confirmed a thyroid metabolism altered; additionally goiter may be aggravated by selenium deficiency.

Keywords: sheep; goiter; iodine; selenium; thyroxin; triiodothyronine; TSH.

RESUMEN

En un rebaño ovino de pequeña escala, localizado en el Estado de México, con ocho ovejas y un semental, de las cuales cuatro ovejas presentaron signos clínicos de bocio endémico, dos fetos abortados fueron usados para un estudio de diagnóstico. De ambos fetos, muestras de la glándula tiroidea fueron usadas para la evaluación histopatológica, y muestras de hígado, corazón, riñón y músculo esquelético fueron usadas para medir el contenido de selenio. En el suero sanguíneo de las ovejas se midió el perfil de las hormonas tiroideas por la prueba de ELISA. En ambos fetos hubo un aumento de tamaño de la glándula tiroidea (6-8 cm), con consistencia firme y color rojo intenso, así como escasas de vellón y edema subcutáneo; también hubo hiperplasia e hipertrofia de las células foliculares de la tiroidea, con aspecto cuboide, expansión difusa, contorno irregular y distensión con presencia de vacuolas y abundante coloide eosinofílico. Las concentraciones de selenio en el hígado y riñón fueron bajas (0.25 y 0.90 ppm). En las ovejas los contenidos de las hormonas tiroxina (T₄) y triyodotironina (T₃) fueron deficientes (0.48±0.08 y 4.14±0.29 µg dL⁻¹), y la relación (T₄:T₃) fue muy amplia (1:8.6 µg dL⁻¹). Se concluye que los corderos sufrieron de bocio coloide. Las concentraciones de hormonas tiroideas en las ovejas fueron bajas y confirmaron un metabolismo tiroideo alterado; adicionalmente, el bocio puede ser agravado por la deficiencia de selenio.

Palabras clave: ovinos; bocio; iodo; selenio; tiroxina; triiodotironina; TSH

¹ Submitted March 20, 2017 – Accepted August 02, 2017. This work is licensed under a [Creative Commons Attribution 4.0 International License](https://creativecommons.org/licenses/by/4.0/)

INTRODUCTION

Iodine (I) deficiency causes abnormal growth of the thyroid gland, a condition more commonly known as goiter. In the nineteenth century the relationship of iodine with goiter was found in humans and farm animals, indicating that the incidence of endemic goiter is inversely related to iodine content in soil, food and water in several areas of the world; in addition, it was reported that endemic goiter symptoms were similar to those of functional thyroid deficiency (Underwood and Suttle, 1999). In all continents of the earth have been described extensive areas with predisposition, in humans and farm animals, to endemic goiter, initially the main cause is associated with a lack of iodine in the environment, which can be reversed by supplying more dietary iodine salts. Iodine deficiency in humans and farm animals predisposes goiter development, current troublesome condition in many parts of the world, which is estimated that more than 13% of the world's human population suffers from disorders caused by I deficiency (Berger, 2000).

There is now increased interest in the problems caused by iodine deficiency in the development and maturation of the central nervous system of humans and livestock species (Hetzl, 1991). The main factors that limit the structural and functional capacity of human and animal thyroid gland are: a) severe environmental iodine deficiency, b) presence of goitrogenic substances in foods, c) Selenium (Se) and iron (Fe) dietary deficiency, d) cold stress, e) environmental contamination with endocrine disruptors (Underwood and Suttle, 1999).

In sheep, the metabolism of the thyroid gland is fundamental for fetal growth and development (Medeiros et al., 1993; Piosik et al., 1997). Thyroxin (T_4) synthesis and the conversion of it into triiodothyronine (T_3) depend on the integrity of the thyroid gland and the opportune supply of the substrates in the required amounts. The synthesis of T_4 and T_3 in the mother and its transference to the fetus have been studied in several species and its deterioration causes goiter (Medeiros et al., 1993). Goiter can occur in mammals and birds as a consequence of hyperplasia and hypertrophy of the thyroid follicular cells (Kategile et al., 1978). The causes that induce thyroid hyperplasia are: deficient diets in I that produce simple goiter affection with scarce or null production of thyroid hormones (Corah and Ives, 1991). Recent studies have shown the potential interactions between I and Se in the health and reproductive performance of the animal, deficiency of Se can cause indirect or induced goiter, as it is essential in the diiodinase enzymes which transform thyroxin into triiodothyronine (Maddocks

et al., 1985); likewise certain goiter-genic substances of plants from the *Brassicaceae* family (Barberan and Valderrabano, 1987) which interfere with the synthesis of thyroxin. In this case the concentrations of (T_4) and (T_3) in blood can be reduced, i.e., detection through the hypothalamus which stimulates hypophysis so that the secretion of TSH increases, causing hyperplasia and hypertrophy of the thyroid follicular cells (Astera et al., 1999). The objective of this study is to describe and to inform on the occurrence of an endemic goiter case in fetuses aborted at the end of pregnancy, considering it the first case witnessed in sheep flocks in the State of Mexico with no documented antecedents of similar cases in Mexico.

MATERIALS AND METHODS

Description of the case

The fetuses aborted, approximately with 4.5 months of pregnancy, were placed on ice and transported the same day, 35 km, at Center of Research and Advanced Studies on Animal Health of the Faculty of Veterinary Medicine and Animal Science of the Autonomous University of the State of Mexico. The two sheep male fetuses, Suffolk x Rambouillet genotype came from a small sheep flock comprised of a stud and eight mature ewes, located in Jocotitlan, Mexico State. About clinic history, the sheep flock is of small holder scale and is locked overnight in a dirt floor pen and during the day grazing (6 to 8 h) in a native prairie of grass *Pennisetum clandestinum*, in the afternoon receives corn stover and small amounts of a concentrate based on sorghum, maize grains, wheat bran, soybean and canola meals. The water source is drinkable for free access. The sheep were not vaccinated, did not receive mineral supplements and the application of vitamins and antiparasitic agents are sporadic. Two ewes of the flock died without determining the causes; four ewes showed clinical signs of endemic goiter size incremented in the cranial ventral cervical region of the neck at a severe degree, and three of them aborted during the same season. The ram and the other two ewes showed an incremented moderate size, of the cranial ventral cervical region of the neck.

Postmortem evaluation

The postmortem study of the fetuses was carried out immediately the same day after the fetuses were aborted, in accordance with the technique described by Martin and Aitken (2000). Thyroid gland was inspected and evaluated in both fetuses; samples of about 1 cm³ were fixed in buffered formaldehyde at 10%, pH 7.2. Small parts of tissues were cut and introduced newly in plastic cassettes to complete their

fixation in buffered formaldehyde at 10%, then were included into paraffin and blocks were formed. The pieces included in paraffin were cut with a rotary microtome, Reichert-Jung brand, model Biocut 2035 (Leica, Germany), with affixed disposable blades of the Reichert (Leica) brand, model 819. The thickness of the cuts was 4-5 mm and they were stained with Hematoxiline-eosine.

Thyroid profile determination

Blood samples from jugular vein were taken from four ewes with severe clinical signs of endemic goiter, and placed in vacutainer tubes without anticoagulant and centrifuged at relative centrifugal force of 1613 g, in order to obtain blood serum. A ELISA tests (Access, Beckman Instruments, Inc. USA) was used to determine the hormonal thyroid profile by the quantifications and calculation of free thyroxin concentration (FT_4), the percentage of fixation to thyroxin (TU), total level of thyroxin (TO_4), total level of triiodothyronine (TO_3), thyroxin average (FTI) and thyroid stimulating hormone (TSH).

Selenium quantification

Samples of liver, kidney, heart and skeletal muscle of the two ovine fetuses were taken to determine the concentrations of selenium by atomic absorption spectrophotometry (AAS) (AOAC, 1990). Samples were dried at 100 °C for 24 hours and later pulverized in a porcelain mortar. Five grams of tissue were mixed with a solution of magnesium oxide and magnesium nitrate and dried in a stove and incinerated in a muffle at 450 °C for 24 h. Ash was dissolved in 50 mL of 1 N hydrochloric acid and preserved in hermetic flasks until analysis. The calibration curve and AAS (Perkin Elmer 2380) conditions were performed according to Beaty (1978).

RESULTS AND DISCUSSION

Macroscopic evaluation

In ovine fetuses evident increment of thyroid gland size (from 6 to 8 cm in length), firm consistency and intense red color were observed (Figures 1A and 1B). Despite the fetuses reached the end of pregnancy, there was scarce fleece presence and light subcutaneous edema, but there were no morphological or pathological changes observed in other organs. The abnormal macroscopic findings in the thyroid glands of fetus evaluation suggest a case

of colloidal goiter. Changes in skin and extension of fleece growth are common characteristics of thyroid dysfunction in sheep (Ludcke and Schone, 1988).

Histopathology evaluation

The thyroid gland in both fetuses presented hyperplasia and hypertrophy of the follicular cells with a cube-like aspect, laid on one, two or three layers making small papillary structures which are projected in the light of the follicle (Figures 1C and 1D). The follicles were diffusely expanded, irregularly shaped and with the aspect of macro follicles distended by the presence of abundant colloid lightly eosinophilic. Colloidal goiter constitutes an involution phase of the diffuse hyperplastic goiter, where hyperplastic cells continue producing colloid, yet there is a decrease in the endocytosis of the colloid (McGavin *et al.*, 2001).

Selenium in ovine fetuses

Selenium concentrations (ppm) in the organs of ovine fetuses were: liver 0.15 ± 0.03 , kidney 0.26 ± 0.07 , skeletal muscle 0.29 ± 0.1 , and cardiac muscle 0.11 ± 0.02 . According to Puls (1994), liver Se concentration of 0.25 ppm is slightly deficient "marginal", 0.90 ppm in kidney is deficient and 0.09 ppm in striated skeletal muscle is adequate. It indicates that liver and kidney are deficient in Se. The secondary hypothyroidism can be caused by the reduction of the conversion of T_4 to T_3 , and then the concentration of T_4 can be deceitful, hence, the measurement of T_3 can be more effective in the diagnosis of thyroid dysfunction. The hypothyroidism has been associated to insufficiency of Se. Wichtel *et al.* (1996) found lower concentrations of T_3 ($P < 0.04$) in dairy cows which responded to the supply of Se compared to cows with no response (1.81 vs 2.06 nMol L^{-1}); and the concentrations of T_4 were reduced in cows treated with Se (66 vs 99 nMol L^{-1}).

Thyroid profile in serum blood of ewes

The blood serum of ewes had total thyroxin concentrations below the range considered by Puls (1994) as "marginal" (< 5.5 μg dL^{-1}); likewise, the content of total triiodothyronine was under leveled (< 6.5 μg dL^{-1}) in the four ewes, they had low contents (< 0.05 μg dL^{-1}) of thyroid stimulating hormone also. The thyroid profile (Table 1) indicates that the concentration of TO_4 was marginal, whereas that of T_3 was deficient, in relation to reference values (Puls, 1994).

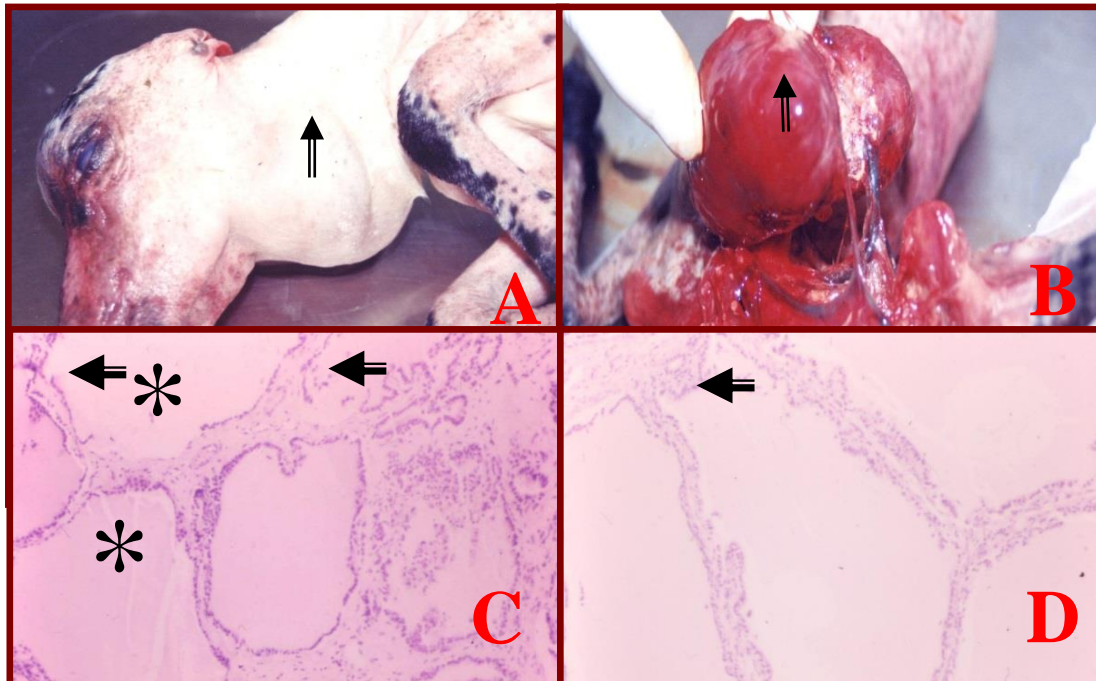


Figure 1. A. Aborted lamb at the end of gestation, with increment in size in the anterior ventral cervical region (⇧); B. Thyroid gland with increment in size, firm consistency and pale to intense red color (⇧); C. Thyroid gland, follicles with diffuse dilatation and abundant presence of colloid (*), 10x; C and D. Thyroid gland, hyperplasia of the follicular cells (⇐), C 10x; D 40x.

Table 1. Total concentrations of thyroxin (TO₄), free thyroxin (FT₄), fixation percentage to thyroxin (TU), total triiodothyronine (TO₃) and thyroid stimulating hormone (TSH) in blood serum from ewes with clinical signs of goiter.

Hormone	Ewe 1	Ewe 2	Ewe 3	Ewe 4	Mean ± S.E.	Reference Values ¹
TO ₄ (µg dL ⁻¹)	5.47	2.65	3.64	5.25	4.25 ± 1.34	4.7-5.5 (“marginal”) ² 6.0-6.6 (adequate)
FT ₄ (µg dL ⁻¹)	0.52	0.43	0.39	0.58	0.48 ± 0.08	
TU (%)	26.50	26.90	28.30	26.00	26.92 ± 0.98	
TO ₃ (µg dL ⁻¹)	4.11	4.07	4.54	3.84	4.14 ± 0.29	6.5 (deficient) 12.4 (adequate)
TSH (µg dL ⁻¹)	0.01	0.02	0.03	0.04	0.025 ± 0.01	

¹ Normal concentrations of T₄ and T₃ and deficient in serum from adult sheep (Puls, 1994).

² Slightly deficient “marginal”

Pregnancy ewes with I deficiency and a low concentration of thyroid hormones can develop goiter and transmit it to their fetuses (Underwood and Suttle, 1999). Colloidal goiter is a consequence of TSH decreasing in the serum, which is manifested in

the thyroid gland as lesser vascularization and the presence of distended follicles by the accumulation of colloid (Asteria *et al.*, 1999). The fetuses of lambs studied in the present case had TSH and triiodothyronine concentrations under of normal

values, which confirm a state of colloidal goiter and it can induced the abortions (Puls, 1994). Goiter, in small ruminants, can be induced by the ingestion of plants containing goitergenic substances, which can join I in the gastrointestinal tract and inhibit the intestinal I recycling (Underwood and Suttle, 1999), although in the small ovine farm, there were no identified goitergenic plants and feeds related with I deficiency.

Deficiencies of I can cause goiter in sheep, this takes place when flocks are grazed in areas where soils, water and forages have low concentrations of I, and there is not an adequate supplementation of this mineral; deficiencies of micro minerals like Se and Fe can increase the problem of goiter due to iodine deficiency in ewes. Previous study in the same area (Domínguez-Vara and Huerta-Bravo, 2008), have reported high levels of Fe in soils, grass and blood serum of sheep. Likewise, histological studies of the striated skeletal and cardiac muscles of dead lambs during the peri-natal and postnatal stages indicated Se deficiency and congenital nutrimental myopathy, nevertheless, in the same studies no pathological changes in the thyroid gland are indicated (Montes de Oca *et al.*, 1992).

The thyroid profile in serum blood of ewes can be associated with a petty amount of extra thyroid I, it is in a free form and when it transforms into iodine chloride, rapidly moves to the tissues (Hillman and Curtis, 1980), the thyroid efficiency depends on the requirement of the animal and is determined by the secretion of thyrotropine (TRH) and TSH, which determine the secretion rate of T₄. The activation of T₄ is carried out by three deiodinase enzymes type I, II and III, which are dependence on Se (Arthur *et al.*, 1990; Arthur, 1997). An important characteristic of the T₃ hormone, physiologically active, is that this hormone can be synthesized in peripheral places where it is required.

In animals with a normal I level, 80% or more of T₃ can be synthesized in extrathyroid organs, mainly in liver, kidney (Ingar, 1985) and skin (Hetzl and Welby, 1997); however, the proportion can decline when there is I insufficiency. Likewise, in the phase of initial I depletion, the main biochemical manifestation of privation is the lesser concentration of mineral in the thyroid gland (McCoy *et al.*, 1997). During the deficiency phase, the chemical forms of I in the thyroid gland and blood are disproportionately changed, in an attempt to preserve I homeostasis and to use it more efficient; in the I deficiency biochemical changes include the preferential synthesis of T₃ over T₄ and an increment in the relation of monoiodothyrosine T₁ to T₂ (Karmarkar *et al.*, 1974).

In the deterioration of the hormonal thyroid function, besides the supply of absorbable I, dietary deficiency of Se can reduce the transformation of T₄ to T₃ and predispose to a secondary or induced I deficiency (Arthur *et al.*, 1992). Adaptation changes of enzymes that contain Se confirm their participation in the thyroid function. In the present study the liver of fetuses were in normal size and consistency.

This sort of adaptations limits the diagnosis of goiter exclusively from the size of the thyroid gland and the concentration of T₄ in blood.

In the present case study the ratio T₄:T₃ was broad (1:8.6 µg dL⁻¹). Histological abnormalities in the thyroid gland of cows and their calves, with I deficiency, presented lower concentration of I in the thyroid gland and plasma, nevertheless the concentration of T₄ was normal (McCoy *et al.*, 1997).

Despite the values of T₄ in serum can reflect the state of I and the functioning of thyroid gland in sheep, the results can be scarcely satisfactory to evaluate hypothyroidism due to the multiple factors that can affect thyroid secretion. For instance, in sheep, serum concentration of T₄ is usually higher in winter (Andrewartha *et al.*, 1980); whereas intestinal parasitism reduces level of I too (Pichard *et al.*, 1974). In the present case, in addition to the deficiency of I in diet, factors such as the season (cold stress) and parasitism could also have contributed to reduce T₄ concentration in serum, however these factors were no studied.

CONCLUSION

The macroscopic and histopathological findings in the ovine fetuses indicate a typical case of sheep colloidal goiter. The low serum concentrations of T₃ and T₄ thyroid hormones and their broad relation between them in ewes, confirms a disorder in the thyroid metabolism. Selenium deficiencies found in liver and kidney of ovine fetuses are evidence that besides the lack of iodine, Se can be the cause of secondary goiter implied, and thereby aggravate the problem of induced goiter.

REFERENCES

- Andrewartha, K. A., Caple, I. W., Davies, W. D. and McDonald, J. W. 1980. Observations on serum thyroxine concentrations in lambs and ewes to assess iodine nutrition. *Australian Veterinary Journal* 56:18-21.
- AOAC (Association of Official Analytical Chemists). 1990. *Official Methods of Analysis*. 18th ed. AOAC: International, USA.

- Arthur, J. R. 1997. Selenium biochemistry and function. *In: Fischer, P. W. F., L' Abbé. M. R., Cockell, K. A. and Gibson, R. S. (Eds.)* Proceedings of the Ninth International Symposium on Trace Elements in Man and Animals (TEMA 9). NRC. Research Press. Ottawa, Canada, pp. 1-5.
- Arthur, J. R., Nicol, F. and Beckett, G. J. 1990. Hepatic iodothyronine deiodinase: the role of selenium. *Biochemical Journal* 272:537-540.
- Arthur, J. R., Nicol, F., Guo, Y. and Trayhurn, P. 1992. Progressive effects of selenium deficiency on the acute, cold-induced stimulation of type II deiodinase activity in rat brown adipose tissue. *Proceedings of the Nutrition Society* 51:63A.
- Asteria, C. O., Rajanayagam, T. N., Collingwood, L., Persani, R., Romoli, R., Mannavola, D., Zamperini, P., Buzi, F., Ciralli, V. K. K., Chatterjee, R. and Beck-Peccoz, P. 1999. Prenatal Diagnosis of Thyroid Hormone Resistance. *The Journal of Clinical Endocrinology*. 84:405-410.
- Barberan, M. and Valderrabano, J. 1987. Pathological features in thymus and thyroids of lambs fed on turnips. *Veterinary Record* 120:367-368.
- Beaty, R. D. 1978. Concepts, instrumentation and techniques in atomic absorption spectrophotometry. Perkin Elmer: U.S.A.
- Berger, L. L. 2000. Iodine and selenium interactions. *In: Salt and Trace Minerals*. Salt Institute for Animal Nutrition Professional. 32(2):1-4.
- Contreras, P. A., Matamoros, R., Monroy, R., Kruze, J., Leyan, V., Andaur, M., Bohmwald, H. and Wittwer, F. 2002. Effect of a selenium deficient diet on blood values of T₃ and T₄ in cows. *Comparative Clinical Pathology* 11:65-70.
- Corah, L. R. and Ives, S. 1991. The effects of essential trace minerals on reproduction in beef cattle. *Veterinary Clinical Food Animal Practice* 7:41-57.
- Domínguez-Vara, I. A. and M. Huerta-Bravo. 2008. Mineral concentration and interrelationship in soil, forage and blood serum of sheep during two seasons in the Toluca Valley, Mexico. *Agrociencia* 42:173-183.
- Hillman, D. and Curtis, A. R. 1980. Chronic iodine toxicity in dairy cattle: blood chemistry, leucocytes and milk iodine. *Journal of Dairy Science* 63:55-63.
- Hetzel, B. S. 1991. The international Public Health significance of iodine deficiency. *In: Momcilovic, B. (ed.)*. Proceedings of the Seventh International Symposium on Trace Elements in Man and Animal. Dobroonic, Zagreb, Croatia. IMI. Zagreb. pp. 7-1-7-3.
- Hetzel, B. S. and Welby, M. C. 1997. Iodine. *In: O'Dell, B. L. and Sunde, R. A. (Eds.)*. Handbook of the Nutritionally Essential Mineral Elements. Marcel Decker, New York. pp. 557-582.
- Ingar, S. H. 1985. The thyroid gland. *In: Wilson, J.D. and Foster, D.W. (Eds.)*. Williams Textbook of Endocrinology. Saunders. Philadelphia. pp. 682-815.
- Karmarkar, M. G., Deo, M. G., Kochupillai, N. and Ramalingaswami, V. 1974. Pathophysiology of Himalayan endemic goiter. *American Journal of Clinical Nutrition* 27:96-103.
- Kategile, J. A., Mgongo, F. O. and Frederiksen, J. H. 1978. The effects of iodine supplementation on the reproductive tastes of goats and sheep. *Nordic Veterinary Medicine* 30:30-36.
- Ludcke, H. and Schone, F. 1988. Cooper and iodine in pigs diets with high glucosinolate rapeseed meal. I. Performance and thyroid hormone status. *Animal Feed Science and Technology* 22:33-43.
- Maddocks, S., Chandrasekhar, Y. and Setchell, B. P. 1985. Effect on wool growth of thyroxine replacement in thyroidectomized merino rams. *Australian Journal Biological Science* 38:405-410.
- Martin, W. B. and Aiteken, I. D. 2000. Diseases of sheep. Ed. Blackwell Science. Oxford USA.
- McCoy, M. A., Smyth, J. A., Ellis, W. A., Arthur, J. R. and Kennedy, D. G. 1997. Experimental reproduction of iodine deficiency in cattle. *Veterinary Record* 141:544-547.
- McGavin, M. D., Carlton, W. W. and Zachary, J. F. 2001. *Special Veterinary Pathology*, 3rd edition. Mosby. London, UK.
- Medeiros, G. N., Targovnik, H. M. and Vassart, G. 1993. Defective thyroglobulin synthesis and secretion causing goiter and hypothyroidism. *Endocrinology Reviews* 14:165-83.
- Montes de Oca, J.R., Velazquez, O.V., Lopez, L.R., Valladares, C.B. 1992. Determinación de los niveles de selenio en hígado, riñón, corazón y músculo de corderos de 0 a 90 días de edad en explotaciones ovinas del Valle de Toluca. *Memorias del Primer Encuentro de Ciencia y*

- Tecnología del Sector Agropecuario y Forestal del Estado de México. Toluca, México. pp. 127.
- Pichard, R. K., Hennessy, D. R. and Griffiths, D.A. 1974. Endocrine responses of sheep to infection with *Trichostrongylus colubriformis*. *Research in Veterinary Science* 17:182-187.
- Piosik, P. A., Van Groenigen, M., Van Doorn, J., Baas, F. and de Vijlder, J. M. 1997. Effects of maternal thyroid status on thyroid hormones and growth in congenitally hypothyroid goat fetuses during the second half of gestation. *Endocrinology* 138:5-11.
- Puls, R. 1994. *Mineral Levels in Animal Health. Diagnostic Data.* Sherpa International. Clearbrook B.C. Trinity Western University Press. Canada. pp. 83-109.
- Seimiya, Y., Ohshima, K., Itoh, H., Ogasawara, N., Matsukida, Y. and Yuita, K. 1991. Epidemiological and pathological studies on congenital diffuse hyperplastic goiter in calves. *Journal of Veterinary Medicine Science* 53:989-994.
- Underwood, E. J. and Suttle, N. F. 1999. *The mineral nutrition of livestock, 3rd* CABI Publishing. UK.
- Wichtel, J. J., Craigie, A. L., Freeman, D. A., Varela-Alvarez, H., Williamson, N. B. 1996. Effect of selenium and iodine supplementation on growth rate and on thyroid and somatotropic function in dairy calves at pasture. *Journal of Dairy Science* 79:1865-1872.