

Characteristics of testicular tumors in prepubertal children (age 5–12 years)

Boaz Karmazyn <sup>a,\*</sup>, David L. Weatherly <sup>b</sup>, Stephen J. Lehnert <sup>c</sup>, Mark Cain <sup>d</sup>, Rong Fan <sup>e</sup>, S. Gregory Jennings <sup>f</sup>, Fangqian Ouyang <sup>g</sup>, and Martin Kaefer <sup>d</sup>

<sup>a</sup> Department of Radiology and Imaging Sciences, Indiana University School of Medicine, Riley Hospital for Children, Indianapolis, IN, USA

<sup>b</sup> Urologic Consultants, Downtown/Main office, Grand Rapids, MI, USA

<sup>c</sup> Indiana University School of Medicine, Indianapolis, IN, USA

<sup>d</sup> Department of Urology, Indiana University School of Medicine, Riley Hospital for Children, Indianapolis, IN, USA

<sup>e</sup> Department of Pathology and Laboratory Medicine, Indianapolis, IN, USA

<sup>f</sup> Department of Radiology and Imaging Sciences, Indiana University School of Medicine, Indianapolis, IN, USA

<sup>g</sup> Department of Biostatistics, Indiana University School of Medicine, Indianapolis, IN, USA

## KEYWORDS

Testicular tumors;

Ultrasound;

Prepubertal

\* Corresponding author. Department of Radiology and Imaging Sciences, Indiana University School of Medicine, Riley Hospital for Children, 705 Riley Hospital Drive, Room 1053, Indianapolis, IN 46202, USA.

*E-mail address:* [bkarmazy@iupui.edu](mailto:bkarmazy@iupui.edu)

**Summary Introduction:** Testicular tumors in children have two peaks with different types of tumors; in the first 4 years of life a third to half are benign with increased risk of malignancy during puberty. The pathology of testicular tumors between these peaks, at the age of 5 to 12 years, is not known. We hypothesized that because of the low level of testosterone at this time, the incidence of malignant tumors is very low.

**Objective:** To compare malignancy risk of primary testicular tumors in children in the prepubertal period (5–12 years) compared with younger (0–4 years) and pubertal (13–18 years) children.

*Study design:* We retrospectively (2002–2016) identified patients <18 years with surgery for primary testicular tumor. Patients with testicular tumor risk were excluded. Ultrasound studies were reviewed for contralateral testis volume, tumor morphology, and tumor maximal diameter, for three age groups: 0–4, 5–12, and 13–18 years. The Freeman-Halton extension of the Fisher exact probability test was adopted for categorical outcomes, and one-way ANOVA for continuous outcomes.

*Results:* Fifty-two patients (mean age 11.0 years, range 6 days to 18 years) were identified. Malignant tumor prevalence significantly differed ( $p<0.01$ ) among age groups (Fig.): 0–4 (72.7%, 8/11), 5–12 (0%, 0/16), and 13–18 years (44.0%, 11/25). The most common tumor types in 5–12 years were epidermoid cyst (31.3%, 5/16) and tumor mimics (37.5%, 6/16). Prevalence of cystic tumors in 5–12 year olds was not significantly different compared with other age groups. Contralateral testicular volume >4 mL (pubertal surge) significantly ( $p<0.01$ ) differed among groups: 0–4 years (0/11), 5–12 years (3/16), and 13–18 years (19/20). In children aged 13–18 years the mean tumor maximal diameter ( $29.8\pm 4.4$  mm) was significantly larger ( $p<0.01$ ) compared with children 5–12 years ( $9.3\pm 5.5$  mm) and all malignant tumors had contralateral testicular volume >4 mL.

*Discussion:* We found that preadolescent children between the ages of 5 and 12 years have distinctive characteristics compared with the other age groups. Most importantly, no malignant testicular tumors were found in this age group. About a third of the children presented with an incidental testicular mass. The testicular tumors were significantly smaller ( $9.3\pm 6.7$  mm) compared with those in children aged 13–18 years ( $29.8\pm 4.4$  mm). There were limitations because of the retrospective nature of the study.

*Conclusion:* We found no malignant testicular tumors in children aged 5 to 12 years with no risk factors and prior to pubertal surge. Our study suggests use of more conservative treatment in this group of patients.

**Figure.** Contralateral testicular volume in children with benign and malignant testicular tumors.

## Introduction

Testicular tumors in children have a bimodal age distribution: one peak occurs at age 2–4 years, and the second occurs at age 15–18 years [1,2]. The clinical consideration in these two age periods is quite different and thus therapy varies as well.

In prepubertal boys younger than 5 years, testicular tumors are different from adult neoplasms. Germ cell tumors are less common than in adults and account for 60–77% of the testicular tumors [3–6]. The most common germ cell tumors are teratoma and yolk sac tumors. Prepubertal teratomas are all benign and most yolk sac tumors present as clinical stage I. About a third of the tumors are benign gonadal stromal tumors including Sertoli cell tumors, juvenile granulosa cell tumors, and Leydig cell tumors [3–6]. Therefore, when possible, testicular-sparing surgery should be considered.

In pubertal boys, most germ cell tumors are malignant; the most common types are mixed germ cell tumors. Radical orchiectomy is both diagnostic and therapeutic. Treatment with chemotherapy depends on histology and the stage of tumor. The initial therapy for metastatic or retroperitoneal disease is multi-agent chemotherapy. Retroperitoneal dissection is performed for residual or nonresponsive disease in the retroperitoneum. If there are no radiographic nodes at presentation, then surveillance, staging retroperitoneal dissection, or chemotherapy are options [7].

However, between these two age peaks, little is known about the nature of testicular tumors presenting in prepubertal boys after the age of 5 years. Such knowledge is needed to choose among markedly different treatment strategies. In this study, we compared the clinical presentation, ultrasound findings, tumor pathology, and treatment in 5–12 year olds compared with other age groups. We wanted to know if there are any distinctive characteristics of tumors in this age group that can help in patient management.

### **Materials and methods**

This HIPAA-compliant study was approved by our institutional review board, with waiver of informed consent. From the pathology archive at our institution, we retrospectively identified all pediatric patients who underwent biopsy or surgical resection of ultrasound-diagnosed primary testicular tumor, during a 15-year (2002–2016) period. Only children who were treated at our institution were included. Results from outside consultations were excluded. We also excluded patients with an underlying risk for testicular tumors (e.g., congenital adrenal hyperplasia, Peutz-Jeghers syndrome, mixed gonadal dysgenesis, testosterone insensitivity syndrome), and testicular tumors found in children who had orchiectomy of undescended atrophic testis.

Medical records were reviewed for epidemiologic data, clinical presentation, levels of alpha fetoprotein (AFP), and beta human chorionic gonadotropin (hCG). Normal values of AFP and hCG levels by age were used as a reference [8,9]. From the pathology report, we retrieved the final diagnosis and whether the tumor was malignant or benign. Using the

ultrasound studies, we evaluated the maximal diameter of the tumor, echotexture, presence of calcifications in the tumor, and presence of microlithiasis. Testicular masses were categorized as follows: solid, cystic (cystic mass without any solid component), and complex (contain both solid and cystic component). When images from ultrasound studies were not available for review, we retrieved the information from the report. As the testicular mass may change overall testicular volume, we evaluated the volume of the contralateral testis from ultrasound performed before surgery as follows: length  $\times$  height  $\times$  width  $\times$  0.52 [10].

Descriptive statistics (means and standard deviations (SD), frequencies) were calculated for patient tumor characteristics. We compared tumor characteristics among three age groups (0–4 years, 5–12 years, and 13–18 years). The Freeman-Halton extension of the Fisher exact probability test was adopted for categorical outcomes, and one-way ANOVA for continuous outcomes. One-way repeated measures ANOVA was used for assessing the difference between mean tumor diameters as one patient had bilateral tumors. A post-hoc test was performed to examine specific differences across groups. A *p*-value less than 0.05 was considered to be significant.

## Results

The study group included 52 children with an age range of 6 days to 18 years (mean 11.0 years). Eleven children were aged 0–4 years, 16 were aged 5–12 years, and 25 were aged 13–18 years. There was a significant difference in prevalence of the different types of clinical presentation between those aged 5–12 years and other age groups ( $p < 0.02$ , Table 1). Nine patients had incidental non-palpable testicular mass and had scrotal US for evaluation of contralateral testicular pain ( $n=4$ ), non-localized scrotal discomfort/pain ( $n=2$ ), evaluation of varicocele ( $n=1$ ), post-orchiopey evaluation ( $n=1$ ), and ecchymosis on the scrotum in a child with Henoch-Schonlein purpura ( $n=1$ ). Incidental non-palpable testicular mass was most common in the 5–12 age group (6/16, 37.5%), but the difference was not significant compared with age 0–4 (0/11, 0%,  $p=0.22$ ), and age 13–18 (3/25, 12.0%,  $p=0.12$ ), after multiple testing correction. Only one child (age 11.4 years) had a history of orchiopey for undescended testis. Laboratory results of AFP and hCG were available in 49/52 (94.2%) of the patients. None of the patients in the age group of 5–12 years had elevated AFP or hCG compared with 7/49 (14.3%) patients with elevated AFP and 8/49 (16.3%) elevated hCG in the other age groups (Table 1).

### *Ultrasound*

Of the preoperative ultrasound studies, 48/52 (92.3%) were available for review; in four other patients the information was retrieved from the reports. There was no significant difference in

prevalence of cystic tumors in children aged 5–12 years (5/16, 31.3%) compared with the other age groups (0/11, 0%,  $p=0.08$ , for age 0–4 and 10/25, 40.0%,  $p=0.12$  for age 13–18).

The testicular tumor maximal diameter was available in 51 patients. The mean tumor maximal diameter was significantly smaller ( $p=0.01$ ) in patients in the 5–12 year age group ( $9.3\pm 5.5$  mm), compared with children aged 13–18 years ( $29.8\pm 4.4$  mm), but not significantly different ( $p=0.44$ ) from children aged 0–4 years ( $20.3\pm 6.9$  mm).

As expected, mean contralateral testicular volume was significantly ( $p<0.01$ , Table 1) different among the three age groups (summary Figure), ranging from  $0.6\pm 0.3$  mL at 0–4 years to  $2.6\pm 2.2$  mL at age 5–12 years and  $12.0\pm 6.0$  mL at age 13–18 years. The presence of a contralateral testicular size  $> 4$  mL was also significantly ( $p<0.01$ ) different among groups, ranging from 0/10 (0%) at 0–4 years to 3/16 (18.8%) at 5–12 years and 21/22 (95.4%) at 13–18 years. In children aged 13–18 years with malignant tumors, the smallest testicular volume was 5.9 mL. Ultrasound of the contralateral testis was not available for review in four patients.

Preoperative ultrasound was not available for review in one pubertal patient, a 17.6 year old with mixed germ cell tumor. The contralateral testicular volume measured from a CT of the abdomen performed to evaluate for retroperitoneal metastatic lymph nodes was 25.3 mL, based on the same method described for the ultrasound.

### *Pathology*

There was a significant ( $p<0.01$ , Table 1) difference among the prevalence of malignant tumors in the age group of 5–12 years (no malignant tumors) compared with 63.6% (7/11) at 0–4 years and 44.0% (11/25) at 13–18 years (Table 2).

For age 5–12 years, the most common tumor was epidermoid cysts ( $n=5$ ). There were seven benign conditions mimicking a tumor: Leydig cell nodular hyperplasia ( $n=3$ , Fig. 1), Sertoli cell nodule ( $n=1$ ), and mixed stages of testicular maturation ( $n=3$ , Fig. 2). Most (4/7, 57.1%) of the benign conditions had a maximal diameter of less than 5 mm by ultrasound.

The malignant tumors for age 0–4 years were juvenile granulosa cell ( $n=4$ ), and yolk sac tumor ( $n=3$ ), and the most common benign tumor was teratoma ( $n=3$ ). In patients aged 13–18 years, the most common malignant tumors were germ cell tumors ( $n=11$ ), eight of which were mixed germ cell tumors. The malignant tumor with the smallest maximal diameter was 7 mm by ultrasound. Three of the germ cell tumors were metastatic. The most common benign tumor was epidermoid cyst ( $n=10$ ).

None of the 14 children 5 years or older with contralateral testicular volume <4 mL had malignant testicular tumor, while 10/24 (41.7%) of these children with testicular volume  $\geq$ 4 mL had malignant tumor ( $p<0.01$ ).

### *Treatment*

Table 1 summarizes the treatment for testicular masses. Of the group aged 5–12 years, 11/16 (68.8%) underwent testicular-sparing surgery. This did not significantly differ after multiple testing adjustments from the 0–4 year group (2/11,  $p=0.05$ ) or the 13–18 year group (10/25,  $p=0.33$ ).

### **Discussion**

Prepubertal testicular tumors are rare, with an incidence of 1-2% of all pediatric solid tumors and occurring at an incidence of 0.5 to 2/100,000 children [4,5]. There is little literature on preadolescent children after the first peak of testicular tumors at the age of 2–4 years and before the second peak of testicular tumors in postpubertal boys after the age of 15 years [1,2]. In this study we summarized the unique clinical, imaging, and pathology characteristics of this group of patients at the age range of 5–12 years. Our findings in this age group are further validated by our findings in younger and older children, which are similar to previously published series. In our study, in patients under the age of 5, 36.4% (4/11) of the tumors were benign, which is comparable with prior publications indicating that a third to half of these tumors are benign [3–5,11]. In patients between 13 and 18 years in our series, 11/25 (44.0%) of the tumors were malignant; the most common was mixed germ cell tumor (8/11, 72.7%). This is consistent with a reported peak incidence of malignant testicular tumors in adolescents of 15–19 years [12].

We found that preadolescent children between ages 5 and 12 years with testicular masses have unique characteristics that were significantly different compared with the other age groups. About a third of the children presented with an incidental testicular mass. No child had elevated tumor markers (AFP or hCG). The testicular tumors were significantly smaller ( $9.3\pm 6.7$  mm) compared with  $29.8\pm 4.4$  mm in children aged 13–18 years. Most importantly, in this group all tumors were benign. Malignant testicular tumors have been rarely reported in this age group. In a prepubertal registry in Korea, 209 testicular tumors were identified in 87 hospitals during a period of 5 years. Seven of the 100 yolk sac tumors were diagnosed at age 4-8 years and two cases of mixed germ cell tumors at age 8-10 years [4]. In a registry of testicular tumors on preadolescent boys 12 years and younger, 98 patients were found in four large tertiary children's hospitals in a period of time that ranged from 11

to 25 years [3]. There were no details on tumor distribution per age. None of these patients had seminoma or mixed germ cell tumor.

There are no details on the presentation, ultrasound findings, and pubertal stage in these studies.

Ultrasound characteristics of the tumor were only helpful in the preoperative diagnosis of epidermoid tumor as all had the typical onion ring appearance. All other masses had nonspecific findings. It is of interest that seven of the 16 children aged 5–12 years had benign conditions mimicking a tumor on ultrasound. These benign conditions included nodular hyperplasia of Leydig cells ( $n=3$ ), Sertoli cells nodule ( $n=1$ ), and mixed stages of testicular maturation ( $n=3$ ). Nodular hyperplasia of Leydig cells is rare in children and was described in several case reports in children presenting with precocious puberty [13–15]. Leydig cell hyperplasia was not described as an incidental mass in prepubertal boys. It is possible that elevated luteinizing hormone at the start of puberty rarely causes nodular hyperplasia of Leydig cells. Mixed stages of testicular maturation can also be a result of the early stages of puberty. Sertoli cell nodules, also called Pick's adenoma, are usually found incidentally in the testis and only rarely produce symptoms [16]. This has not been described before as presenting as a testicular nodule. It is possible that with the increased use of scrotal ultrasound there is increased identification of incidental benign non-palpable testicular lesions [17,18].

There is a clear relationship between development of malignant germ cell tumors and stage of puberty. In a study on risk stratification of pubertal children and postpubertal adolescents (21 years and younger) with clinical stage I testicular nonseminomatous germ cell tumors, 23 patients were identified. Pathologic high-risk germ cell tumors were found only in patients with Tanner stages 4 and 5 [7]. Our study suggests that in prepubertal boys at the period of time that the hypothalamic pituitary axis is blocked, there is a very low risk for malignant transformation. It is therefore important to consider not only the age group but also the stage of puberty. The beginning of puberty is marked by testicular growth. A testicular volume of 4 mL was taken as the indication of onset of puberty [19]. This has been supported by studies [11–14] that show a testicular volume of 4 mL is achieved just before the stage of the testicular growth spurt. In our study we found that 88.9% of the boys in the age group of 5–12 years had a contralateral testicular volume of less than 4 mL, and that the smallest testicular volume in the age group of 13–18 years with testicular cancer was 5.9 mL.

Our experience and evidence from other studies showing a low malignancy rate in children aged 5–12 years with testicular tumors suggest that in this group of patients, when

tumor markers are negative, a conservative approach should be considered. Rather than using an upper age limit of 12 years, evidence of pubertal Tanner stage 2 or lower, or contralateral testicular volume of less than 4 mL may be better selection criteria. In our case series, all of the 14 patients older than 5 years with contralateral testicular volume less than 4 mL had a benign testicular mass. Most (57.1%) of the testicular tumor mimickers had a diameter of less than 5 mm. Therefore, in some prepubertal children with a small (maximal diameter <5mm) incidental non-palpable testicular mass, follow-up ultrasound should be considered rather than a biopsy. There are studies that suggest that the use of contrast enhanced ultrasound can help with this conservative approach if no vascularity is identified in the testicular mass [20].

Our study has a few limitations because of the relatively small number of patients, the retrospective nature of the study, and selective bias as our institution is a referral medical center for testicular tumors. One other limitation is that four patients did not have preoperative ultrasound for review. Three of these patients were older than 5 years; only one of them (age 17.6 years) had a malignant tumor with contralateral testicular volume of 25.3 mL measured from the abdominal CT scan.

#### *Conclusion*

In summary, among prepubertal children older than 5 years with a testicular mass on ultrasound and without preexisting risk factors, we found no malignant tumors. Based on our experience, we suggest consideration of a more conservative approach to this group of patients, with only ultrasound follow-up for selected small non-palpable masses, and strong consideration for testicular-sparing surgery if biopsy is negative for malignant tumor.

#### **Conflict of interest**

None.

#### **Funding**

None.

#### **References**

- [1] Poynter JN, Amatruda JF, Ross JA. Trends in incidence and survival of pediatric and adolescent patients with germ cell tumors in the United States, 1975 to 2006. *Cancer*. 2010;116:4882–91.
- [2] McKiernan JM, Goluboff ET, Liberson GL, Golden R, Fisch H. Rising risk of testicular cancer by birth cohort in the United States from 1973 to 1995. *J Urol*. 1999;162:361–3.
- [3] Pohl HG, Shukla AR, Metcalf PD, Cilento BG, Retik AB, Bagli DJ, *et al*. Prepubertal testis tumors: actual prevalence rate of histological types. *J Urol*. 2004;172:2370–2.



- [4] Lee SD. Epidemiological and clinical behavior of prepubertal testicular tumors in Korea. *J Urol* 2004;172:674–8.
- [5] Thomas JC, Ross JH, Kay R. Stromal testis tumors in children: a report from the prepubertal testis tumor registry. *J Urol* 2001;166:2338–40.
- [6] Skoog SJ. Benign and malignant pediatric scrotal masses. *Pediatr Clin North Am*. 1997;44:1229–50.
- [7] Cost NG, Lubahn JD, Adibi M, Romman A, Wickiser JE, Raj GV, *et al*. Risk stratification of pubertal children and postpubertal adolescents with clinical stage I testicular nonseminomatous germ cell tumors. *J Urol* 2014;191:1485–90.
- [8] Schneider DT, Calaminus G, Gobel U. Diagnostic value of alpha 1-fetoprotein and beta-human chorionic gonadotropin in infancy and childhood. *Pediatr Hematol Oncol*. 2001;18:11–26.
- [9] Wu JT, Book L, Sudar K. Serum alpha fetoprotein (AFP) levels in normal infants. *Pediatr Res*. 1981;15:50–2.
- [10] Diamond DA, Paltiel HJ, DiCanzio J, Zurakowski D, Bauer SB, Atala A, *et al*. Comparative assessment of pediatric testicular volume: orchidometer versus ultrasound. *J Urol* 2000;164:1111–4.
- [11] Agarwal PK, Palmer JS. Testicular and paratesticular neoplasms in prepubertal males. *J Urol* 2006;176:875–81.
- [12] Howlader N, Noone AM, Krapcho M, Miller D, Bishop K, Kosary CL, *et al*. (eds). SEER Cancer Statistics Review, 1975–2014, National Cancer Institute. Bethesda, MD, [https://seer.cancer.gov/csr/1975\\_2014/](https://seer.cancer.gov/csr/1975_2014/), based on November 2016 SEER data submission, posted to the SEER web site, April 2017.
- [13] Leung AC, Kogan SJ. Focal lobular spermatogenesis and pubertal acceleration associated with ipsilateral Leydig cell hyperplasia. *Urology*. 2000;56:508–9.
- [14] Leschek EW, Chan WY, Diamond DA, Kaefer M, Jones J, Barnes KM, *et al*. Nodular Leydig cell hyperplasia in a boy with familial male-limited precocious puberty. *J Pediatr*. 2001;138:949–51.
- [15] Wilson BE, Netzloff ML. Primary testicular abnormalities causing precocious puberty Leydig cell tumor, Leydig cell hyperplasia, and adrenal rest tumor. *Ann Clin Lab Sci*. 1983;13:315–20.
- [16] Vallangeon BD, Eble JN, Ulbright TM. Macroscopic sertoli cell nodule: a study of 6 cases that presented as testicular masses. *Am J Surg Pathol*. 2010;34:1874–80.

[17] Eifler JB, Jr., King P, Schlegel PN. Incidental testicular lesions found during infertility evaluation are usually benign and may be managed conservatively. *J Urol* 2008;180:261–4; discussion 5.

[18] Carmignani L, Gadda F, Gazzano G, Nerva F, Mancini M, Ferruti M, *et al.* High incidence of benign testicular neoplasms diagnosed by ultrasound. *J Urol* 2003;170:1783–6.

[19] Bundak R, Darendeliler F, Gunoz H, Bas F, Saka N, Neyzi O. Analysis of puberty and pubertal growth in healthy boys. *Eur J Pediatr.* 2007;166:595–600.

[20] Isidori AM, Pozza C, Gianfrilli D, Giannetta E, Lemma A, Pofi R, *et al.* Differential diagnosis of nonpalpable testicular lesions: qualitative and quantitative contrast-enhanced US of benign and malignant testicular tumors. *Radiology.* 2014;273:606–18.

**Table 1.** Characteristics of 52 children with testicular masses categorized into three age groups: 0–4 years, 5–12 years, and 13–18 years

Age group	<5 years (N=11)	5–12 years (N=16)	13–18 years (N=25)	<i>p</i> - value
Presentation				0.02
Mass	11 (100%)	8 (50%)	16 (64.0%)	
EPain	0	2 (12.5%)	6 (24.0%)	
Incidental	0	6 (37.5%)	3 (12.0%)	
Ultrasound morphology				<0.01
Solid	2 (18.8%)	8 (50.0%)	10 (40.0%)	
Cystic	0	5 (31.3%)	10 (40.0%)	
Complex	9 (81.8 %)	3 (18.8%)	5 (20.0%)	
Mean size of tumor± SD (mm)	20.3±6.9	9.3±5.5	29.8±4.4	0.02
Mean size of contralateral testis± SD (mL)	0.6±0.3	2.6±2.2	12.0±6.0	<0.01
Tumor markers				
Elevated AFP	4 (36.4%)	0	3 (30%)	0.02
Elevated hCG	1 (12.5%)	0	7 (87.5%)	0.02
Pathology				<0.01
Benign	4 (36.4%)	16 (100%)	14 (56.0%)	
Malignant	7 (63.6%)	0	11 (44.0%)	
Surgical intervention				0.03
Radical orchiectomy	9 (81.8%)	5 (31.2%)	15 (60.0%)	
Testis-sparing surgery	2 (18.2%)	11 (68.8%)	10 (40.0%)	

AFP = alpha fetoprotein; hCG = human chorionic gonadotropin.

**Table 2.** Clinical, ultrasound, and pathologic findings in children aged 5–12 years with testicular mass

Patient number	Age, years	Presentation	Testicle	Tumor	Surgery					
			Side	Volume (mL) <sup>a</sup>	MLT	Size (mm)	Characteristics	Vascularity	Pathology	
1	5.0	Incidental	RT	1.1	No	9	Cyst + "onion rings"	No	Epidermoid cyst	TSS
2	5.8	Mass	RT	0.6	No	28	Cyst + calcification	Increased at the rim	Benign Sertoli cell tumor	Orchiectomy
3 <sup>b</sup>	6.1	Mass	RT	2.8	No	22	Cyst, lamellate	No	Cystic dysplasia	Orchiectomy
4	7.7	Mass	LT	0.6	No	4	Hypoechoic	Normal	Leydig cell hyperplasia	TSS
5	8.0	Incidental	LT	2.2	Yes	6.7	Peripheral hyperechogenicity	Normal	Leydig cell hyperplasia	TSS
6	9.0	Incidental	RT	1.6	No	7.5	Peripheral hyperechogenicity	Increased	Benign Leydig cell tumor	Orchiectomy
7	10.1	Mass	LT	1.0	No	7	Cyst + "onion rings"	No	Epidermoid cyst	TSS
8	10.3	Incidental	LT	2.2	No	4	Hypochoic rim + microcalcifications <sup>c</sup>	No	Pick's adenoma	TSS
9	10.7	Pain	LT	2.3	No	4.8	Hypoechoic rim	Increased	Capillary hemangioma	TSS
10	11.0	Mass	RT	3.8	No	9.3	Cyst + "onion rings"	No	Epidermoid cyst	TSS
11	11.3	Incidental	LT	2.3	Yes	4.1	Hypochoic rim + microcalcifications <sup>c</sup>	Normal	Mixed maturation	TSS
12	11.5	Incidental	LT	0.9	No	7.5	Peripheral hyperechog	Increased	Mixed maturat	TSS

							enicity		ion	
13	11.9	Pain	LT	4.2	No	3.6	Echogenic	Normal	Mixed maturation	Orchiectomy
14	12.0	Mass	RT	9.6	No	9.6	Multilobulated complex cyst	No	Benign cystic teratoma	TSS
15	12.1	Mass	RT	4.6	No	11.2	Cyst + "onion rings"	No	Epidermoid cyst	Orchiectomy
16	12.3	Mass	LT	1.7	No	10.5	Cyst + "onion rings"	No	Epidermoid cyst	TSS

MLT = microlithiasis; RT = right; LT = left; TSS = testicular-sparing surgery.

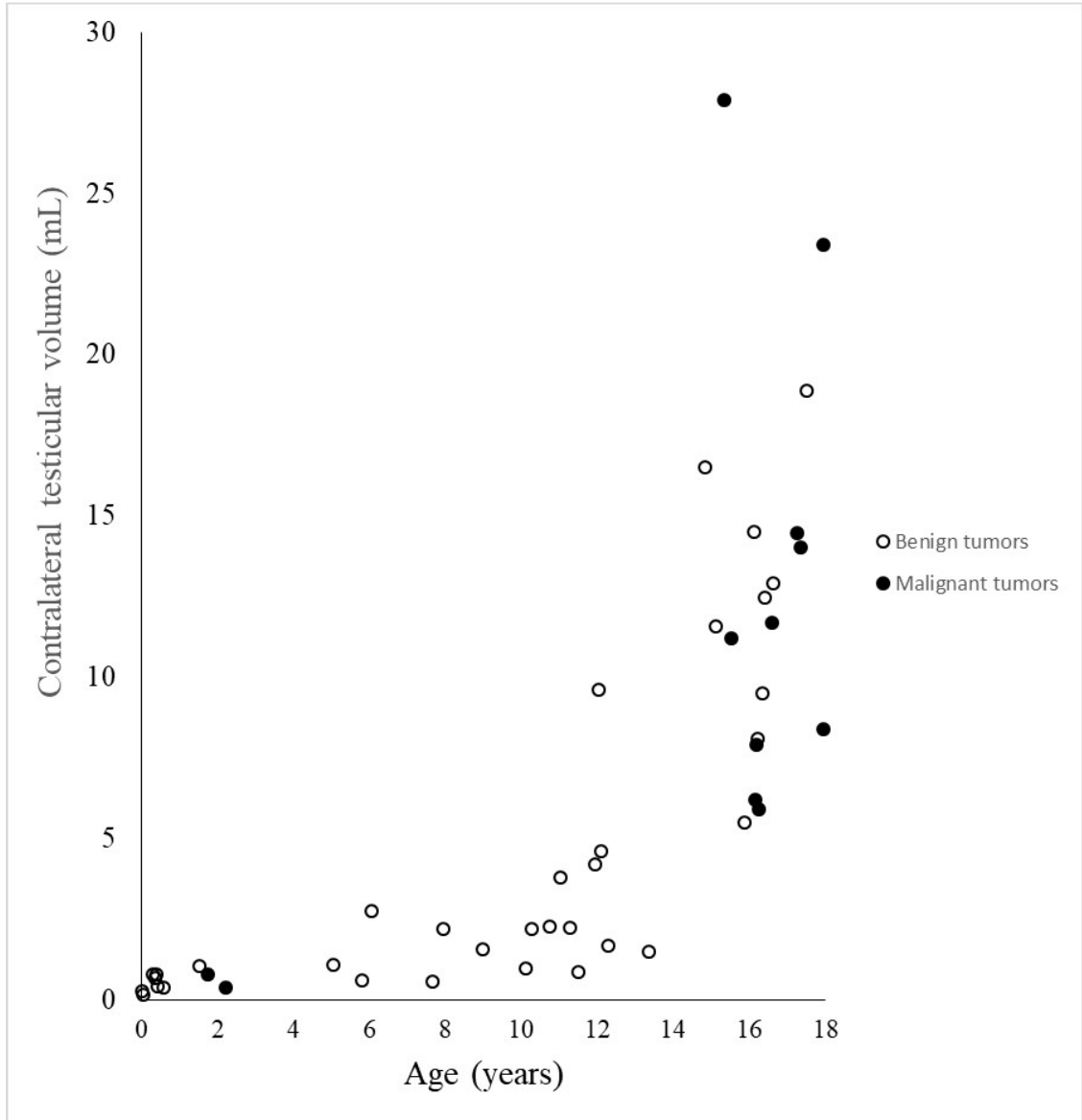
<sup>a</sup> Contralateral testicular volume.

<sup>b</sup> Findings in patient 3 were based on ultrasound report.

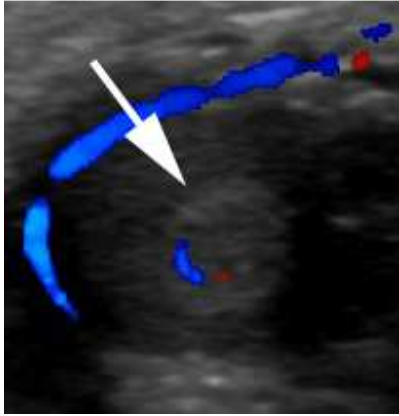
<sup>c</sup> Microcalcifications confined to the mass.

**Figure 1.** An island of immature testis mimicking a mass in an 11.8-year-old boy who presented with left testicular pain. (A) Transverse ultrasound demonstrates an echogenic nodule (arrow). (B), (C) Post orchiectomy hematoxylin and eosin staining pathology slides demonstrate an island of immature testis surrounded by tissue with more developed spermatogenesis (arrow (B), magnification of 1.25, arrowheads (C) magnification of 4).

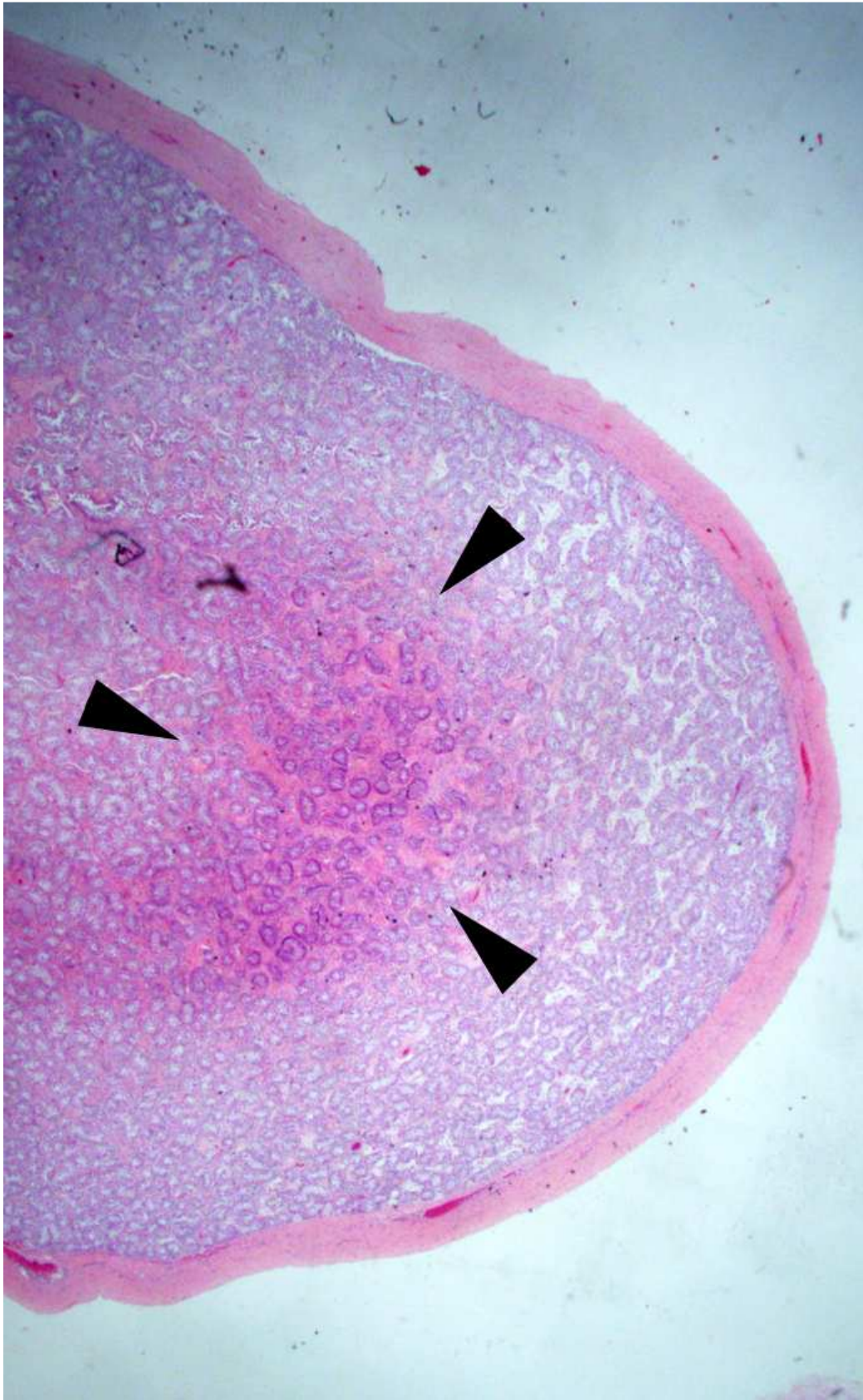
**Figure 2.** An 8-year-old presented with intermittent left testicular swelling. (A) Longitudinal ultrasound demonstrates a testicular nodule with thick echogenic rim associated with microlithiasis. (B) Post-biopsy hematoxylin and eosin staining pathology slides demonstrate an island of Leydig cell nodular hyperplasia (arrow, magnification 1.25).

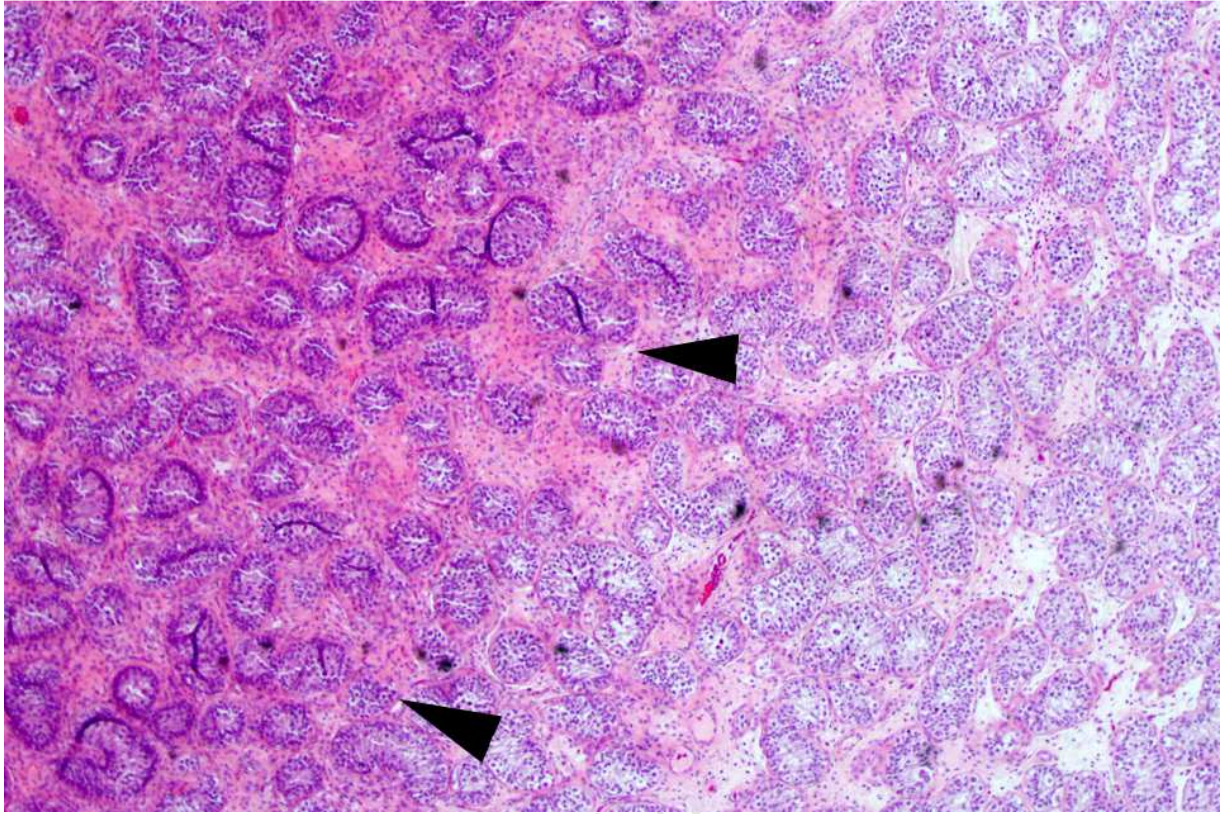


ACCE

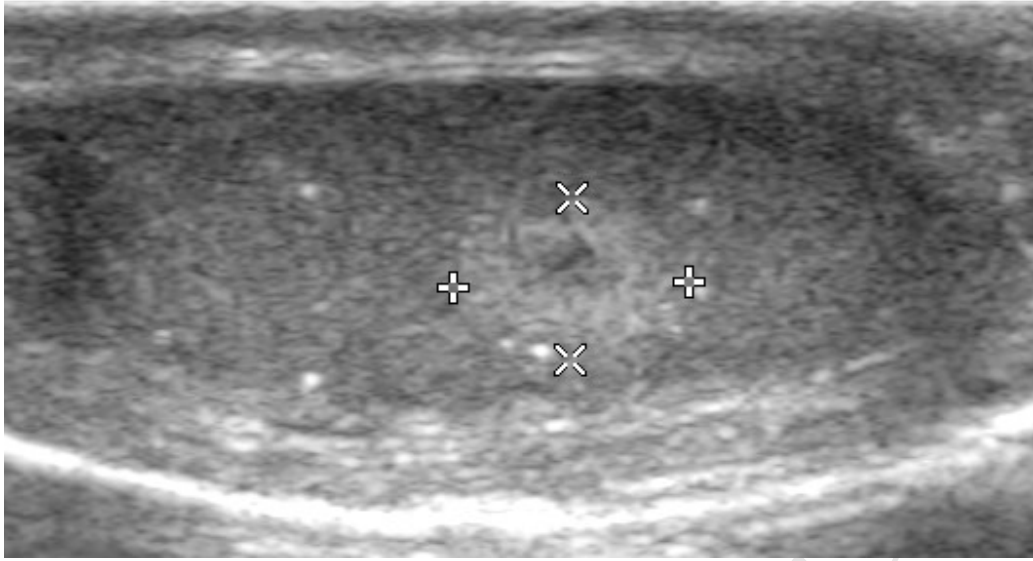


ACCEPTED MANUSCRIPT

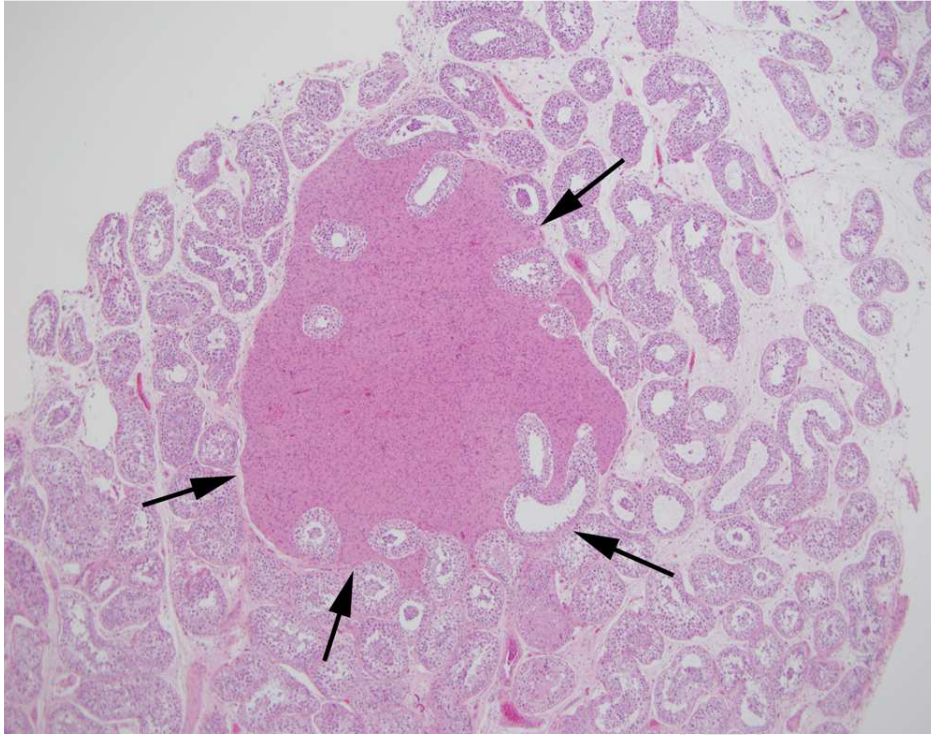








ACCEPTED MANUSCRIPT



ACCEPTED MANUSCRIPT