

## Case Report

Janeil M. Belle, Nektarios Vasilottos, Todd D. Nebesio and Benjamin C. James\*

# Pediatric toxic polycystic thyroid

DOI 10.1515/jpem-2016-0443

Received November 27, 2016; accepted April 18, 2017; previously published online June 16, 2017

### Abstract

**Background:** Polycystic thyroid disease (PCTD) is a rare condition and has been described in adults in the setting of subclinical and clinical hypothyroidism. We present the first known case of a pediatric patient with diffuse macrocystic degeneration of the thyroid.

**Clinical presentation:** A 6-year-old previously healthy patient was evaluated after presenting with a 16-month history of an enlarging polycystic thyroid and hyperthyroidism. Markers of autoimmune thyroid disease including thyroid stimulating immunoglobulin (TSI), thyroid stimulating hormone (TSH) receptor antibody, thyroid peroxidase antibody and thyroglobulin antibody were negative. No family history of benign or malignant thyroid or cystic disease was present. The patient underwent a total thyroidectomy without perioperative complication. She remains euthyroid with thyroid hormone replacement therapy.

**Summary:** To our knowledge, this is the first report of PCTD in the pediatric population associated with hyperthyroidism without evidence of autoimmune disease. Somatic activating thyrotropin-receptor gene mutations are known to cause non-autoimmune hyperthyroidism in children, however it is unknown if similar mechanisms are responsible for pediatric PCTD.

**Conclusions:** Polycystic thyroid degeneration can occur in children and may result in a hyperthyroid state.

**Keywords:** pediatric hyperthyroidism; pediatric thyroid disease; polycystic; thyroid cyst.

## Introduction

Polycystic thyroid disease (PCTD) has been described in the adult population, as a rare cause of hypothyroidism [1, 2]. An estimated 7.8% of overt hypothyroidism in regions with high iodine intake are thought to be induced by PCTD [3]. PCTD is defined as the presence of four or more thyroid cysts in the absence of thyroid auto-antibodies and is most often observed in asymptomatic individuals [2, 3].

The pathogenesis and natural history of cyst development in PCTD is largely unknown. PCTD cysts have been previously documented up to a span of 5 mm in diameter on histological section but have not been reported to induce compressive symptoms. PCTD cysts have been found in thyroidectomy specimens of individuals with papillary thyroid cancer but have not been directly shown to undergo malignant transformation.

PCTD is best described in the adult population. The presence of multiple small thyroid cysts have been reported previously in two children under 15 years of age, with subclinical hypothyroidism. This is the first case of diffuse polycystic thyroid reported in a child associated with a non-autoimmune hyperthyroid state.

## Case presentation

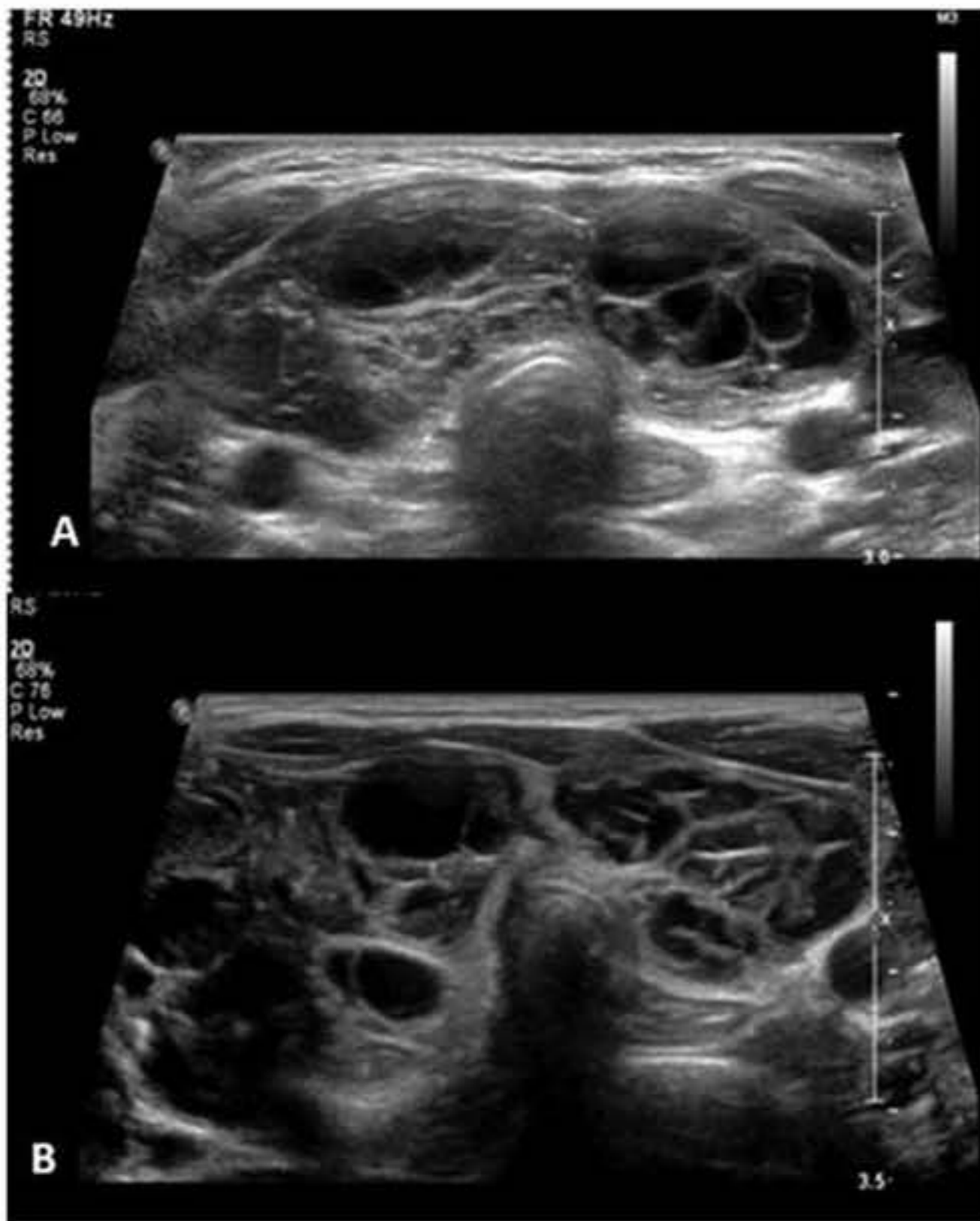
A 6-year-old, developmentally normal, previously healthy female patient, was referred for surgical consultation, following a 16-month history of an enlarging thyroid gland and new-onset hyperthyroidism. The patient was initially evaluated by her pediatrician after her family appreciated fullness over her neck. At that time, she was found to have a non-tender goiter and appeared clinically euthyroid. Serum thyroid stimulating hormone (TSH) levels were suppressed and undetectable and free thyroxine (T<sub>4</sub>) was 1.58 ng/dL (reference range 0.80–1.80). TSH receptor antibodies (TRAb), thyroid-stimulating immunoglobulin (TSI), thyroid peroxidase antibodies (TPOAb) and thyroglobulin antibodies (TgAb) were not detected on serum assay. Thyroid ultrasound showed bilateral lobe enlargement, increased gland vascularity and numerous, diffuse cysts (Figure 1A).

\*Corresponding author: Benjamin C. James, MD, MS, Assistant Professor of Surgery, Section of Endocrine Surgery, Department of General Surgery, Indiana University School of Medicine, 545 Barnhill Drive, Emerson Hall, 537 Indianapolis, IN 46202, USA, E-mail: becjames@iupui.edu

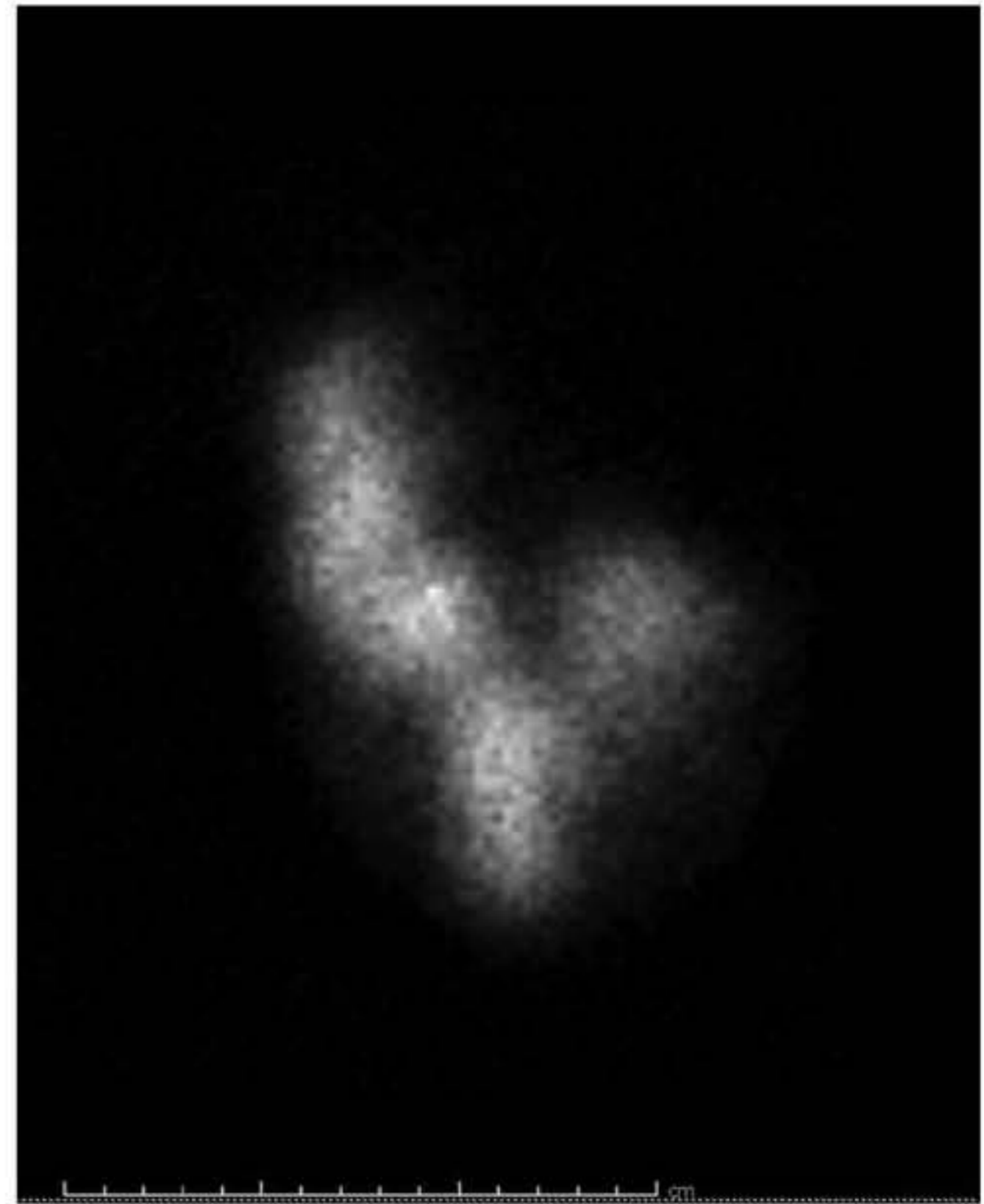
Janeil M. Belle and Nektarios Vasilottos: Department of Surgery, Indiana University School of Medicine, Indianapolis, IN, USA

Todd D. Nebesio: Section of Endocrinology/Diabetology, Department of Pediatrics, Indiana University School of Medicine, Indianapolis, IN, USA





**Figure 1:** Thyroid ultrasound, transverse. (A) Initial ultrasound; (B) 16 months later.



**Figure 2:** I-123 sodium iodide scintigram. Diffusely increased thyroid uptake, right lobe > left, 65% at 24 h.

Over the next year, the patient and her family observed gradual, asymmetric enlargement of her thyroid gland with a prominent right lobe. Interval TSH levels continued to be low and total triiodothyronine (T3) and T4 levels were in the normal range. She experienced one episode of acute dyspnea and tachycardia resulting in an emergency room visit. This prompted a referral to a pediatric endocrinologist for evaluation. The consulting pediatric endocrinologist noted her serum total T3 level to be elevated at 242 ng/dL (RR 82–179 ng/dL) with again a low TSH level of 0.006  $\mu$ U/mL (RR 0.400–4.200  $\mu$ U/mL). Repeat thyroid antibody testing was negative. An ultrasound of her thyroid gland revealed marked enlargement, with a total gland volume of over 40 mL and near-complete parenchymal replacement with large thin and thick-walled cysts (Figure 1B). No lymphadenopathy was observed on ultrasound of the lateral neck. An I-123 scintigraphy demonstrated diffusely increased uptake with right lobe predominance, 65% at 24 h (Figure 2).

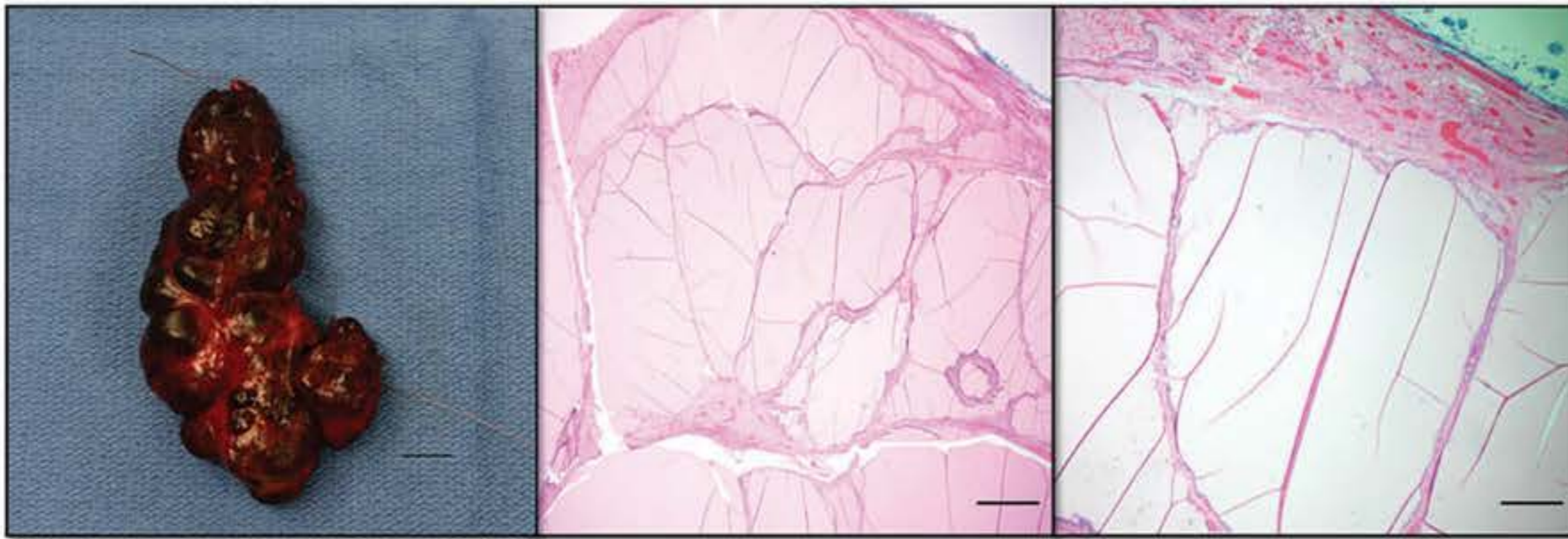
The patient was then referred to the endocrine surgery clinic for consideration of surgical management. On evaluation, the patient denied experiencing compressive symptoms or symptoms suggestive of thyroid hormone derangement following the episode of dyspnea and

palpations 1 month prior. She did not have a family history of thyroid or cystic diseases. On physical examination, the patient had a non-tender, visibly enlarged thyroid gland with marked asymmetry and greater prominence of the right lobe. No suspicious cervical lymphadenopathy was appreciable. Ultimately, the patient underwent a total thyroidectomy for definitive treatment.

The total thyroidectomy was successfully completed. Four parathyroid glands were identified and preserved. There were no perioperative complications and the patient was discharged home the following morning on a full dose of levothyroxine. The patient recovered well postoperatively, without any hypocalcemia or hoarseness of voice. She remains euthyroid with oral levothyroxine supplementation.

The thyroid featured a capsule, densely adherent to adjacent tissues and multiple large cm-sized cysts bilaterally, which completely replaced the thyroid parenchyma. The thyroid gland weighed 36.5 g. Right and left lobe dimensions were 7.0×2.8×2.8 cm and 3.7×2.8×1 cm, respectively (Figure 3). Numerous colloid-filled and hemorrhagic cysts ranging from 0.1 cm to 1 cm in maximal diameter were observed in the bilateral lobes on a thin-section. The cyst were round and ellipsoid in shape.





**Figure 3:** Total thyroidectomy specimen (Left).

Multiple large cysts replaced both lobes of the thyroid. Bar represents 1 cm. Representative histological sections. (Middle, Right) Multiple colloid nodules with cystic generation and hemorrhage, hematoxylin and eosin. Bar represents 1 mm, 2× (Middle) and bar represents 200 μm, 10× (Right).

Normal thyroid follicles were quite rare and appeared compressed and distorted, secondary to mass effect from surrounding cysts. No histologically abnormal or malignant-appearing thyroid follicles were identified (Figure 3).

## Discussion

PCTD has recently been described as a rare cause of hypothyroidism in adults [3]. Two cases of a 6-year-old and a 14-year-old female with multiple small, sub-centimeter cysts have been reported in the literature [1]. However, our case is the first report of a child with diffuse PCTD associated with symptomatic and biochemical hyperthyroidism.

PCTD is a rare, poorly understood clinical entity with limited descriptions in the literature with predominately asymptomatic but varied clinical presentations. PCTD has been defined in a patient with four or more thyroid cysts with negative TgAb and TPOAb and no evidence of in-situ thyroid disease [3]. The complete clinical phenotype, pathogenesis and natural history of PCTD is unknown. A retrospective review of over 8000 adults with non-autoimmune hypothyroidism found that 0.82% of the patients possess PCTD features and that two-thirds of these patients exhibited subclinical hypothyroidism and one-third demonstrated signs of overt hypothyroidism. One series of six adult patients with PCTD features reported that all six patients were biochemically hypothyroid [2]. The development of thyroid cysts in PCTD has been thought to result in follicular destruction with subsequent hypothyroidism [4].

The case presented here is unusual as hyperthyroidism was observed in the setting of near-total gland replacement by degenerative cysts. The underlying

etiology of the patient's cyst proliferation and hyperthyroidism is unclear but it does not appear to be mediated by an autoimmune mechanism. Clinical hyperthyroidism from an autonomously functioning thyroid nodule in a child is rare and hyperthyroidism from cystic disease is even more uncommon. Most autonomous thyroid nodules are due to somatic activating mutations within the genes encoding the TSH receptor, *THSR*, or the  $\alpha$ -subunit of the stimulating G-protein, such as *GNAS*. Somatic activating thyrotropin-receptor gene mutations have been reported to cause non-autoimmune hyperthyroidism in children [5]. Mutations in *DICER1* genes have also been implicated in the development of multinodular goiter in children [6]. It is unknown if similar mechanisms are responsible for cystic thyroid disease in children.

In adults, radioactive iodine or surgical resection are treatment options for an autonomously hyper-functioning nodule. In children, however, surgical resection is the recommended treatment as up to one-third of the pediatric patients with autonomous thyroid nodules may have incidentally discovered differentiated thyroid cancer [7, 8]. Due to the patient's persistent hyperthyroid state and concerning ultrasound findings, surgical resection was performed with benign histological findings on final pathology.

**Acknowledgments:** The authors thank Dr. Eric Allen Albright and Dr. Alaleh Esmaili Shandiz, Department of Pathology, Riley Hospital for Children at Indiana University Health for technical assistance with photomicroscopy.

**Author contributions:** All the authors have accepted responsibility for the entire content of this submitted manuscript and approved submission.



**Research funding:** None declared.

**Employment or leadership:** None declared.

**Honorarium:** None declared.

**Competing interests:** The funding organization(s) played no role in the study design; in the collection, analysis, and interpretation of data; in the writing of the report; or in the decision to submit the report for publication.

## References

1. Naranjo ID, Robinot DC, Rojo JC, Ponferrada MR. Polycystic thyroid disease in pediatric patients: an uncommon cause of hypothyroidism. *J Ultrasound Med* 2016;35:209–11.
2. Kubota S, Fujiwara M, Hagiwara H, Tsujimoto N, Takata K, et al. Multiple thyroid cysts may be a cause of hypothyroidism in patients with relatively high iodine intake. *Thyroid* 2010;20:205–8.
3. Kubota S, Maruta T, Fujiwara M, Hagiwara H, Tsujimoto N, et al. The prevalence of polycystic thyroid disease in hypothyroid patients with negative thyroid autoantibodies. *Thyroid* 2010;20:1205–8.
4. Kubota S, Hirokawa M, Takamura Y, Ito Y, Tamai H, et al. Pathologic features of polycystic thyroid disease: comparison with benign nodular goiter. *Endocr J* 2011;58:783–8.
5. Schwab KO, Pfarr N, van der Werf-Grohmann N, Pohl M, Radecke J, et al. Autonomous thyroid adenoma: only an adulthood disease? *J Pediatr* 2009;154:931–33 e932.
6. Darrat I, Bedoyan J, Chen M, Schuette J, Lesperance M. A novel DICER1 mutation causes multinodular goiter in children. *Head Neck* 2013;35:10.
7. Francis GL, Waguespack SG, Bauer AJ, Angelos P, Benvenga S, et al. American Thyroid Association Guidelines Task Force. Management guidelines for children with thyroid nodules and differentiated thyroid cancer. *Thyroid* 2015;25:716–59.
8. Damle N, Gupta S, Kumar P, Mathur S, Bal C. Papillary carcinoma masquerading as clinically toxic adenoma in very young children. *J Pediatr Endocrinol Metab* 2011;24:1051–4.