



Published in final edited form as:

J Magn Reson Imaging. 2017 April ; 45(4): 1171–1176. doi:10.1002/jmri.25428.

T_1 Mapping for Diagnosis of Mild Chronic Pancreatitis

Temel Tirkes, MD^{1,*}, Chen Lin, PhD¹, Evan L. Fogel, MD², Stuart S. Sherman, MD², Qiushi Wang, MD³, and Kumaresan Sandrasegaran, MD¹

¹Department of Radiology and Clinical Sciences, Indiana University School of Medicine, Indianapolis, Indiana, USA

²Department of Medicine, Division of Gastroenterology, Indiana University School of Medicine, Indianapolis, Indiana, USA

³Department of Radiology, Guangdong General Hospital, Guangdong Academy of Medical Sciences No 106, Guangzhou, Guangdong, China

Abstract

Purpose—To determine if the T_1 relaxation time of the pancreas can detect parenchymal changes in mild chronic pancreatitis (CP).

Materials and Methods—This Institutional Review Board (IRB)-approved, Health Insurance Portability and Accountability Act (HIPAA)-compliant retrospective study analyzed 98 patients with suspected mild CP. Patients were grouped as normal ($n = 53$) or mild CP ($n = 45$) based on history, presenting symptomatology, and concordant findings on both the secretin-enhanced magnetic resonance cholangiopancreatography (S-MRCP) and endoscopic retrograde cholangiopancreatography (ERCP). T_1 maps were obtained in all patients using the same 3D gradient echo technique on the same 3T scanner. T_1 relaxation times, fat signal fraction (FSF), and anterior–posterior (AP) diameter were correlated with the clinical diagnosis of CP.

Results—There was a significant difference ($P < 0.0001$) in the T_1 relaxation times between the control (mean = 797 msec, 95% confidence interval [CI]: 730, 865) and mild CP group (mean = 1099 msec, 95% CI: 1032, 1166). A T_1 relaxation time threshold value of 900 msec was 80% sensitive (95% CI: 65, 90) and 69% specific (95% CI: 56, 82) for the diagnosis of mild CP (area under the curve [AUC]: 0.81). Multiple regression analysis showed that T_1 relaxation time was the only statistically significant variable correlating with the diagnosis of CP ($P < 0.0001$). T_1 relaxation times showed a weak positive correlation with the pancreatic FSF ($\rho = 0.33$, $P = 0.01$) in the control group, but not in the mild CP group.

Conclusion—The T_1 relaxation time of the pancreatic parenchyma was significantly increased in patients with mild CP. Therefore, T_1 mapping might be used as a practical quantitative imaging technique for the evaluation of suspected mild CP.

Chronic pancreatitis (CP) involves progressive inflammatory changes in the pancreas characterized by chronic unrelenting pain with episodic flares, impairment of exocrine, and endocrine function. A population-based study in the U.S. showed that the prevalence of CP

*Address reprint requests to: T.T., 550 N. University Blvd., Ste. 0663, Indianapolis, IN, 46202. atirkes@iupui.edu.

is 41/100,000, with its incidence rising mainly due to alcohol use.¹ To facilitate early diagnosis, practical tests (eg, fecal elastase) have been developed; however, in mild pancreatic insufficiency, sensitivity of these tests has been found to be inadequate.² Imaging of ductal morphology is crucial to establish diagnosis of CP. The Cambridge Classification has been used since 1984 as a reference standard to diagnose and grade CP by endoscopic retrograde cholangiopancreatography (ERCP) and magnetic resonance cholangiopancreatography (MRCP).³ Clinical use of ERCP as a purely diagnostic tool has declined as less invasive procedures have become available.⁴ Endoscopic ultrasound (EUS) carries less risk of complications compared to ERCP⁵; however, multicenter studies have shown that the interobserver agreement of EUS is suboptimal for the diagnosis of CP.⁶ Endoscopic pancreatic function tests (ePFT) have the potential to detect CP at an earlier stage than other available diagnostic tests, but their use is, for the most part, limited to tertiary referral centers.² Therefore, validation of a widely available, noninvasive imaging technique to detect early CP would have tremendous clinical benefit.

Several vendors are now offering rapid (one breath-hold) acquisition of T_1 mapping techniques. The purpose of this study was to determine if the T_1 relaxation time of the pancreas quantitatively measured by the T_1 mapping could be a useful test for patients being evaluated for mild CP.

Materials and Methods

Patient Selection

The Institutional Review Board approved this retrospective study, and the requirement for informed consent for the patient data review was waived. A Health Insurance Portability and Accountability Act (HIPAA)-compliant retrospective analysis performed on patients with suspected pancreaticobiliary pathology presenting to the Gastroenterology Clinic in a tertiary referral center. Review of the electronic medical records between March 2014 and January 2016 identified 346 of such patients. Patients were excluded from the study if they were younger than 18 years of age, had diabetes mellitus, acute pancreatitis, moderate or severe CP, cystic or solid pancreatic neoplasm, evidence of iron overload, or cystic fibrosis. Following the exclusion criteria, 98 nonconsecutive patients were studied in the mild CP and control groups. Patients in the mild CP group ($n = 45$) were selected based on history of positive symptomatology (abdominal pain suspected to be of pancreatic origin), concordant ductal findings on secretin-enhanced MR cholangiopancreatography (S-MRCP) and ERCP for mild CP according to the Cambridge Classification,³ and normal pancreatic amylase and lipase levels at the time of S-MRCP. Patients with normal ductal findings on S-MRCP and ERCP, normal amylase and lipase levels, and without history of acute or chronic pancreatitis were studied in the control group ($n = 53$). Nine patients in the control group had these findings not associated with any form of pancreatitis: choledocholithiasis ($n = 5$), sphincter of Oddi dysfunction ($n = 3$), primary sclerosing cholangitis ($n = 1$), and Peutz-Jeghers syndrome ($n = 1$). Average age of the patients in the control group was 55 (range: 19–84), versus 59 (range: 32–82) in the mild CP group. Sixty-six percent of the control group were female (mean age: 49, range: 19–67), versus 40% in the mild CP group (mean age: 52,

range: 26–84). Patients within both groups had similar body mass index, serum amylase, and lipase levels (Table 1).

Imaging Technique

An axial T_1 mapping sequence was integrated into routine S-MRCP protocol and was performed in all patients. Patients fasted for at least 4 hours prior to the MR examination. All patients were imaged on the same 3T Magnetom Verio (Siemens Medical Solutions, Malvern, PA) scanner. T_1 maps were acquired using a dual flip angle 3D gradient echo technique with the same imaging protocol and Siemens MapIt software for all the patients. Imaging parameters were: 48 axial slices of 4 mm thickness acquired within an 18-second breath-hold with repetition time (TR) of 3.87 msec, echo time (TE) of 1.32 msec, flip angle of 2° and 13° , acquisition matrix of 320×168 , parallel imaging (Siemens GRAPPA) factor of 2, field of view of 300×400 mm (adjusted according to patient size), and bandwidth of 446 Hz/pixel. Region of interest (ROI) measurements for calculation of fat signal fraction (FSF) were made on axial breath-hold 2-point DIXON T_1 -weighted images, which was acquired using TR of 5.45 msec, TE of 2.45 and 3.67 msec, and 9° flip angle. The secretin phase of the S-MRCP was performed following administration of $16 \mu\text{g}$ of secretin (ChiRhoStim, ChiRhoClin, Burtonsville, MD) via slow intravenous infusion over 1 minute. Subsequently, the pancreas was imaged using a coronal 2D single-shot turbo spin echo sequence (HASTE, Siemens Medical Solutions), repeated every 60 seconds for up to 10 minutes.

Image Analysis

During the initial assessment of the patients, the largest diameter of the main pancreatic duct and number of ectatic branch ducts were recorded on the last image of the post-secretin S-MRCP by a radiologist with 12 years of experience (Q.W.). Patients were included in the study if both ERCP and S-MRCP ductal findings indicated either normal or mild CP based on Cambridge Classification of CP. Subsequently, two separate fellowship-trained abdominal imagers with 8 and 11 years of experience, blinded to the ERCP and S-MRCP dataset, performed measurement of T_1 relaxation time, FSF, and anterior–posterior (AP) diameter from the head, body, and tail of the pancreas. Special attention was given to drawing ROI circles (1.5 cm^2) in a homogenous region of the parenchyma avoiding volume averaging from retroperitoneal fat, vessels, and pancreatic duct (Fig. 1). T_1 -weighted DIXON series were used for FSF and measuring AP diameter. FSF of the parenchyma was calculated from signal intensities (SI) of fat and water fractions using the formula:

$$\text{FSF} = \text{SI}_{\text{Fat}} / [\text{SI}_{\text{Fat}} + \text{SI}_{\text{Water}}]$$

Statistical Analysis

The two-tailed probability t -test was used to determine differences of T_1 relaxation times, FSF, main pancreatic duct diameter, and AP diameter between the control and mild CP patients. One-way analysis of variance (ANOVA) was used to compare the T_1 values in the head, body, and tail of the pancreas. A linear weighted kappa value was used to assess interobserver agreement. Receiver operating characteristic (ROC) curve analysis was

performed to determine the accuracy of the T_1 relaxation time as a differentiating criterion for mild CP. Spearman's rank correlation coefficient was used to assess the relationship between T_1 relaxation times, age, AP diameter, and FSF. The significance level (α) used in this study was <0.05 and correlation coefficients were interpreted as: weak, 0.2; moderate, 0.5; strong, 0.8; and perfect 1.0.⁷ A multiple regression model was used to analyze the relationship between a dependent variable (presence of mild CP) and independent variables (T_1 relaxation time, FSF, patient's age, and AP diameter of the pancreas). Multiple regression models used automatic weighting to correct for heteroscedasticity. Statistical analyses were performed using MedCalc v. 16.2.0 (MedCalc Software, Mariakerke, Belgium).

Results

Mean pancreatic ductal diameter in the control group was 2.6 mm (range: 1–3.2 mm) versus 3.2 mm in the mild CP group (range: 2.5–3.7) ($P < 0.0001$). The mean number of ectatic side-branches in the control group was 1 (range: 0–2) versus 5 (range: 3–10) in the mild CP group. Serum amylase and lipase levels were within the normal range in both groups (Table 1).

Correlation of T_1 Relaxation Time and Mild Chronic Pancreatitis (Table 2)

The T_1 relaxation times measured in the head, body, and tail of the pancreas were similar in the control ($P = 0.68$) and mild CP groups ($P = 0.57$); therefore, average values were used in the analysis. There was a statistically significant difference ($P < 0.0001$) in the mean T_1 relaxation times of the pancreas between the control (mean = 797 msec, 95% confidence interval [CI]: 730, 865) and mild CP groups (mean = 1099 msec, 95% CI: 1032, 1166) (Fig. 2). Using the area under the ROC curve analysis, a T_1 relaxation time threshold value of 900 msec revealed 80% sensitivity (95% CI: 65, 90) and 69% specificity (95% CI: 56, 82) for the diagnosis of mild CP (area under the curve [AUC] = 0.81) (Fig. 3). There was a substantial interobserver agreement (kappa = 0.74, 95% CI: 0.65–0.82) for measurement of T_1 relaxation times between the two radiologists.

Correlation of Age With T_1 Relaxation Time, FSF, and AP Diameter (Table 3)

There was a weak positive correlation between the age and T_1 relaxation time in the control group ($\rho = 0.28$, 95% CI: 0.01, 0.51, $P = 0.04$) and in the mild CP group ($\rho = 0.17$, 95% CI: -0.13, 0.44, $P = 0.17$) (Fig. 4). There was a weak positive correlation between the age and FSF in the control group ($\rho = 0.34$, 95% CI: 0.07, 0.56, $P = 0.01$) and in the mild CP group ($\rho = 0.26$, 95% CI: -0.04 to 0.51, $P = 0.08$). There was a negative correlation between the age and AP diameter of the gland in the mild CP group ($\rho = -0.56$, 95% CI: -0.73, -0.32, $P < 0.0001$) and in the control group ($\rho = -0.26$, 95% CI: -0.49, 0.01, $P = 0.06$). The mean AP diameter of the pancreas was 1.1 mm larger in the control group (19.3 mm, range: 11–27 mm) than the mild CP group (18.2 mm, range: 12–24 mm), but this was not statistically significant ($P = 0.11$).

Correlation of FSF With T_1 Relaxation Time and AP Diameter (Table 4)

We found a weak positive correlation between the T_1 relaxation time and the FSF in the control group ($\rho = 0.33$, 95% CI: 0.07 to 0.55, $P = 0.01$), but we did not see this correlation in the mild CP group ($\rho = 0.01$, 95% CI: -0.28 to 0.31, $P = 0.92$). There was a weak negative correlation between the FSF and the AP diameter of the gland in the mild CP group ($\rho = -0.31$, 95% CI: -0.55, -0.02, $P = 0.04$) and in the control group ($\rho = -0.26$, 95% CI: -0.49, 0.01, $P = 0.06$) (Table 4).

Multiple Regression Analysis for Diagnosis of Mild Chronic Pancreatitis (Table 5)

T_1 relaxation time was the only statistically significant variable correlating with the diagnosis of mild CP ($P < 0.0001$). Patient's age, FSF, and diameter of the gland did not have a statistically significant correlation with the mild CP ($P = 0.22$, 0.24 and 0.35, respectively).

Discussion

T_1 mapping used to be a burdensome MRI technique, since traditional spin echo images required long imaging times and was difficult to accomplish when covering large volumes and dealing with respiratory motion.⁸ However, commercially available fast volumetric T_1 mapping techniques⁸⁻¹¹ have lowered the imaging time to a single breath-hold, allowing T_1 mapping to reemerge as a potentially valuable tool in the evaluation of variety of pathologies. T_1 mapping has been successfully used in a number of cardiac conditions including myocardial fibrosis and myocardial deposition diseases.¹² One of the first studies using T_1 mapping in the abdomen was done for detection of liver fibrosis.¹³

Previous studies reported the usefulness of different imaging techniques incorporated into S-MRCP for the diagnosis of CP. Studies using conventional T_1 -weighted MR images (eg, gradient echo imaging) were limited by variation of the image contrast, which depends on the type of sequence and the imaging parameters used in different scanners. This limitation mandated using the signal intensity ratio (SIR), which is the ratio of pancreas to another organ such as spleen, paraspinal muscle, kidney, or liver. When Balci et al measured T_1 SIR of pancreas to spleen in 24 patients and compared them to the results of endoscopic pancreatic function testing (ePFT), there was no statistically significant difference between the normal and CP groups.¹⁴ However, a recent investigation of 29 patients who underwent pancreatectomy reported that the T_1 SIR and apparent diffusion coefficient (ADC) of the pancreas correlated with the degree of fibrosis.¹⁵

The T_1 mapping technique used in this study should be a more reliable and accurate method than the conventional T_1 -weighted techniques since it is directly measuring the T_1 relaxation time of the target organ. This numerical value is a tissue-specific property and it is independent of imaging parameters. Despite the variety of methods of image acquisition by different vendors, T_1 relaxation times should be interchangeable across MRI machines with minimal variances as long as it is performed in the same strength magnet. Nevertheless, it may be necessary to verify this via multicenter and multivendor studies.

Secretin is a hormone that stimulates pancreas to secrete a significant amount of pancreatic fluid while transiently increasing the tone of the sphincter of Oddi. If the secretin is given during MRCP, measuring the volume of fluid filling the duodenum has been shown to provide an indirect estimate of exocrine function with a sensitivity of 72% and specificity of 87%.^{16,17} However, using secretin adds 12 minutes of imaging time and at least 2 minutes of slow intravenous infusion, as well significant cost to the study. T_1 mapping acquisition takes only 20 seconds to acquire and therefore might have potential to be a practical imaging test for the diagnosis of CP without any additional cost.

Establishing a diagnosis often requires multiple imaging tests when the patient's history and laboratory findings are suspicious for mild CP. Traditionally, ERCP and ePFT have been used as a gold standard, at least for research purposes.² In this study the diagnosis of mild CP was established by combining the patient's history, presenting symptomatology, laboratory tests, and concordant findings on ERCP and S-MRCP using the Cambridge Classification. Future studies using ePFT as the reference standard would be helpful to further assess the value of T_1 mapping.

An important factor for imaging of CP is the presence of fatty infiltration and parenchymal atrophy, which are two commonly observed manifestations of the disease. Since fat tissue intermixing with the pancreas could interfere with the MR signal, we wanted to ensure that the reviewers placed ROIs on the most homogenous regions of the gland. We found the mean FSF of the mild CP group (8.3%) to be higher than the control group (10.4%). Our results concur with a recent study of 165 patients who underwent MRCP and subsequent pancreatectomy and reported a positive correlation between the pancreatic fibrosis and FSF.¹⁸ We observed a weak positive correlation between FSF and T_1 signal in the control group; however, there was no correlation in the mild CP group. Since fat tissue has a significantly shorter T_1 relaxation time, the presence of relatively higher FSF in CP group might have lowered the average values of T_1 relaxation times in this group. We also looked into the relationship between the T_1 relaxation time and other variables using multiple regression analysis and found that FSF, age, and diameter of the gland did not correlate with the diagnosis of mild CP.

This study is limited by its retrospective design, patient selection criteria, relatively small subject numbers, and some results being close to statistical significance. The Cambridge Classification used by both ERCP and MRCP has been reported to have low sensitivity for the detection of early CP.^{19,20} We used a dual flip angle, 3D gradient echo technique (Siemens MapIt Software) to acquire T_1 maps. While this method can acquire volumetric T_1 maps within a much shorter time window, it is sensitive to B1 + field inhomogeneity.²¹ Therefore, B1 + correction may be incorporated as an improvement in future studies. Also, the T_1 relaxation time of the tissues depend on the magnetic field strength²²; therefore, T_1 relaxation times should only be compared with the same strength scanners.

In conclusion, T_1 mapping shows promise as a practical and relatively cost-effective quantitative imaging technique for the diagnosis of mild CP. It would be helpful to validate our results with multicenter and multivendor studies and also with other reference standards such as ePFT or surgical pathology.

References

1. Yadav D, Timmons L, Benson JT, Dierkhising RA, Chari ST. Incidence, prevalence, and survival of chronic pancreatitis: a population-based study. *Am J Gastroenterol*. 2011; 106:2192–2199. [PubMed: 21946280]
2. Chowdhury RS, Forsmark CE. Review article: Pancreatic function testing. *Aliment Pharmacol Ther*. 2003; 17:733–750. [PubMed: 12641496]
3. Sarner M, Cotton PB. Classification of pancreatitis. *Gut*. 1984; 25:756–759. [PubMed: 6735257]
4. Cote GA, Smith J, Sherman S, Kelly K. Technologies for imaging the normal and diseased pancreas. *Gastroenterology*. 2013; 144:1262–1271. e1261. [PubMed: 23622136]
5. Alvarez-Sanchez MV, Jenssen C, Faiss S, Napoleon B. Interventional endoscopic ultrasonography: an overview of safety and complications. *Surg Endosc*. 2014; 28:712–734. [PubMed: 24196551]
6. Stevens T, Lopez R, Adler DG, et al. Multicenter comparison of the interobserver agreement of standard EUS scoring and Rosemont classification scoring for diagnosis of chronic pancreatitis. *Gastrointest Endosc*. 2010; 71:519–526. [PubMed: 20189510]
7. Zou KH, Tuncali K, Silverman SG. Correlation and simple linear regression. *Radiology*. 2003; 227:617–622. [PubMed: 12773666]
8. Kimelman T, Vu A, Storey P, McKenzie C, Burstein D, Prasad P. Three-dimensional T1 mapping for dGEMRIC at 3.0 T using the Look Locker method. *Investig Radiol*. 2006; 41:198–203. [PubMed: 16428993]
9. Henderson E, McKinnon G, Lee TY, Rutt BK. A fast 3D look-locker method for volumetric T1 mapping. *Magn Reson Imaging*. 1999; 17:1163–1171. [PubMed: 10499678]
10. Shin W, Gu H, Yang Y. Fast high-resolution T1 mapping using inversion-recovery Look-Locker echo-planar imaging at steady state: optimization for accuracy and reliability. *Magn Reson Medicine*. 2009; 61:899–906.
11. Chen Y, Jiang Y, Pahwa S, et al. MR fingerprinting for rapid quantitative abdominal imaging. *Radiology*. 2016; 152037
12. Schelbert EB, Messroghli DR. State of the art: clinical applications of cardiac T1 mapping. *Radiology*. 2016; 278:658–676. [PubMed: 26885733]
13. Kim KA, Park MS, Kim IS, et al. Quantitative evaluation of liver cirrhosis using T1 relaxation time with 3 tesla MRI before and after oxygen inhalation. *J Magn Reson Imaging*. 2012; 36:405–410. [PubMed: 22392835]
14. Balci NC, Smith A, Momtahan AJ, et al. MRI and S-MRCP findings in patients with suspected chronic pancreatitis: correlation with endoscopic pancreatic function testing (ePFT). *J Magn Reson Imaging*. 2010; 31:601–606. [PubMed: 20187202]
15. Watanabe H, Kanematsu M, Tanaka K, et al. Fibrosis and postoperative fistula of the pancreas: correlation with MR imaging findings--preliminary results. *Radiology*. 2014; 270:791–799. [PubMed: 24475834]
16. Cappeliez O, Delhaye M, Deviere J, et al. Chronic pancreatitis: evaluation of pancreatic exocrine function with MR pancreatography after secretin stimulation. *Radiology*. 2000; 215:358–364. [PubMed: 10796908]
17. Matos C, Metens T, Deviere J, et al. Pancreatic duct: morphologic and functional evaluation with dynamic MR pancreatography after secretin stimulation. *Radiology*. 1997; 203:435–441. [PubMed: 9114101]
18. Yoon JH, Lee JM, Lee KB, et al. Pancreatic steatosis and fibrosis: quantitative assessment with preoperative multiparametric MR imaging. *Radiology*. 2015; 142254
19. Buchler MW, Martignoni ME, Friess H, Malferteiner P. A proposal for a new clinical classification of chronic pancreatitis. *BMC Gastroenterol*. 2009; 9:93. [PubMed: 20003450]
20. Forsmark CE. The diagnosis of chronic pancreatitis. *Gastrointest Endosc*. 2000; 52:293–298. [PubMed: 10922118]
21. Treier R, Steingoetter A, Fried M, Schwizer W, Boesiger P. Optimized and combined T1 and B1 mapping technique for fast and accurate T1 quantification in contrast-enhanced abdominal MRI. *Magn Reson Med*. 2007; 57:568–576. [PubMed: 17326175]

22. Bottomley PA, Foster TH, Argersinger RE, Pfeifer LM. A review of normal tissue hydrogen NMR relaxation times and relaxation mechanisms from 1–100 MHz: dependence on tissue type, NMR frequency, temperature, species, excision, and age. *Med Phys.* 1984; 11:425–448. [PubMed: 6482839]

Author Manuscript

Author Manuscript

Author Manuscript

Author Manuscript

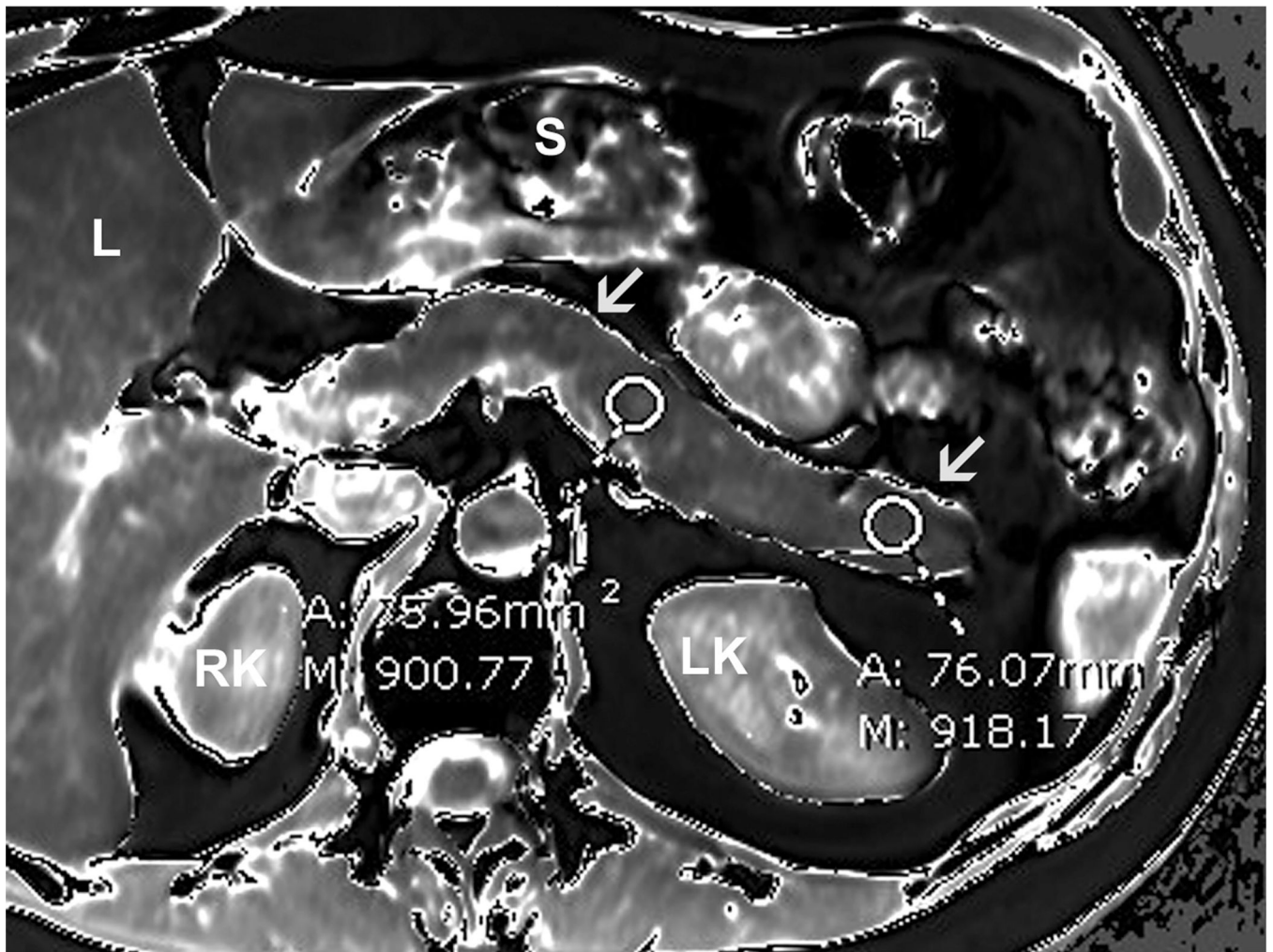


FIGURE 1.

T_1 maps can be displayed in color or gray scale where signal intensity of each pixel quantitatively encodes its T_1 relaxation time. This is a gray-scale axial T_1 map acquired in a 51-year-old female with upper abdominal pain. Circular ROI measurements were obtained from the head, body, and tail of the pancreas. Special attention was given to drawing ROI circles in a homogenous region of the parenchyma avoiding volume averaging from retroperitoneal fat, vessels and pancreatic duct. Arrows = pancreas, L = liver, S = stomach, RK = right kidney, LK = left kidney.

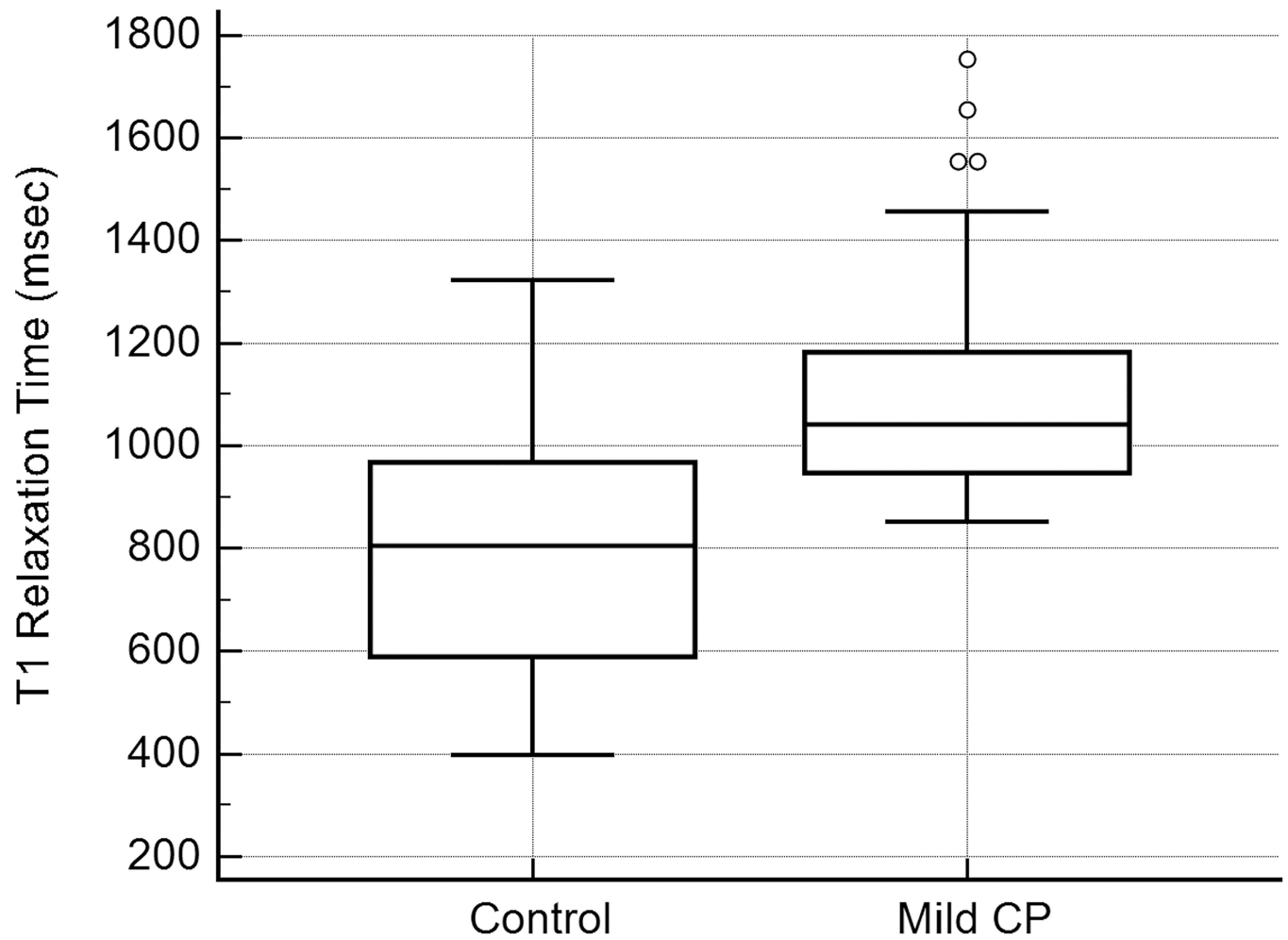


FIGURE 2.

Box-and-whisker plot of T_1 relaxation times in the control (mean = 797 msec, 95% CI: 730, 865) and mild CP group (mean = 1099 msec, 95% CI: 1032, 1166). There is a statistically significant increase ($P < 0.0001$) in the average T_1 relaxation time of the pancreas in mild CP group.

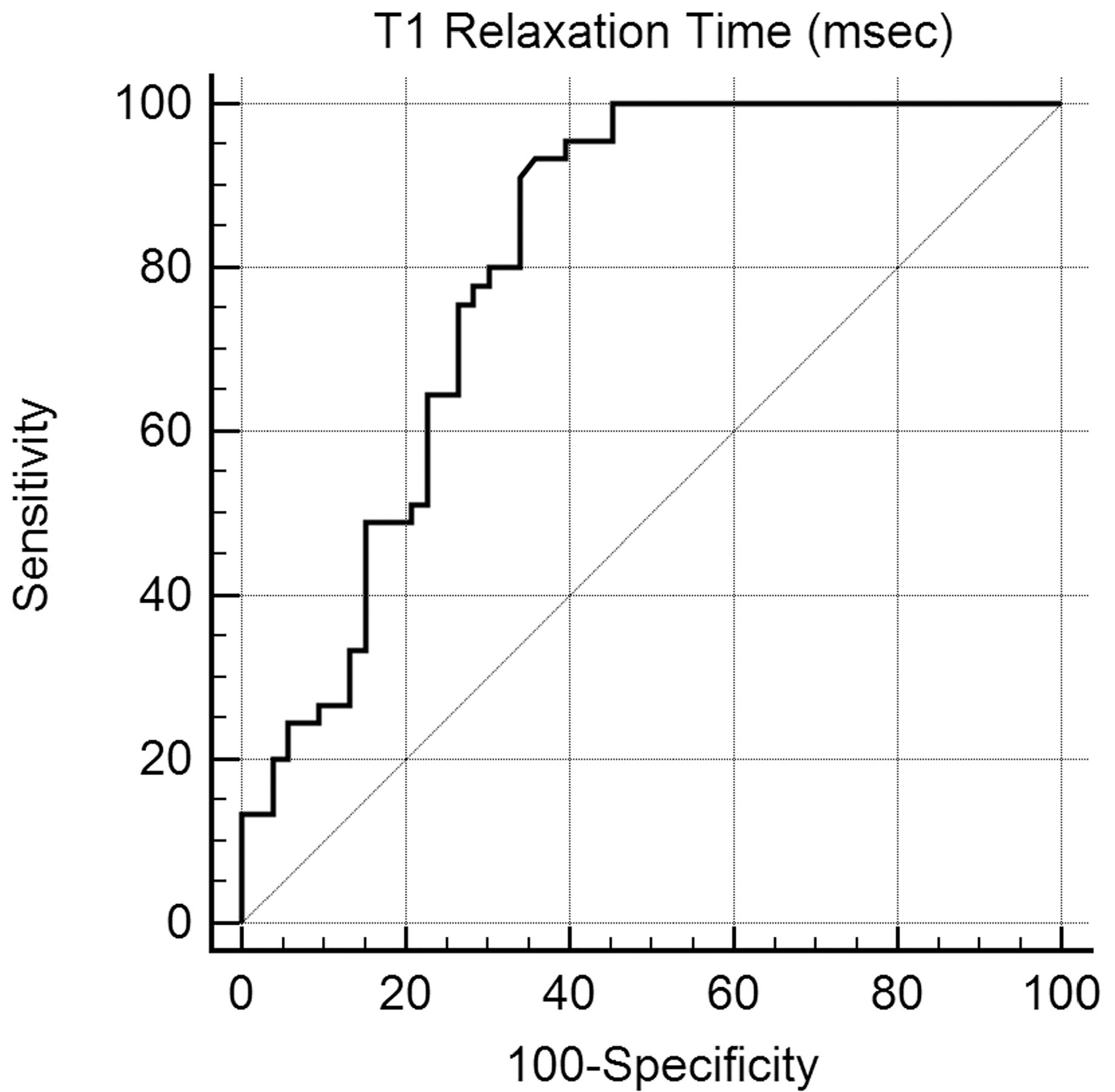


FIGURE 3.

ROC curve analysis for T_1 relaxation time as a criterion for diagnosis of mild CP. Threshold value of 900 msec was 80% sensitive (95% CI: 65, 90) and 69% specific (95% CI: 56, 82) for the diagnosis of mild CP (AUC = 0.81).

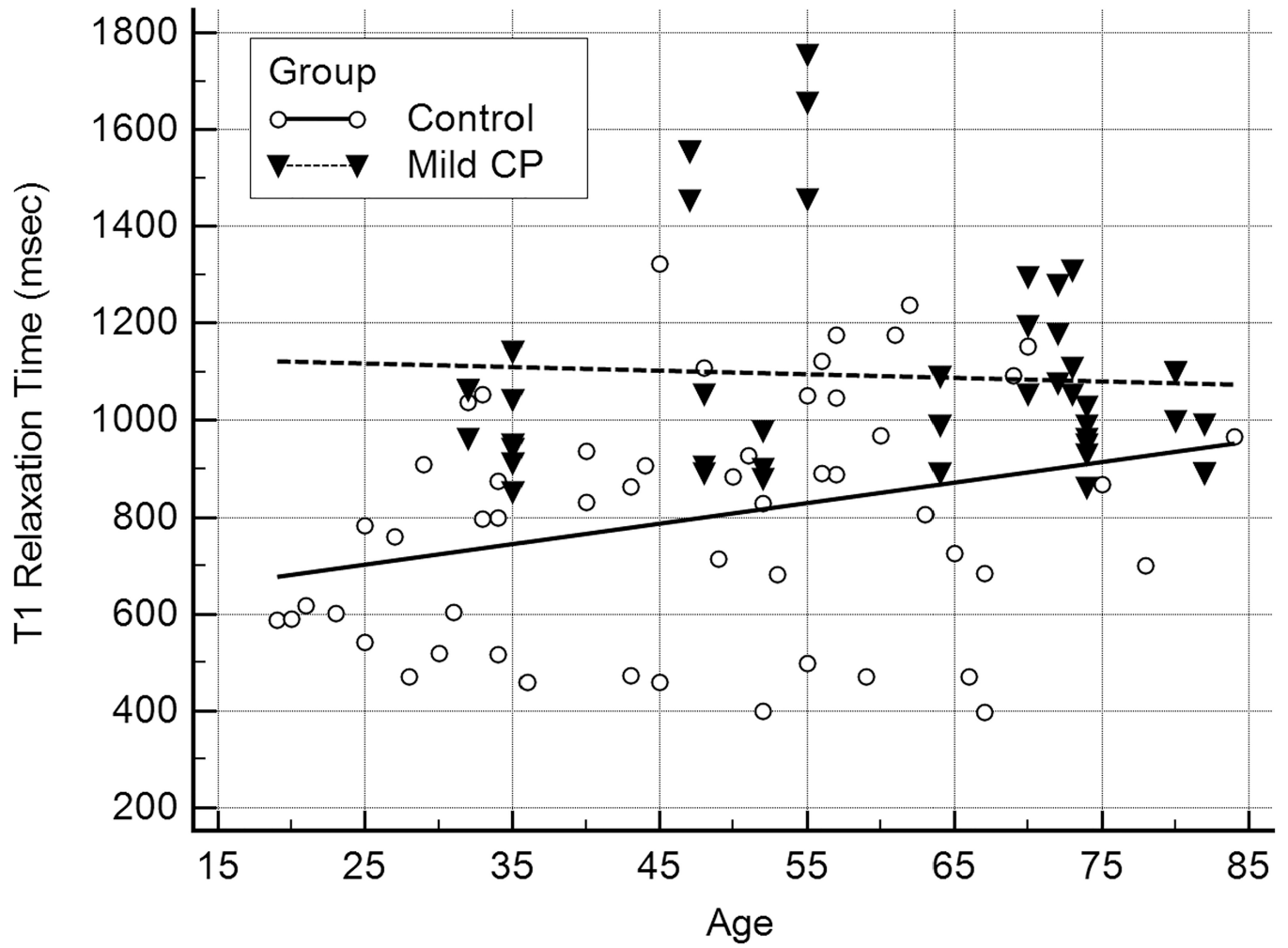


FIGURE 4.

This scatterplot with regression lines shows a weak positive correlation between the age and T_1 relaxation time of the pancreas in the control group ($P < 0.01$). This positive correlation was not observed in the mild CP group ($P = 0.55$).

TABLE 1

Study Population Separated by Control and Mild CP Groups

	Control (n = 53)	Mild CP (n = 45)
Age	55 (Range: 19–84)	59 (Range: 32–82)
Female (F:M)	66% (35:53)	40% (18:45)
BMI	35.4 (Range: 24.1–41.4)	37.8 (Range: 25.6–42.7)
Lipase level	62 (Range: 31–173)	76 (Range: 26–156)
Amylase level	32 U/L (Range: 26–78)	44 U/L (range: 25–89)
AP diameter	19.3 mm (Range: 11–27 mm)	18.2 mm (range: 12–24 mm)
Fat signal fraction (FSF)	8.3% (95% CI: 7.2, 9.5 %)	10.4% (95%CI: 9.1, 11.7 %)
MPD diameter	2.6 mm (Range: 1.0–3.2 mm)	3.2 mm (Range: 2.5–3.7 mm)
Ectatic side-branches (#)	1 (Range: 0–2)	5 (Range: 3–10)

MPD = main pancreatic duct (average), AP = anterior-posterior, BMI = Sbody-mass index. Normal range for amylase is 20–85 U/L. Normal range for lipase is 0–160 U/L.

Author Manuscript

Author Manuscript

Author Manuscript

Author Manuscript

TABLE 2

T1 Relaxation Times Within the Control and Mild CP Groups

T1 relaxation time	Control (<i>n</i> = 53)	Mild CP (<i>n</i> = 45)	
Mean	797 msec (95% CI: 730, 865)	1099 msec (95% CI: 1032, 1166)	<i>P</i> < 0.0001
Head	773 (SD: 269)	1047 (SD: 366)	<i>P</i> < 0.0001
Body	803 (SD: 344)	1135 (SD: 407)	<i>P</i> = 0.0001
Tail	827 (SD: 330)	1072 (SD: 441)	<i>P</i> = 0.003

Average T1 relaxation time in mild CP group is significantly higher than the control group. Both the control and mild CP groups showed similar measurements in the head, body and tail (*P* = 0.68 and 0.57, respectively) therefore, average values were used in the analysis. Numbers in parentheses show standard deviation.

Correlation of Patient's Age With the T1 Relaxation Time, FSF, and Diameter of the Gland in the Control and Mild CP Groups

TABLE 3

	Control (<i>n</i> = 53)			Mild CP (<i>n</i> = 45)		
	ρ	95% CI	<i>P</i>	ρ	95% CI	<i>P</i>
T1 relaxation time (msec)	0.28	0.01, 0.51	0.04	0.17	-0.13, 0.44	0.17
AP diameter (mm)	-0.26	-0.49, 0.01	0.06	-0.56	-0.73, -0.32	<0.0001
FSF	0.34	0.07, 0.56	0.01	0.26	-0.04, 0.51	0.08

Rho (ρ) = Spearman's rank correlation coefficient. AP = anterior-posterior, FSF = fat signal fraction.

Correlation of FSF With the T1 Relaxation Time and Diameter of the Pancreas in the Control and Mild CP Groups

TABLE 4

	Control (<i>n</i> = 53)			Mild CP (<i>n</i> = 45)		
	ρ	95% CI	<i>P</i>	ρ	95% CI	<i>P</i>
T1 relaxation time	0.33	0.07, 0.55	0.01	0.01	-0.28, 0.31	0.92
AP diameter	-0.26	-0.49, 0.01	0.06	-0.31	-0.55, -0.02	0.04

Rho (ρ) = Spearman's rank correlation coefficient. AP = anterior-posterior.

TABLE 5

Multiple Regression Analysis Showing Correlation of the Mild CP With Other Independent Variables

	Coefficient	Standard error	P
T1 relaxation time	0.0009	0.0001	<0.0001
Age	0.0031	0.0025	0.22
FSF	1.1652	0.9876	0.24
AP diameter	-0.0103	0.0110	0.35

AP = anterior-posterior, FSF = fat signal fraction.

Author Manuscript

Author Manuscript

Author Manuscript

Author Manuscript