

## Do no harm: Observation only in a 98-year-old woman with a suspicious large intraocular tumour



Ido Didi Fabian<sup>a,b,\*</sup>, Mandeep S. Sagoo<sup>a,c</sup>

<sup>a</sup> Ocular Oncology Service, Moorfields Eye Hospital, London, UK

<sup>b</sup> Ocular Oncology Service, Goldschleger Eye Institute, Sheba Medical Center, Tel-Aviv University, Tel Aviv, Israel

<sup>c</sup> NIHR Biomedical Research Centre for Ophthalmology at Moorfields Eye Hospital and UCL Institute of Ophthalmology, London, UK

### 1. Case report

A 98-year-old asymptomatic white female was referred with the incidental finding of a suspicious right iris mass. Medical history included treated hypertension and hypothyroidism. On examination, visual acuity was 20/60 in the right eye and 20/40 in the left eye. The left eye was structurally normal. In the right eye there was erosion of the iris root at the 1 o'clock position (Fig. 1). Through an undilated pupil, the edge of a pale mass with overlying pigment changes (Fig. 1) was visible. Intraocular pressure was 14 mmHg. The iridocorneal angle was obscured by the tumour on gonioscopy, but there was no suspicious circumferential spread. She was pseudophakic and on transpupillary transillumination light was transmitted through the mass. Anterior chamber-optical coherence tomography demonstrated a mass located posterior to the iris (Fig. 1). B-mode ultrasound scan (14 MHz) showed a bi-lobed tumour of medium internal echogenicity, an elevation of 4.8 mm and detectable internal blood flow (Fig. 1). Fundoscopy showed only age-related macular changes.

The differential diagnosis included an iris naevus or melanoma, metastasis to the ciliary body or a medulloepithelioma, but also rarer tumours of the non-pigmented epithelium of the ciliary body, including a true adenoma, adenocarcinoma or a Fuchs adenoma. The management options included a diagnostic tissue biopsy, plaque brachytherapy, lesion excision, enucleation, or observation. Given the patient's age, general medical background and clinical features on eye examination, especially the light transmission properties on transillumination, the working clinical diagnosis was of Fuchs adenoma, a benign pseudotumour of the non-pigmented ciliary body epithelium. Observation after 6 months showed no progression of the lesion, supporting the original diagnosis.

### 2. Discussion

Fuchs, or coronal adenoma, is an age-related hyperplasia of the non-pigmented ciliary body epithelium.<sup>1</sup> It is commonly found on autopsy, but rarely in clinical practice, as it usually occurs in the pars plicata of the eye, hidden behind the iris. Only rarely does it become large enough

to reach clinical attention,<sup>2</sup> and then can be confused for a melanoma or other cancer that would erroneously prompt biopsy, radiotherapy or even enucleation of the eye. However, if Fuchs adenoma is suspected on careful clinical examination, in an elderly patient such as in the case presented herein, close monitoring is a suitable option. In this circumstance, even for a melanoma, observation is an option if the eye is not immediately threatened, as the metastatic risk is 15% at 5 years.<sup>3</sup> For younger patients, however, even in their 70's or 80's, an interventional diagnostic approach should be seriously considered.

### 3. Conclusion

Medical intervention, whether diagnostic, therapeutic, or both, is a common approach across oncology in cases of a suspicious mass. There is an impetus once diagnosis is reached that leads to treatment, aiming for tumour control, reducing anxiety of the patient and often the treating clinician. However, in certain cases, a period of watchful waiting can be a suitable approach: *primum non nocere*, or first do no harm. Given the working diagnosis, patient's age, and inherent risks in surgery and anesthesia, observation was found to be an appropriate action in the present case.

### Patient consent

Consent to publish this case report has been obtained from the patient in writing.

### Disclosures

#### Funding

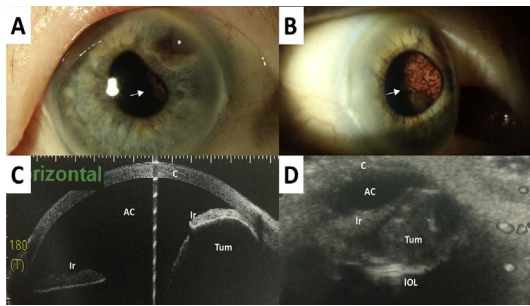
No funding or grant support.

#### Conflict of interest

The authors have no financial disclosures.

All authors attest that they meet the current ICMJE criteria for

\* Corresponding author. Moorfields Eye Hospital, 162 City Road, London EC1V 2PD, UK.  
E-mail address: [didifabian@gmail.com](mailto:didifabian@gmail.com) (I.D. Fabian).



**Fig. 1.** Fuchs adenoma in a 98-year-old woman. (A) Colour photo of the right iris showing a mass lesion on the pupillary margin (arrow) that has also eroded through the iris root (asterisk). (B) The same eye on left gaze. An amelanotic mass with overlying pigment changes and a cyst on its inferior border is seen behind the iris (arrow). (C) Anterior chamber-optical coherence tomography and (D) B-scan ultrasonography showing the tumour (Tum) pushing the iris (Ir) anteriorly, and blocking the angle (C – cornea; AC – anterior chamber, IOL – intraocular lens).

#### Authorship.

#### Acknowledgments

None.

#### References

1. Bateman JB, Foos RY. Coronal adenomas. *Arch Ophthalmol.* 1979;97(12):2379–2384.

2. Shields JA, Shields CL, Eagle Jr RC, Friedman ES, Wheatley HM. Age-related hyperplasia of the nonpigmented ciliary body epithelium (Fuchs adenoma) simulating a ciliary body malignant neoplasm. *Arch Ophthalmol.* 2009;127(9):1224–1225.
3. Shields CL, Furuta M, Thangappan A, et al. Metastasis of uveal melanoma millimeter-by-millimeter in 8033 consecutive eyes. *Arch Ophthalmol.* 2009;127(8):989–998.