



Approach to fungal infections in HIV-infected individuals: *Pneumocystis* and beyond

Richard J. Wang, MD¹, Robert F. Miller, MBBS, CBiol, FRSB, FRCP², and Laurence Huang, MD¹

Richard J. Wang: richard.wang@ucsf.edu; Robert F. Miller: robert.miller@ucl.ac.uk; Laurence Huang: laurence.huang@ucsf.edu

¹University of California San Francisco, USA

²Research Department of Infection and Population Health, Institute of Epidemiology and Healthcare University College London, London, UK, and Department of Clinical Research, Faculty of Infectious and Tropical Diseases, London School of Hygiene and Tropical Medicine, London, UK

SYNOPSIS

Many fungi cause pulmonary disease in HIV-infected patients. Major pathogens include *Pneumocystis jirovecii*, *Cryptococcus neoformans*, *Aspergillus* species, *Histoplasma capsulatum*, *Coccidioides* species, *Blastomyces dermatitidis*, *Paracoccidioides brasiliensis*, *Talaromyces marneffeii*, and *Emmonsia* species. Because symptoms are frequently non-specific, a high index of suspicion for fungal infection is required for diagnosis. Clinical manifestations of fungal infection in HIV-infected patients frequently depend on the degree of immunosuppression and the CD₄⁺ T_H cell count. Establishing definitive diagnosis is important because treatments differ. Primary and secondary prophylaxis depends on CD₄⁺ T_H cell counts as well as geographic location and local prevalence of disease.

Keywords

HIV; Opportunistic Infection; Pneumonia; Mycoses; *Pneumocystis*

The recognition of an outbreak of *Pneumocystis* pneumonia (PCP) in 1981 was a fraught moment in the history of medicine.¹ It heralded the coming HIV pandemic, a disease heretofore unknown to humankind. Opportunistic fungal pathogens, *Pneumocystis jirovecii* in particular, have contributed significantly to the morbidity and mortality of HIV-infected patients. Fortunately, the development of and increasing access to effective combination antiretroviral therapy (ART) have reduced the incidence of opportunistic infections in HIV-infected patients worldwide. Nevertheless, fungi remain an important cause of disease, especially for patients with undiagnosed HIV infection and for patients without access to, or who fail to adhere to, ART.

Publisher's Disclaimer: This is a PDF file of an unedited manuscript that has been accepted for publication. As a service to our customers we are providing this early version of the manuscript. The manuscript will undergo copyediting, typesetting, and review of the resulting proof before it is published in its final citable form. Please note that during the production process errors may be discovered which could affect the content, and all legal disclaimers that apply to the journal pertain.

In immunocompetent hosts, an array of immune mechanisms averts disease caused by fungi. Potential fungal pathogens are detected by pattern recognition receptors of innate immune cells.² These in turn produce cytokines, including IL-12, that result in activation of CD₄⁺ T_H cells. Production of interferon- γ by T_H1 cells then triggers cell-mediated, adaptive, cytotoxic immunity. The downstream effects of interferon- γ production include recruitment of leukocytes to the site of infection and enhanced macrophage phagocytosis and killing, typically resulting in elimination of the invading fungi.³

The hallmark of HIV is infection of CD₄⁺ T_H cells and, to a lesser degree, other CD₄⁺ cells including macrophages. Left untreated, HIV disrupts the function of CD₄⁺ T_H cells and, ultimately, depletes them. The consequences of HIV-mediated immune dysregulation are wide ranging and include: decreased production of interferon- γ ,⁴ impaired macrophage phagocytosis,⁵ impaired neutrophil chemotaxis,⁶ impaired neutrophil oxidative killing,⁷ B cell exhaustion, and decreased B cell antigen responsiveness.⁸ These defects in immunity conspire against the host and result in susceptibility to opportunistic fungal infections.

Because the clinical presentation and radiographic findings of opportunistic fungal infections are frequently non-specific, diagnosis relies on maintaining a high index of suspicion. The intensity and duration of immunosuppression in HIV-infected patients is a major risk factor. The likelihood of some infections, like PCP, is inversely related to a patient's CD₄⁺ T_H cell count; for other infections, like coccidioidomycosis, the clinical manifestations differ among patients with lower CD₄⁺ T_H cell counts than for immunocompetent patients. Diagnosis typically relies on identification of the fungus by microscopy or culture, except in select instances where antigen or serum antibody testing can be definitive.

This review discusses the clinical presentation, radiographic findings, diagnosis, and management of selected respiratory fungal infections in patients with HIV. Particular attention is extended to *Pneumocystis pneumonia*, which, in some geographic locales even today, remains the most common AIDS-defining opportunistic infection.⁹

I. *Pneumocystis pneumonia*

A. *Pneumocystis jirovecii*

Pneumocystis is a genus of host obligate ascomycete fungus. There are numerous species of *Pneumocystis*, each of which is specific to a particular mammalian host species. *Pneumocystis jirovecii* infects and colonizes humans. It is host obligate, it cannot be cultured or grown outside of the human body, and there is as yet no reliable evidence for an environmental reservoir for this organism other than the human host.¹⁰⁻¹²

In immunocompetent humans, *Pneumocystis* does not cause any clear clinical syndrome. Serologic studies indicate that humans are exposed to *Pneumocystis* as infants or young children.¹³ *Pneumocystis* is unlikely to cause anything more than mild, self-limiting respiratory symptoms.^{14,15} Animal models indicate that *Pneumocystis* is spread from host to host via airborne transmission, and *Pneumocystis jirovecii* is likely spread among human hosts in the same fashion.¹⁶ Most healthy adults do not have detectable *Pneumocystis* in

respiratory specimens, but it is possible for immunocompetent adults, especially those with chronic obstructive pulmonary disease (COPD) or cystic fibrosis, to harbor an asymptomatic colonization with *Pneumocystis*. The consequences of chronic colonization may be progressive impairment of lung function over time.¹⁷

By contrast, in immunocompromised hosts, *Pneumocystis* causes a devastating and frequently fatal pneumonia. The risk of *Pneumocystis* pneumonia increases with the degree of immunosuppression, and lower CD4⁺ T_H cell counts predict risk of PCP. Among patients with HIV, 95% of cases of PCP occur in patients with a CD4⁺ T_H cell count less than 200 cells/μL; at a CD4⁺ T_H cell count of 50 cells/μL, the risk of PCP is higher than at 100 cells/μL or 200 cells/μL.^{18–20}

B. What is the clinical presentation of *Pneumocystis* pneumonia?

The clinical presentation of PCP is non-specific and cannot reliably be distinguished from other infectious pulmonary processes. Typical symptoms include fever, dyspnea, and a cough that can be either non-productive or productive of scant sputum, but is rarely purulent. Although the disease can be fulminant, PCP in patients with HIV frequently presents with an indolent course. Patients may experience weeks of slowly progressive symptoms, including a sensation of chest discomfort or chest tightness and exercise intolerance.²¹ This is different from the presentation of PCP in medically immunosuppressed patients without HIV infection, which is more frequently acute and may rapidly progress to respiratory failure within days.²² Physical examination is also non-specific. Chest auscultation may reveal end-inspiratory crackles, but is frequently normal.²¹ Severe disease may be characterized by signs of acute respiratory failure. Hypoxemia is characteristic and can be mild (partial pressure of arterial oxygen when breathing room air greater than 70 mm Hg and alveolar-arterial O₂ difference less than 35 mm Hg), moderate (alveolar-arterial O₂ difference 35 to 45 mm Hg), or severe (alveolar-arterial O₂ difference greater than 45 mm Hg).²³

C. What tests can be used for diagnosing *Pneumocystis* pneumonia?

There is no serologic test that is specific for PCP. Lactate dehydrogenase is a non-specific biomarker of cell turnover and cellular damage, and serum levels are frequently elevated in patients with PCP but are also elevated in the setting of other diseases including pneumonia caused by bacteria, mycobacteria, and other fungi.^{24,25} (1–3) β-D-glucan is a component of the fungal cell wall and can be detected in the serum of patients with PCP, but also does not distinguish between PCP and other fungal pneumonias.²⁶ These tests can be useful to support a clinical suspicion for PCP but on their own are not specific enough for definitive diagnosis in most cases.

Chest imaging has an important role in the diagnosis of PCP. The classic appearance of a chest radiograph for a patient with PCP is diffuse, bilateral, interstitial type (commonly described as reticular, granular, or “ground glass”) opacities (Fig. 1).²⁷ However, the chest radiograph in a patient with early disease may be normal; with late or severe disease, the chest radiograph may show frank alveolar consolidation. Unusual but not inconsistent features of PCP on chest radiography include focal asymmetric interstitial or alveolar

Because of the high diagnostic yield of bronchoscopy with BAL, biopsy is seldom necessary to confirm, or rule out, the diagnosis of PCP.

D. What are treatment options for *Pneumocystis pneumonia*?

If there is clinical suspicion for PCP in an HIV-infected patient, it is reasonable to initiate empiric therapy while awaiting the results of diagnostic tests. Treatment need not be deferred, since the yield for diagnosis of PCP from BAL fluid is unchanged for up to 14 days after starting treatment.²³

The first choice of treatment is trimethoprim-sulfamethoxazole (TMP-SMX). The 1:5 fixed-dose combination of TMP 15–20 mg/kg/day and SMX 75–100 mg/kg/day is given in 3–4 divided doses. It can be administered orally or intravenously (IV). Although oral bioavailability is excellent, IV therapy is often preferred initially for cases of moderate to severe PCP.³⁵ The total recommended dose duration is 21 days; shorter courses have resulted in higher rates of treatment failure.²² Use of TMP-SMX may be limited by adverse reactions, including rash, fever, transaminitis, nephritis, hyperkalemia, and cytopenias.

There are alternative treatment options if TMP-SMX is not tolerated or if treatment fails. IV pentamidine dosed at 4 mg/kg once daily has equivalent efficacy to IV TMP-SMX, but greater toxicity.^{35,36} Adverse reactions include infusion site phlebitis, severe hypotension during infusion, prolonged QT, torsades de pointes, pancreatitis, hypoglycemia, transaminitis, nausea and vomiting, nephrotoxicity, hypocalcemia, hypomagnesemia, hyponatremia, and leukopenia. Given the variety and severity of these toxicities, IV pentamidine is typically reserved for patients with severe, life-threatening PCP who cannot tolerate or are unresponsive to TMP-SMX.

Other alternative therapies include clindamycin with primaquine. Clindamycin can be administered intravenously, 900 mg three times daily, or orally, 600 mg three times daily. Primaquine is only available in an oral formulation and is given 30 mg once daily.³⁵ Clindamycin with primaquine has equivalent efficacy to TMP-SMX for initial treatment of mild to moderate PCP, and there is evidence to suggest that it is more effective than IV pentamidine as a salvage therapy although there are no randomized controlled trials comparing them.³⁷

Oral dapsone 100 mg daily with TMP 15 mg/kg/day in three divided doses is as effective as oral TMP-SMX for mild or moderate PCP but is ineffective for severe PCP. Atovaquone suspension 750 mg orally, twice daily, is inferior therapy compared to TMP-SMX for mild or moderate PCP and is ineffective for severe PCP.³⁵

Adjunctive corticosteroids decrease need for ICU admission, mechanical ventilation, and mortality in HIV-infected patients with moderate to severe PCP (partial pressure of arterial oxygen when breathing room air less than 70 mm Hg or alveolar-arterial O₂ difference greater than 35 mm Hg).^{38,39} Ideally, steroids should be started at the time that *Pneumocystis*-specific treatment is initiated, and definitely within the first 72 hours of treatment. The recommended dosing schedule is 40 mg prednisone (or an equipotent dose of

IV methylprednisolone) twice daily for 5 days, then 40 mg once daily for 5 days, and 20 mg once daily for the remaining 11 days of treatment.³⁵

With treatment, overall mortality from PCP in HIV-infected patients is about 10%. With appropriate treatment, early clinical deterioration is common, attributed to a host inflammatory response provoked by antibiotic-induced lysis of *Pneumocystis* organisms. If there is no improvement or further clinical decline after at least 5 days of treatment, treatment failure is a possibility and it would be reasonable to consider switching to an alternative therapy, although other causes of clinical deterioration, such as iatrogenic hypervolemia, pneumothorax, and methemoglobinemia, would need to be excluded.

E. When is prophylaxis appropriate and with what regimen?

The NIH, CDC, and IDSA consensus guidelines recommend PCP prophylaxis for patients with CD4⁺ T_H cell counts below 200 cells/ μ L. TMP-SMX is the preferred agent. Traditionally, one double strength tablet (160 mg TMP and 800 mg SMX) once daily has been the regimen of choice, but one single strength tablet (80 mg TMP and 400 mg SMX) once daily is also effective. Alternatively, one double strength tablet can be taken three times weekly. If TMP-SMX cannot be used because of adverse effects, alternative options for prophylaxis include aerosolized pentamidine 300 mg once monthly; dapsone 100 mg once daily; dapsone 50 mg once daily with pyrimethamine 50 mg once weekly; and atovaquone 1500 mg oral suspension once daily. These regimens are less effective than prophylaxis with TMP-SMX. PCP prophylaxis can be discontinued if the CD4⁺ T_H cell count increases to above 200 cells/ μ L for at least three months as a result of ART. Although PCP can occur when CD4⁺ T_H counts are greater than 200 cells/ μ L, the benefit of ongoing PCP chemoprophylaxis is diminished and may be outweighed by the risk of drug toxicity.³⁵

II. Cryptococcus

Cryptococcus is a genus of encapsulated yeast that is ubiquitous in human-populated environments and can be isolated from bird excrement, rotting fruit, and soil.⁴⁰ Some species, such as *Cryptococcus gatii*, are known to cause disease in immunocompetent hosts. The species that most frequently affects HIV-infected patients is *Cryptococcus neoformans*. Although it is known to occasionally cause asymptomatic colonization in immunocompetent hosts with structural lung disease, *C. neoformans* is almost exclusively an opportunistic pathogen. A CD4⁺ T_H cell count less than 100 cells/ μ L is a risk factor for cryptococcosis.⁴¹

C. neoformans gains access to the human host through inhalation of fungal basidiospores. Host immunosuppression allows *C. neoformans* to disseminate throughout the body. In HIV-infected patients, cryptococcal meningitis is the most common manifestation. In disseminated disease, multiple organs including the skin, bone, eye, prostate, and lung can be affected. Although the respiratory system is the portal of entry, isolated cryptococcal pneumonia without other organ involvement is less common than disseminated disease.⁴² Symptoms of cryptococcal pneumonia are non-specific and include cough, dyspnea, sputum production, chest pain, and pleurisy. Findings on chest radiography are varied, and include unilateral or bilateral interstitial opacities, focal consolidation, solitary or multiple pulmonary nodules, cavitation, hilar adenopathy, and pleural effusion (Fig 3).⁴³ Because of

the severity of immunosuppression that permits invasive cryptococcosis, simultaneous coinfection with other pulmonary pathogens is common.

The cryptococcal antigen (CrAg) test, which detects the presence of capsular polysaccharides, is important for investigating cryptococcal infection. The test can be performed on serum, cerebrospinal fluid, BAL fluid, or pleural fluid. The serum CrAg test is highly sensitive for both cryptococemia and cryptococcal meningitis; a negative serum CrAg markedly decreases the likelihood of cryptococcal meningitis. The serum CrAg test is often positive in cases of cryptococcal pneumonia, although it can be negative in cases of isolated cryptococcal pneumonia without dissemination.^{43,44} The CrAg test can also be performed on BAL fluid, although caution is warranted; in one study, the sensitivity of the test was 71% and the positive predictive value was 0.59.⁴⁵

Definitive diagnosis of cryptococcal pneumonia is typically made by cytopathologic examination of a respiratory specimen, histopathologic examination of a biopsy specimen, or culture of either. The yield of expectorated sputum is low; in one series, sputum microscopy detected only one of 11 patients with cryptococcal pneumonia.⁴⁶ BAL fluid is significantly better with a diagnostic yield of 82%.^{44,46} The use of PCR for the detection of *Cryptococcus* DNA in respiratory specimens is offered by some laboratories and appears promising, but the clinical utility remains to be determined.⁴⁷

There are no randomized controlled clinical trials for HIV-infected patients with isolated cryptococcal pneumonia or disseminated cryptococcosis with pulmonary involvement. Treatment recommendations are extrapolated from trials of treatment of cryptococcal meningitis. For isolated pulmonary disease with mild symptoms, treatment with oral fluconazole 400 mg daily for 12 months is recommended. For severe pulmonary disease or disseminated disease, the standard initial (induction) treatment regimen is IV amphotericin B and oral flucytosine for at least two weeks. If clinical improvement is noted, treatment can be changed to consolidation therapy with oral fluconazole 400 mg daily for at least an additional 8 weeks, followed by maintenance therapy with oral fluconazole 200 mg daily for at least one year to prevent relapse. Extrapolating from data on patients who have recovered from cryptococcal meningitis, secondary prophylaxis can be stopped if CD4⁺ T_H counts are greater than 200 cells/ μ L and the HIV viral load is undetectable for three months on ART.³⁵

Current guidelines do not support primary prophylaxis of cryptococcal disease regardless of CD4⁺ T_H count. However, routine screening for asymptomatic cryptococcal antigenemia is recommended by some experts for patients with a new diagnosis of HIV and a CD4⁺ T_H count less than 100 cells/ μ L. If the serum CrAg test is positive, CSF evaluation is required to assess for meningitis. Asymptomatic cryptococcal antigenemia is treated with fluconazole 400 mg oral daily for 12 months.³⁵

III. Aspergillus

Aspergillus is a genus of mold that is ubiquitous in the environment and can be isolated from soil worldwide.⁴⁸ Various species are known to cause human disease but the most frequent pathogen is *Aspergillus fumigatus*. Human exposure to *Aspergillus spp.* occurs by inhalation of airborne conidia. In immunocompetent hosts with normal lung architecture, it is rare for

Aspergillus to cause disease. In immunocompromised patients or patients with structural lung abnormalities, *Aspergillus* is associated with several distinct chest syndromes: aspergilloma, allergic bronchopulmonary aspergillosis (ABPA), tracheobronchial aspergillosis, chronic necrotizing aspergillosis, and invasive pulmonary aspergillosis (IPA). Different syndromes have unique risk factors. For aspergilloma, structural lung disease, like bullae in chronic obstructive pulmonary disease, is a major predisposing condition. ABPA has a predilection for patients with cystic fibrosis and severe asthma. IPA, the most severe and most dangerous manifestation of *Aspergillus* infection, affects immunocompromised hosts, particularly patients with absent or abnormal phagocyte function. The classic risk factors for IPA are corticosteroid use and granulocytopenia from hematologic malignancy or its therapies.^{49,50}

All *Aspergillus* syndromes have been described in patients with HIV infection but compared to the occurrence of other opportunistic pathogens, *Aspergillus* infection is uncommon. While IPA was initially included as an AIDS-defining opportunistic infection by the Centers for Disease Control, it was removed in 1984 when it was found that the incidence of IPA in patients with HIV infection was 0.1 percent; incidence is lower still today because of widespread use of effective ART.⁵¹ Even in patients with very low CD4⁺ T_H counts, IPA is unusual in the absence of additional risk factors such as neutropenia.

The clinical presentations of the various forms of *Aspergillus*-related disease in HIV-infected patients are not distinct from those of HIV-uninfected patients, and are described elsewhere in this volume. For invasive aspergillosis, patients with and without HIV can present with fever, cough, dyspnea, pleurisy, and sometimes hemoptysis. Imaging findings vary and can include consolidation, cavities, nodules, and pleural effusions. Definitive diagnosis requires demonstration of tissue invasion on biopsy and isolation of the organism by culture. In patients for whom biopsy is infeasible or fails to demonstrate invasive disease but for whom IPA is still suspected, initiating empiric treatment for probable IPA is reasonable. Voriconazole is the preferred therapy; alternative treatments include amphotericin, caspofungin, or posaconazole.⁵² Given its low incidence even in advanced HIV disease, prophylaxis is not recommended.³⁵

IV. Endemic fungi

Around the world, there are pathogenic fungi that have limited geographic distribution. These include *Histoplasma capsulatum*, *Coccidioides* species, *Blastomyces dermatitidis*, *Paracoccidioides brasiliensis*, *Talaromyces* (formerly *Penicillium*) *marneffeii*, and *Emmonsia* species. These fungi are dimorphic. In the environment, they grow as molds. The predominant method of human infection is through inhalation of spores from contaminated soils. Once deposited in the human respiratory tract, the fungi change and grow as yeasts. All are known to cause disease in immunocompetent hosts. Typically, the severity of disease is related to the size of the inoculum as well as to the state of host immunity. In patients who are immunocompromised, particularly with respect to cell-mediated immunity, infections are more severe, more likely to disseminate beyond the respiratory system, and more frequently fatal.

Histoplasma capsulatum is found throughout the Americas, Africa, and Asia. It is endemic to the Ohio and Mississippi River Valleys in the United States, as well as in regions of Mexico, Venezuela, Brazil, Ecuador, Paraguay, Argentina, and Uruguay. In Asia, it is endemic to parts of China, India, Thailand, and South Korea. Information is more limited from Africa but cases have been reported from South Africa, Zimbabwe, Uganda, and Tanzania.⁵³ In immunocompetent hosts, histoplasmosis is typically a mild self-limited respiratory illness characterized by fevers, chills, headache, myalgias, non-productive cough, and chest pain that resolves over weeks. Immunocompromised patients, including HIV-infected patients with CD4⁺ T_H cell counts less than 150 cells/ μ L, are at risk for disseminated histoplasmosis.^{54–57} In addition to cough and dyspnea, disseminated disease presents with constitutional symptoms including fever and weight loss, as well as evidence of other organ involvement including lymphadenopathy, hepatosplenomegaly, skin lesions, meningitis, and infiltration of bone marrow. The tempo of illness can vary from indolent to fulminant. Patterns on chest radiography associated with histoplasmosis include a diffuse interstitial pattern or a military nodular pattern (Fig. 4). Less common but also compatible are focal alveolar opacities or a normal chest radiograph. The *Histoplasma* antigen test can be very helpful for diagnosis; in HIV-infected patients with disseminated disease, the sensitivity of the urine *Histoplasma* antigen test approaches 100%, although the test may also be positive in some patients with other endemic mycoses including blastomycosis, coccidioidomycosis, paracoccidioidomycosis, and penicilliosis (talaromycosis).⁵⁸ Antigen testing in BAL fluid can be diagnostic, especially for relatively immunocompetent patients with isolated pulmonary disease who may not have antigenuria or antigenemia.⁵⁹ In disseminated disease, fungal cultures are frequently positive from blood, bone marrow, lymph node, and skin. Preferred treatment for disseminated histoplasmosis is IV liposomal amphotericin B for at least two weeks or until evidence of clinical improvement, followed by oral itraconazole for at least 12 months.³⁵ Immunocompetent patients with mild pulmonary disease can be treated with itraconazole for at least 12 weeks.⁶⁰ Serial *Histoplasma* urine or serum antigen levels can be used to monitor therapeutic response. Primary prophylaxis for histoplasmosis is not recommended except for patients with CD4⁺ T_H cell counts less than 150 cells/ μ L and who live in an area with hyperendemic rates of histoplasmosis (greater than 10 cases/100 patient-years).³⁵

Coccidioidomycosis is caused by two species of *Coccidioides*, *C. immitis* and *C. posadasii*. They are endemic to semiarid regions of North and South America, including parts of California, Arizona, New Mexico, Texas, Mexico, and Argentina. In immunocompetent hosts, including HIV-infected patients with CD4⁺ T_H cell counts greater than 250 cells/ μ L, the spectrum of disease ranges from asymptomatic exposure to an influenza-like illness characterized by fever, cough, fatigue, headache, and myalgia (colloquially called “valley fever”) to frank pneumonia. In immunocompromised hosts, including HIV-infected patients with CD4⁺ T_H cell counts less than 150 cells/ μ L, *Coccidioides* spp. can disseminate causing meningitis, lymphadenitis, hepatitis, and skin lesions.^{61,62} Disseminated disease frequently presents with systemic symptoms including night sweats and weight loss. Radiographic findings include diffuse nodular opacities, focal consolidation, solitary pulmonary nodules, and cavitory lesions (Fig. 5). Definitive diagnosis is established by culture from infected tissues or cyto- or histo-pathologic identification of pathognomonic giant spherules in

sputum, BAL fluid, or biopsy specimens. Serologic tests are useful adjunctive tests. Detection of *Coccidioides*-specific antibodies by complement fixation, enzyme immunoassay, or immunodiffusion can support a diagnosis of coccidioidomycosis and can also be used to monitor response to treatment. Preferred treatment for severe or disseminated coccidioidomycosis is amphotericin B.³⁵ When clinical improvement is noted, switching from amphotericin B to fluconazole or itraconazole for a minimum of another 12 months is appropriate.⁶⁰ HIV-infected patients who have recovered from coccidioidomycosis can be considered for secondary prophylaxis with fluconazole or itraconazole if CD4⁺ T_H cell counts remain less than 250 cells/ μ L. Current guidelines do not support primary prophylaxis of coccidioidomycosis regardless of CD4⁺ T_H count. However, annual screening for *Coccidioides* exposure with an antibody test is recommended for patients with a CD4⁺ T_H count less than 250 cells/ μ L and who live in an endemic region. Coccidioidal seroconversion is treated with daily oral fluconazole.³⁵

Blastomyces dermatitidis is found primarily in North America along the Ohio, Mississippi, and St. Lawrence Rivers. Blastomycosis is less common than either histoplasmosis or coccidioidomycosis. In immunocompetent hosts, the manifestations of blastomycosis range from asymptomatic infection to pneumonia to disseminated disease affecting the skin, bone, genitourinary tract, and central nervous system. The frequency of severe or disseminated disease is higher in immunocompromised hosts, including HIV-infected patients with CD4⁺ T_H cell counts less than 200 cells/ μ L.⁶³ Radiographic findings include diffuse interstitial opacities, a military nodular pattern, focal or diffuse airspace consolidation, solitary or multiple pulmonary nodules, mass lesions, or cavitary lesions.⁶⁴ Definitive diagnosis is established by culture of infected tissues or respiratory samples, including BAL fluid. In the absence of a positive culture, histo- or cyto-pathologic identification of *Blastomyces* yeast forms can support a diagnosis of blastomycosis. For severe life-threatening disease, amphotericin B is the preferred treatment until there is evidence of clinical improvement, followed by itraconazole for 6 to 12 months. For mild to moderate severity disease, initial treatment with itraconazole is recommended for a duration of 6 to 12 months.⁶⁰ Secondary prophylaxis with itraconazole is recommended for HIV-infected patients with CD4⁺ T_H cell counts that remain less than 200 cells/ μ L. Current guidelines do not support primary prophylaxis for blastomycosis regardless of CD4⁺ T_H cell counts.⁶⁰

Paracoccidioides brasiliensis is found throughout much of South and Central America, but it is most common in parts of Brazil, Colombia, and Venezuela. The great majority of infections are asymptomatic. Symptomatic disease is expected to manifest in 1% to 2% of infected persons. There are two patterns of disease manifestation. Acute or juvenile paracoccidioidomycosis occurs exclusively in children and young adults less than 30 years of age, and is characterized by fever, weight loss, lymphadenopathy, hepatosplenomegaly, and cytopenias as a result of disseminated disease within the reticuloendothelial system; the illness evolves and progresses over weeks to months. Chronic or reactivation paracoccidioidomycosis develops more slowly, over months, and can involve the lungs, mucosa, skin, lymph nodes, adrenal glands, bones, and central nervous system.⁶⁵ In HIV-infected patients, paracoccidioidomycosis tends to be disseminated, more severe, and more rapidly progressive.^{66–69} Chest radiograph findings vary and can include diffuse bilateral reticular opacities, nodular opacities, airspace consolidation, cavitation, mediastinal

adenopathy, and pleural effusion.^{69,70} Definitive diagnosis is typically established by identification of *Paracoccidioides* yeast forms on microscopy of clinical specimens, including sputum, BAL fluid, pleural effusion, lymph node aspirate, or tissue biopsy.⁶⁷ Culture of the fungus is possible but can take several weeks so is clinically less useful. Detection of specific serum antibodies by immunodiffusion is also diagnostic and reported sensitivity is 90%.⁷¹ For severe life-threatening disease, amphotericin B is the preferred treatment until there is evidence of clinical improvement, followed by itraconazole for 6 to 12 months. For mild to moderate disease, initial treatment with itraconazole is recommended for 6 to 12 months.⁶⁰ There are no specific recommendations for primary prophylaxis against *Paracoccidioides* in HIV-infected patients although PCP prophylaxis with trimethoprim-sulfamethoxazole may confer some protection as *Paracoccidioides* is susceptible to sulfonamides.³⁵

The causative agent for penicilliosis, previously known as *Penicillium marneffeii*, was determined to be substantially genetically different from other members of the *Penicillium* genus and so was renamed *Talaromyces marneffeii* in 2011.⁷² It is endemic to parts of Asia including Vietnam, Thailand, Cambodia, Laos, Malaysia, Myanmar, Singapore, India, China, Hong Kong, and Taiwan.^{73–76} Although penicilliosis can affect immunocompetent patients, it is predominantly an opportunistic infection and symptoms are attributable to disseminated infection.⁷⁷ Clinical manifestations of penicilliosis are myriad and include cough, fever, dyspnea, chest pain, lymphadenopathy, anemia, hepatosplenomegaly, abdominal pain, diarrhea, skin and mucosal lesions, arthritis, and osteomyelitis.⁷⁶ Chest radiographic findings can mimic those of PCP, and include interstitial opacities, airspace consolidation, pleural effusion, and cavitory lesions.⁷⁷ Definitive diagnosis is made by culture from blood or BAL, skin biopsy, bone marrow biopsy, or lymph node aspirate or biopsy. Presumptive diagnosis can be made by microscopic examination of clinical specimens, including BAL fluid. The preferred treatment is liposomal amphotericin B for at least two weeks until clinical improvement, followed by oral itraconazole for 10 weeks.⁷⁸ For HIV-infected patients, it is reasonable to provide secondary prophylaxis with itraconazole for at least an additional 6 months and until CD4⁺ T_H cell counts increase to greater than 100 cells/ μ L.⁷⁹ Primary prophylaxis is indicated for HIV-infected patients with a CD4⁺ T_H count less than 100 cells/ μ L and who reside or travel to endemic regions.³⁵

At least four species of *Emmonsia* are known to be pathogenic in humans. Three species are named: *E. parva*, *E. crescens*, and *E. pasteuriana*. *E. parva* and *E. crescens* cause adiaspiromycosis, a pulmonary infection which is common in rodents but has been known to affect immunocompetent humans as well. A striking feature of adiaspiromycosis is the identification of giant conidia, or adiaspores, on microscopy, which neither replicate nor disseminate but provoke a granulomatous response from the host. *E. pasteuriana* does not cause adiaspiromycosis but, in case reports from Italy, Spain, China, and India, is described to cause disseminated fungal disease in patients with cell-mediated immunodeficiency from HIV infection, medical immunosuppression, or both.^{80–85} In 2013, a new species of an as yet unnamed *Emmonsia* species of fungus was described in HIV-infected patients in South Africa.⁸⁶ In a case series of 54 patients, 51 were HIV-infected, one was medically immunosuppressed following renal transplantation, and two had no apparent cause for immunodeficiency.⁸⁷ Genetically, the novel pathogen is more similar to *E. pasteuriana* and,

unlike *E. parva* and *E. crescens*, it does not create adiaspores. For HIV-infected patients in this case series, the median CD4⁺ T_H count was 16 cells/μL; in 12 of the 51 HIV-infected patients, symptomatic disease was likely provoked by immune reconstitution after initiation of ART. Overall, 88% of the patients had lower respiratory disease as evidenced by chest radiograph abnormalities including diffuse or focal opacities, lobar atelectasis, hilar adenopathy, or an intrathoracic mass. Ninety-six percent of patients had cutaneous lesions, ranging from papules, plaques, nodules, and ulcers, mimicking Kaposi's sarcoma, varicella, cutaneous tuberculosis, or syphilis. Other clinical features included fever, weight loss, night sweats, and lymphadenopathy. Given the frequency of skin involvement, the most common diagnostic procedure was skin biopsy which revealed yeast on histologic exam in 92% and was culture positive in 72%. Organisms were also identified in respiratory tissue, bone marrow, brain tissue, liver tissue, and blood. In total, 48% of patients died, half of them before diagnosis was established. Most patients were treated with amphotericin B followed by maintenance triazole therapy. However, much remains unknown about this new pathogen, including whether it causes asymptomatic and self-limited infection in immunocompetent hosts and its true geographic range. The final species name for this pathogen remains to be determined.

V. Summary

Many fungi cause pulmonary disease in HIV-infected patients. Major pathogens include *Pneumocystis jirovecii*, *Cryptococcus neoformans*, *Aspergillus species*, *Histoplasma capsulatum*, *Coccidioides species*, *Blastomyces dermatitidis*, *Paracoccidioides brasiliensis*, *Talaromyces marneffeii*, and *Emmonsia species*. Because symptoms are frequently non-specific, a high index of suspicion for fungal infection is required for diagnosis. Clinical manifestations of fungal infection in HIV-infected patients frequently depend on the degree of immunosuppression and the CD4⁺ T_H cell count. Establishing definitive diagnosis is important because treatments differ. Primary and secondary prophylaxis depends on CD4⁺ T_H cell counts as well as geographic location and local prevalence of disease.

References

1. Gottlieb MS, Schanker HM, Fan PT, Saxon A, Weisman JD. *Pneumocystis pneumonia*--Los Angeles. MMWR Morb Mortal Wkly Rep. 1981; 30(21):250–252.
2. Romani L. Immunity to fungal infections. Nat Rev Immunol. 2011; 11(4):275–288. [PubMed: 21394104]
3. Schroder K, Hertzog PJ, Ravasi T, Hume DA. Interferon-gamma: an overview of signals, mechanisms and functions. J Leukoc Biol. 2004; 75(2):163–189. [PubMed: 14525967]
4. Huson AM, Hoogendijk AJ, De Vos AF, Grobusch MP, Van Der Poll T. The impact of HIV infection on blood leukocyte responsiveness to bacterial stimulation in asymptomatic patients and patients with bloodstream infection. J Int AIDS Soc. 2016; 19(1):20759.
5. Koziel H, Eichbaum Q, Kruskal BA, et al. Reduced binding and phagocytosis of *Pneumocystis carinii* by alveolar macrophages from persons infected with HIV-1 correlates with mannose receptor downregulation. J Clin Invest. 1998; 102(7):1332–1344. [PubMed: 9769325]
6. Nielsen H, Kharazami A, Faber V. Blood monocyte and neutrophil functions in the acquired immune deficiency syndrome. Scand J Immunol. 2006; 24(3):291–296.
7. Murphy PM, Clifford Lane H, Fauci AS, Gallin JI. Impairment of neutrophil bactericidal capacity in patients with AIDS. J Infect Dis. 1988; 158(3):627–629.

8. Moir S, Fauci AS. B cells in HIV infection and disease. *Nat Rev Immunol.* 2009; 9(4):235–245. [PubMed: 19319142]
9. Djawe K, Buchacz K, Hsu L, et al. Mortality risk after AIDS-defining opportunistic illness among HIV-Infected persons—San Francisco, 1981–2012. *J Infect Dis.* 2015; 212(9):1366–1375. [PubMed: 26044289]
10. Bartlett MS, Vermund SH, Jacobs R, et al. Detection of *Pneumocystis carinii* DNA in air samples: likely environmental risk to susceptible persons. *J Clin Microbiol.* 1997; 35(10):2511–2513. [PubMed: 9316898]
11. Skalski JH, Kottom TJ, Limper AH, et al. Pathobiology of *Pneumocystis* pneumonia: life cycle, cell wall and cell signal transduction. *FEMS Yeast Res.* 2015; 15(6):1.
12. Gigliotti F, Wright TW. *Pneumocystis*: where does it live? *PLOS Pathog.* 2012; 8(11):e1003025. [PubMed: 23209406]
13. Vargas SL, Hughes WT, Santolaya ME, et al. Search for primary infection by *Pneumocystis carinii* in a cohort of normal, healthy infants. *Clin Infect Dis.* 2001; 32(6):855–861. [PubMed: 11247708]
14. Wakefield AE, Stewart TJ, Moxon ER, Marsh K, Hopkin JM. Infection with *Pneumocystis carinii* is prevalent in healthy Gambian children. *Trans R Soc Trop Med Hyg.* 1990; 84(6):800–802. [PubMed: 2096511]
15. Respaldiza N, Medrano FJ, Medrano AC, et al. High seroprevalence of *Pneumocystis* infection in Spanish children. *Clin Microbiol Infect.* 2004; 10(11):1029–1031. [PubMed: 15522012]
16. Morris A, Norris KA. Colonization by *Pneumocystis jirovecii* and its role in disease. *Clin Microbiol Rev.* 2012; 25(2):297–317. [PubMed: 22491773]
17. Morris A, Sciarba FC, Lebedeva IP, et al. Association of chronic obstructive pulmonary disease severity and *Pneumocystis* colonization. *Am J Respir Crit Care Med.* 2004; 170(4):408–413. [PubMed: 15117741]
18. Walzer PD, Evans HER, Copas AJ, Edwards SG, Grant AD, Miller RF. Early predictors of mortality from *Pneumocystis jirovecii* pneumonia in HIV-infected patients: 1985–2006. *Clin Infect Dis.* 2008; 46(4):625–633. [PubMed: 18190281]
19. Stansell JD, Osmond DH, Charlebois E, et al. Predictors of *Pneumocystis carinii* pneumonia in HIV-infected persons. *Am J Respir Crit Care Med.* 1997; 155(1):60–66. [PubMed: 9001290]
20. Kaplan JE, Hanson DL, Navin TR, Jones JL. Risk factors for primary *Pneumocystis carinii* pneumonia in human immunodeficiency virus-infected adolescents and adults in the United States: reassessment of indications for chemoprophylaxis. *J Infect Dis.* 1998; 178(4):1126–1132. [PubMed: 9806044]
21. Kales CP, Murren JR, Torres RA, Crocco JA. Early predictors of in-hospital mortality for *Pneumocystis carinii* pneumonia in the acquired immunodeficiency syndrome. *Arch Intern Med.* 1987; 147(8):1413–1417. [PubMed: 3115209]
22. Kovacs JA, Hiemenz JW, Macher AM, et al. *Pneumocystis carinii* pneumonia: a comparison between patients with the acquired immunodeficiency syndrome and patients with other immunodeficiencies. *Ann Intern Med.* 1984; 100(5):663–671. [PubMed: 6231873]
23. Miller RF, Huang L, Walzer PD. *Pneumocystis* pneumonia associated with human immunodeficiency virus. *Clin Chest Med.* 2013; 34(2):229–241. [PubMed: 23702173]
24. Tasaka S, Hasegawa N, Kobayashi S, et al. Serum indicators for the diagnosis of *Pneumocystis* pneumonia. *Chest.* 2007; 131(4):1173–1180. [PubMed: 17426225]
25. Quist J, Hill AR. Serum lactate dehydrogenase (LDH) in *Pneumocystis carinii* pneumonia, tuberculosis, and bacterial pneumonia. *Chest.* 1995; 108(2):415–418. [PubMed: 7634877]
26. Sax PE, Komarow L, Finkelman MA, et al. Blood (1-3)-beta-D-Glucan as a diagnostic test for HIV-related *Pneumocystis jirovecii* pneumonia. *Clin Infect Dis.* 2011; 53(2):197–202. [PubMed: 21690628]
27. DeLorenzo LJ, Huang CT, Maguire GP, Stone DJ. Roentgenographic patterns of *Pneumocystis carinii* pneumonia in 104 patients with AIDS. *Chest.* 1987; 91(3):323–327. [PubMed: 3493117]
28. Kennedy CA, Goetz MB. Atypical roentgenographic manifestations of *Pneumocystis carinii* pneumonia. *Arch Intern Med.* 1992; 152(7):1390–1398. [PubMed: 1627019]

29. Gruden JF, Huang L, Webb WR, Gamsu G, Hopewell PC, Sides DM. AIDS-related Kaposi sarcoma of the lung: radiographic findings and staging system with bronchoscopic correlation. *Radiology*. 1995; 195(2):545–552. [PubMed: 7724781]
30. Richards PJ, Riddell L, Reznick RH, Armstrong P, Pinching AJ, Parkin JM. High resolution computed tomography in HIV patients with suspected *Pneumocystis carinii* pneumonia and a normal chest radiograph. *Clin Radiol*. 1996; 51(10):689–693. [PubMed: 8893636]
31. Kovacs JA, Ng VL, NGVL, et al. Diagnosis of *Pneumocystis carinii* pneumonia: improved detection in sputum with use of monoclonal antibodies. *N Engl J Med*. 1988; 318(10):589–593.
32. Huang L, Hecht FM, Stansell JD, Montanti R, Hadley WK, Hopewell PC. Suspected *Pneumocystis carinii* pneumonia with a negative induced sputum examination: is early bronchoscopy useful? *Am J Respir Crit Care Med*. 1995; 151(6):1866–1871. [PubMed: 7767533]
33. Oren I, Finkelstein R, Hardak E, Sprecher H, Yigla M. Polymerase chain reaction-based detection of *Pneumocystis jirovecii* in bronchoalveolar lavage fluid for the diagnosis of *Pneumocystis* pneumonia. *Am J Med Sci*. 2011; 342(3):182–185. [PubMed: 21642823]
34. Alvarez-Martínez MJ, Miró JM, Valls ME, et al. Sensitivity and specificity of nested and real-time PCR for the detection of *Pneumocystis jirovecii* in clinical specimens. *Diagn Microbiol Infect Dis*. 2006; 56(2):153–160. [PubMed: 16678378]
35. Panel on Opportunistic Infections in HIV-Infected Adults and Adolescents. [Accessed on November 22, 2016] Guidelines for the prevention and treatment of opportunistic infections in HIV-infected adults and adolescents: recommendations from the Centers for Disease Control and Prevention, the National Institutes of Health, and the HIV Medicine Association of the Infectious Diseases Society of America. Available at http://aidsinfo.nih.gov/contentfiles/lvguidelines/adult_oi.pdf
36. Wharton JM, Coleman DL, Wofsy CB, et al. Trimethoprim-sulfamethoxazole or pentamidine for *Pneumocystis carinii* pneumonia in the acquired immunodeficiency syndrome: a prospective randomized trial. *Ann Intern Med*. 1986; 105(1):37–44. [PubMed: 3521428]
37. Benfield T, Atzori C, Miller RF, Helweg-Larsen J. Second-line salvage treatment of AIDS-associated *Pneumocystis jirovecii* pneumonia. *J Acquir Immune Defic Syndr*. 2008; 48(1):63–67. [PubMed: 18360286]
38. Bozzette SA, Sattler FR, Chiu J, et al. A controlled trial of early adjunctive treatment with corticosteroids for *Pneumocystis carinii* pneumonia in the acquired immunodeficiency syndrome. *N Engl J Med*. 1990; 323(21):1451–1457. [PubMed: 2233917]
39. Gagnon S, Boota AM, Fischl MA, Baier H, Kirksey OW, La Voie L. Corticosteroids as adjunctive therapy for severe *Pneumocystis carinii* pneumonia in the acquired immunodeficiency syndrome. *N Engl J Med*. 1990; 323(21):1444–1450. [PubMed: 2233916]
40. Kielstein, Hotzel, Schmalreck, Khaschabi, Glawischnig. Occurrence of *Cryptococcus* spp. in excreta of pigeons and pet birds. *Mycoses*. 2000; 43(1–2):7–15. [PubMed: 10838840]
41. Mirza SA, Phelan M, Rimland D, et al. The changing epidemiology of cryptococcosis: an update from population-based active surveillance in 2 large metropolitan areas, 1992–2000. *Clin Infect Dis*. 2003; 36(6):789–794. [PubMed: 12627365]
42. Chuck SL, Sande MA. Infections with *Cryptococcus neoformans* in the acquired immunodeficiency syndrome. *N Engl J Med*. 1989; 321(12):794–799. [PubMed: 2671735]
43. Meyohas M-C, Roux P, Bollens D, et al. Pulmonary cryptococcosis: localized and disseminated infections in 27 patients with AIDS. *Clin Infect Dis*. 1995; 21(3):628–633. [PubMed: 8527555]
44. Batungwanayo J, Taelman H, Bogaerts J, et al. Pulmonary cryptococcosis associated with HIV-1 infection in Rwanda: a retrospective study of 37 cases. *AIDS*. 1994; 8(9):1271–1276. [PubMed: 7802979]
45. Kralovic SM, Rhodes JC. Utility of routine testing of bronchoalveolar lavage fluid for cryptococcal antigen. *J Clin Microbiol*. 1998; 36(10):3088–3089. [PubMed: 9738078]
46. Malabonga VM, Basti J, Kamholz SL. Utility of bronchoscopic sampling techniques for cryptococcal disease in AIDS. *Chest*. 1991; 99(2):370–372. [PubMed: 1989797]
47. Rivera V, Gaviria M, Muñoz-Cadavid C, Cano L, Naranjo T. Validation and clinical application of a molecular method for the identification of *Cryptococcus neoformans/Cryptococcus gattii* complex DNA in human clinical specimens. *Brazilian J Infect Dis*. 2015; 19(6):563–570.

48. Skalski J, Limper A. Fungal, viral, and parasitic pneumonias associated with human immunodeficiency virus. *Semin Respir Crit Care Med.* 2016; 37(2):257–266. [PubMed: 26974302]
49. Garnacho-Montero J, Amaya-Villar R, Ortiz-Leyba C, et al. Isolation of *Aspergillus* spp. from the respiratory tract in critically ill patients: risk factors, clinical presentation and outcome. *Crit Care.* 2005; 9(3):R191–199. [PubMed: 15987390]
50. Pagano L, Caira M, Candoni A, et al. Invasive aspergillosis in patients with acute myeloid leukemia: a SEIFEM-2008 registry study. *Haematologica.* 2010; 95(4):644–650. [PubMed: 19850903]
51. Mylonakis E, Barlora TF, Flanigan T, Rich JD. Pulmonary aspergillosis and invasive disease in AIDS. *Chest.* 1998; 114(1):251–262.
52. Patterson TF, Thompson GR, Denning DW, et al. Practice guidelines for the diagnosis and management of aspergillosis: 2016 update by the Infectious Diseases Society of America. *Clin Infect Dis.* 2016; 63(4):e1–e60. [PubMed: 27365388]
53. Wheat LJ, Azar MM, Bahr NC, et al. Histoplasmosis. *Infect Dis Clin North Am.* 2016; 30(1):207–227. [PubMed: 26897068]
54. Sarosi GA, Johnson PC. Disseminated histoplasmosis in patients infected with human immunodeficiency virus. *Clin Infect Dis.* 1992; 14(S1):S60–67. [PubMed: 1562697]
55. Johnson P, Khardori N, Najjar A, Butt F, Mansell P, Sarosi G. Progressive disseminated histoplasmosis in patients with the acquired immunodeficiency syndrome. *Am J Med.* 1988; 85(2):152–158. [PubMed: 3400691]
56. Wheat LJ, Slama TG, Zeckel ML. Histoplasmosis in patients with the acquired immune deficiency syndrome. *Am J Med.* 1986; 78(2):203–210.
57. McKinsey DS, Spiegel RA, Hutwagner L, et al. Prospective study of histoplasmosis in patients infected with human immunodeficiency virus: incidence, risk factors, and pathophysiology. *Clin Infect Dis.* 1997; 24(6):1195–1203. [PubMed: 9195082]
58. Connolly PA, Durkin MM, Lemonte AM, Hackett EJ, Wheat LJ. Detection of *Histoplasma* antigen by a quantitative enzyme immunoassay. *Clin Vaccine Immunol.* 2007; 14(12):1587–1591. [PubMed: 17913863]
59. Hage CA, Davis TE, Fuller D, et al. Diagnosis of histoplasmosis by antigen detection in BAL fluid. *Chest.* 2010; 137(3):623–628. [PubMed: 19837826]
60. Limper AH, Knox KS, Sarosi GA, et al. An official American Thoracic Society statement: treatment of fungal infections in adult pulmonary and critical care patients. *Am J Respir Crit Care Med.* 2011; 183(1):96–128. [PubMed: 21193785]
61. Ampel NM, Dols CL, Galgiani JN. Coccidioidomycosis during human immunodeficiency virus infection: results of a prospective study in a coccidioidal endemic area. *Am J Med.* 1993; 94(3):235–240. [PubMed: 8095771]
62. Masannat FY, Ampel NM. Coccidioidomycosis in patients with HIV-1 infection in the era of potent antiretroviral therapy. *Clin Infect Dis.* 2010; 50(1):1–7. [PubMed: 19995218]
63. Pappas PG, Pottage JC, Powderly WG, et al. Blastomycosis in patients with the acquired immunodeficiency syndrome. *Ann Intern Med.* 1992; 116(10):847–853. [PubMed: 1567099]
64. Patel RG, Patel B, Petrini MF, Carter RR, Griffith J. Clinical presentation, radiographic findings, and diagnostic methods of pulmonary blastomycosis: a review of 100 consecutive cases. *South Med J.* 1999; 92(3):289–295. [PubMed: 10094269]
65. Queiroz-Telles F, Escuissato D. Pulmonary paracoccidioidomycosis. *Semin Respir Crit Care Med.* 2011; 32(6):764–774. [PubMed: 22167404]
66. Sarti ECFB, de Oliveira SM, dos VL, dos Santos LF, de Camargo ZP, Paniago AMM. Paracoccidioidal infection in HIV patients at an endemic area of paracoccidioidomycosis in Brazil. *Mycopathologia.* 2012; 173:145–149.
67. Paniago AMM, de Freitas ACC, Aguiar ESA, et al. Paracoccidioidomycosis in patients with human immunodeficiency virus: review of 12 cases observed in an endemic region in Brazil. *J Infect.* 2005; 51(3):248–252. [PubMed: 16230222]

68. Silva-Vergara ML, Teixeira AC, Curi VGM, et al. Paracoccidioidomycosis associated with human immunodeficiency virus infection: report of 10 cases. *Med Mycol.* 2003; 41(3):259–263. [PubMed: 12964719]
69. Morejón KML, Machado AA, Martínez R. Paracoccidioidomycosis in patients infected with and not infected with human immunodeficiency virus: a case-control study. *Am J Trop Med Hyg.* 2009; 80(3):359–366. [PubMed: 19270282]
70. Marchiori E, Gasparetto EL, Escuissato DL, Souza AS, Barreto MM. Pulmonary paracoccidioidomycosis and AIDS: high-resolution CT findings in five patients. *J Comput Assist Tomogr.* 31(4):605–607. [PubMed: 17882041]
71. Moreto TC, Marques MEA, de Oliveira MLSC, Moris DV, de Carvalho LR, Mendes RP. Accuracy of routine diagnostic tests used in paracoccidioidomycosis patients at a university hospital. *Trans R Soc Trop Med Hyg.* 2011; 105(8):473–478. [PubMed: 21684567]
72. Samson RA, Yilmaz N, Houbraken J, et al. Phylogeny and nomenclature of the genus *Talaromyces* and taxa accommodated in *Penicillium* subgenus *Biverticillium*. *Stud Mycol.* 2011; 70(1):159–183. [PubMed: 22308048]
73. Vanittanakom N, Cooper CR, Fisher MC, Sirisanthana T. *Penicillium marneffeii* infection and recent advances in the epidemiology and molecular biology aspects. *Clin Microbiol Rev.* 2006; 19(1):95–110. [PubMed: 16418525]
74. Sirisanthana T, Supparatpinyo K. Epidemiology and management of penicilliosis in human immunodeficiency virus-infected patients. *Int J Infect Dis.* 1998; 3(1):48–53. [PubMed: 9831676]
75. Supparatpinyo K, Khamwan C, Baosoung V, Sirisanthana T, Nelson K. Disseminated *Penicillium marneffeii* infection in Southeast Asia. *Lancet.* 1994; 344(8915):110–113. [PubMed: 7912350]
76. Duong TA. Infection due to *Penicillium marneffeii*, an emerging pathogen: review of 155 reported cases. *Clin Infect Dis.* 1996; 23(1):125–130. [PubMed: 8816141]
77. Kawila R, Chaiwarith R, Supparatpinyo K. Clinical and laboratory characteristics of penicilliosis marneffeii among patients with and without HIV infection in Northern Thailand: a retrospective study. *BMC Infect Dis.* 2013; 13:464. [PubMed: 24094273]
78. Sirisanthana T, Supparatpinyo K, Perriens J, Nelson KE. Amphotericin B and itraconazole for treatment of disseminated *Penicillium marneffeii* infection in human immunodeficiency virus-infected patients. *Clin Infect Dis.* 1998; 26(5):1107–1110. [PubMed: 9597237]
79. Chaiwarith R, Charoenyos N, Sirisanthana T, Supparatpinyo K. Discontinuation of secondary prophylaxis against penicilliosis marneffeii in AIDS patients after HAART. *AIDS.* 2007; 21(3):365–367.
80. Gori S, Drouhet E, Gueho E, et al. Cutaneous disseminated mycosis in a patient with AIDS due to a new dimorphic fungus. *J Mycol Med.* 1998; 8(2):57–63.
81. Tang XH, Zhou H, Zhang XQ, et al. Cutaneous disseminated emmonsiosis due to *Emmonsia pasteuriana* in a patient with cytomegalovirus enteritis. *JAMA Dermatology.* 2015; 151(11):1263–1264. [PubMed: 26200259]
82. Feng P, Yin S, Zhu G, et al. Disseminated infection caused by *Emmonsia pasteuriana* in a renal transplant recipient. *J Dermatol.* 2015; 42(12):1179–1182. [PubMed: 26105618]
83. Pelegrín I, Ayats J, Xiol X, et al. Disseminated adiaspiromycosis: case report of a liver transplant patient with human immunodeficiency infection, and literature review. *Transpl Infect Dis.* 2011; 13(5):507–514. [PubMed: 21323828]
84. Pelegrín I, Alastruey-Izquierdo A, Ayats J, Cuenca-Estrella M, Cabellos C. A second look at *Emmonsia* infection can make the difference. *Transpl Infect Dis.* 2014; 16(3):519–520. [PubMed: 24796631]
85. Malik R, Capoor MR, Vanidassane I, et al. Disseminated *Emmonsia pasteuriana* infection in India: a case report and a review. *Mycoses.* 2016; 59(2):127–132. [PubMed: 26647904]
86. Kenyon C, Bonorchis K, Corcoran C, et al. A dimorphic fungus causing disseminated infection in South Africa. *N Engl J Med.* 2013; 369(15):1416–1424. [PubMed: 24106934]
87. Schwartz IS, Govender NP, Corcoran C, et al. Clinical characteristics, diagnosis, management, and outcomes of disseminated emmonsiosis: a retrospective case series. *Clin Infect Dis.* 2015; 61(6):1004–1012. [PubMed: 26060283]

KEY POINTS

1. Among HIV-infected patients, major fungal pathogens include *Pneumocystis jirovecii*, *Cryptococcus neoformans*, *Aspergillus* species, *Histoplasma capsulatum*, *Coccidioides* species, *Blastomyces dermatitidis*, *Paracoccidioides brasiliensis*, *Talaromyces marneffeii*, and *Emmonsia* species.
2. Clinical manifestations of fungal infection in HIV-infected patients frequently depend on the degree of immunosuppression and the CD4⁺ T_H cell count.
3. Establishing definitive diagnosis is important because treatments differ.
4. Primary and secondary prophylaxis depends on CD4⁺ T_H cell counts as well as geographic location and local prevalence of disease.

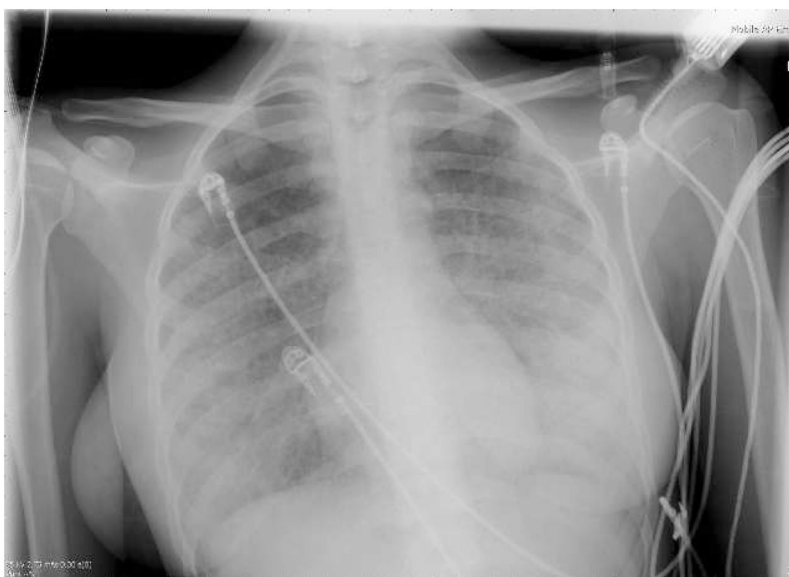


Figure 1. Chest radiograph of a patient with newly-diagnosed HIV infection presenting with severe PCP. There is diffuse bilateral interstitial shadowing, more marked on the left. Courtesy of Robert F. Miller, MBBS CBiol FRSB FRCP; used with permission.

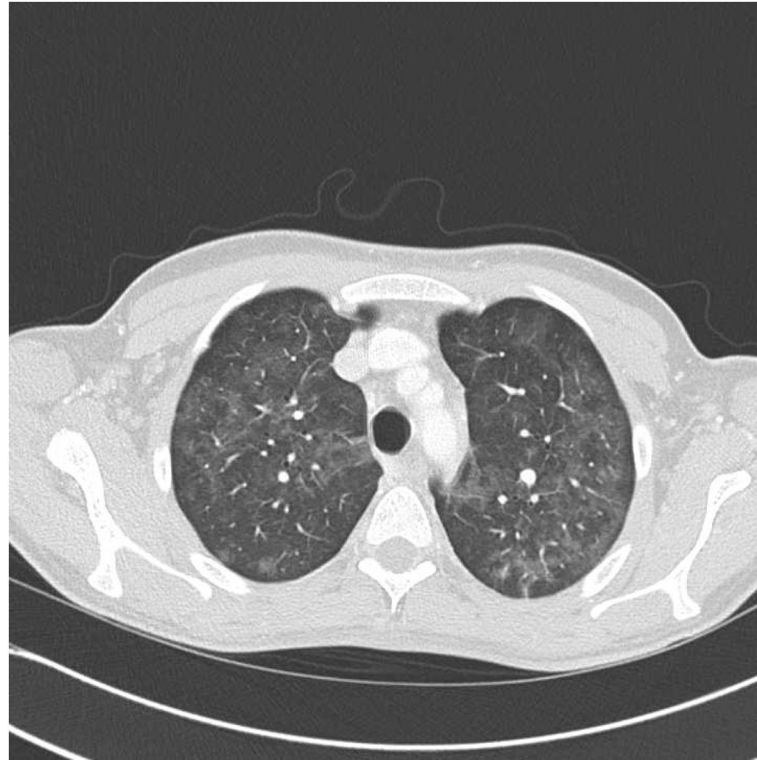


Figure 2. Axial HRCT of the upper chest of an HIV-infected patient with PCP. There are bilateral patchy “ground glass” infiltrates, with sub-pleural sparing.
Courtesy of Robert F. Miller, MBBS CBiol FRSB FRCP; used with permission.

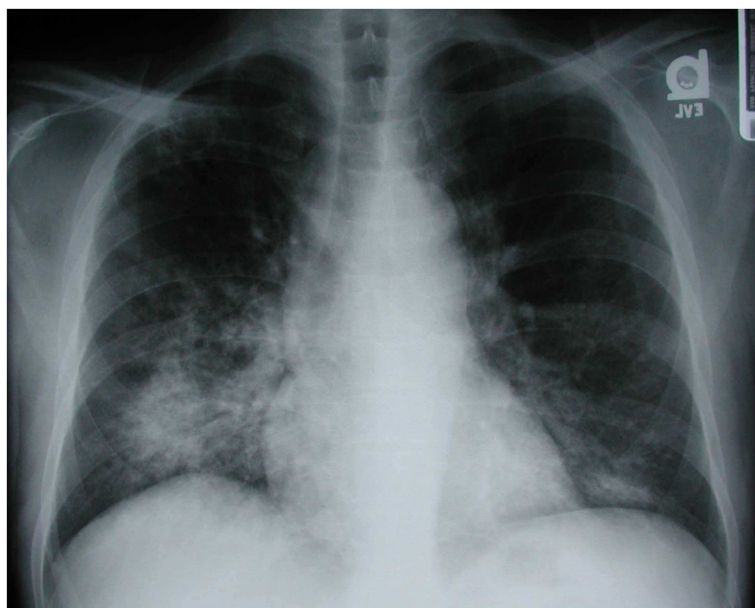


Figure 3. Chest radiograph of an HIV-infected patient with isolated cryptococcal pneumonia. There is a focal consolidation in the right lower lobe with areas of cavitation. Courtesy of Laurence Huang, MD; used with permission.

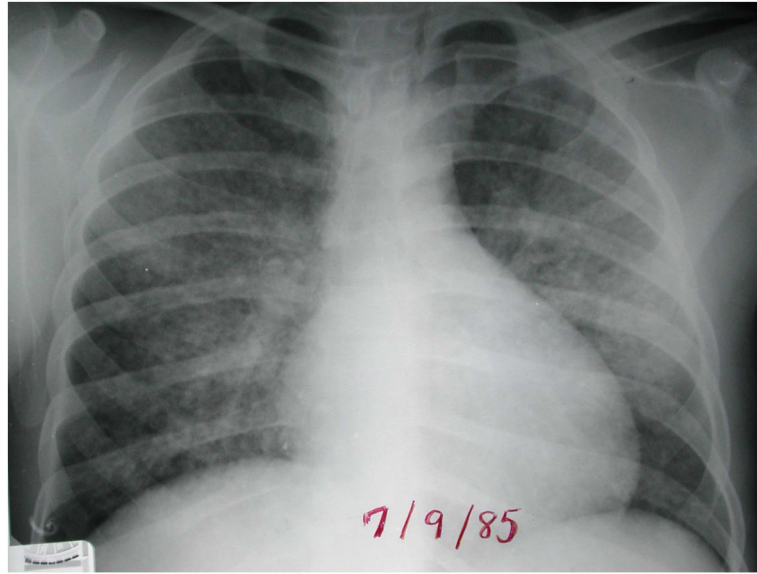


Figure 4. Chest radiograph of an HIV-infected patient with disseminated histoplasmosis demonstrating diffuse interstitial opacities. Courtesy of Laurence Huang, MD; used with permission.

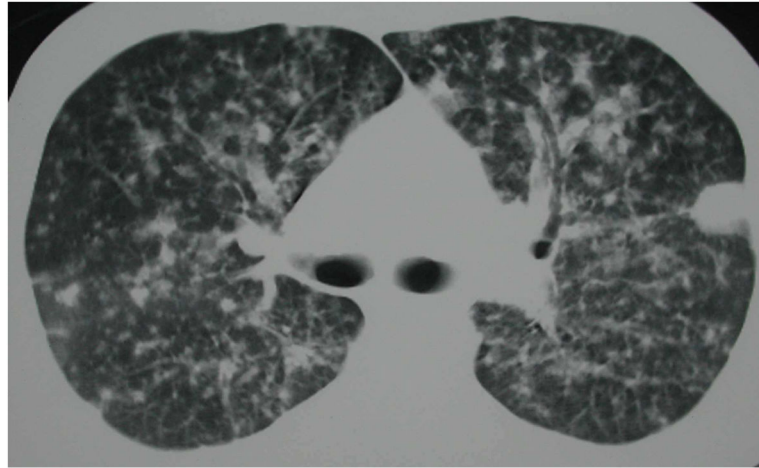


Figure 5. Axial HRCT of the chest of an HIV-infected patient with coccidioidomycosis. There are numerous nodules in a military pattern. Courtesy of Laurence Huang, MD; used with permission.