

Summer 8-30-2017

Improving the Early Identification of Acute Appendicitis Using Ultrasound in Pediatric Patients

Teresa de Jesus Sanchez Rodriguez
University of San Diego, tsanchezrodriguez@sandiego.edu

Karen Sue Hoyt
University of San Diego

Babak Khazeani
University of California, Riverside

Follow this and additional works at: <https://digital.sandiego.edu/dnp>

 Part of the [Nursing Commons](#)

Digital USD Citation

Sanchez Rodriguez, Teresa de Jesus; Hoyt, Karen Sue; and Khazeani, Babak, "Improving the Early Identification of Acute Appendicitis Using Ultrasound in Pediatric Patients" (2017). *Doctor of Nursing Practice Final Manuscripts*. 49.
<https://digital.sandiego.edu/dnp/49>

This Doctor of Nursing Practice Final Manuscript is brought to you for free and open access by the Theses and Dissertations at Digital USD. It has been accepted for inclusion in Doctor of Nursing Practice Final Manuscripts by an authorized administrator of Digital USD. For more information, please contact digital@sandiego.edu.

Approved Final Manuscript

Improving the Early Identification of Acute Appendicitis Using Ultrasound in
Pediatric Patients

Teresa de Jesus Sanchez Rodriguez MSN, RN, FNP-BC, DNP-Student

Karen Sue Hoyt, PhD, FNP-BC, ENP-C, FAEN, FAANP, FAAN

Babak Khazeani, MD, FAAEM, FACEP

Abstract

Purpose: The purpose of this evidence-based practice project was to improve early identification using ultrasound in pediatric patients who met the diagnostic criteria for acute appendicitis in the emergency department.

Background: One of the most common diagnoses of pediatric patients seen in the emergency department with an abdominal complaint is an acute appendicitis (Mostbeck et al., 2016).

Methodology: A quality improvement program in an emergency department was led by a nurse practitioner. Retrospective baseline data was collected for 12 months and 8 weeks post intervention.

Results: An increased utilization of ultrasound by 18.2% and a decrease utilization of computed tomography (CT) by 32.56% were noted.

Conclusions: This project demonstrated improved early identification of acute appendicitis via ultrasound while reducing the use of ionizing radiation of CTs. Barriers identified were the initial attitudes and beliefs about the use of ultrasound vs. CT. The nurse practitioner will provide sustainability to this ongoing program by coordinating an instructional program to improve ultrasound technician technique.

Background

Acute appendicitis is the most common emergency surgical procedure for pediatric patients in the emergency department (Mostbeck et al., 2016). In the United States alone, annual estimates of appendectomies were over 250,000 (Agency for Healthcare Research and Quality and the Effective Health Care Program [AHRQ and EHCP], 2013). Acute appendicitis can be present at any age, however, is more predominantly seen in patients ages nine through twelve (Kharbanda & Sawaya, 2011). Acute appendicitis has a seven percent lifetime prevalence of occurring with a higher frequency seen in males than females, resulting in a 3:2 ratio (AHRQ and EHCP, 2013; Mostbeck et al., 2016). Ages four and below have a 90% risk of perforation (Kharbanda & Sawaya, 2011). Improving pediatric patient outcomes in the emergency department that present with acute abdominal pain requires: critical understanding of the sequelae of disease, history and presentation of illness, and most recent best practices in diagnostics and management of acute appendicitis in pediatric populations.

Anatomy and Clinical Presentation

Acute appendicitis is defined as an inflammatory process to the appendiceal lumen and wall thickening causing obstruction to the appendix (Hansen & Dolgin, 2016). The appendix lives off the cecum in the right lower quadrant of the abdomen where the small and large intestines meet (Mostbeck et al., 2016). Classic presentations of acute appendicitis in pediatric patients include the following: periumbilical pain that migrates to the right lower quadrant of the abdominal, nausea with or without vomiting, low-grade fever, and loss of appetite (Kharbanda & Sawaya, 2011). Variations of the appendix include: retrocecal, subcecal, post-ileal, pelvic, paracecal, pre-ileal, and other

positions of the appendix resulting in abdominal pain that presents as referred, vague, and poorly localized by the pediatric population (Kim, 2013; Humes, & Simpson, 2006). Acute appendicitis may be challenging to the providers due to possible absence of classic symptoms and the inability to collect an accurate history of the pediatric patient and/or cooperation in examination (Choi, Ryoo, Jo, Hann, & Kim, 2016). Collection of a comprehensive history and clinical examination is key to assess differential working diagnoses. Additionally, identifying an index of suspicion with experience from a novice and expert clinician is also valuable.

On clinical examination, localized pain is elicited at McBurney's point that is approximately one third the distance along a line from the anterior superior iliac spine to the umbilicus (Mostbeck et al., 2016). Other clinical signs that may or may not be seen in acute appendicitis are the psoas test, the Rovsing's sign, and the obturator sign (Kharbanda & Sawaya, 2011). Emergency department workup for suspected acute appendicitis includes a complete blood count with differential having leukocytosis more than $10,000/\text{mm}^3$, a left shift of $> 75\%$ of neutrophilia, and radiological images (Kharbanda & Sawaya, 2011). Unfortunately, acute appendicitis with perforation is a common occurrence in the pediatric population due to a thinner appendiceal wall and less developed omentum (AHRQ and EHCP, 2013). Identification of acute appendicitis as early as possible can reduce the risk of perforation and/or necrosis. Reducing the sequelae of the disease and preventing prolonged patients' hospital stay will reduce the risk of septicemia and mortality.

There has been an ongoing debate in the last two decades about the appropriate images required to make a final diagnosis for acute appendicitis in pediatric patients.

This evidence-based project will focus on analyzing the best medical practice to improve early identification of acute appendicitis in pediatric patients ages four to seventeen in the emergency department setting.

Evidence-Based Practice PICO

In pediatric patients who meet the criteria for acute appendicitis in the emergency department, does a nurse practitioner-led evidence-based program provided to clinicians improve early identification of acute appendicitis via ultrasound utilization over eight weeks?

Nature of the Issue

Due to the nature of acute appendicitis in pediatric patients, it can be difficult to complete an accurate history and physical examination. This unfortunately affects the patients, the parents, the clinician, and the entire emergency department. The relationship of time and the urgency of diagnostic plan are critical while the progressive nature of the disease sequelae can cause harm to the pediatric patient at risk for perforation with possible necrosis, abscesses, and fistulas. Prompt diagnosis is the most important factor to prevent adverse events from occurring. Missed pediatric acute appendicitis has been documented as the second most common missed diagnosis in the emergency department that resulted in litigation with an estimate of 39% diagnostic errors (Scammell, Lansdale, Sprigg, Campbell, & Marven, 2011).

Nature of the Issue

Due to the nature of acute appendicitis in pediatric patients, it can be difficult to complete an accurate history and physical examination. This unfortunately affects the patients, the parents, the clinician, and the entire emergency department. The

relationship of time and the urgency of diagnostic plan are critical while the progressive nature of the disease sequelae can cause harm to the pediatric patient at risk for perforation with possible necrosis, abscesses, and fistulas. Prompt diagnosis is the most important factor to prevent adverse events from occurring. Missed pediatric acute appendicitis has been documented as the second most common missed diagnosis in the emergency department that resulted in litigation with an estimate of 39% diagnostic errors (Scammell, Lansdale, Sprigg, Campbell, & Marven, 2011).

Description of the Clinical Problem

National Problem

In the United States, there has been an estimate of 80,000 pediatric patients who have suffered from acute appendicitis requiring surgical interventions (Cogley, O'Connor, Houshyar, & Dulaimy, 2012). Within the last two decades, drastic increases of CT have been conducted in the emergency departments for pediatric patients with abdominal pain as a chief complaint (Cogley, O'Connor, Houshyar, & Dulaimy, 2012). Approximately nine million CTs in the United States have been done in pediatric patients alone (Cogley, O'Connor, Houshyar, & Dulaimy, 2012; National Cancer Institute at the National Institute of Health [NCI at the NIH], 2012). A recent survey conducted by the American College of Surgeons suggests that CTs are being over used in pediatric patients exhibiting classic symptoms of acute appendicitis (Drake & Flum, 2013).

The literature reports evidence of an increased concern of ionizing radiation exposure in pediatric patients with a possible risk of developing cancer. Pediatric patients have a higher risk of malignancies due to the higher life expectancy as compared to an adult when exposed to ionizing radiating at a young age (Verdun et al.,

2008; Lin, 2010). Additionally, pediatrics are three to four times more radiosensitive than adults (Verdun et al., 2008; Lin, 2010). Evidence of “radiating-induced cancer risk” has been clearly documented as a direct epidemiological result of the atomic bomb survivors in Hiroshima and Nagasaki, Japan (Lin, 2010, p. 1142). The researchers noted there might be a seven to fifty year latent period in which a malignancy may occur after radiation exposure (Bruner, Sutker, & Maxwell, 2009). On average, an adult individual receives a total of natural background radiation of three millisievert (mSv) per year (Lin, 2010). Adults are exposed to 10 mSv for a CT of the abdomen and pelvis, which takes a total of three years to accumulate (Lin, 2010). Pediatric patients vary in size; therefore, mSv are calculated by weight and body surface area (Gelfand, Parisi, & Treves, 2011).

This public health crisis has received a lot of attention causing a national movement to raise healthcare professional awareness and education of potential risk of malignancies with correlation of exposure of ionizing radiating to the pediatric population. A national campaign was started in 2006 as a committee with the Society for Pediatric Radiologic called, The Image Gently Alliance (The Image Gently Alliance, n.d.). This campaign led an innovating alliance to improve pediatric healthcare resulted in an increase support from many organizations including the following: Society for Pediatric Radiology, American College of Radiology, American Society for Radiological Technologist, the American Association of Physicists in Medicine, and many more (The Image Gently Alliance, n.d.).

Local Problem

The pediatric population in the Coachella Valley is a growing population. Managing this vulnerable population in the emergency department requires trained

clinicians and evidence-based practice treatment plans. There are three acute care hospitals that provide emergency services to this community. However, of these three hospitals in the region, only one hospital has a dedicated twelve bed medical surgical ward for pediatric patients. Critical pediatric patients are transferred out to specialized pediatric acute care facilities by air helicopter.

In this particular acute care hospital, level two-trauma center, has a total of twenty-six emergency department beds that encounters over 72,000 visits per year. A total of 15,964 pediatric patients were seen in 2016. This provides an estimate of over 1,000 pediatric patients monthly. Out of these patients, there are a total of 303 who complain of abdominal pain with an ICD-10 code documented as unspecified abdominal pain in 2016. Therefore, it is essential to identify pediatric patients with the classic clinical complaint of acute appendicitis and provide best practices in radiological imaging modalities.

Clinical Problem in the Practice Setting. The primary clinical problem in the local practice setting is the lack of use of ultrasound, as this is the primary modality in pediatric patients who present in the emergency department with classic symptoms of acute appendicitis. A needs analysis was conducted with Dr. Babak Khazeani, medical director/champion to assess and identify areas of improvement and collaboration to provide the best clinical practices in the emergency department. As a result, acute appendicitis in pediatric patients and the improvement of early identification to reduce wait time, and provide appropriate care was at the top of the list. This clinical problem is significant in the local ED due to the high risk and exposure of radiation-induced cancer risk in pediatric patients. An overuse of CTs being ordered by emergency department

clinicians for pediatric patients to rule out acute appendicitis was identified.

Evidence-based practice and potential barriers were discussed during the project due to changes in culture and clinical practice. The barriers included attitudes, behaviors, and practice changes for the clinicians in the emergency department. Additionally, certain acute care surgeons were identified as potential barriers that may influence ultrasound utilization as the primary modality in the acute appendicitis pediatric population.

Facilitators. The facilitators in this evidence-based project included many of the stakeholders including the medical director in the emergency department as the clinical champion for the project, who is dedicated to improving current practice trends and evidence-base practice. He is a dedicated educator, mentor, and emergency department medical director due to his responsibility to the current and best practices to his patients and his emergency department residency program. Involving the implementation team and the stakeholders early is key. The implementing team consisted of early adopters, who were selected from the emergency department clinicians and radiologist. In addition, during discussion between the emergency department personnel, stakeholders appeared to be very receptive and provided ideas for success in the implementation phase. Radiologists have also been supportive and agreed in ultrasound as a primary modality in acute appendicitis.

Sources of Resistance and Barriers. Multifactorial sources were identified as responsible barriers, which as a result, delayed the implementation of the project. Some emergency department clinicians discussed the inability to provide adequate ultrasounds resulting in an inconclusive test; therefore providing mistrust with this modality of

imaging. Additionally, there was an extensive debate and resistance with one of four acute care surgeons. The acute care surgeons are ultimately responsible for these pediatric patients. One particular surgeon continued to request CTs even in the presence of positive abdominal ultrasound results. The primary goal was to overcome resistance and aim for early identification of ultrasounds as a primary radiological modality for acute appendicitis pediatric patients' ages four to seventeen in the emergency department.

Evidence-Based Practice Model

The Iowa Model is a well-tested framework utilized by healthcare professionals to promote quality care and improve health care outcomes in patient populations (Titler et al., 2001). Widely used in the clinical and academic settings, the Iowa Model aims to improve quality care with team building while attempting to make a positive change in daily practice through critique and syntheses of research (Titler, 2010). The Iowa model was chosen as the framework for this evidence-based practice project because of its feasibility and applicability to the project (Titler, 2010). Each step of the model is described in detail and provides a feedback loop of how to analyze patients' outcomes (2001).

Identification of the problem is the initial step in the process of facilitating step-by-step direction to promote quality care and enrich clinical practice through evidence-based data (Titler, 2010). While collaborating with the emergency department medical director, improved early identification of acute appendicitis using ultrasound as the primary radiological modality in pediatric patients was the problem identified. The second step in the project guided by the Iowa Model, was to assess early identification

of acute appendicitis in the pediatric population as a priority for the facility (Titler et al., 2001). This priority is due to the improvement of short wait times in the emergency department. The third step was to assemble a team of stakeholders that are aligned with the values and goals of the plan while identifying tasks that fit each stakeholder (Titler et al., 2001).

A literature and research review to help build a base of evidence was the fourth step in the project using the Iowa Model framework (Titler et al., 2001). Step five involved reviewing the literature to see if there was sufficient research done on the topic once all the related articles are collected, critiqued, and synthesized (Titler et al., 2001). In this particular project, there was a good research base covering the importance of ultrasound as the primary modality of acute appendicitis in pediatric patients due to the awareness of pediatrics risk of radiation-induced malignancies.

Step six involved the initiation of a “pilot change for practice” (Titler, 2010, p. 138). Upon completion of the pilot study and evaluation of the processes outcomes, a decision must be made whether the new process is appropriate to adopt in into practice or not (Titler et al., 2001). Comfort in using the Iowa Model was felt due to the descriptions and expectations of each step including the feedback loop of how to monitor and analyze costs and patient outcomes (2001).

Evidence-Based Solutions

Searching for Evidence

A complete scholarly search was done through the University of San Diego’s Copley Library search engines including the PubMed database, CINAHL Plus, and Cochrane database. Key words searched in search text, and MeSH terms included, but

were not limited to the following: “acute appendicitis,” “pediatrics,” “last ten years,” “ultrasound,” “emergency department,” and “radiation.” Limitations on the search included studies done within the past ten years and in the English language. Articles were excluded if they focused only in adults, since pediatric patients was the focus group in this project. A total of 21,637 articles were identified and narrowed down to 550. After reviewing the 550 articles, 70 articles were selected. After reading the abstracts of the 70 articles, 18 articles met the search criteria and were related to the current evidence-based best practice in improving pediatric patients in the emergency department who have classic signs and symptoms of acute appendicitis. These last chosen articles are helpful in evaluating and promoting ultrasound as the primary modality of radiological images with pediatric patients who complain of classic symptoms of acute appendicitis.

Evidence-Based Strategies

An extensive review of the current data was conducted resulting in the evaluation of the levels of evidence. Considering that randomized control trials (RCTs) are not conducted on vulnerable populations and pediatric patients in the emergency department with emergent clinical presentations are classified as a vulnerable patient population, there was a lack of RCTs throughout the search of evidence. As a result, many articles were retrospective or prospective meta-analyses.

The first meta-analysis on pediatric patients focusing on the preferred diagnostic modality for acute appendicitis showed no statistical significance between ultrasound, CT, or MRI (Zhang, Liao, Chen, Zhu, & Byanju, 2017). Ultrasound has been the principle diagnostic modality in acute appendicitis in pediatric patients since the 1990’s,

discussed by the authors (Zhang, Liao, Chen, Zhu, & Byanju, 2017). The authors' recommended using ultrasound as a low cost and easier modality with the possibility of using CT as a complementary modality if the appendix is not visualized or not excluded (Zhang, Liao, Chen, Zhu, & Byanju, 2017).

A second meta-analysis and systemic review discussed pediatric patients with clinical presentations of acute appendicitis in the emergency department (Benabbas, Hanna, Shah, & Sinert, 2017). The authors determined that an emergency department's point-of-care ultrasound and radiology department ultrasound are equivocal (Benabbas, Hanna, Shah, & Sinert, 2017). This article concluded that the emergency department point-of-care ultrasound done by the emergency department should be sufficient to rule in acute appendicitis in pediatric populations (Benabbas, Hanna, Shah, & Sinert, 2017).

American College of Radiology (ACR) completed a diagnostic imaging performance-measure set in February 2015 with the help of the American Medical Association (AMA) in which they came together with the Physician Consortium for Performance Improvement (PCPI) and the National Committee for Quality Assurance (NCQA) to review and recommend evidence-based practice. They concluded that ultrasound in pediatric patients is the preferred method of initial diagnosis in the emergency department to reduce the ionizing radiating (ACR, AMA - PCPI, NCQA, 2015). Considered to be ranked at a Level B evidence, the authors of the article recommended ultrasounds should be used as a confirming method of acute appendicitis in children, but not to excluded acute appendicitis (ACR, AMA - PCPI, NCQA, 2015).

In 2015, JAMA published an article reviewing a total of thirty-five pediatric institutions for a total of three years (Bachur, Levy, Callahan, Rangel, & Monuteaux).

Bucher and his colleagues stated that ultrasound as the primary imaging modality to rule out acute appendicitis is the preferred method resulting in a decrease need of a CT (Bachur, Levy, Callahan, Rangel, & Monuteaux, 2015). This also resulted in an improved performance of ultrasound techniques by the technicians (Bachur, Levy, Callahan, Rangel, & Monuteaux, 2015).

Evidence shows there is no increase in complications of acute appendicitis when hospitals transition to an ultrasound-first paradigm (Le, Kurian, Cohen, Weinberg, & Scheinfeld, 2013). Use of ultrasound as the primary modality decreases the risk of cancer by decreasing ionizing radiation following the principles of the Image Gently campaign and using the as low as reasonable achievable (ALARA) approach for radiological images (Le, Kurian, Cohen, Weinberg, & Scheinfeld, 2013).

Three valid variables in the literature are ultrasound's sensitivity and specificity and cost. Ultrasounds by graded-compression has been documented as 91% sensitivity (95% CI, 89-93%) and 97% specificity (95% CI, 95-99%) (Rosen et al., 2011). Research also recognizes that ultrasound results vary from technician dependent and institutions (Mostbeck et al., 2016). The ultrasound cost ranges from \$100s to \$200s dollars as compared to CTs that range from \$800s to \$2,000s. Therefore, ultrasounds are more cost effective and provide a valid sensitivity and specificity.

Program Development and Implementation Timeline

The project plan and timeline implementation are demonstrated in Figure 1 and Figure 2. September through December 2016, the focus was on completing a needs assessment and gap analysis with the emergency department medical director/champion. A literature review by collecting evidence-based practice articles from peer-reviewed

journals was conducted using the University of San Diego’s Copley Library search engines including PubMed database. Once the articles were collected, then an approval was issued from the emergency department medical director/champion, faculty advisor, and nursing director for the nurse practitioner programs. Subsequently, a plan of action was formulated and a team including key stakeholders was identified. Institution Review Board (IRB) was then approved at the clinical site on December 5, 2016 and University of San Diego on December 7, 2017.

Figure 1. Project Plan Implementation

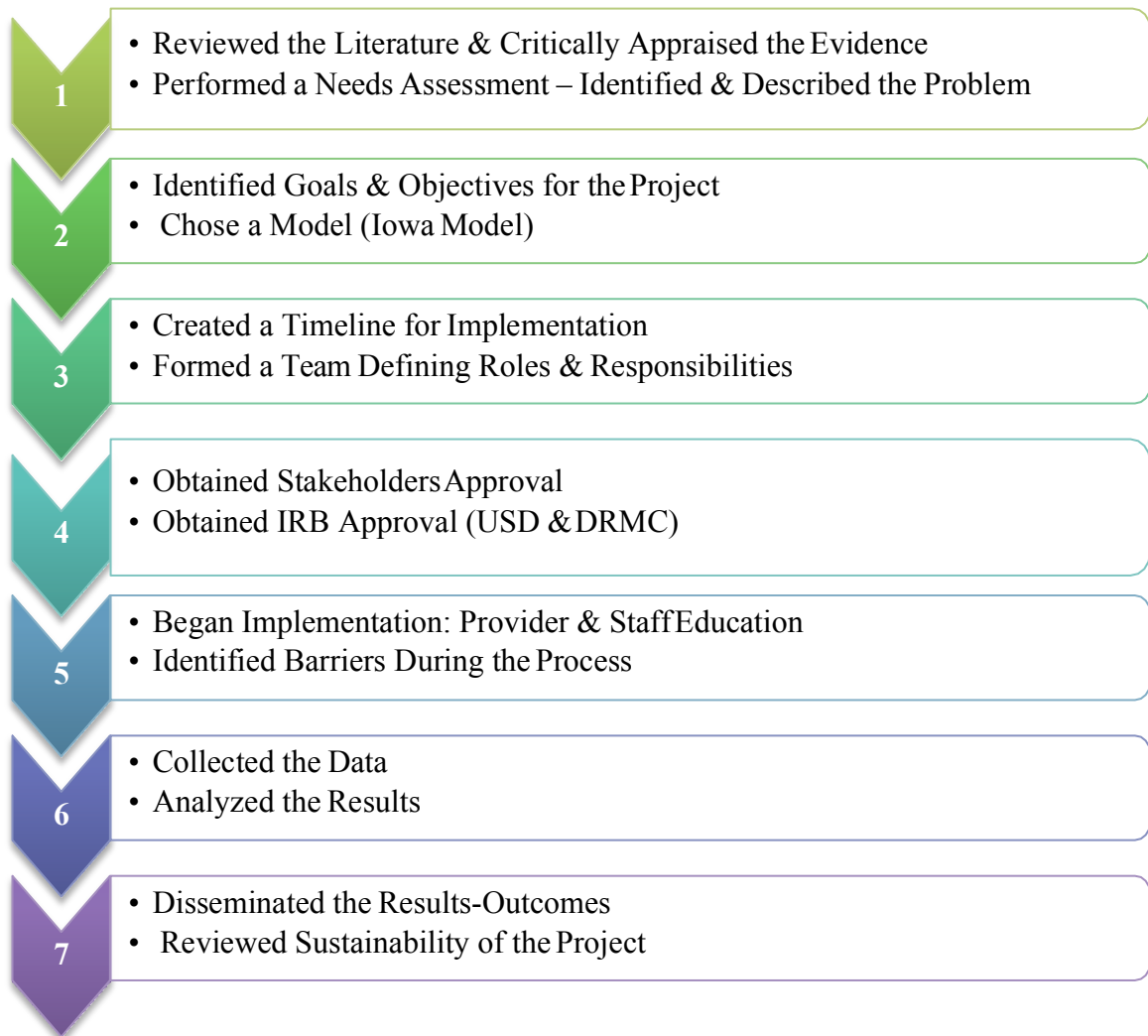
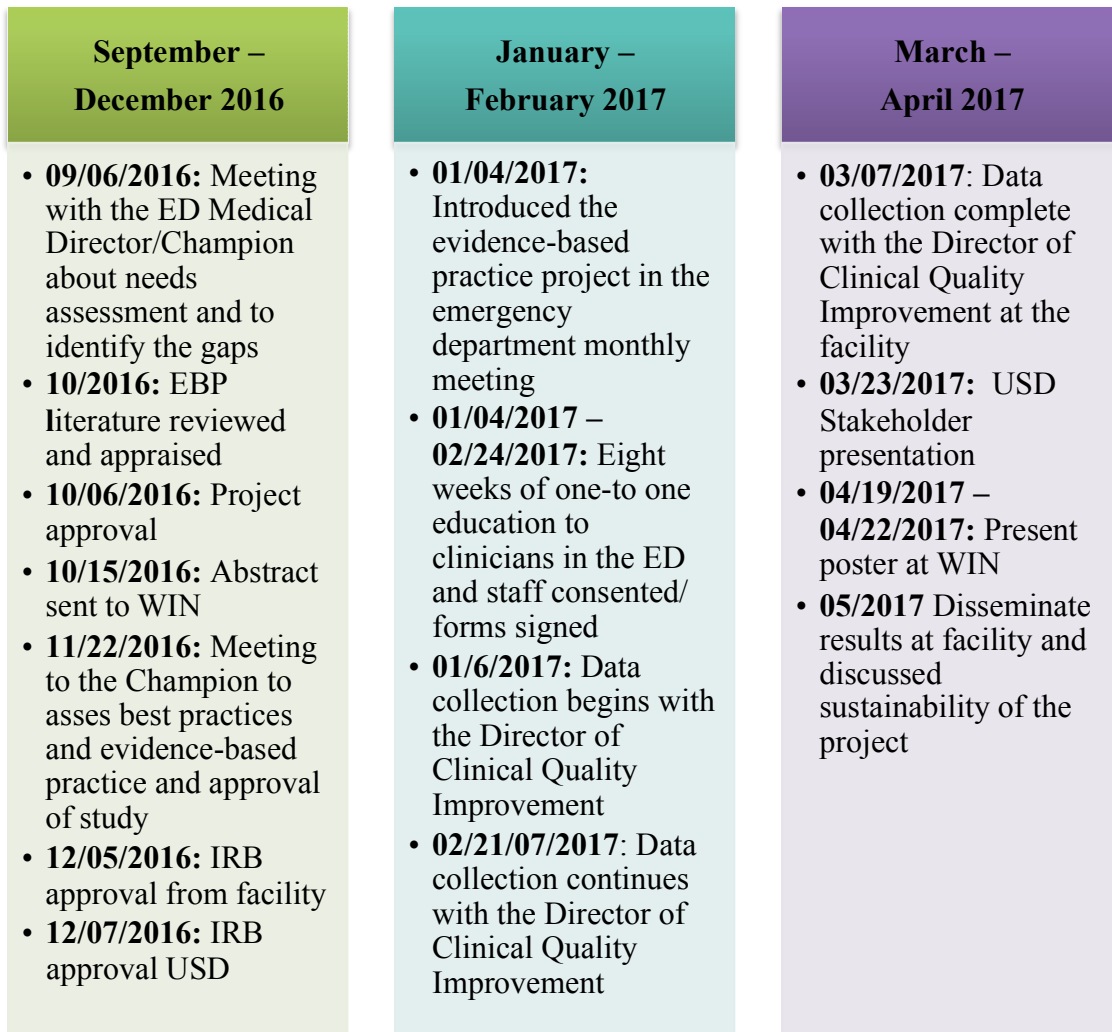


Figure 2. Timeline



In January and February 2017, the evidence-based project was introduced by the nurse practitioner in the first emergency department meetings of the year. Discussions in the meeting involved the implementation plan of the project and potential barriers to be identified. During these months, an educational discussion was held with each clinician regarding the literature and a three-page document was reviewed to improve the early identification of acute appendicitis using ultrasound in pediatric patients ages four to seventeen. Questions were answered appropriately and

written staff consent was obtained.

During the months of March through April 2017, data collection was compiled with the help of the Director of Clinical Quality Improvement at the clinical site. This information was then analyzed and drafted by the USD data consultant, Dr. Dee Cannon. The next steps in the project plan were to present to the stakeholder presentation on March 23rd, 2017 at USD, complete a poster by March 28th, 2017, present the poster at the Western Institute of Nursing Conference April 19th – 22nd, 2017, present the stakeholder presentation to the clinical champion and clinical faculty on April 25th, 2017, and finalize the manuscript before the end of April.

Project Approval

Faculty Mentor and Champion

Faculty mentor, Dr. Karen Sue Hoyt, granted approval of this project. A review of the project was discussed in great detail with Dr. Hoyt and changes were made when needed. Also, the second important approval was received by the project champion and medical director of the emergency department, Dr. Babak Khazeani. Important meetings were held with Dr. Hoyt and Dr. Khazeani who are the key players in implementing this project.

Intuitional Review Board

Applications of the two institutional review boards DRMC and the University of San Diego have been granted. Supportive documents are located in the appendix.

Results

The diagnostic modalities used to evaluate acute right lower quadrant and / or periumbilical abdominal pain in pediatric patients were assessed using baseline data from January through December 2016 and post intervention data during the first eight

weeks of the 2017. From the baseline to the post intervention data, there was a total of 18.2% increase of ultrasound utilization, a decrease of CTs by 32.56%, and an increase utilization of both ultrasound and CTs by 8.09% as seen in Table 1. Additionally, data was collected comparing diagnostic modalities from pre- and post-intervention illustrating the results of ruling in or ruling out acute appendicitis, Table 2.

Table 1. Diagnostic Modalities used to Evaluate Acute Right Lower Quadrant/Periumbilical Abdominal Pain in Pediatric Patients in the Emergency Department

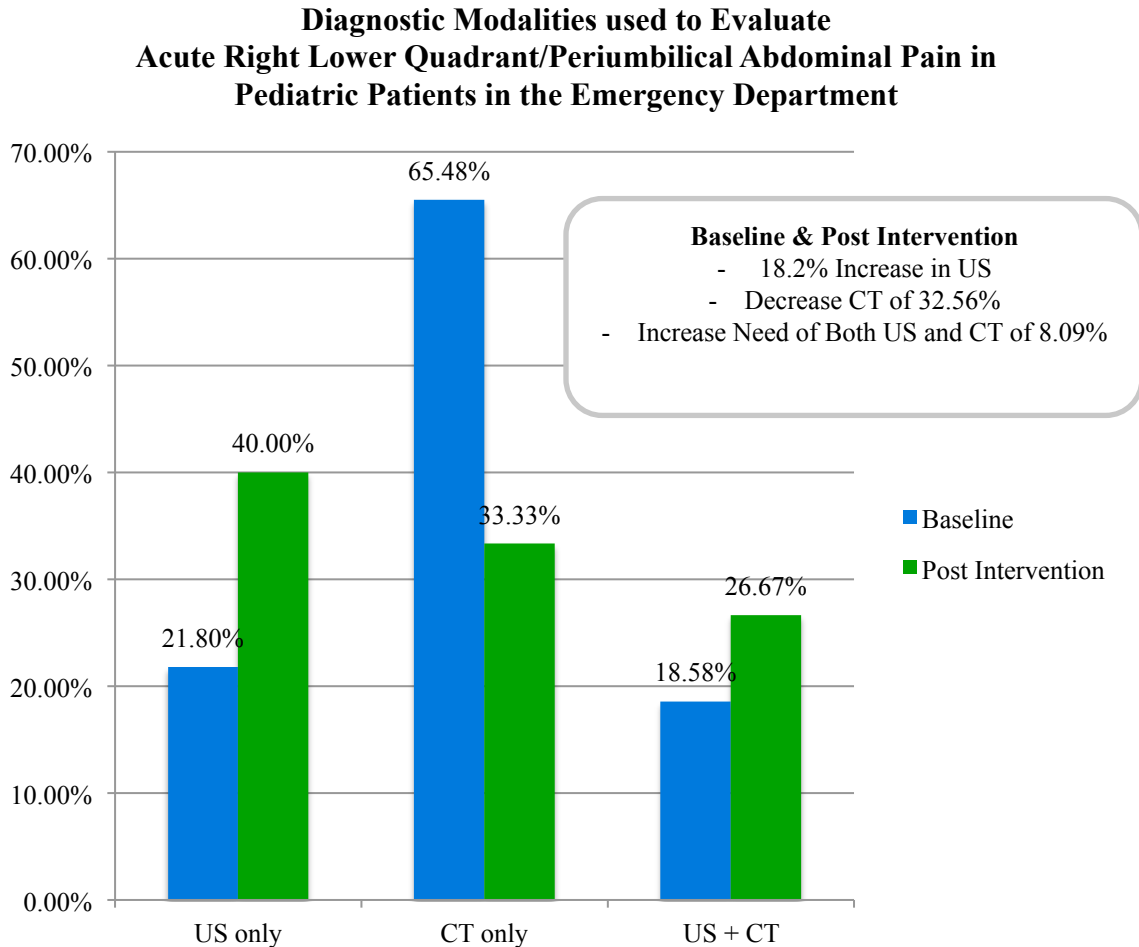
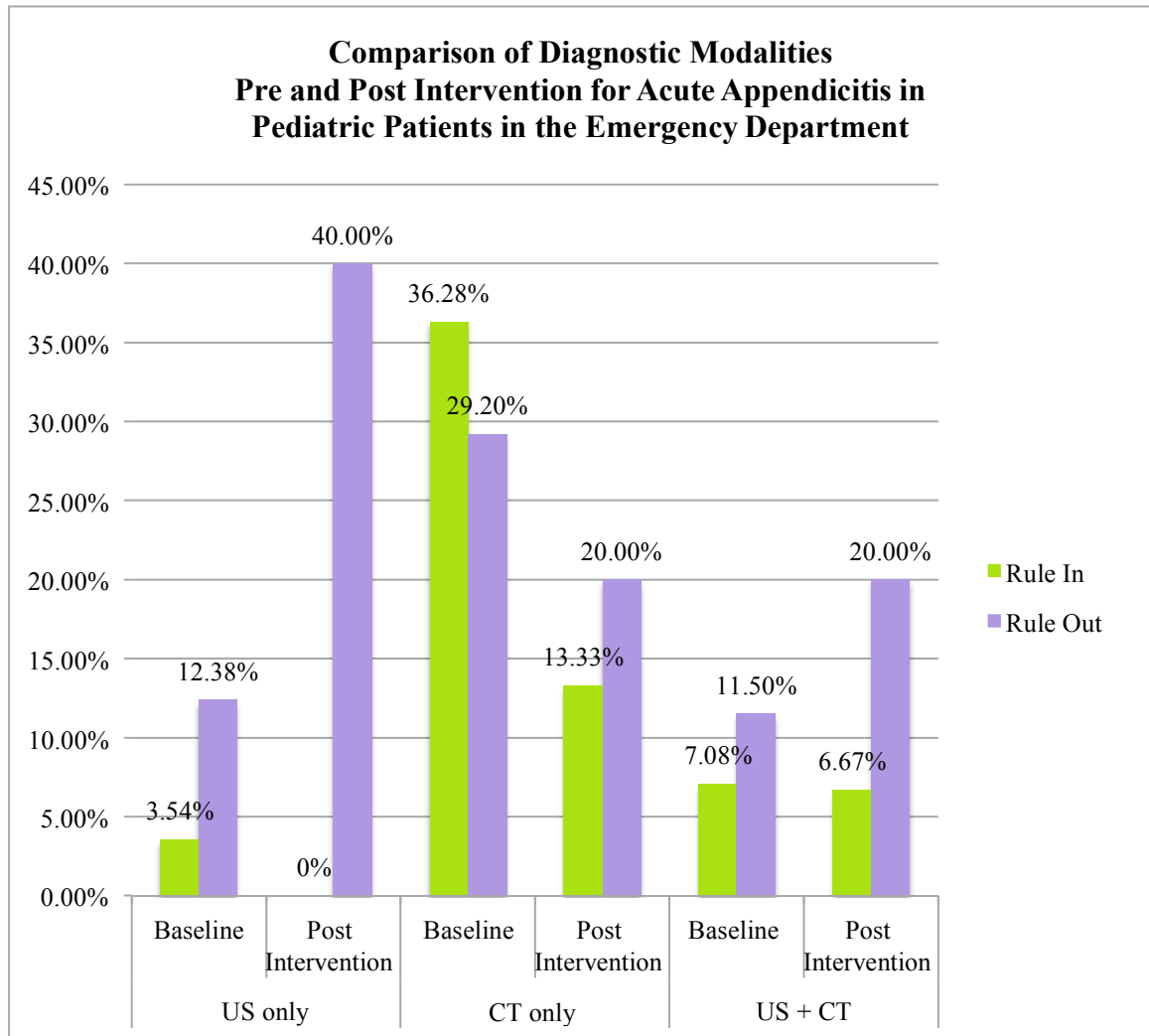


Table 2. Comparison of Diagnostic Modalities Pre and Post Intervention for Acute Appendicitis in Pediatric Patients in the Emergency Department



Implications for Nursing Practice

Project Impact

Attitudes and beliefs were also evaluated and identified as important implications of clinical practice. The overall impact was to improve pediatric care with a sustainable project that primarily benefits the pediatric patients and their parents. The project is still being conducted by focusing on improving early identification of acute

appendicitis in pediatric patients, decreasing overall wait times, decreasing radiation exposure, and improving cost-savings.

Limitations

Due to variable schedules, not all clinicians eligible for the study were included in the education and consent process of the project. Clinicians that were unable to participate in the education and consent process potentially contributed to the limited adherence to ultrasound- first implementation in acute abdominal pain for the pediatric population. Depending on the acute care surgeon, push back was given on certain occasions regarding the use of ultrasound and requested CTs. Variable clinician participation and limited duration of the study had an impact on the small sample size provided. Generalizability of the study was limited due to being conducted at a single institution with unique population demographics and facility-specific diagnostic protocols used by practicing clinicians that may differ from other facilities.

Future Recommendations

Continuing the culture of decreasing ionizing radiation and cost-effective care in pediatric patients presenting to the emergency department with acute right lower quadrant and / or periumbilical abdominal pain is critical. Ongoing education for the clinicians and radiologists to sustain this evidence-based project would also be critical for its sustainability. In addition, ongoing training and education provided to ultrasound technicians related to technique will also contribute to improve quality care and sustainability.

References

- Agency for Healthcare Research and Quality and the Effective Health Care Program. (2013). *Evidence-based practice center systematic review protocol. Practice title: Diagnosis of right lower quadrant pain (suspected acute appendicitis)*. Retrieved from <http://effectivehealthcare.ahrq.gov/index.cfm/search-for-guides-reviews-and-reports/?pageaction=displayproduct&productid=1827>
- American College of Radiology, American Medical Association - convened Physician Consortium for Performance Improvement, and National Committee for Quality Assurance. (2015). *Diagnostic Imaging Performance Measurement Set*. Retrieved from : <http://www.acr.org/~media/acr/documents/pdf/qualitysafety/quality%20measurement/performance%20measures/diagnosticimagingmeasureset2015.pdf>
- Association of American Medical Colleges. (2012). *Recent Studies and Reports on Physician Shortages in the US*. Retrieved from Center for Workforce Studies Association of American Medical Colleges: <https://www.aamc.org/download/100598/data/>
- Bachur, R. G., Levy, J. A., Callahan, M. J., Rangel, S. J., & Monuteaux, M. C. (2015, June 22). Effect of reduction in the use of computed tomography on clinical outcomes of appendicitis. *JAMA Pediatrics*, 8, 755-760. <http://dx.doi.org/10.1001/jamapediatrics.2015.0479>
- Benabbas, R., Hanna, M., Shah, J., & Sinert, R. (2017, February 18). Diagnostic accuracy of history, physical exam, laboratory tests and point-of-care-ultrasound for

pediatric acute appendicitis in the emergency department: A systematic review and meta-analysis. *Acad Emerg Med*.
<http://dx.doi.org/10.1111/acem.13181>

Beverly, C. J. (2014). Changing health care environment: Getting beyond the PhD versus DNP discussion. *Journal of Professional Nursing*, 30, 101-102.

<http://dx.doi.org/10.1016/j.profnurs.2014.02.003>

Bruner, A., Sutker, W., & Maxwell, G. (2009). Minimizing patient exposure to ionizing radiation from computed tomography scans. *Proc (Bayl Univ Med Cent)*, 22(2), 119-123. Retrieved from

<https://www.ncbi.nlm.nih.gov/pmc/articles/PMC2666855/>

Choi, J. Y., Ryoo, E., Jo, J. H., Hann, T., & Kim, S. M. (2016, August 12). Risk factors of delayed diagnosis of acute appendicitis in children: for early detection of acute appendicitis. *Korean J Pediatr*, 59(9), 368-373.

<http://dx.doi.org/10.3345/kjp.2016.59.9.368>

Cogley, J. R., O'Connor, S. C., Houshyar, R., & Dulaimy, K. A. (2012). Emergent pediatric US: What every radiologist should know. *Pediatric Imaging*, 32, 651-665. <http://dx.doi.org/10.1148/rg.323115111>

Drake, F. T., & Flum, D. R. (2013). Improvement in the diagnosis of appendicitis. *AdSurg*, 47, 299-328. Retrieved from

<https://www.ncbi.nlm.nih.gov/pmc/articles/PMC4214266/>

Gelfand, M. J., Parisi, M. T., & Treves, S. T. (2011, October 15). Pediatric radiopharmaceutical administered doses: 2010 North American consensus guidelines. *The Journal of Nuclear Medicine*, 52, 318-322.

<http://dx.doi.org/10.2967/jnumed.110.084327>

- Hansen, L. W., & Dolgin, S. E. (2016, February 2). Trends in the Diagnosis and Management of Pediatric Appendicitis. *Pediatrics in Review*, 37(2), 52-58. <http://dx.doi.org/10.1542/pir.2015-0021>.
- Humes, D. J., & Simpson, J. (2006, September 9). Clinical review: Acute appendicitis. *BMJ*, 333, 530-534. <http://dx.doi.org/10.1136/bmj.38940.664363.AE>
- Kahn, S. A., Davis, S. A., Banes, C. T., Dennis, B. M., May, A. K., & Gunter, O. D. (2015). Impact of advanced practice providers (nurse practitioners and physician assistants) on surgical residents' critical care experience. *Journal of Surgical Research*, 1-6. <http://dx.doi.org/10.1016/jss.2015.05.036>
- Kharbanda, A. B., & Sawaya, R. D. (2011). Acute abdominal pain in children. In J. E. Tintinalli, J. S. Stapczynski, O. J. Ma, D. M. Cline, R. K. Cydulka, & G. D. Meckler (Eds.), *Tintinalli's emergency medicine: A comprehensive study guide* (7th ed., pp. 839-842). New York, CA: McGraw-Hill.
- Kim, J. S. (2013, December 31). Acute abdominal pain in children. *Pediatr Gastroenterol Hepatol Nutr*, 16(4), 219-224. <http://dx.doi.org/10.5223/pghn.2013.16.4.219>
- Le, J., Kurian, J., Cohen, H. W., Weinberg, G., & Scheinfeld, M. H. (2013, December 17). Do clinical outcomes suffer during transition to an ultrasound-first paradigm for the evaluation of acute appendicitis in children? *AJR Am J Roentgenol*, 6, 1348-1352. <http://dx.doi.org/10.2214/AJR.13.10678>
- Lin, E. C. (2010). Radiation risk from medical imaging. *Mayo Clin Proc*, 85(12), 1142. <http://dx.doi.org/10.4065/mcp.2010.0260>

- Mostbeck, G., Adam, E. J., Nielsen, M. B., Claudon, M., Clevert, D., Nicolau, C., ... Owens, C. M. (2016, February). How to diagnose acute app. *Insights Imaging*, 7, 255-263. <http://dx.doi.org/10.1007/s13244-016-0469-6>
- National Cancer Institute at the National Institute of Health. (2012). Radiation risks and pediatric computed tomography: A guide for health care providers. Retrieved November 18, 2016, from <https://www.cancer.gov/about-cancer/causes-prevention/risk/radiation/pediatric-ct-scans>
- Pastores, S. M., Michael, O., Ruth, K. M., Lena, N., Nicholas, W., Heatherlee, B., ... Craig, C. M. (2011). The accreditation council for graduate medical education resident duty hour new standards: History, changes, and impact on staffing of intensive care units. *Critical Care Medicine*, 39, 2250-2549. <http://dx.doi.org/10.1097/CCM.0b013e318225776f>
- Rosen, M. P., Ding, A., Blake, M. A., Baker, M. E., Cash, B. D., Fidler, J. L., ... Katz, D. S. (2011). ACR appropriateness criteria right lower quadrant pain - Suspected appendicitis. *American College of Radiology*, 8, 749-755. <http://dx.doi.org/10.1016/j.jacr.2011.07.010>
- Scammell, S., Lansdale, N., Sprigg, A., Campbell, D., & Marven, S. (2011). Ultrasonography aids decision-making in children with abdominal pain. *Ann R Coll Surg Engl*, 93(5), 405-409. <http://dx.doi.org/10.1308/003588411X582672>
- The Image Gently Alliance. (n.d.). <http://www.imagegently.org/About-Us/The-Alliance>
- Titler, M. (2010). Chapter 6: Iowa model of evidence-based practice. In J. Rycroft-Malone & T. Bucknall (Eds.), *Models and frameworks for implementing*

evidence-based practice: Linking evidence to action (pp. 136-146). West Sussex, United Kingdom: Wiley-Backwell.

Titler, M. G., Kleiber, C., Steelman, V. J., Rackel, B. A., Budreau, G., Everett, L. Q., ... Goode, C. J. (2001, December). The Iowa model of evidence-based practice to promote quality care. *Critical Care Nursing Clinics of North America*.

U.S. Department of Health and Human Services, and Centers for Disease Control and Prevention. (2013). *National Health and Nutrition Examination Survey* (03-0260). Washington, DC: Government Printing Office.

Verdun, F. R., Bochud, F., Gundinchet, F., Aroua, A., Schnyder, R., & Meuli, R. (2008, September 4). Quality initiatives radiation risk: What you should know to tell your patient. *Radiographics*, 28(7), 1807-1816.
<http://dx.doi.org/10.1148/rg.287085042>

Zhang, H., Liao, M., Chen, J., Zhu, D., & Byanju, S. (2017). Ultrasound, computed tomography, or magnetic resonance imaging - which is preferred for acute appendicitis in children? A meta-analysis. *Pediatr Radiol*, 47, 186-196. <http://dx.doi.org/10.1007/s00247-016-3727-3>



Institutional Review Board Project Action Summary

Action Date: December 7, 2016 *Note: Approval expires one year after this date.*

Type: New Full Review New Expedited Review Continuation Review New Exempt Review
 Modification

Action: Approved Approved Pending Modification Not Approved

Project Number: 2016-12-108

Researcher(s): Teresa de Jesus Sanchez Rodriguez DNP student
Dr. Karen Sue Hoyt Fac SON

Project Title: Improving early identification of acute appendicitis in pediatrics with ultrasound

Note: We send IRB correspondence regarding student research to the faculty advisor, who bears the ultimate responsibility for the conduct of the research. We request that the faculty advisor share this correspondence with the student researcher.

Modifications Required or Reasons for Non-Approval

None

The next deadline for submitting project proposals to the Provost's Office for full review is N/A. You may submit a project proposal for expedited review at any time.

Dr. Thomas R. Herrinton
Administrator, Institutional Review Board
University of San Diego
herrinton@san Diego.edu
5998 Alcalá Park
San Diego, California 92110-2492

Office of the Vice President and Provost
Hughes Administration Center, Room 214
5998 Alcalá Park, San Diego, CA 92110-2492
Phone (619) 260-4553 • Fax (619) 260-2210 • www.sandiego.edu