

LONDON
SCHOOL of
HYGIENE
& TROPICAL
MEDICINE



Shantha, JG; Mattia, JG; Goba, A; Barnes, KG; Ebrahim, FK; Kraft, CS; Hayek, BR; Hartnett, JN; Shaffer, JG; Schieffelin, JS; Sandi, JD; Momoh, M; Jalloh, S; Grant, DS; Dierberg, K; Chang, J; Mishra, S; Chan, AK; Fowler, R; O'Dempsey, T; Kaluma, E; Hendricks, T; Reiners, R; Reiners, M; Gess, LA; O'Neill, K; Kamara, S; Wurie, A; Mansaray, M; Acharya, NR; Liu, WJ; Bavari, S; Palacios, G; Teshome, M; Crozier, I; Farmer, PE; Uyeki, TM; Bausch, DG; Garry, RF; Vandy, MJ; Yeh, S (2018) Ebola Virus Persistence in Ocular Tissues and Fluids (EVICT) Study: Reverse Transcription-Polymerase Chain Reaction and Cataract Surgery Outcomes of Ebola Survivors in Sierra Leone. *EBioMedicine*. ISSN 2352-3964 DOI: <https://doi.org/10.1016/j.ebiom.2018.03.020>

Downloaded from: <http://researchonline.lshtm.ac.uk/4647258/>

DOI: [10.1016/j.ebiom.2018.03.020](https://doi.org/10.1016/j.ebiom.2018.03.020)

Usage Guidelines

Please refer to usage guidelines at <http://researchonline.lshtm.ac.uk/policies.html> or alternatively contact researchonline@lshtm.ac.uk.

Available under license: <http://creativecommons.org/licenses/by-nc-nd/2.5/>



Research Paper

Ebola Virus Persistence in Ocular Tissues and Fluids (EVICT) Study: Reverse Transcription-Polymerase Chain Reaction and Cataract Surgery Outcomes of Ebola Survivors in Sierra Leone[☆]



Jessica G. Shantha^{a,b}, John G. Mattia^{c,1}, Augustine Goba^d, Kayla G. Barnes^{e,f}, Faiqa K. Ebrahim^g, Colleen S. Kraft^h, Brent R. Hayek^a, Jessica N. Hartnettⁱ, Jeffrey G. Shaffer^j, John S. Schieffelinⁱ, John D. Sandi^d, Mambu Momoh^d, Simbirie Jalloh^d, Donald S. Grant^{d,y}, Kerry Dierberg^k, Joyce Chang^k, Sharmistha Mishra^l, Adrienne K. Chan^l, Rob Fowler^l, Tim O'Dempsey^m, Erick Kalumaⁿ, Taylor Hendricksⁿ, Roger Reiners^o, Melanie Reiners^o, Lowell A. Gess^o, Kwame O'Neill^p, Sarian Kamara^p, Alie Wurie^p, Mohamed Mansaray^q, Nisha R. Acharya^b, William J. Liu^r, Sina Bavari^s, Gustavo Palacios^s, Moges Teshome^{o,t}, Ian Crozier^u, Paul E. Farmer^k, Timothy M. Uyeki^v, Daniel G. Bausch^w, Robert F. Garryⁱ, Matthew J. Vandy^{p,1}, Steven Yeh^{a,x,*,1}

^a Emory Eye Center, Emory University School of Medicine, Atlanta, GA, United States

^b University of California San Francisco, Proctor Foundation, San Francisco, CA, United States

^c Lunsar Baptist Eye Hospital, Port Loko, Sierra Leone

^d Kenema Government Hospital Lassa Hemorrhagic Fever Laboratory, Kenema, Sierra Leone

^e Department of Organismic and Evolutionary Biology, Harvard University, United States

^f Broad Institute of MIT and Harvard, Cambridge, MA, United States

^g World Health Organization, Geneva, Switzerland

^h Department of Pathology and Laboratory Medicine, Department of Medicine, Division of Infectious Diseases, Atlanta, GA, United States

ⁱ Tulane University School of Medicine, New Orleans, LA, United States

^j Department of Biostatistics and Bioinformatics, Tulane School of Public Health, New Orleans, LA, United States

^k Partners in Health, Boston, MA, United States

^l University of Toronto, Toronto, ON, Canada

^m University of Liverpool, Liverpool, United Kingdom

ⁿ Comprehensive Program for Ebola Survivors, Freetown, Sierra Leone

^o Lowell and Ruth Gess Eye Hospital, Freetown, Sierra Leone

^p Ministry of Health and Sanitation, Sierra Leone

^q Sierra Leone Association of Ebola Survivors, Freetown, Sierra Leone

^r National Institute for Viral Disease Control and Prevention, Chinese Center for Disease Control and Prevention, Beijing, China

^s United States Army Medical Research Institute of Infectious Diseases, Frederick, MD, United States

^t Christian Blind Mission International, Washington, D.C., United States

^u Integrated Research Facility, Division of Clinical Research, National Institute of Allergy and Infectious Diseases, National Institutes of Health, Bethesda, MD, United States

^v Centers for Disease Control and Prevention, Atlanta, GA, United States

^w UK Public Health Rapid Support Team Public Health England/London School of Hygiene and Tropical Medicine, London, United Kingdom

^x Emory Global Health Institute, Emory University, Atlanta, GA, United States

^y Department of Community Health, University of Sierra Leone, Freetown, Sierra Leone

ARTICLE INFO

Article history:

Received 15 October 2017

Received in revised form 16 March 2018

Accepted 17 March 2018

Available online 23 March 2018

Keywords:

Ebola virus disease

Ebolavirus

ABSTRACT

Background: Ebola virus disease (EVD) survivors are at risk for uveitis during convalescence. Vision loss has been observed following uveitis due to cataracts. Since Ebola virus (EBOV) may persist in the ocular fluid of EVD survivors for an unknown duration, there are questions about the safety and feasibility of vision restorative cataract surgery in EVD survivors.

Methods: We conducted a cross-sectional study of EVD survivors anticipating cataract surgery and patients with active uveitis to evaluate EBOV RNA persistence in ocular fluid, as well as vision outcomes post cataract surgery. Patients with aqueous humor that tested negative for EBOV RNA were eligible to proceed with manual small incision cataract surgery (MSICS).

[☆] This work has been presented, in part, at the American Uveitis Society Winter Symposium (Dr. Shantha; All Co-Authors; Park City, Utah, January 14–16, 2017) and as a presentation at Association for Research in Vision and Ophthalmology Annual Meeting (Dr. Yeh; All Co-Authors; Baltimore, Maryland, May 7–11, 2017).

* Corresponding author at: 1365B Clifton Rd. NE, Atlanta, GA 30322, United States.

E-mail address: steven.yeh@emory.edu. (S. Yeh).

¹ Principal Investigators.

Ophthalmology
Uveitis
Global Health
Cataract

Findings: We screened 137 EVD survivors from June 2016 – August 2017 for enrolment. We enrolled 50 EVD survivors; 46 with visually significant cataract, 1 with a subluxated lens, 2 with active uveitis and 1 with a blind painful eye due to uveitis. The median age was 24.0 years (IQR 17–35) and 35 patients (70%) were female. The median logMAR visual acuity (VA) was 3.0 (Snellen VA Hand motions; Interquartile Range, IQR: 1.2–3.0, Snellen VA 20/320 – Hand motions). All patients tested negative for EBOV RNA by RT-PCR in aqueous humor/vitreous fluid and conjunctiva at a median of 19 months (IQR 18–20) from EVD diagnosis in Phase 1 of ocular fluid sampling and 34 months (IQR 32–36) from EVD diagnosis in Phase 2 of ocular fluid sampling. Thirty-four patients underwent MSICS, with a preoperative median VA improvement from hand motions to 20/30 at three-month postoperative follow-up ($P < 0.001$).

Interpretation: EBOV persistence by RT-PCR was not identified in ocular fluid or conjunctivae of fifty EVD survivors with ocular disease. Cataract surgery can be performed safely with vision restorative outcomes in patients who test negative for EBOV RNA in ocular fluid specimens. These findings impact the thousands of West African EVD survivors at-risk for ocular complications who may also require eye surgery during EVD convalescence.

© 2018 The Authors. Published by Elsevier B.V. This is an open access article under the CC BY-NC-ND license (<http://creativecommons.org/licenses/by-nc-nd/4.0/>).

1. Introduction

Uveitis syndromes due to ocular viral infection can lead to significant visual morbidity and blindness (Connors et al., 2015). In addition to commonly recognized pathogens (e.g. herpes simplex virus, cytomegalovirus), emerging viruses (e.g. chikungunya, zika) are increasingly implicated as causes of uveitis (Connors et al., 2015). The West African Ebola virus disease (EVD) outbreak in 2013–2016 brought attention to a range of uveitis findings ranging from anterior uveitis to sight-threatening panuveitis as a sequelae of Ebola virus infection diagnosed in 13% to 34% of EVD survivors (Varkey et al., 2015; Tiffany et al., 2016; Shantha et al., 2017; Hereth-Hebert et al., 2017). A complex disease spectrum was noted, leading to severe vision impairment or blindness in nearly 40% of affected eyes (Shantha et al., 2017). Vision loss due to uveitis impacts overall quality-of-life amidst a number of other clinical sequelae of EVD, including arthralgias, myalgias, headache, and abdominal pain (Epstein et al., 2015; Vetter et al., 2016).

Ebola virus (EBOV) has been noted to persist in immune privileged sites including the aqueous humor (Varkey et al., 2015) and cerebrospinal fluid (Jacobs et al., 2016), leading to severe uveitis and meningoencephalitis, respectively, during EVD convalescence. Long-term EBOV RNA detection in semen (Deen et al., 2017; Soka et al., 2016), breast milk (Sissoko et al., 2017), and placenta (Bower et al., 2016), with rare transmission events reported (Sissoko et al., 2017; Bower et al., 2016; Mate et al., 2015; Diallo et al., 2016), highlight the individual and public health consequences of EBOV persistence and emphasize the urgent need to investigate EBOV RNA clearance from immune-privileged sites.

In EVD survivors, invasive ophthalmic procedures (e.g. cataract surgery, open globe repair, retinal detachment surgery) currently pose an uncertain risk of EBOV transmission via ocular fluid to health care workers and close contacts of EVD survivors. We conducted The Ebola Virus Persistence in Ocular Tissues and Fluids (EVICT) study to establish an evidence base for a safe, effective approach to invasive ophthalmic procedures in EVD survivors. Anterior chamber paracentesis was performed in patients with active uveitis or in patients who require ophthalmic surgery to test for EBOV viral persistence before intraocular surgery. Herein, we report the clinical ophthalmic phenotypes, prevalence of EBOV RT-PCR in ocular fluid of a cohort of Sierra Leonean EVD survivors anticipating ocular surgery or with active uveitis. We also describe the vision restorative outcomes of patients meeting criteria for cataract surgery.

2. Methods

We designed a cross-sectional study to evaluate EBOV RNA persistence in ocular fluids and tissues of EVD survivors. Institutional Review Board approval was obtained from Emory University and the Office of

Ethics and Scientific Review Committee, Sierra Leone Ministry of Health and Sanitation (MOHS). Human research was conducted according to the Tenets of the Declaration of Helsinki, and informed consent was obtained with the assistance of Sierra Leonean interpreters in the native dialect of enrolled patients. During the ocular fluid sampling portion of the EVICT Study, patients underwent ocular fluid testing for EBOV RNA by RT-PCR. Patients who tested negative for EBOV RNA were then eligible for the surgical portion of the EVICT Study, which included manual small-incision cataract surgery (MSICS) with intraocular lens (IOL) implantation when medically indicated.

2.1. EVICT Facility, Study Site Preparation, and Personal Protective Equipment

Patient ophthalmologic evaluations were conducted at the Lowell and Ruth Gess Eye Hospital in Freetown, Sierra Leone. An ophthalmic procedure room was designed adhering to World Health Organization (WHO) guidelines (World Health Organisation, 2016), and guidance from the Emory University Serious Communicable Disease Unit (SCDU), with high-level safety precautions for potential EBOV exposure (Fig. 1). Eye care providers performed the ocular fluid sampling procedure in full personal protective equipment (PPE) with monitoring from an infectious disease physician trained in the care of EVD in the acute Ebola treatment unit (ETU) setting.

2.2. Patient Recruitment

EVD survivors anticipating ophthalmic surgery (cataract and/or retinal surgery) were identified via an ophthalmic screening program conducted by the MOHS National Eye Care Program from March 2015 through March 2016. In addition, EVD survivors were referred from local eye clinics for vision loss and cataract evaluation. These centers included Connaught Government Hospital (Freetown), Lunsar Baptist Eye Hospital (Port Loko) and Kenema Government Hospital (Kenema), as well as direct referral from the Sierra Leone Association of Ebola Survivors (SLAES).

2.3. Patient Screening, Ophthalmic Exam, and Follow-Up

Ophthalmic exams for EVD survivors included corrected visual acuity (VA), pupillary examination, confrontational visual fields, ocular motility and intraocular pressure (tonopen, Avia, Reichert Technologies). Anterior chamber (AC) cell grade was measured per Standardization of Uveitis Nomenclature guidelines via slit lamp examination (Jabs et al., 2005). Cataract was classified as nuclear sclerotic, posterior subcapsular, anterior subcapsular, uveitic white cataract, uveitic white cataract with anterior capsular fibrosis, and graded from one to four. Funduscopy evaluation was performed with a 90- and 28-diopter

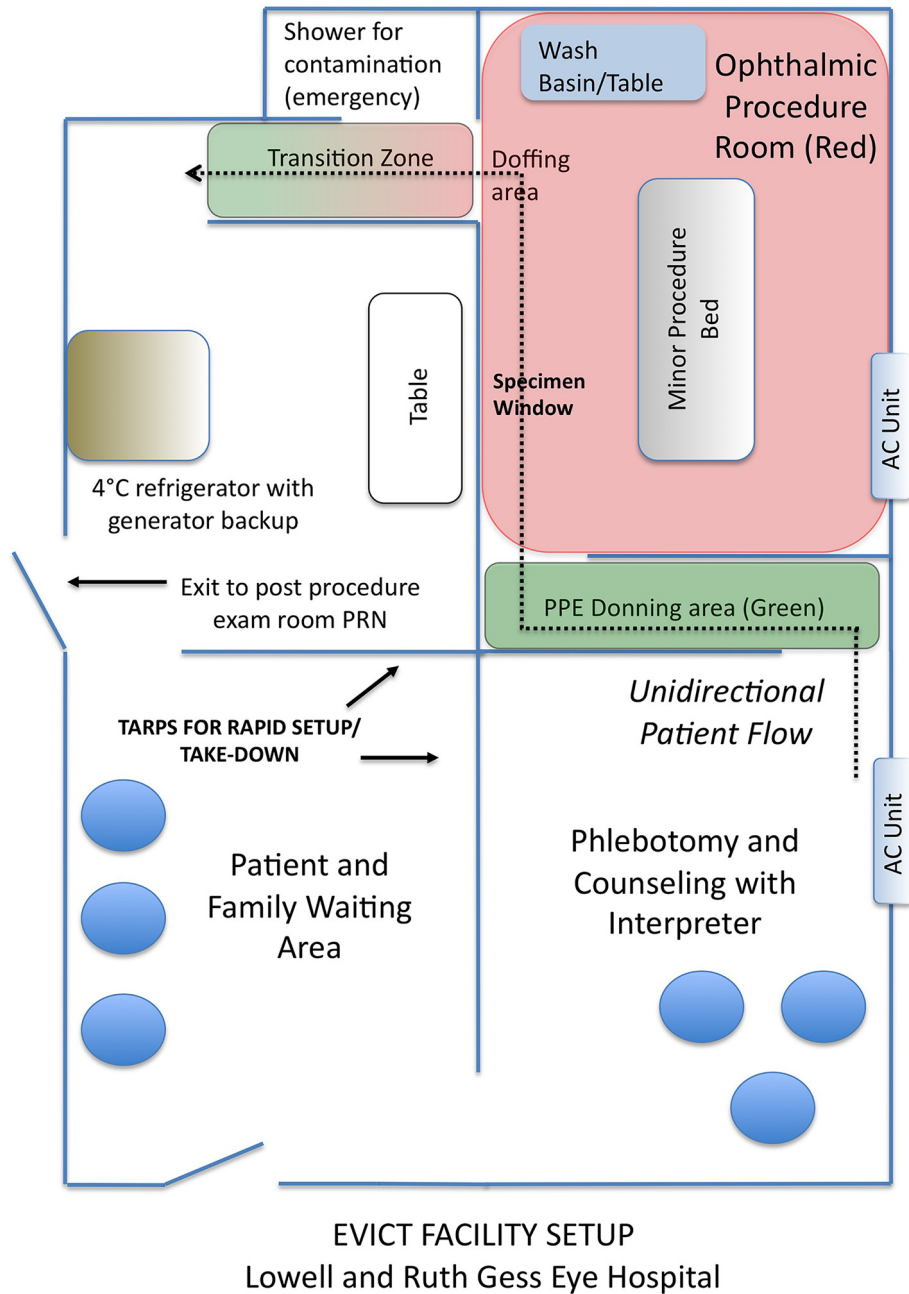


Fig. 1. Schematic blueprint of EVICT facility. Features of the EVICT room for ophthalmic procedures include a unidirectional patient flow with separate entry and exit areas, health care worker monitoring during donning and doffing of personal protective equipment, and specimen handling protocols for harvesting and storage of specimens in a temperature-monitored 4 °C refrigerator prior to transportation to reference laboratory.

lens. When media opacity (e.g. dense cataract) precluded adequate view of the retina, a B-scan ultrasound was performed. Patients who were anticipating intraocular surgery or with active uveitis were offered EVICT enrollment for ocular fluid sampling. Exclusion criteria included clinical findings suggesting minimal to no benefit from intraocular surgery (e.g. chronic tractional retinal detachment by B-scan would preclude cataract surgery) and was determined by the clinical investigator. Following their ocular fluid (aqueous humor or vitreous) sampling procedure, patients were seen at one-day, one-week, and one-month post procedure. Patients were evaluated sooner when clinically indicated. Patients who underwent MSICS with IOL implantation were evaluated at postoperative day one (POD1), at week one (POW1), at month one (POM1), and at three to four months (POM 3/4).

2.4. Laboratory Workup and Serologic Testing for Causes of Uveitis

Serologic evidence of prior EBOV infection was evaluated on sera collected from enrolled patients using ReEBOV® IgG ELISA Test Kits (Zalgen Labs, Germantown, MD) as described in the Supplementary Appendix by the Kenema Government Hospital Lassa Hemorrhagic Fever Laboratory. Patients also underwent laboratory evaluation for other causes of uveitis, including serum testing for HIV 1/2- Antigen-Antibody (Alere Determine™, San Diego, CA), and syphilis testing by rapid plasma reagin (RPR). Specific syphilis antibody testing with FTA-ABS or syphilis IgG was not available. Serology for Lassa fever (LASV) IgG using ReLASV™ Pan-Lassa IgG/IgM ELISA Test Kit (Zalgen Labs) was also performed.

2.5. Ocular Fluid Sampling Procedure

We performed ocular fluid sampling in full PPE in a facility with infection prevention measures following guidelines from the WHO and Emory SCU (Fig. 1). Patients underwent extra- and intraocular fluid sampling by Retina Fellowship-trained ophthalmologists. Anterior chamber paracentesis or vitreous tap was performed as detailed in the Supplemental Appendix. Approximately 100–200 μ l were aspirated from the aqueous humor and 500 μ l were obtained from the vitreous humor. We obtained conjunctival swabs from the inferior conjunctival fornix pre-procedure and immediately post procedure with a Dacron swab, and placed them in viral transport media (Hardy Diagnostics, Springboro, OH). Ocular fluid sampling proceeded in two phases with Phase 1 occurring in June 2016 and Phase 2 occurring in July and August 2017. The patients in Phase 1 were largely from Freetown and included Port Loko and Western Area Districts, whereas the patients in Phase 2 included individuals from more distant locations including Bo, Kenema, Moyamba, Tonkolili.

2.6. EBOV Reverse Transcription Polymerase Chain Reaction (RT-PCR) Testing of Ocular Fluid

EBOV RT-PCR was performed on conjunctival swab specimens and ocular fluid following RNA extraction using the QIAamp Viral RNA Mini kit (Qiagen, Germantown, MD) at the Kenema Government Hospital (KGH). Patient samples then underwent EBOV RT-qPCR analysis using the KGH primer set (Gire et al., 2014) and Power SYBR Green RNA-to-Ct 1-Step qRT-PCR assay (Life Technologies, Carlsbad, CA). The details of the EBOV RT-PCR procedure are outlined in the Supplemental Appendix.

2.7. Manual Small-Incision Cataract Surgery Procedure

Patients with ocular fluid specimens that tested negative for EBOV RNA by RT-PCR had the opportunity to undergo MSICS with IOL implantation to achieve a postoperative refractive error between -0.50 and -1.00 diopters. PPE was modified to sterile surgical attire (fluid impervious gown, gloves, mask and shoe covers). The details of MSICS are summarized in the Supplemental Appendix.

2.8. Statistical Analysis

Data were presented as percentage frequencies as appropriate or medians with interquartile range (IQR) for continuous variables. VA was converted to logarithm of the minimal angle of resolution (logMAR) for statistical analysis. Counting fingers and hand motions were converted to logMAR as previously described (Holladay, 2004). Patients with only light perception or no light perception were excluded from statistical analyses. We used a paired *t*-test to compare preoperative to postoperative VA at follow-up. The Jeffrey's interval approach was used to calculate a confidence interval estimating the true proportion of ocular specimens with EBOV presence. Descriptive and univariate analyses were carried out using Microsoft Excel (v2013, Redmond, WA) and SAS (v9.3, Cary, NC). All statistical tests were two-sided and a *p* value < 0.05 was considered statistically significant for all comparisons.

3. Results

3.1. Characteristics of Screened and Enrolled Patients

We examined 137 EVD survivors from Sierra Leone in from June 2016 – August 2017 (Fig. 2, Consort diagram), of whom 32 (23%) EVD-survivors showed evidence of cataract but did not fulfill EVICT eligibility criteria due to non-visually significant (i.e. immature) cataract (16 patients), retinal or optic nerve disease precluding VA improvement

(11 patients) and hypotony/phthisis bulbi (5 patients). Fifty-one patients met eligibility criteria and one patient deferred enrollment. Fifty (35%) EVD survivors were enrolled into the EVICT study for ocular fluid sampling.

3.2. Baseline Enrolled Patient Characteristics

The median age of the 50 EVD survivor participants was 24.0 years (IQR 17–35). Thirty-five patients (70%) were female. The median time spent in an ETU was 21 days (IQR 14–45). The median time from EVD diagnosis to AC paracentesis in Phase 1 of ocular fluid sampling was 19 months (IQR 18–20); in Phase 2 of ocular fluid sampling, the median time from EVD diagnosis to AC paracentesis was 34 months (IQR 32–36 months). The most commonly observed ophthalmic complaints at the time of EVICT enrollment included vision loss (49%), eye pain (37%), and tearing (27%) (Supplemental Table 1). Systemic complaints at study enrollment are summarized in Supplemental Table 2, with headache, joint pain, and weight loss being most frequently observed.

The median logMAR visual acuity of the affected eyes was 3 (IQR 1.2 – 3.0; Snellen visual acuity equivalent hand motions; IQR 20/320 – Hand Motions). Thirty eyes (60%) involved the left eye. Indications for enrollment included visually significant cataract (46 eyes, 92%), active uveitis (2 eyes, 4%), subluxed lens (1 eye, 2%), and blind painful eye due to chronic uveitis (1 patient, 2%). Cataracts were identified in 46 (92%) patients. Uveitic white cataract (25, 54.3%) and posterior subcapsular cataract alone (8, 17.4%) were most frequently seen. Other cataract subtypes included uveitic white cataract with anterior capsular fibrosis (4, 8.7%) combination nuclear sclerotic/posterior subcapsular (4, 8.7%), combination anterior subcapsular/posterior subcapsular (3, 6.5%), and age-related nuclear sclerotic (2, 4.3%) (Fig. 3).

Two enrollees (4%) had active uveitis, one of whom also had a non-visually significant cataract. Forty-six survivors (92%) had a history of uveitis. Structural complications in affected eyes included posterior synechiae (40, 80%), chorioretinal scars (7, 14%), inactive, pigmented keratic precipitates (9, 18%), active keratic precipitates (2, 4%) and band keratopathy (3, 6%). B-scan ultrasound was required due to inadequate view of the posterior segment in 36 (72%) patients (Fig. 4). Ocular treatments prior to study enrollment included oral prednisone (4, 8%), sulfamethoxazole/ trimethoprim 800 mg/160 mg and oral prednisone (1, 2%), topical prednisolone acetate 1% (2, 4%) and a combination of topical prednisolone acetate 1% and oral prednisone (15, 30%).

3.3. Procedures, Safety Monitoring, and Follow-Up

Forty-nine (98%) patients underwent an AC paracentesis and 1 patient had a vitreous tap. The median volume of the AC paracentesis was 140 (IQR: 110–170) microliters. The vitreous sample was 500 μ l. We obtained pre-procedure and immediate post procedure conjunctival swabs in all patients. One adverse event was observed following ocular fluid sampling. Specifically, the patient who underwent the vitreous tap developed a 1.0 mm hyphema with a transient elevation of intraocular pressure that resolved to a normal intraocular pressure with topical prednisolone acetate, atropine, and ocular hypotensives. One month after the procedure, all patients were stable with no new adverse events. Visual acuities and intraocular pressures remained stable at 2-months follow-up.

3.4. Laboratory Investigations

Sera collected from enrolled EVD survivors yielded seropositive results for EBOV IgG in 49 (98%) patients. LASV IgG, HIV, and RPR were positive in 8 (16%), 1 (2%), and 1 (2%) patients respectively.

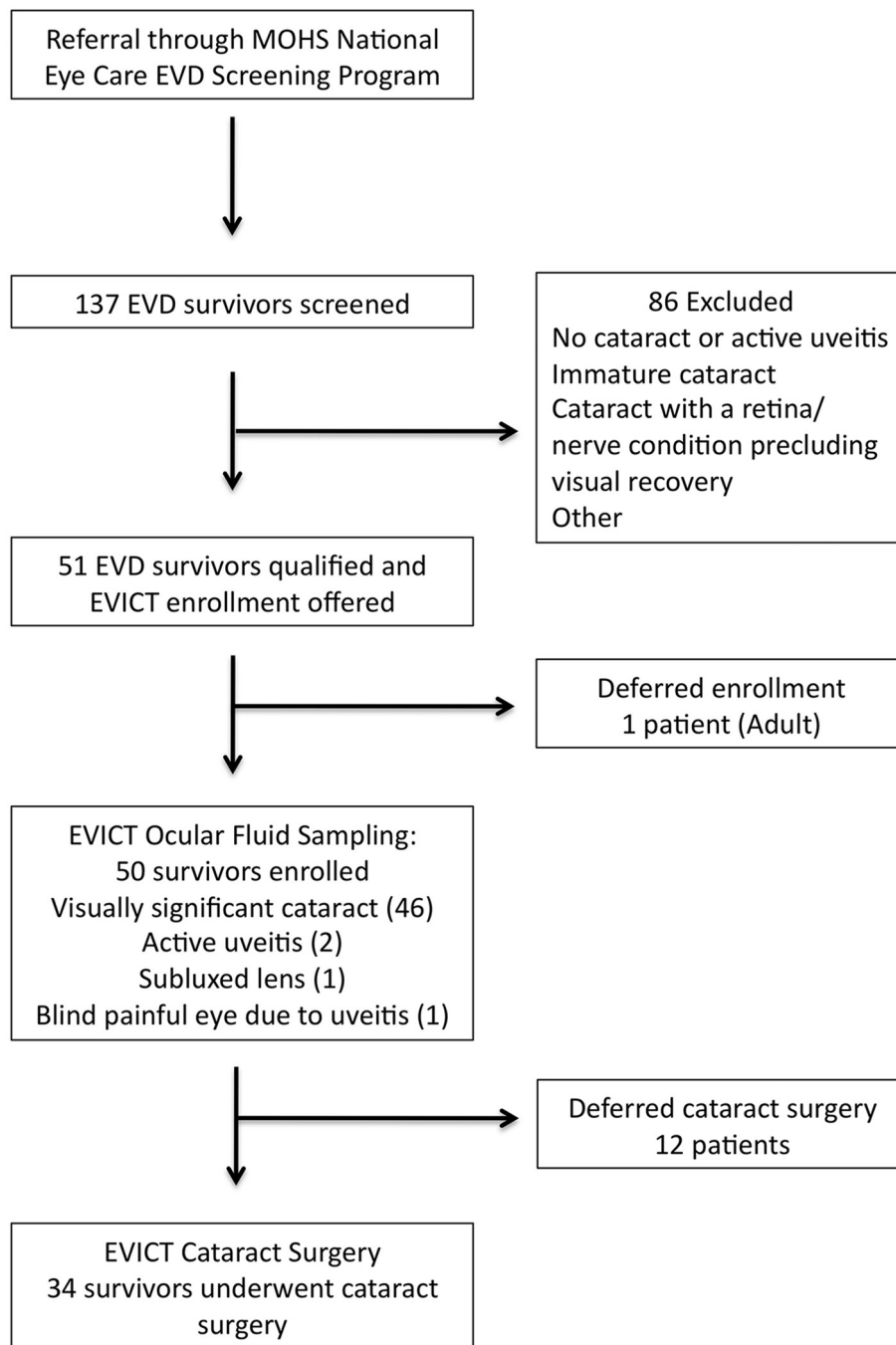


Fig. 2. CONSORT Diagram depicting Ebola virus disease survivors screened, excluded, and enrolled for EVICT Study. Following negative Ebola virus RT-PCR testing of ocular fluid, survivors with visually significant cataract underwent surgery.

3.5. Ocular Fluid Analysis

Forty-nine aqueous humor samples and one vitreous aspirate tested EBOV RNA-negative by RT-PCR. Pre-procedure and immediate post procedure conjunctival swab specimens tested negative by EBOV RT-PCR in all patients. Following negative testing results for EBOV RNA of ocular fluid specimens, the 46 patients with visually significant cataract were deemed eligible for MSICS. With all 50 ocular fluid specimens testing negative for EBOV RNA by RT-PCR, it is estimated with 95% confidence that the true EBOV presence in ocular fluid specimens would be no greater than 5% in our cohort of patients assessed.

3.6. Manual Small Incision Cataract Surgery Outcomes

Thirty-four of 46 (74%) patients with visually significant cataract underwent MSICS with IOL implantation (Fig. 2). Twenty of the patients (59%) were female. Eighteen patients (53%) had a cataract in the right eye and thirty patients (88%) required B-scan ultrasound for evaluation of the posterior segment. Preoperative median logMAR VA (IQR; Median Snellen VA) improved from 3 (Snellen VA equivalent Hand motions; IQR 1.0-3.0; IQR 20/200 – Hand motions) to 0.54 (IQR 0.18-0.78; Median Snellen VA 20/70, IQR 20/30 – 20/120) at POM1 ($p < 0.001$) and 0.18 (IQR 0-0.69; Median Snellen VA 20/30, IQR 20/20–20/100) at POM3/4 (Fig. 5).

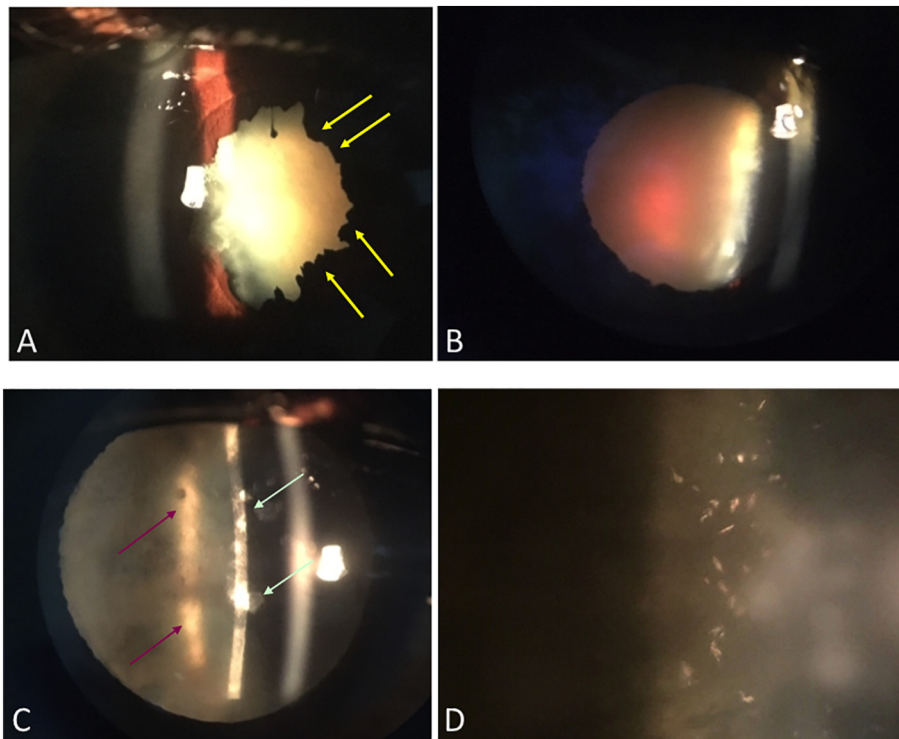


Fig. 3. Slit lamp photographs of cataract in Ebola virus disease (EVD) survivors. Slit lamp photograph of an EVD survivor (A) shows a mature white cataract with posterior synechiae (yellow arrows) indicating prior uveitis. Slit lamp photograph of an EVD survivor with a 4+ brunescens, age-related nuclear sclerotic cataract (B). A slit lamp photograph of an EVD survivor shows a distinct combination of anterior and posterior lenticular changes with anterior (light green arrow) and posterior subcapsular cataract (red arrows, C) with highly refractile cortical deposits at higher magnification (D).

Twenty-four of 34 eyes (70%) in this cohort met the International Classification of Disease-10 (ICD-10) definition of blindness in the affected eye with a preoperative VA < 20/400. Of these 24 patients with poorer than 20/400 visual acuity, 20 patients (83%) improved by 3 or more lines of visual acuity during follow-up. Of the 34 patients undergoing MSICS, 27 patients experienced VA improvement of ≥ 3 Snellen eye chart lines by their final visit with 20 patients (60%) demonstrating VA of 20/40 or better at their last visit. Five patients remained poorer

than 2'/200E (i.e. counting fingers vision) due to vitreoretinal pathology. Nine patients underwent yttrium aluminum garnet (YAG) capsulotomy during follow-up. Monitoring for uveitis recurrences is ongoing.

4. Discussion

This study is the first to systematically evaluate EBOV persistence in the eyes of EVD survivors with cataract or active inflammation. Because uveitis has been estimated in 13 to 34% of EVD survivors, and cataract blindness is a disabling, but potentially treatable complication of uveitis, the study findings provide initial evidence to directly impact clinical care and timing of vision rehabilitation via cataract surgery. Amidst public health uncertainty around the persistence of EBOV in immune privileged sites (Varkey et al., 2015), interim WHO guidance includes the avoidance of elective surgery (i.e. cataract surgery) until further data is obtained (World Health Organization, n.d.). The step-wise approach involving ocular screening, ocular fluid sampling, and subsequent cataract surgery was safe, feasible, and vision restorative in this cohort of EVD survivors.

Among the 50 EVD survivors we enrolled, the majority presented with severe vision impairment or blindness in the affected eye. All 50 tested negative for EBOV RNA by RT-PCR in their ocular fluid and conjunctiva at a median of 19 months after EVD diagnosis in Phase 1 of ocular fluid sampling and at a median of 34 months after EVD in Phase 2 of ocular fluid sampling. Survivors with a cataract could then proceed with eye surgery with preliminary reassurance to eye care providers that aqueous humor was free of EBOV by RT-PCR. The 34 EVD survivors who underwent cataract surgery experienced significant VA improvement over three to four months of follow-up. It is particularly notable that the preoperative vision of over 70% of eyes was poorer than Snellen visual acuity 20/400 or big "E" optotype. The vision loss was reversible with treatment despite signs of previous inflammation and the need for a complex MSICS procedure.

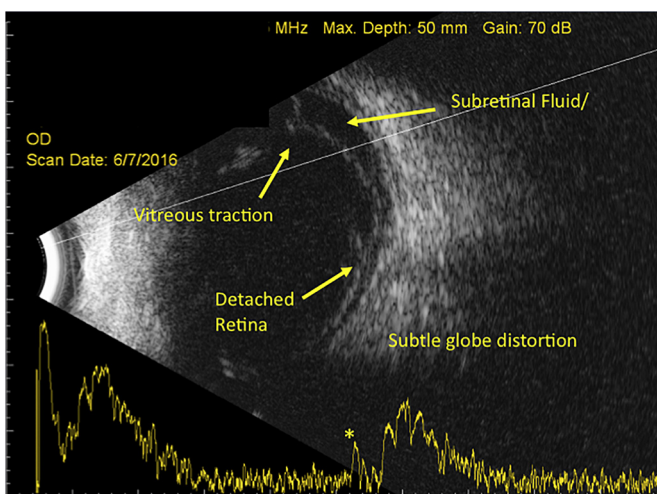


Fig. 4. B-scan ultrasound of an Ebola virus disease (EVD) survivor with a traction retinal detachment. A B-scan ultrasound of an EVD survivor with a gain of 70 dB shows vitreous traction with concomitant retinal detachment and subretinal fluid involving the macula, which is confirmed by the high-frequency spike on the A-scan (yellow asterisk). There is subtle globe distortion indicative of early phthisis bulbi (cosmetic deformity of globe due to chronic low intraocular pressure). EVICT protocol enrolment and surgery were deferred owing to poor visual prognosis.

Visual Acuity Outcomes after Cataract Surgery

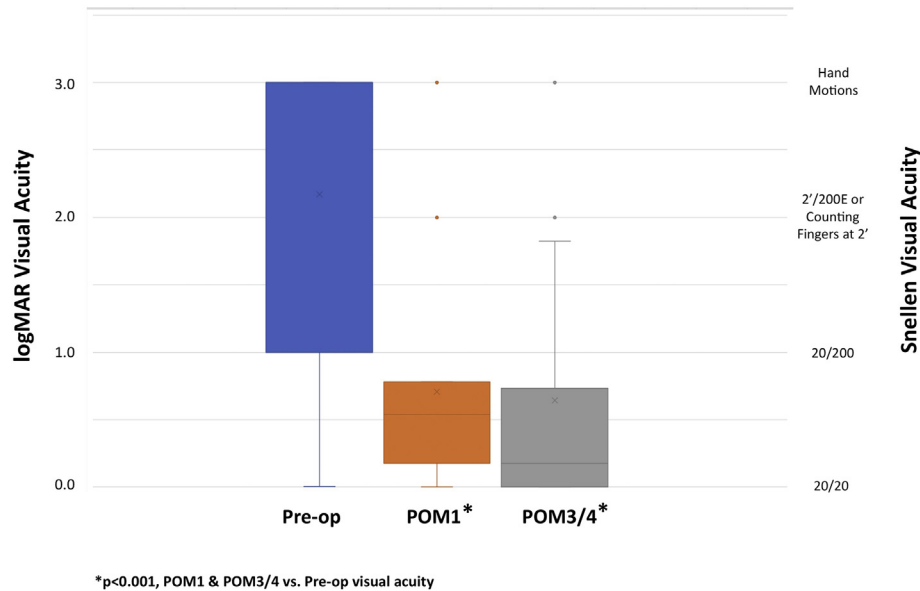


Fig. 5. Visual acuity (VA) in eyes following cataract surgery in EVICT Study. Preoperative median logMAR VA was 3.0 (Snellen VA hand motions level) with an improvement to logMAR VA 0.54 (Snellen VA 20/70) at postoperative month 1 and continued improvement to logMAR VA 0.176 (Snellen VA 20/30) at postoperative month 3–4. Note: n = 18 for POM1; n = 28 for POM3/4.

The mechanism by which the dense cataracts leading to blindness rapidly developed in association with uveitis in EVD survivors is unknown. Contributing factors may include chronic, untreated inflammation, acute severe episodic inflammation, corticosteroid-related factors, or EBOV persistence. While EBOV persistence in seminal fluid has been evaluated in several studies (Deen et al., 2017; Mate et al., 2015; Christie et al., 2015), the clearance dynamics of EBOV from other immune privileged sites (i.e. eye, central nervous system) require further investigation. Recent studies in non-human primates have demonstrated that EBOV may persist in monocytes and macrophages within the vitreous humor in association with uveitis (Zeng et al., 2017). Moreover, in vitro studies have shown that human retinal pigment epithelial cells are permissive to EBOV infection (Smith et al., 2017).

Limitations of this cross-sectional study include the length of time after acute EVD when ocular fluid sampling occurred. Specifically, our study cannot determine if survivors with uveitis may have harbored EBOV in their eye at earlier time points when ocular inflammation was active. Although the RT-qPCR is very sensitive, the low amount of sample extracted could affect the ability to capture EBOV RNA, especially when using conjunctival swabs, which have very little total RNA. Moreover, only approximately 50–150 μ l of aqueous humor can be safely obtained from the anterior chamber of the eye to avoid complications, which include ocular hypotony, hyphema, damage to the lens capsule, and vision loss. Nonetheless, it currently remains unknown whether EBOV may persist at low levels after infection, which remain beneath the threshold of detection of RT-PCR, or in other locations within the eye, which were not specifically assessed in this study. Another limitation in the evaluation of cataract outcomes was the variable follow-up. The majority of patients, however, returned for their 3-month follow-up appointments and their visual acuity outcomes showed statistically significant and clinically meaningful improvement.

Future study considerations include assessment of survivors at time points earlier than 19 months, patients with active uveitis, and a larger sample size. While our study findings in 50 EVD survivors support that the expected true proportion of EBOV RNA-positive patients would be no greater than 5% in a comparable patient population, a larger sample size could provide greater reassurance to eye care providers performing invasive surgical procedures to restore vision. Specifically, the minimum

number of subjects testing negative for EBOV RNA by RT-PCR to achieve a 95% confidence interval of 0.99–1.00 (i.e. expected proportion of EBOV RNA positive samples \leq 1%) is 250.

In summary, the EVICT Study provides the first systematically collected evidence evaluating EBOV persistence in ocular fluid of EVD survivors. We also demonstrate that cataract surgery can be performed safely with vision restorative outcomes. Given the magnitude of the West African EVD outbreak and the thousands of survivors at risk of complications of uveitis, including cataract, efforts to address the ongoing ophthalmic medical and surgical needs of survivors are urgently needed.

Funding Sources

Supported by an unrestricted grant from Research to Prevent Blindness to the Emory Eye Center and National Eye Institute, National Institutes of Health Core Grant to Emory University (P30EY006360). Supported by the Building Interdisciplinary Careers in Women's Health of the National Institutes of Health (K12HD085850). The content is solely the responsibility of the authors and does not necessarily represent the official views of the National Institutes of Health. Funding sources also include Emory University Research Committee Grant, Marcus Foundation, Emory Global Health Institute Seed Grant, Santen (SY, JGS), Alcon Research Institute (SY), Bayer Global Ophthalmology Awards Program (JGS) and the Heed Ophthalmic Foundation (JGS). This work was supported in part by the Center for AIDS Research (P30 AI050409). The views expressed are those of the authors and do not necessarily reflect the official policy of the Centers for Disease Control and Prevention.

Authors' Contributions

Literature search - JGS, JM, KGB, FI, CK, SM, RF, JS, LAG, IC, TMU, DGB, RFG, MV, SY.

Figures - JGS, JM, AG, KGB, BRH, LAG, RR, MR, MT, IC, TMU, RFG, MV, SY.

Study design - JGS (Shantha), JGM, AG, KGB, FI, CK, BRH, JH, JGS (Shaffer), SM, AKC, RF, TOD, EK, TH, RR, MR, LAG, KO, SK, AW, MM, NA, WL, SB, GP, MT, KD, JC, IC, PEF, TMU, DGB, RFG, MJV, SY.

Data collection - JGS, AG, KGB, FI, CK, BRH, JH, JGS, JS, MM, SJ, DG, LAG, MM, MT, EK, TH, IC, RFG, MV, SY.

Data analysis and interpretation - All authors contributed.

Manuscript drafting - JGS (Shantha), JM, AG, KGB, JH, JGS (Shaffer), TMU, DGB, IC, MV, SY.

Manuscript revision and approval of the final manuscript - All authors contributed.

Acknowledgments

We gratefully thank the patients in the EVICT Study and their families for accompanying them on their journey to the eye clinic and through the ophthalmic procedures. We are grateful to the Sierra Leone Association of Ebola Survivors organization and leadership. We also thank the Kissy United Methodist Church Hospital, Kissy UMC Medical Board, and Bishop John Yambasu; Christian Blind Mission International; Lowell and Ruth Gess Eye Hospital staff and eye care providers, Lead Outreach Administrator Mr. Ibrahim Conteh; Central Global Vision Fund; Ministry of Health and Sanitation, Sierra Leone; Chief Medical Officer Dr. Brima Kargbo for guidance in the EVICT Study; Program Implementation Unit, Comprehensive Program for Ebola Survivors, Ministry of Health and Sanitation; Partners in Health; Emory Eye Center, Emory Global Health Institute, Emory University School of Medicine, Dr. Allen Beck, Dr. Timothy Olsen, Dr. Alcides Fernandes, Mr. Andy Garrard, Mrs. Kimberly Monroe, Ms. Anita Hester; World Hope International; Kenema Government Hospital Lassa Fever Laboratory; Alcon Foundation; and Helen Keller International.

Appendix A. Supplementary data

Supplementary data to this article can be found online at <https://doi.org/10.1016/j.ebiom.2018.03.020>.

References

- Bower, H., Grass, J.E., Veltus, E., et al., 2016. Delivery of an Ebola virus-positive stillborn infant in a rural community health center, Sierra Leone, 2015. *Am. J. Trop. Med. Hyg.* 94, 417–419.
- Christie, A., Davies-Wayne, G.J., Cordier-Lassalle, T., et al., 2015. Possible sexual transmission of Ebola virus - Liberia, 2015. *MMWR Morb. Mortal. Wkly Rep.* 64, 479–481.
- Connors, D.B., Shantha, J.G., Yeh, S., 2015. Emerging causes of viral-associated uveitis. *Int. Ophthalmol. Clin.* 55, 103–113.
- Deen, G.F., Broutet, N., Xu, W., et al., 2017. Ebola RNA persistence in semen of Ebola virus disease survivors - final report. *N. Engl. J. Med.* 377, 1428–1437.
- Diallo, B., Sissoko, D., Loman, N.J., et al., 2016. Resurgence of Ebola virus disease in guinea linked to a survivor with virus persistence in seminal fluid for more than 500 days. *Clin. Infect. Dis.* 63, 1353–1356.
- Epstein, L., Wong, K.K., Kallen, A.J., Uyeki, T.M., 2015. Post-Ebola signs and symptoms in U.S. survivors. *N. Engl. J. Med.* 373, 2484–2486.
- Gire, S.K., Goba, A., Andersen, K.G., et al., 2014. Genomic surveillance elucidates Ebola virus origin and transmission during the 2014 outbreak. *Science* 345, 1369–1372.
- Hereth-Hebert, E., Bah, M.O., Etard, J.F., et al., 2017. Ocular complications in survivors of the Ebola outbreak in Guinea. *Am J. Ophthalmol.* 175, 114–121.
- Holladay, J.T., 2004. Visual acuity measurements. *J. Cataract Refract. Surg.* 30, 287–290.
- Jabs, D.A., Nussenblatt, R.B., Rosenbaum, J.T., 2005. Standardization of uveitis nomenclature for reporting clinical data. results of the first international workshop. *Am J. Ophthalmol.* 140, 509–516.
- Jacobs, M., Rodger, A., Bell, D.J., et al., 2016. Late Ebola virus relapse causing meningoencephalitis: a case report. *Lancet* 388, 498–503.
- Mate, S.E., Kugelman, J.R., Nyenswah, T.G., et al., 2015. Molecular evidence of sexual transmission of Ebola virus. *N. Engl. J. Med.* 373, 2448–2454.
- Shantha, J.G., Crozier, I., Hayek, B.R., et al., 2017. Ophthalmic manifestations and causes of vision impairment in Ebola virus disease survivors in Monrovia, Liberia. *Ophthalmology* 124, 170–177.
- Sissoko, D., Duraffour, S., Kerber, R., et al., 2017. Persistence and clearance of Ebola virus RNA from seminal fluid of Ebola virus disease survivors: a longitudinal analysis and modelling study. *Lancet Glob. Health* 5 (e80–e8).
- Smith, J.R., Todd, S., Ashander, L.M., et al., 2017. Retinal pigment epithelial cells are a potential reservoir for Ebola virus in the human eye. *Transl. Vis. Sci. Technol.* 6, 12.
- Soka, M.J., Choi, M.J., Baller, A., et al., 2016. Prevention of sexual transmission of Ebola in Liberia through a national semen testing and counselling programme for survivors: an analysis of Ebola virus RNA results and behavioural data. *Lancet Glob. Health* 4, e736–43.
- Tiffany, A., Vetter, P., Mattia, J., et al., 2016. Ebola virus disease complications as experienced by survivors in Sierra Leone. *Clin. Infect. Dis.* 62, 1360–1366.
- Varkey, J.B., Shantha, J.G., Crozier, I., et al., 2015. Persistence of Ebola virus in ocular fluid during convalescence. *N. Engl. J. Med.* 372, 2423–2427.
- Vetter, P., Kaiser, L., Schibler, M., Ciglenecki, I., Bausch, D.G., 2016. Sequelae of Ebola virus disease: the emergency within the emergency. *Lancet Infect. Dis.* 16, e82–e91.
- World Health Organization, Feb. 2016. Clinical management of patients with viral hemorrhagic fever: a pocket guide for front-line health workers. 2nd edition.
- World Health Organization. Clinical care for survivors of Ebola virus disease: Interim Guidance. <http://www.who.int/csr/resources/publications/ebola/guidance-survivors/en/>.
- Zeng, X., Blancett, C.D., Koistinen, K.A., et al., 2017. Identification and pathological characterization of persistent asymptomatic Ebola virus infection in Rhesus monkeys. *Nat. Microbiol.* 2, 17113.