



Al-Rudainy, D., Ju, X., Stanton, S., Mehendale, F. V. and Ayoub, A. (2018) Assessment of regional asymmetry of the face before and after surgical correction of unilateral cleft lip. *Journal of Cranio-Maxillofacial Surgery*, 46(6), pp. 974-978. (doi:[10.1016/j.jcms.2018.03.023](https://doi.org/10.1016/j.jcms.2018.03.023))

This is the author's final accepted version.

There may be differences between this version and the published version. You are advised to consult the publisher's version if you wish to cite from it.

<http://eprints.gla.ac.uk/160422/>

Deposited on: 09 April 2018

Enlighten – Research publications by members of the University of Glasgow

<http://eprints.gla.ac.uk>

# Accepted Manuscript

sAssessment of Regional Asymmetry of the Face Before and After Surgical Correction of Unilateral Cleft Lip

Dhelal Al-Rudainy, M.Sc.Ortho., B.D.S, Xiangyang Ju, B.Eng., M.Eng., Ph.D, Steve Stanton, RMIP, Felicity V. Mehendale, F.R.C.S.(PLAST), Ashraf Ayoub, F.D.S.R.C.S. (Edin.), F.D.S.R.C.P.S. (Glasg.), Ph.D

PII: S1010-5182(18)30099-4

DOI: [10.1016/j.jcms.2018.03.023](https://doi.org/10.1016/j.jcms.2018.03.023)

Reference: YJCMS 2941

To appear in: *Journal of Cranio-Maxillo-Facial Surgery*

Received Date: 22 June 2017

Revised Date: 19 March 2018

Accepted Date: 27 March 2018

Please cite this article as: Al-Rudainy D, Ju X, Stanton S, Mehendale FV, Ayoub A, sAssessment of Regional Asymmetry of the Face Before and After Surgical Correction of Unilateral Cleft Lip, *Journal of Cranio-Maxillofacial Surgery* (2018), doi: 10.1016/j.jcms.2018.03.023.

This is a PDF file of an unedited manuscript that has been accepted for publication. As a service to our customers we are providing this early version of the manuscript. The manuscript will undergo copyediting, typesetting, and review of the resulting proof before it is published in its final form. Please note that during the production process errors may be discovered which could affect the content, and all legal disclaimers that apply to the journal pertain.



**Title:** Assessment of Regional Asymmetry of the Face Before and After Surgical Correction of Unilateral Cleft Lip

**Authors:**

Dhelal Al-Rudainy, M.Sc.Ortho., B.D.S.

Xiangyang Ju, B.Eng., M.Eng., Ph.D.

Steve Stanton, RMIP

Felicity V. Mehendale, F.R.C.S.(PLAST)

Ashraf Ayoub, F.D.S.R.C.S. (Edin.), F.D.S.R.C.P.S. (Glasg.), Ph.D.

**Academic rank or position, and institutional affiliation for each author**

Dr Al-Rudainy is a PhD student in the Orthodontic Department, Glasgow Dental School, School of Medicine, College of Medical, Veterinary and Life Sciences, University of Glasgow, Glasgow, United Kingdom.

Dr Ju is Senior Software Engineer, Medical Devices Unit, Department of Clinical Physics and Bioengineering, National Health Service of Greater Glasgow and Clyde, United Kingdom.

Mr Stanton is Medical Photographer at the Royal Hospital for Sick Children, Edinburgh, United Kingdom.

Dr Mehendale is Consultant Cleft and Plastic Surgeon, Royal Hospital of Sick Children Edinburgh, United Kingdom.

Dr Ayoub is Professor of Oral and Maxillofacial Surgery, College of Medical, Veterinary and Life Sciences, School of Medicine, Dental School, University of Glasgow, Glasgow, United Kingdom.

**Corresponding Author:**

Prof. Ashraf F. Ayoub

Glasgow University Dental Hospital & School

378 Sauchiehall Street

Glasgow G2 3JZ

Tel: 0044 141 211 9600

Fax: 0044 141 2119601

Email: [ashraf.ayoub@glasgow.ac.uk](mailto:ashraf.ayoub@glasgow.ac.uk)

**Running titles:**

Facial asymmetry following the surgical repair of cleft lip

**Abstract:**

This study was carried out on 26 unilateral cleft lip and palate (UCLP) cases with mean age  $3.6 \pm 0.7$  months. 3D facial images were captured for each infant 2–3 days before the repair of cleft lip and at 4 months following surgery at a mean age of  $8.2 \pm 1.8$  months, using a stereophotogrammetry imaging system. An iterative closest point (ICP) algorithm was used to superimpose the 3D facial model to its mirror image using VRMesh software. After the superimposition, the face model was divided into seven anatomical regions. Asymmetry of the entire face and of the anatomical regions was calculated by measuring the absolute distances between the 3D facial surface model and its mirror image. Colour maps were used to illustrate the patterns and magnitude of the facial asymmetry before and after surgery. There were significant decreases in the asymmetry scores for the nose, upper lip and the cheeks as a result of the surgical repair of cleft lips. Surgery did not change the magnitude of the asymmetry scores for the lower lip and chin.

The main outcome of the findings of this innovative study is to inform the required surgical refinement of primary repair of cleft lip in order to minimise facial asymmetry and to guide secondary corrective surgery. We have presented a sensitive tool that could be used for comparative analysis of lip repair at various cleft centres.

**Introduction:**

Cleft lip and palate is the most common craniofacial deformity. The main goal of the primary surgical repair of cleft lip in the early months of life is to restore facial symmetry. Residual

facial asymmetry associated with unilateral cleft lip and palate (UCLP) has been widely reported (Bilwatsch et al., 2006; Stauber et al., 2008; Meyer-Marcotty et al., 2011; Bugaighis et al., 2013; Bell et al., 2014; Djordjevic et al., 2014; Kuijpers et al., 2015).

Stereophotogrammetry facilitates the recording and the assessment of facial asymmetry in cleft cases. The system has been used routinely to record the face in 3D due to the simplicity of its capture process (Ras et al. in 1994).

There is limited information on the assessment of cleft-related facial asymmetry in infants before the surgical repair of cleft lip (Yamada et al., 2002). In addition, most of the studies that have assessed facial asymmetry before and after the surgical repair of cleft lip were based on the evaluation of a few facial landmarks around the naso-labial region (Hood et al., 2003; Seidenstricker-kink et al., 2008; Schwenzer-Zimmerer et al., 2008). This landmark-based analysis has its limitations in describing the 3D surface facial asymmetry; the method does not describe the characteristics of the facial surface morphology between these landmarks.

One of the most crucial aspects of analysing facial morphology is to assess surface asymmetry, especially in those regions where it is difficult to digitize reliable landmarks, including the forehead and cheek areas. Iterative closest point (ICP) enables the superimposition (registration) of two models by minimizing the closest point distances between the two surfaces of the models. Facial asymmetry is measured by superimposing the original 3D facial model on its mirror image. The surface-based analysis has the advantage of displaying morphological differences in colour maps that illustrate the

magnitude and direction of the asymmetry. The right side of the face is superimposed on the left side to measure morphological asymmetries of the entire face as well as in specific regions (Alqattan et al., 2013; Ovsenik et al., 2014). The method has been applied to the analysis of cleft lip and palate in various age groups between 5 and 9 years (Djordjevic et al., 2014; Kuijpers et al., 2015; Van Loon et al., 2010). To our knowledge, no 3D surface analysis has been reported in the English language literature to evaluate facial asymmetry before and after surgical repair of cleft lip in infants. This was the aim of our study.

### **Materials and methods:**

Ethics approval to conduct this study was obtained from the REC and R&D committees (reference number: 15/SW/0095). The facial 3D images of 26 UCLP infants were captured before and after the surgical repair of cleft lip. The infants were all Caucasian in origin and all received the same surgical protocol — a modified Millard cheiloplasty and a McComb primary rhinoplasty, which were carried out by the same surgeon. Each infant had a 3D facial image captured 1–2 days before primary surgery and again about 4 months after surgery. The images were captured using the same stereophotogrammetric device — 3dMDface System (3dMD Inc., Atlanta, GA, USA). A professional photographer recorded the images at the NHS Lothian Medical Photography Service, the Royal Hospital for Sick Children, Edinburgh, Scotland, UK. The system was calibrated every morning according to the manufacturer's protocol.

The stereo images of the infants were captured at rest, while the infants were sitting on an elevated infant seat about 1.5 meters away from the camera and were distracted to look upwards above the midpoint of the camera pods, in order to obtain a clear picture of the nose. The system captured the 3D image of the face from the right ear to the left ear with

an acquisition time about 1.5 milliseconds, which was fast enough to avoid image distortion due to change in facial expression or head movement. Two active stereophotogrammetry pods were used to capture the face in 3D. The stereo images were processed by a connected computer to build the 3D model of the face of each patient. The 3D model was saved in obj file format.

**Assessment of facial asymmetry:**

The 3D facial images were imported into virtual reality surface mesh software (VRMesh), allowing peripheral facial regions outside the field of interest to be removed to avoid the confounding noise (Verhoeven et al., 2013). These regions included surfaces beyond the hairline, along the anterior border of the ears, and under the chin (Mcavinchey, 2013).

The symmetries of facial models were assessed and compared before and after the surgical repair of cleft lip. This was achieved by creating a mirror image of each 3D facial model using a reflection plane outside the face (Meyer-Marcotty et al., 2011; Kornreich et al., 2016). Each 3D mirror image was initially aligned to its original model based on nine facial landmarks (right and left exocanthion, right and left endocanthion, pronasale, subnasale, right and left cheilion, sublabialis). Further accurate surface registration of the mirror images to their original ones was achieved by applying an iterative closest point (ICP) algorithm with 0.5 mm tolerance (Figure 1).

Facial asymmetry scores were calculated for the full face, and for seven anatomical regions identified by 25 landmarks, which were digitised on each 3D facial image (Table 1) (Naudi et al., 2013; Shafi et al. 2013; Khambay and Ullah, 2015). The seven facial regions were the

forehead, eyes, nose, upper lip, lower lip, chin, and cheeks. The colour maps illustrated the magnitude of 3D asymmetry of the facial models (Figures 2 and 3).

In a perfectly symmetrical face, the surface difference between the 3D model of the face and its mirror image is zero. The facial asymmetry score was defined as the ninety percentile of the absolute linear distances between the original 3D surface model and its mirror image, for the full face and for the selected anatomical regions. The ninety percentile was used to avoid the noisy data near the boundaries of the surfaces. Paired *t*-tests were applied to assess the changes in asymmetry of the 3D facial models before and after surgery.

Measurements of the asymmetry score were repeated twice, 2 weeks apart, on 15 randomly selected models to assess the reproducibility of the method, using paired *t*-tests at  $p < 0.05$ .

### **Results:**

The mean age of infants was  $3.6 \pm 0.7$  months before surgery and  $8.2 \pm 1.8$  months after surgery. There were no statistically significant differences between the repeated measurements of the asymmetry scores of the ninety percentile for the whole face, and for each facial region ( $p > 0.05$ ).

Table 2 shows the descriptive statistics and the *p*-values for paired *t*-tests of the asymmetry scores of the ninety percentile for the whole face and for the facial regions before and after surgery.



The impact of surgery was quite clear around the upper lip and the nose — the associated symmetry improved significantly. Likewise, the symmetry of the full face showed statistically significant improvement after surgery. Interestingly, surgical repair of the cleft lip had a visible impact on the cheeks. There were no significant differences in the asymmetry scores for the lower lip and chin before and after surgical repair of the cleft lip.

**Discussion:**

This is the first study to investigate regional facial asymmetry before and after the surgical repair of cleft lip. It provides a more accurate display of asymmetry at the surgical site; this is usually masked by the more symmetrical regions of the face when a total facial asymmetry score is the parameter used to measure surgical outcome. Previous investigations have explored asymmetry by dividing the face into geometric horizontal sections using a set of horizontal planes (Djordjevic et al., 2014), or into four geometric regions using a set of vertical and horizontal planes (Kuijpers et al., 2015). These did not demonstrate an understanding of the surgical implications of the repair of cleft lip in terms of specific anatomical structures. The identification of residual regional asymmetries for facial regions as individual anatomical units is not possible using these previously reported methods. Our study attempted to address these deficiencies by subdividing the face into recognised anatomical regions.

In this study, the original 3D facial model and its mirror image were subdivided into seven anatomical regions. The method used for the assessment of facial asymmetry did not depend on head position during image acquisition or on precise identification of facial points. The robustness of the method is dependent on the application of ICP for the

accurate superimposition of the 3D facial images and their mirror images. The method eliminates the need to identify the central midline/middle plane of the face, which is an unreliable guide for quantifying facial asymmetry.

There was a significant improvement in total facial symmetry after surgery (Table 2). Asymmetry of the nose and upper lip decreased significantly following surgery, with these regions showing the maximum impact of primary surgery. This is in agreement with Hood et al., 2003, but the impact of surgery on overall facial morphology, including the cheeks, was not considered in their analysis or in any previous publications.

We report here, for the first time, significant improvement in symmetry of the cheeks following the surgical repair of cleft lip. We believe that this is due to reconstruction of the superficial musculo-aponeurotic system on the cleft side, which was displaced laterally, posteriorly, and inferiorly, and to the readjustment of the oblique running of the orbicularis oris muscle on the cleft side. This is in agreement with the anatomical report provided by Campbell et al., 2010. The primary surgery restored the musculature in the cleft area and improved the muscular balance in the middle part of the face by improving the position of the superficial musculo-aponeurotic system.

Asymmetry of facial regions was previously analysed in 12-year-olds, comparing a cleft and a non-cleft group (Schwenzer-Zimmerer et al., 2008). Their study showed a significant difference in asymmetry between the control group and the UCLP group of the cheek region only. Our study also highlighted residual asymmetries, despite the noticeable improvement in facial appearance after surgery.

Our analysis identified areas of residual dysmorphology, which may require further surgical correction. Not surprisingly, the improvement in symmetry of the forehead, eyes, lower lip, and chin regions were not significant after surgery. Improvement in symmetry following surgery was mainly in the mid-face region, which is in agreement with a previous study (Seidenstricker-kink et al., 2008), which reported that most of the symmetry achieved after surgery was in the area surrounding the cleft lip. However, their study did not clarify the exact anatomical regions that showed improvement in asymmetry because their analysis was based on a set of landmarks that did not consider the whole field of 3D facial morphology.

The surface-based analysis that was applied in this study provided a comprehensive evaluation of 3D facial morphology, evaluated surface characteristics of the face, and overcame the limitations of landmark-based analysis. It would not have been possible to assess the morphology of the cheek based on a single landmark, which is usually digitised at the most prominent point of this region.

This study provided innovative findings regarding the anatomical basis of residual asymmetry. A longitudinal analysis of the presented cases would be useful in exploring the impact of facial growth on postsurgical residual facial asymmetry.

**Conclusion:**

This study showed that primary surgery of unilateral cleft lip improves facial symmetry. There were significant improvements in morphology of the upper lip and nose, while the primary surgery had an indirect effect on the cheeks.

The main outcome of the findings of this innovative study is to inform the required surgical refinement of primary repair of cleft lip in order to minimise facial asymmetry and to guide secondary corrective surgery. We have presented a sensitive tool that could be used for comparative analysis of lip repair at various cleft centres.

**Table 1 Definitions of the sub-divided anatomical regions.**

<b>Anatomical region</b>	<b>Description of the soft tissue area.</b>
<b>Up lip</b>	Subnasale–cheilion (R)–cheilion (L)–stomion superior
<b>Lower lip</b>	Cheilion (R)–cheilion (L)–stomion inferior –sublabiale
<b>Chin</b>	Sublabiale–cheilion (R) perpendicular at level of pogonion–cheilion (L) perpendicular at level of pogonion–gnathion
<b>Right cheek</b>	maxillofrontale (R)–cheilion (R)–gonion (R)–infraorbitale (R)
<b>Left cheek</b>	maxillofrontale (L)–cheilion (L)–gonion (L)–infraorbitale (L)
<b>Nose</b>	Nasion–maxillofrontale (R)–alar curvature point (R)–subnasale)–alar curvature point (L)–maxillofrontale(L)
<b>Forehead</b>	Nasion–superciliare (R)–frontozygomatic(R)–frontotemporale(R)–trichion–frontotemporale(L)–frontozygomatic(L)–superciliare (L)
<b>Right eye</b>	Superciliare (R)–maxillofrontale(R)–infraorbitale(R)–frontozygomatic(R)
<b>Left eye</b>	Superciliare (L)–maxillofrontale(L)–infraorbitale(L)–frontozygomatic(L)

**Table 2 Descriptive statistics and  $p$ -values for paired  $t$ -tests for the ninety percentile of the absolute mean distance (in millimetres) between the original and mirror images for the whole face and the anatomical regions.**

	Before surgery				After surgery				$p$ -value
	Mean	SD	Max	Std error mean	Mean	SD	Max	Std error mean	
<b>Whole face</b>	0.61	0.19	1.87	0.03	0.52	0.15	1.62	0.02	0.004 (S)
<b>Nose</b>	2.04	0.85	4.94	0.16	1.02	0.64	2.87	0.12	0.000 (S)
<b>Upper lip</b>	2.30	0.62	4.89	0.12	1.13	0.40	2.73	0.08	0.000 (S)
<b>Lower lip</b>	0.92	0.45	2.49	0.08	0.80	0.26	2.30	0.05	0.185
<b>Chin</b>	0.64	0.24	1.92	0.04	0.58	0.23	1.76	0.04	0.229
<b>Forehead</b>	0.66	0.37	2.71	0.07	0.60	0.27	2.01	0.05	0.509
<b>Cheeks</b>	1.09	0.40	3.42	0.07	0.88	0.37	2.81	0.07	0.015 (S)
<b>Eyes</b>	0.70	0.34	2.38	0.06	0.62	0.25	2.00	0.04	0.354

**Figure legends:**

**Figure 1:** Surface-based registration of an original 3D facial model (top left) and its mirror copy (top right), and the superimposition of the two images to assess facial asymmetry

**Figure 2:** Colour map of UCLP before surgery (A) and after surgical repair of the cleft lip (B)

**Figure 3:** Colour map showing differences between original and mirror images of a preoperative 3D facial model of UCLP, divided into seven anatomical regions: forehead, eyes, nose, cheeks, upper lip, lower lip, and chin

#### References:

- Alqattan M, Djordjevic J, Zhurov AI, Richmond S. Comparison between landmark and surface-based three-dimensional analyses of facial asymmetry in adults. *Eu J Orthod* 37: 1–12, 2013.
- Bell A, Tsz-Wai RL, Brown D, Bowman AW, Siebert JP, Simmons DR, Millet DT, Ayoub AF. Three-dimensional assessment of facial appearance following surgical repair of unilateral cleft lip and palate. *Cleft Palat-Craniofac J* 51(4): 462–471, 2014.
- Bilwatsch S, Kramer M, Haeusler G, Schuster M, Wurm J, Vairaktaris, E, Nkenke E. Nasolabial symmetry following Tennison–Randall lip repair: a three-dimensional approach in 10-year-old patients with unilateral clefts of lip, alveolus and palate. *J Cranio-Maxillofac Surg* 34: 253–262, 2006.
- Bugaighis I, Mattick CR, Tiddeman B, Hobson, R. 3D asymmetry of operated children with oral clefts. *Orthod Craniofac Res* 17: 27–37, 2013.
- Campbell A, Costello BJ, Ruiz RL. Cleft lip and palate surgery: an update of clinical outcomes for primary repair. *Oral Maxillofac Surg Clin North Am* 22(1): 43–58, 2010.
- Djordjevic J, Lewis BM, Donaghy CE, Zhurov AI, Knox J, Hunter L, Richmond S. Facial shape and asymmetry in 5-year-old children with repaired unilateral cleft lip and/or palate: an

- exploratory study using laser scanning. *Eu J Orthod* 36(5): 497–505, 2014.
- Hood CA, Bock M, Hosey MT, Bowman A, Ayoub AF. Facial asymmetry — 3D assessment of infants with cleft lip & palate. *Int J Paed Dent* 13(6): 404–410, 2003.
- Khambay B, Ullah R. Current methods of assessing the accuracy of three-dimensional soft tissue facial predictions: technical and clinical considerations. *Int J Oral Maxillofac Surg* 44(1): 132–8, 2015.
- Kornreich D, Mitchell AA, Webb BD, Cristian I, Jabs EW. Quantitative assessment of facial asymmetry using three-dimensional surface imaging in adults: validating the precision and repeatability of a global approach. *Cleft Palate-Craniofac J* 53(1): 126–131, 2016.
- Kuijpers MA, Desmedt DJ, Nada RM, Bergé SJ, Fudalej PS, Maal TJ. Regional facial asymmetries in unilateral orofacial clefts. *Eu J Orthod* 37(6): 636–642, 2015.
- Mcavinchey G. The perception of facial asymmetry. University of Birmingham; 2013. Thesis.
- Meyer-Marcotty P, Kochel J, Boehm H, Linz C, Klammert U, Stellzig-Eisenhauer A. Face perception in patients with unilateral cleft lip and palate and patients with severe Class III malocclusion compared to controls. *J Cranio-Maxillofac Surg* 39(3): 158–163, 2011.
- Naudi KB, Benramadan R, Brocklebank L, Ju X, Khambay B, Ayoub A. The virtual human face: superimposing the simultaneously captured 3D photorealistic skin surface of the face on the untextured skin image of the CBCT scan. *Int J Oral Maxillofac Surg* 42: 393–400, 2013.
- Ovsenik M, Perinetti G, Zhurov A, Richmond S, Primozic J. Three-dimensional assessment of facial asymmetry among pre-pubertal class III subjects: a controlled study. *Eu J Orthod* 36(4): 431–435, 2014.
- Ras F, Habets LLMH, Van Ginkel FC, Prah-Andersen B. Facial left right dominance in three-dimensional evaluation of facial asymmetry in cleft lip and palate. *Cleft Palate-*

Craniofac J 31: 116–121, 1994.

Schwenzer-Zimmerer K, Chaitidis D, Berg-Boerner I, Krol Z, Kovacs L, Schwenzer NF,

Zimmerer S, Holberg C, Zeilhofer H. Quantitative 3D soft tissue analysis of symmetry prior to and after unilateral cleft lip repair compared with non-cleft persons J Cranio-Maxillofac Surg 36(8): 431–438, 2008.

Seidenstricker-kink LM, Becker DB, Govier DP, DeLeon VB, Lo LJ, Kane AA. Comparative osseous and soft tissue morphology following cleft lip repair. Cleft Palate Craniofac J 45(5): 511– 517, 2008.

Shafi MI, Ayoub A, Ju X, Khambay B. The accuracy of three-dimensional prediction planning for the surgical correction of facial deformities using Maxilim. Int J Oral Maxillofac Surg 42(7): 801–806, 2013.

Stauber I, Vairaktaris E, Holst A, Schuster M, Hirschfelder U, Neukam F W, Nkenke E. Three-dimensional analysis of facial asymmetry in cleft lip and palate patients using optical surface data. J Orofac Orthop 69(4): 268–282, 2008.

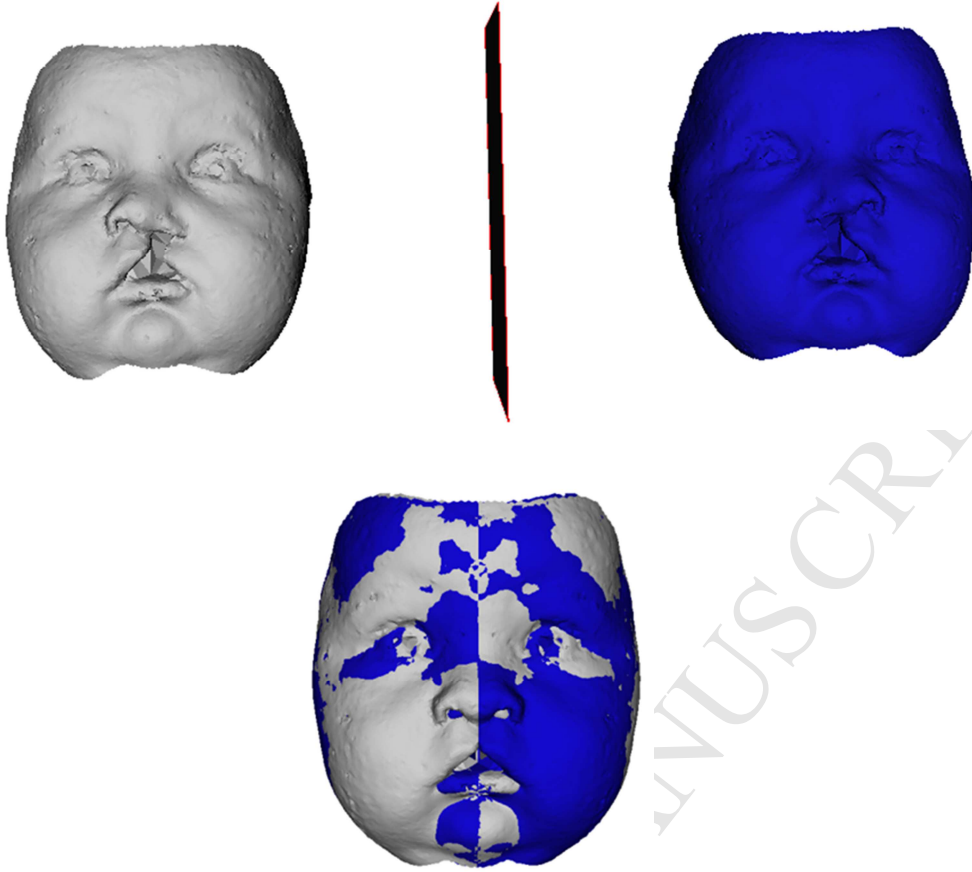
Van Loon B, Maal TJ, Plooi J, Ingels KJ, Borstlap WA, Kuijpers-Jagtman AM, Spauwen PH, Bergé SJ. 3D stereophotogrammetric assessment of pre- and postoperative volumetric changes in the cleft lip and palate nose. Int J Oral Maxillofac Surg 39(6): 534–540, 2010.

Verhoeven TJ, Copen C, Barkhuysen R, Bronkhorst EM, Merckx MAW, Bergé SJ, Maal TJJ. Three dimensional evaluation of facial asymmetry after mandibular reconstruction: validation of a new method using stereophotogrammetry. Int J Oral Maxillofac Surg 42(1): 19–25, 2013.

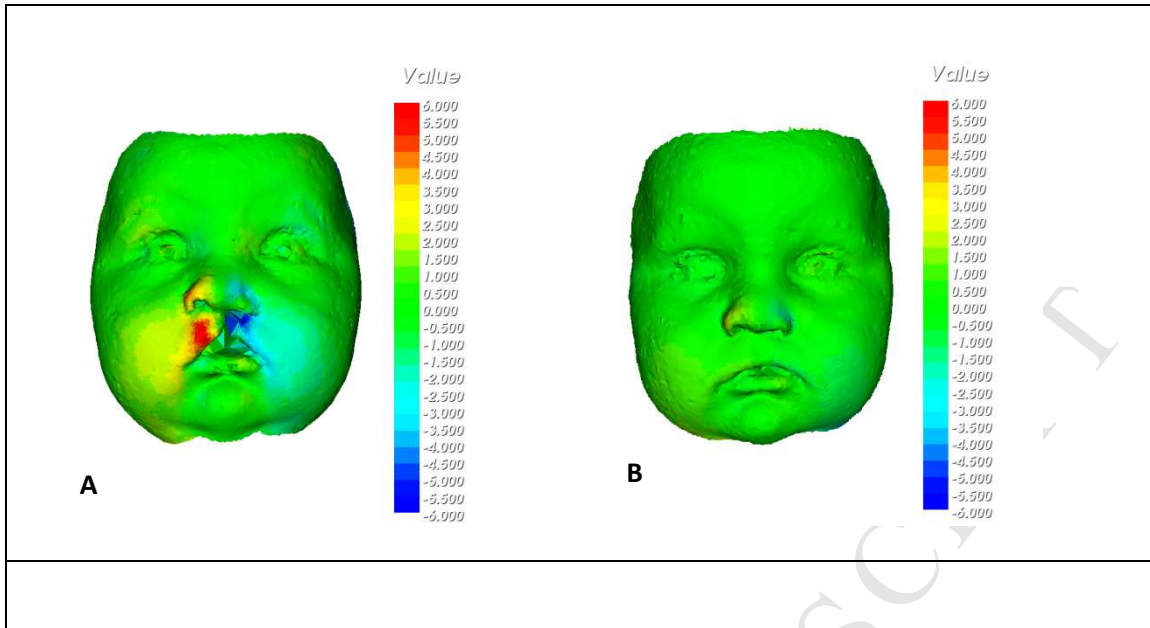
Yamada T, Mori Y, Minami K, Mishima K, Tsukamoto Y. Surgical results of primary lip repair using the triangular flap method for the treatment of complete unilateral cleft lip and palate: a three-dimensional study in infants to four-year-old children. Cleft Palate-

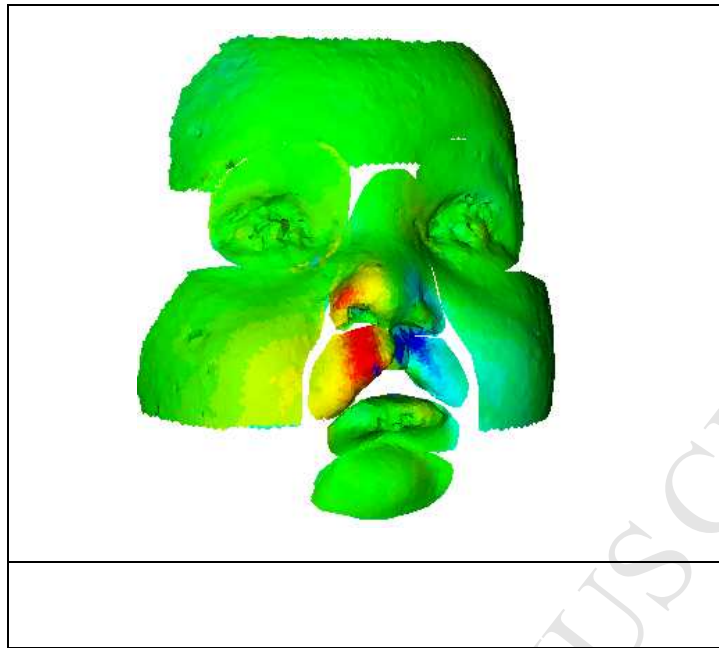


ACCEPTED MANUSCRIPT



ACCEPTED MANUSCRIPT





ACCEPTED MANUSCRIPT