

Keywords: choroidal nevi; uveal melanoma; GNAQ; GNA11; YAP; droplet digital PCR; mutation

GNAQ and GNA11 mutations and downstream YAP activation in choroidal nevi

M J C Vader^{1,2}, M C Madigan², M Versluis¹, H M Suleiman¹, G Gezgin¹, N A Gruis³, J J Out-Luiting³, W Bergman³, R M Verdijk⁴, M J Jager¹ and P A van der Velden^{*,1}

¹Department of Ophthalmology, LUMC, Postbus 9600, Leiden 2300 RC, The Netherlands; ²Save Sight Institute and Department of Ophthalmology, University of Sydney, and School of Optometry and Vision Science, University of New South Wales, 8 Macquarie St, Sydney, NSW 2000, Australia; ³Department of Dermatology, LUMC, Postbus 9600, Leiden 2300 RC, The Netherlands and ⁴Department of Pathology, Section Ophthalmic Pathology, Erasmus MC University Medical Center, PO-Box 2040, Rotterdam 3000 CA, The Netherlands

Background: Mutations in *GNAQ/11* genes are considered an early event in the development of uveal melanoma that may derive from a pre-existing nevus. The Hippo pathway, by way of YAP activation, rather than MAP kinase, has a role in the oncogenic capacity of *GNAQ/11* mutations.

Methods: We investigated 16 nevi from 13 human eyes for driver *GNAQ/11* mutations using droplet digital PCR and determined whether nevi are clonal by quantifying mutant nevus cell fractions. Immunohistochemistry was performed on 15 nevi to analyse YAP activation.

Results: For 15 out of 16 nevi, a *GNAQ/11* mutation was detected in the nevus cells albeit at a low frequency with a median of 13%. Nuclear YAP, a transcriptional co-activator in the Hippo tumour-suppressor pathway, was detected in 14/15 nevi.

Conclusions: Our analysis suggests that a mutation in *GNAQ/11* occurs in a subset of choroidal nevus cells. We hypothesise that *GNAQ/11* mutant-driven extracellular mitogenic signalling involving YAP activation leads to accumulation of wild-type nevus cells.

Similar to cutaneous melanoma (CM), uveal melanoma (UM) can develop *de novo* or from a pre-existing nevus (Figure 1). Uveal nevi most commonly occur in the choroid and are seen in 6.5–30% of the population (Sumich *et al*, 1998; Baderca *et al*, 2013). However, transformation from a choroidal nevus to a UM requires complex genetic aberrations (gain of chromosome 8q/6p, loss of chromosome 3, absence of *BAP1*), and has been reported in only about 1 out of 9000 people (Singh *et al*, 2005). We hypothesise that a choroidal nevus, as a potential precursor of UM, may already harbour clonal driver mutations, just as many cutaneous nevi are reported to present the typical V600E *BRAF* mutation associated with CM (Pollock *et al*, 2003; Shain *et al*, 2015). Mutations in *BRAF* are found in about 66% of CM while 83–95% of UM carry a mutation in either the *GNAQ* or *GNA11* gene (Davies *et al*, 2002; Van Raamsdonk *et al*, 2008, 2010). Although MAPK (mitogen-

activated protein kinase) signalling is activated by the *BRAF* V600E mutation, the oncogenic effect of *GNAQ/11* is still to be defined. A recent publication showed that MAPK activation has a minimal role in the oncogenic potential of *GNAQ* mutations (Mouti *et al*, 2016); however, a central role has been attributed to the YAP/Hippo pathway. YAP (Yes-associated protein) has not only a role in homeostasis and organ size during stress, but also in cancer several oncogenes and tumour suppressor genes converge on YAP (Overholtzer *et al*, 2006). In a sparse cell environment, YAP is expressed in cell nuclei-promoting gene expression. Conversely, in a dense cell environment, YAP is maintained in the cytoplasm and inhibits cell growth. Overall, tissue growth is controlled through the inhibition of YAP and its co-factors. Yu *et al* showed that *GNAQ/11* mutant activity is controlled by YAP activation (nuclear YAP expression) in several UM cell lines (Yu *et al*, 2014, 2015).

*Correspondence: Dr PA van der Velden; E-mail: P.A.van_der_Velden@lumc.nl

Received 21 April 2017; revised 10 July 2017; accepted 13 July 2017; published online 15 August 2017

© 2017 Cancer Research UK. All rights reserved 0007–0920/17

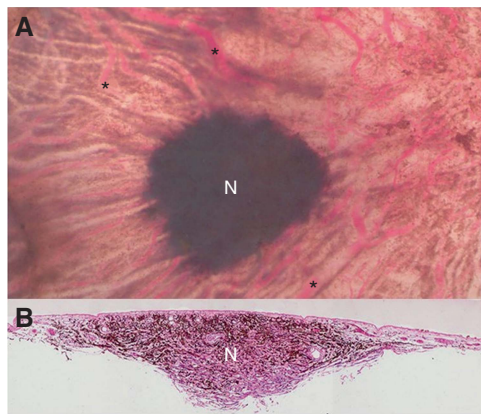

Figure 1. Clinical and histopathological manifestation of a choroidal nevus. **(A)** Choroidal nevus (N) (72 year old, female). Retina and RPE removed; choroidal vessels visible (asterisk). Size ~4 mm diameter. **(B)** Section through nevus showed thickened area of pigmented nevus cells and large blood vessels at the lesion's edge (arrows) (periodic acid-Schiff stain).

In this study, we analysed the frequency of *GNAQ/11* mutations in choroidal nevi and analysed YAP activation as a possible downstream effect.

MATERIALS AND METHODS

From post-mortem human eyes obtained from the Lions NSW Eye Bank (with consent and Human Research Ethics Committee approval), choroidal pigmented lesions were identified, dissected and tissue was paraffin-embedded (Supplementary Materials and Methods) Dermal nevus tissues were obtained from the nevus biobank of the Department of Dermatology, Leiden University Medical Centre.

DNA extraction from nevi. DNA was extracted from formalin-fixed and paraffin-embedded tissue of 16 choroidal nevi using the ReliaPrep FFPE gDNA Miniprep System (Promega Corp, Madison, WI, USA), following the manufacturer's instructions. For DNA extraction from dermal nevi, 20 tissue sections of 25 μ m per nevus were used.

Digital PCR. *GNAQ/11* mutations (*GNAQ* Q209L, *GNAQ* Q209P, *GNAQ* R1830, *GNA11* Q209L and *GNA11* R183C) and the *BRAF* (V600E) mutation were analysed in choroidal nevi and dermal nevi using digital PCR (Versluis *et al*, 2015). For copy number analysis of chromosome 3 and 8q, essays for PPARG and PTK2 were used. Proprietary probes and primers (Bio-Rad Laboratories, Inc., Hercules, CA, USA) were used.

Immunohistochemistry. Immunohistochemistry was performed on paraffin sections of 15 choroidal nevi using the Ventana Benchmark Ultra automated staining system (Ventana Medical Systems Inc, Tuscon, AZ, USA), following the protocol described previously (van Essen *et al*, 2014). Anti-Melan-A antibody (Ventana, 790-2290), YAP antibody (Cell Signalling Technology #4912) and the BAP1 antibody (Santa Cruz, SC-28383, Dallas, TX, USA) were used as primary antibodies. The UltraView Universal Alkaline Phosphatase Red detection kit, (Ventana Ref.: 760-501) was used in combination with target amplification (Ventana ref.: 760-080). The slides were counterstained with haematoxylin II for 8 min, followed by an additional counterstaining with blueing reagent (Ventana medical systems Inc.). Due to red chromogen staining on thin tissue slides, we were able to detect positive staining in pigmented cells.

See also Supplementary Materials and Methods.

RESULTS

In the current study, 16 nevi from 13 post-mortem eyes of 12 donors were analysed for *GNAQ/11* hotspot mutations. One pair of donor eyes presented nevi in both the right and the left eye (nevi 11A-C), with the left eye containing two nevi (nevi 11A-B). Two other eyes also contained two nevi (nevi 6 and 12) (Table 1).

Droplet digital PCR showed that 15 of the 16 choroidal nevi presented one out of the three *GNAQ/11* hotspot mutations (Table 1). Mutations in *GNAQ* and *GNA11* were distributed equally in this cohort, similar to our observations in UM (Versluis *et al*, 2015). None of the nevi showed evidence of multiple mutations. Nevus 12B did not carry either of the *GNAQ/11* hotspot mutations. Different nevi from the same eye (nevi 6A-B, 11A-B and 12A-B) never shared the same hotspot mutation. The nevus from the right eye (nevus 11C) of the donor who had nevi in both eyes contained the same mutation as one of the nevi in the left eye (nevus 11B) (Table 1). The fraction of mutated nevus cells varied from 1–55% with a median of 13%. Immunostaining revealed that over 95% of the cells in 12 nevi were Melan-A positive (Table 1), indicating that the tissue examined represented primarily nevus cells with some stromal cells (Supplementary Figure 1B). Four nevi could not be determined for Melan-A due to lack of material.

We examined tissues for the presence of chromosome aberrations as potential progression markers and as the absence of *BAP1* is correlated with monosomy 3 in UM, we also performed immunohistochemistry for *BAP1* as another progression marker. (van Essen *et al*, 2014) Neither gain of chromosome 8q/chromosome 6p nor loss of chromosome 3 was observed in the three nevi with the highest mutation fraction (nevi 11A-C) (not shown). The eight nevi stained for *BAP1* showed no loss of *BAP1* expression (Table 1).

We determined the presence of *GNAQ/11* and *BRAF* mutations in dermal cutaneous nevi ($n=5$) as a control. None of which contained a *GNAQ/11* hotspot mutation; instead, four out of five dermal nevi harboured the *BRAF* V600E mutation with a median mutant fraction of 45%. The mutant fraction of dermal nevi is in marked contrast with the 13% *GNAQ/11* mutant cells in choroidal nevi and emphasises potential differences between *BRAF* and *GNAQ/11*-driven nevus development. This suggests besides that either other genetic factors are involved or that *GNAQ/11* mutant clones can also drive the proliferation of the wild-type melanocytes in the nevus. The latter mechanism could be explained by YAP activation initiated by *GNAQ/11*-mutated cells, which could stimulate wild-type cells to proliferate.

We found heterogeneous YAP nuclear immunostaining in 14 out of 15 choroidal nevi, with no cytoplasmic staining (Table 1 and Figure 1). Although YAP staining tended to be more abundant in nevi with a high mutant fraction, there was no significant correlation between the percentage of positive YAP cells and the mutant cell fraction (Table 1, $P=0.334$, Spearman correlation coefficient). In the only nevus (12B) without a *GNAQ/11* mutation, positive YAP expression in nuclei was also detected. This indicates that YAP activation may occur independently of the presence of a *GNAQ/11* mutation. Normal choroidal melanocytes were negative for YAP staining, as was retinal tissue. Sporadically a retinal pigment epithelium cell was found with positive YAP staining (Figure 2).

DISCUSSION

As hypothesised, human choroidal nevi did harbour a *GNAQ/11* mutation. No other mutations were found, which suggests that those mutations are clonal. The low *GNAQ/11* mutant fraction in choroidal nevi however presents a paradox for *GNAQ/11*

Table 1. Molecular analysis of choroidal nevus

Nevus	Sex, age (years)	GNA11 Q209L ^a	GNAQ Q209P ^a	GNAQ Q209L ^a	Mutant cells ^b (%)	YAP-positive cells ^c (%)	Melan-A ^d	BAP1 ^e
1	F, 90		+		10	ND	ND	ND
2	F, 79	+			1.1	1.8	>95% Positive	ND
3	F, 62			+	14	6.6	>95% Positive	ND
4	F, 73	+			3	33.1	>95% Positive	Positive
5	F, 87		+		5.8	0	>95% Positive	ND
^f 6A	F, 86		+		16	27.9	>95% Positive	ND
6B	F, 86	+			6.6	44.1	ND	ND
7	F, 59			+	6.2	23.2	ND	ND
8	M, 59	+			12	56.4	>95% Positive	Positive
9	M, 59	+			17	0.4	ND	ND
10	F, 80			+	5.8	47	>95% Positive	Positive
^f 11A	M, 54		+		40	18.6	>95% Positive	Positive
11B	M, 54	+			36	48.2	>95% Positive	Positive
^g 11C	M, 54	+			55	81.1	>95% Positive	Positive
^f 12A	F, 77	+			13	68.5	>95% Positive	Positive
12B	F, 77				0	22.0	>95% Positive	Positive

Abbreviation: ND, not to be determined.

^aGNAQ/11 mutations.

^bMutant cells: fraction of cells containing a hotspot mutation.

^cPercentage of cells positive for YAP staining per nevus.

^dMelan-A: 11 nevi stained positive for Melan-A (Supplementary Figure 1B). In four nevi, expression could ND due to limited material.

^eBAP1: eight nevi stained positive for BAP1. Eight nevi could not be determined due to limited material.

^fTwo nevi detected in one eye indicated by A and B

^gNevus in second eye of donor.

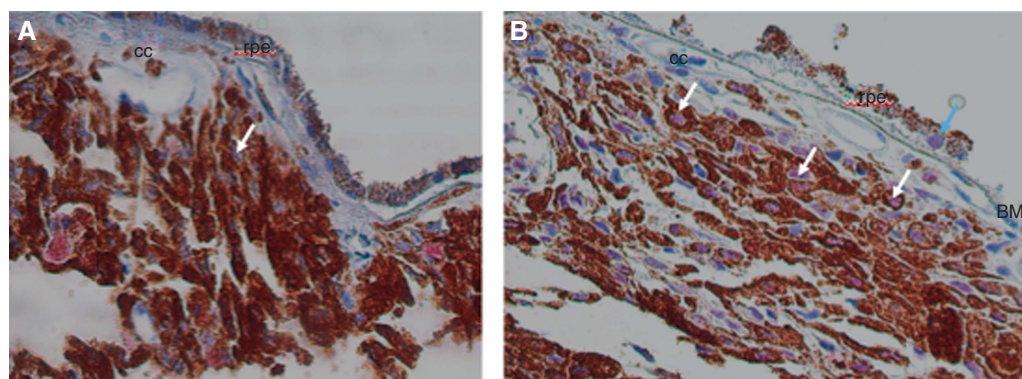


Figure 2. YAP staining in human choroidal nevi. (A) Nevus 2 with an average of 1.8% YAP-positive cells. A nevus cell with a negative, blue nucleus is seen (white arrow). Magnification of objective $\times 40$. **(B)** Nevus 12A with an average of 13% YAP-positive cells. YAP+ nuclei in nevus cells are visible (pink, white arrows). A rare RPE cell is found with nuclear YAP staining (blue arrow). Magnification of objective $\times 40$. BM = Bruch's membrane; cc = choriocapillaris; rpe = retina pigment epithelium.

oncogene function that may be explained by aberrant YAP signalling in choroidal nevi. The oncogenic potential of YAP is broadly recognised and high levels of YAP expression in the nucleus have been associated with several malignancies (Overholtzer *et al*, 2006). Yu *et al* (2014) described a positive correlation between mutant *GNAQ/11* and aberrant YAP activation (nuclear expression) in UM cell lines. In our study, the nevi with a *GNAQ/11* mutation all showed nuclear YAP, confirming this positive correlation between mutant *GNAQ/11* and YAP activation. However, this correlation was not significant. Moreover, the one nevus without *GNAQ/11* mutations still possessed YAP activity in the nucleus. This is in accordance with the results of Yu *et al* who also found evidence of nuclear YAP activity in wild-type UM cell lines (Mel285 and Mel290), suggesting that YAP activation is not solely dependent on *GNAQ/11* mutations, and that other factors may contribute to YAP activity (Yu *et al*, 2014).

In summary, we found that *GNAQ/11* mutant clones make up a fraction of the cells in choroidal nevi. Nevus cells are furthermore characterised by heterogeneous YAP expression. Combined

GNAQ/11 and YAP may constitute a putative precursor tumour pathway with an activated oncogene (*GNAQ/11*) and downstream effector (YAP).

ACKNOWLEDGEMENTS

We acknowledge Frank de Gruijl for helpful discussion. This work was supported by grants from the Nelly Reef Fund, the Leiden Ophthalmology Subsidy Fund (03121401.loof.madeleine vader) and the Dutch Cancer Society (KWF: UL2011-4991).

CONFLICT OF INTEREST

The authors declare no conflict of interest.

REFERENCES

- Baderca F, Solovan C, Boghian L (2013) Epidemiological and morphological data of ocular melanocytic lesions. *Rom J Morphol Embryol* **54**(1): 77–83.
- Davies H, Bignell GR, Cox C, Stephens P, Edkins S, Clegg S, Teague J, Woffendin H, Garnett MJ, Bottomley W, Davis N, Dicks E, Ewing R, Floyd Y, Gray K, Hall S, Hawes R, Hughes J, Kosmidou V, Menzies A, Mould C, Parker A, Stevens C, Watt S, Hooper S, Wilson R, Jayatilake H, Gusterson BA, Cooper C, Shipley J, Hargrave D, Pritchard-Jones K, Maitland N, Chenevix-Trench G, Riggins GJ, Bigner DD, Palmieri G, Cossu A, Flanagan A, Nicholson A, Ho JW, Leung SY, Yuen ST, Weber BL, Seigler HF, Darrow TL, Paterson H, Marais R, Marshall CJ, Wooster R, Stratton MR, Futreal PA (2002) Mutations of the BRAF gene in human cancer. *Nature* **417**(6892): 949–954.
- Mouti MA, Dee C, Coupland SE, Hurlstone AF (2016) Minimal contribution of ERK1/2-MAPK signalling towards the maintenance of oncogenic GNAQQ209P-driven uveal melanomas in zebrafish. *Oncotarget* **7**(26): 39654–39670.
- Overholtzer M, Zhang J, Smolen GA, Muir B, Li W, Sgroi DC, Deng CX, Brugge JS, Haber DA (2006) Transforming properties of YAP, a candidate oncogene on the chromosome 11q22 amplicon. *Proc Natl Acad Sci USA* **103**(33): 12405–12410.
- Pollock PM, Harper UL, Hansen KS, Yudt LM, Stark M, Robbins CM, Moses TY, Hostetter G, Wagner U, Kakareka J, Salem G, Pohida T, Heenan P, Duray P, Kallioniemi O, Hayward NK, Trent JM, Meltzer PS (2003) High frequency of BRAF mutations in nevi. *Nat Genet* **33**(1): 19–20.
- Shain AH, Yeh I, Kovalyshyn I, Sriharan A, Talevich E, Gagnon A, Dummer R, North J, Pincus L, Ruben B, Rickaby W, D'Arrigo C, Robson A, Bastian BC (2015) The genetic evolution of melanoma from precursor lesions. *N Engl J Med* **373**(20): 1926–1936.
- Singh AD, Kalyani P, Topham A (2005) Estimating the risk of malignant transformation of a choroidal nevus. *Ophthalmology* **112**(10): 1784–1789.
- Sumich P, Mitchell P, Wang JJ (1998) Choroidal nevi in a white population: the Blue Mountains Eye Study. *Arch Ophthalmol* **116**(5): 645–650.
- van Essen TH, van Pelt SI, Versluis M, Bronkhorst IH, van Duinen SG, Marinkovic M, Kroes WG, Ruivenkamp CA, Shukla S, de KA, Kilic E, Harbour JW, Luyten GP, van der Velden PA, Verdijk RM, Jager MJ (2014) Prognostic parameters in uveal melanoma and their association with BAP1 expression. *Br J Ophthalmol* **98**(12): 1738–1743.
- Van Raamsdonk CD, Bezroukove V, Green G, Bauer J, Gaugler L, O'Brien JM, Simpson EM, Barsh GS, Bastian BC (2008) Frequent somatic mutations of GNAQ in uveal melanoma and blue naevi. *Nature* **457**(7229): 599–602.
- Van Raamsdonk CD, Griewank KG, Crosby MB, Garrido MC, Vemula S, Wiesner T, Obenaus AC, Wackernagel W, Green G, Bouvier N, Sozen MM, Baimukanova G, Roy R, Heguy A, Dolgalev I, Khanin R, Busam K, Speicher MR, O'Brien J, Bastian BC (2010) Mutations in GNA11 in uveal melanoma. *N Engl J Med* **363**(23): 2191–2199.
- Versluis M, de Lange MJ, van Pelt SI, Ruivenkamp CA, Kroes WG, Cao J, Jager MJ, Luyten GP, van der Velden PA (2015) Digital PCR validates 8q dosage as prognostic tool in uveal melanoma. *PLoS One* **10**(3): e0116371.
- Yu FX, Luo J, Mo JS, Liu G, Kim YC, Meng Z, Zhao L, Peyman G, Ouyang H, Jiang W, Zhao J, Chen X, Zhang L, Wang CY, Bastian BC, Zhang K, Guan KL (2014) Mutant Gq/11 promote uveal melanoma tumorigenesis by activating YAP. *Cancer Cell* **25**(6): 822–830.
- Yu FX, Zhao B, Guan KL (2015) Hippo pathway in organ size control, tissue homeostasis, and cancer. *Cell* **163**(4): 811–828.

This work is published under the standard license to publish agreement. After 12 months the work will become freely available and the license terms will switch to a Creative Commons Attribution-NonCommercial-Share Alike 4.0 Unported License.

Supplementary Information accompanies this paper on British Journal of Cancer website (<http://www.nature.com/bjc>)