

## **The value of computed tomography in detecting distal radio ulnar joint instability after a distal radius fracture**

**R. H. van Leerdam<sup>1,\*</sup>, M. M. E. Wijffels<sup>1,\*</sup>, M. Reijnierse<sup>2</sup>, W. Stomp<sup>2</sup>, P. Krijnen<sup>1</sup> and I. B. Schipper<sup>1</sup>**

<sup>1</sup>Leiden University Medical Center  
Department of Surgery-Traumatology

<sup>2</sup>Leiden University Medical Center,  
Department of Radiology,

### **Abstract**

This study evaluated the value of computed tomography scans for the diagnosis of distal radioulnar joint instability. A total of 46 patients, conservatively treated for a unilateral distal radius fracture, were evaluated. Clinical instability was tested using the stress test and clunk test. A computed tomography scan of both wrists was performed in pronation and supination. Two independent observers reviewed the computed tomography scans using: the radioulnar line, subluxation ratio, epicentre and radioulnar ratio methods. Radiological distal radioulnar joint instability was assessed by comparing the measurements of the injured wrist with those of the contralateral uninjured wrists. A total of 22 patients had clinical instability of whom 12 suffered from pain in the injured wrist. Distal radioulnar joint instability was diagnosed on computed tomography in 29 patients. Reliability analysis between clinical and radiological evaluations showed at best moderate, but generally poor agreement. The diagnostic ability of computed tomography for identifying distal radioulnar joint instability seems limited.

### **Introduction**

Distal radius fractures are common and comprise 17% of all adult fractures (Court-Brown and Caesar, 2006). In the Netherlands, the incidence is 400 fractures per 100,000 people per year (Oskam et al., 1998) and is increasing due to the ageing population. In the literature, distal radioulnar joint (DRUJ) instability, due to or in combination with, a distal radius fracture has been recognized as a potential complication (Lindau et al., 2000) that may cause long-lasting pain and restricted range of motion. The incidence of DRUJ instability after a distal radius fracture is reported to be between 10%–40% (Geissler et al., 1996; Lindau et al., 2000; Stoffelen et al., 1998).

Clinical determination of the diagnosis of DRUJ instability remains a challenge (Pickering et al., 2016), due to the low sensitivity, specificity and reproducibility of available clinical tests (Wijffels et al., 2012). Despite these deficiencies, the stress test and clunk test are generally accepted clinical tests for evaluation of DRUJ instability (Jupiter, 2009; Nakamura et al., 1997).

Various radiological modalities may be used if physical examination is inconclusive, although these all have limitations (Lindau et al., 2000; May et al., 2002; Szabo, 2006). Conventional radiography of the wrist has a low sensitivity for detecting DRUJ pathology (Pan et al., 2003). Arthrography was of limited direct value and has been replaced by magnetic resonance imaging (Levinsohn et al., 1991). The role of magnetic resonance imaging in detecting DRUJ translation is unclear (Anderson et al., 2008). Computed tomography (CT) seems promising for evaluating DRUJ translation (Kim and Park, 2008; Mino et al., 1985), but the most reliable measuring method is still a matter of debate. Several methods for diagnosing DRUJ translation using CT have been proposed. Mino et al. (1985) were the first to describe CT criteria for DRUJ translation. These were later modified by Nakamura et al. (1996) and supplemented by Lo et al. (2001) and Wechsler et al. (1987). Different guidelines for diagnosing DRUJ instability, based on their measurement techniques, were suggested, all lacking hard criteria for standardization. The absence of pre-determined normal values renders definite statements concerning CT-diagnosed DRUJ instability even more difficult.

The agreement between clinical findings and DRUJ translation on CT has not been evaluated in detail. To date, only Kim and Park (2008) studied this in a small group of patients after a short period of follow-up. In this study, we therefore aimed to evaluate the value of CT scans for the diagnosis of DRUJ instability, comparing post-traumatic to contralateral, normal wrists. In addition, the level of agreement between CT findings regarding DRUJ dislocation and clinical DRUJ instability tests was analysed.

## **Materials and methods**

### *Patients*

The institutional medical ethics review board approved this study. All adults that had been conservatively treated for a unilateral distal radius fracture in our hospital between May 2008 and February 2010 were identified from the hospital records. Patients with unstable triangular fibrocartilage complex (TFCC) lesions were not excluded. No further analysis was done regarding the TFCC status. Patients with systemic diseases affecting bones and/or joints, patients with contralateral wrist injury and patients who were unable to give informed consent were excluded.

Eligible patients received an invitation letter for a study visit in our clinic and were included for analysis after they had provided written informed consent.

### *Clinical evaluation*

The patients' wrists were clinically evaluated for DRUJ instability by an experienced trauma surgeon, who had not been involved in the initial treatment and was blinded for the injured side. Clinical instability was determined using both the stress test and clunk test.

Clinical DRUJ instability can be defined as static or dynamic, both to be diagnosed by individual tests. Static DRUJ instability was defined as the existence of pathological movement in the DRUJ when stressed without rotation of the forearm. This can be determined using the stress test. To perform the stress test, the wrist is held in supinated and pronated positions, while the physician attempts to manipulate the distal ulna in dorsal and volar directions. A positive stress test is

defined by more laxity when compared with the uninjured side (Kleinman, 2007).

Dynamic instability is defined as pathologic movement of the ulna relative to the radius during pronosupination and is tested using the clunk test (Jupiter, 2009). During the clunk test the distal ulna is compressed to the radius between thumb and index finger of the physician, with simultaneous passive pronosupination. The clunk test is considered positive if a 'clunk' is palpable for either the patient or examiner (Jupiter, 2009).

Pain at rest and during movement was scored on a visual analogue scale (VAS) ranging from 0 (no pain) to 100 (worst imaginable pain) (Huskisson, 1974).

### *Radiological evaluation*

First, an experienced trauma surgeon (MW) classified the distal radius fractures on the trauma radiographs according to the AO Comprehensive Classification of Fractures (Müller et al., 1991). For further radiological evaluation, CT scans of both wrists were obtained using an Aquilion One (Toshiba Medical Systems) CT-scanner with the patient in prone position with both arms above the head and extended elbows, and with both wrists first in maximal pronation and, during the second run, in maximal supination. Trained radiology assistants subsequently performed post-processing, which included 2 mm coronal and sagittal reformats, as well as 2mm axial reformats perpendicular to the axis of the styloid process, for each wrist separately. Finally, two trained observers (MW and WS), who were blinded for the clinical results, independently assessed DRUJ translation on the CT scans according to the radioulnar line method, subluxation ratio method, epicentre method and radioulnar ratio method (Kim and Park, 2008; Lo et al., 2001; Park and Kim, 2008). All methods quantify radio-ulnar translation by evaluating the position of the ulna relative to the radius resulting in a ratio (Figures 1 to 4). Prior to the study measurements, the two observers scored and discussed 10 CT-scans of wrists of patients not included in this study, for training purposes. For each method, the mean of the observers' measurements was calculated for both the injured and the uninjured side. DRUJ instability on the CT scan was defined in two ways. First, the mean translation measurement of the injured wrist was compared with the mean measurements of all the uninjured wrists. The result was determined to show 'no instability' when the mean measurement was within two standard deviations of the normal range for the specific method. Second, the results of the injured wrist were compared specifically with the measurements of the patient's non-injured wrist. DRUJ instability was considered present if the mean measurement for the injured wrist was outside the range of mean measurements (of the two observers) for that patient's own non-injured wrist.

### *Statistical analysis*

Agreement on presence of DRUJ instability between the clinical test and CT measurements was evaluated using Cohen's Kappa. Kappa values were interpreted according to Landis and Koch (1977) with values below 0 indicating no agreement; 0.01 to 0.20, slight agreement; 0.21 to 0.40, fair agreement; 0.41 to 0.60, moderate agreement; 0.61 to 0.80, substantial agreement; and more than 0.81, almost perfect agreement.

## **Results**

### *Patients*

A total of 158 patients met the inclusion criteria and were invited for the study. Of these, 36 patients did not respond and 73 declined the invitation. Three of the initial 49 participants had an incomplete CT scan due to technical flaws, leaving 46 participants with 92 CT scans of both the injured and uninjured wrist for analysis.

The study group included 38 women and eight men with a mean age of 56.5 years (range 18-87) at the time of trauma. Mean post-traumatic follow-up was 4.2 years (range 3.3-5.0). According to the AO Comprehensive Classification, 22 fractures were type A, four type B and 20 type C fractures. All fractures were consolidated at time of follow-up.

#### *Clinical DRUJ instability*

The results of the stress and clunk tests were positive in 16 (prevalence 35%) and seven (prevalence 15%) patients, respectively (Table 1). Six patients tested positive for both tests. A total of 12 patients suffered from pain in the injured wrist during pronation against resistance with a VAS score ranging from 5 to 8 points, five of whom also reported pain at rest. Five of these patients tested positive for one or both clinical tests. The median VAS-score was 0 in the groups with and without clinical DRUJ instability (Mann-Whitney test,  $p=0.79$ ). Pain was not recorded in one patient. One patient reported pain only in the non-injured wrist.

#### *Radiological DRUJ instability*

The normal values as determined in the uninjured wrist are shown in Table 2. The numbers of patients with DRUJ instability on CT when compared with mean normal values of the uninjured wrist and to individual normal values are shown in Tables 3 and 4.

#### *Reliability analysis between CT findings and clinical tests*

Agreement between CT findings and the clinical tests was moderate at best for all four methods in both

**Table 1.** Results for the stress test and clunk test. A positive test indicates presence of DRUJ instability; a negative test indicates stable DRUJ. supination and pronation (Table 5). The agreement on DRUJ instability was highest for the radioulnar line CT scoring method in pronation, compared with the clunk test ( $\kappa=0.45$ ) when the definition of DRUJ instability on CT was based on the mean normal values for all uninjured wrists.

## **Discussion**

This study showed that the agreement on DRUJ instability between CT and clinical tests was moderate at best, but predominantly poor. The relationship between DRUJ translation measurements on CT and clinical testing of DRUJ instability is difficult to demonstrate, lacking hard standardized criteria for both normal wrist CT values and clinical DRUJ instability tests.

To our knowledge, only one research group has published data on the relationship between the clinical DRUJ instability and radiological DRUJ translation on CT (Kim and Park, 2008). They found at best moderate correlation between the epicentre method CT scan results and the stress test of the wrist after a healed distal radius fracture and concluded that there was poor agreement

between CT scan findings. These findings are in line with our results.

The results published by Kim and Park (2008) may have been influenced by several factors, which may also apply to our study. First, although widely and most frequently used in earlier studies, the stress test is criticized in the literature for being subjective (Jupiter, 2009; Kim and Park, 2008; Szabo, 2006). Despite the assumed subjectivity of the stress test, it has shown good interobserver agreement results (Lindau et al., 2002), which might explain why the stress test is still frequently used as clinical reference test. Unlike Kim and Park (2008) we used both the stress test and clunk test for assessment of clinical DRUJ instability. Jupiter suggested that the clunk test is superior to the stress test (Jupiter, 2009), yet the clunk test has to our knowledge never been compared with CT findings. This study showed that the clunk test has a better agreement with CT scan findings than the stress test, and may therefore be more suitable as a clinically predictive test. Unfortunately, no data are available for the inter-observer agreement on the clunk test.

Second, the CT scan findings may be observer dependent. The reliability of CT-based quantification techniques for DRUJ translation has been published only once by Park and Kim (2008). These authors found interobserver agreement ranging from moderate to almost perfect (0.52–0.91) for various techniques. Recently analysed data from our group are in line with these findings (Wijffels et al., 2016).

In the literature, normal values for the extent of physiological DRUJ translation have not been defined in a uniform way. Therefore, we used two different ways to define whether the extent of DRUJ translation was abnormal. Taking various suggestions from earlier studies into consideration (Kim and Park, 2008; Nakamura et al., 1996), we chose to compare individual DRUJ translation measurements in the injured wrist to the mean measurements for the uninjured wrists of the whole group. Since inter-individual values differ widely, we also compared the values of the wrists of individual patients to define abnormal DRUJ translation. In Table 5 it is apparent that neither the population's reference values, nor the individual reference values, correlate well with the outcome of the clinical tests. Our main conclusion from these results is therefore that there is poor correlation between clinical DRUJ instability and CT scan translation measurements, irrespective of the way the translation is measured on CT.

The current study results should be interpreted in the light of several shortcomings, in accordance with its retrospective character. (1) Only a small proportion of the invited patients gave consent and were included in this study. Nevertheless, the patients included had the same baseline characteristics regarding to age, gender and fracture type as those not included (data not shown). (2) It is also probable that the selection method in this study has introduced a bias toward symptomatic patients, who would more likely agree to participate. (3) The clinical tests were executed by only one observer, with the risk of observer bias. (4) The CT scan was performed with the patient in the prone position with both arms above the head and extended elbows, in order to have two wrists scanned at the same time. This is in contrast with the preferred positioning of the arm with the shoulder in 90° of abduction and the elbow in 90° of flexion (Kim and Park, 2008).

In conclusion, there is a poor correlation between CT scan translation measurements and clinical DRUJ instability. Both establishing reproducible clinical tests and defining normal values for

DRUJ translation on CT scans remain a challenge, which contributes to the fact that currently the diagnostic ability of CT for identifying DRUJ instability seems limited.

## References

Anderson ML, Skinner JA, Felmlee JP, Berger RA, Amrami KK. Diagnostic comparison of 1.5 Tesla and 3.0 Tesla preoperative MRI of the wrist in patients with ulnar-sided wrist pain. *J Hand Surg Am.* 2008, 33: 1153-9.

Court-Brown CM, Caesar B. Epidemiology of adult fractures: a review. *Injury.* 2006, 37: 691-7.

Geissler WB, Fernandez DL, Lamey DM. Distal radioulnar joint injuries associated with fractures of the distal radius. *Clin Orthop Relat Res.* 1996, 327: 135-46.

Huskisson EC. Measurement of pain. *Lancet.* 1974, 2: 1127-31. Jupiter JB. Commentary: the effect of ulnar styloid fractures on patient-rated outcomes after volar locking plating of distal radius fractures. *J Hand Surg Am.* 2009, 34: 1603-4.

Kim JP, Park MJ. Assessment of distal radioulnar joint instability after distal radius fracture: comparison of computed tomography and clinical examination results. *J Hand Surg Am.* 2008, 33: 1486-92.

Kleinman WB. Stability of the distal radioulnar joint: biomechanics, pathophysiology, physical diagnosis, and restoration of function what we have learned in 25 years. *J Hand Surg Am.* 2007, 32: 1086-106.

Landis JR, Koch GG. The measurement of observer agreement for categorical data. *Biometrics.* 1977, 33: 159-74.

Levinsohn EM, Rosen ID, Palmer AK. Wrist arthrography: value of the three-compartment injection method. *Radiology.* 1991, 179: 231-9.

Lindau T, Hagberg L, Adlercreutz C, Jonsson K, Aspenberg P. Distal radioulnar instability is an independent worsening factor in distal radial fractures. *Clin Orthop Relat Res.* 2000, 376: 229-35.

Lindau T, Runnquist K, Aspenberg P. Patients with laxity of the distal radioulnar joint after distal radial fractures have impaired function, but no loss of strength. *Acta Orthop Scand.* 2002, 73: 151-6.

Lo IK, MacDermid JC, Bennett JD, Bogoch E, King GJ. The radioulnar ratio: a new method of quantifying distal radioulnar joint subluxation. *J Hand Surg Am.* 2001, 26: 236-43.

May MM, Lawton JN, Blazar PE. Ulnar styloid fractures associated with distal radius fractures: incidence and implications for distal radioulnar joint instability. *J Hand Surg Am.* 2002, 27: 965-71.

Mino DE, Palmer AK, Levinsohn EM. Radiography and computerized tomography in the

diagnosis of incongruity of the distal radio-ulnar joint. A prospective study. *J Bone Joint Surg Am.* 1985, 67: 247-52.

Müller ME, Perren SM, Allgöwer M Arbeitsgemeinschaft für Osteosynthesefragen. *Manual of internal fixation: techniques recommended by the AO-ASIF group*, 3rd edn. Berlin; New York, Springer-Verlag, 1991: xxviii, 750 p.

Nakamura R, Horii E, Imaeda T, Nakao E. Criteria for diagnosing distal radioulnar joint subluxation by computed tomography. *Skeletal Radiol.* 1996, 25: 649-53.

Nakamura R, Horii E, Imaeda T et al. The ulnocarpal stress test in the diagnosis of ulnar-sided wrist pain. *J Hand Surg Br.* 1997, 22: 719-23.

Oskam J, Kingma J, Klasen HJ. Fracture of the distal forearm: epidemiological developments in the period 1971–1995. *Injury.* 1998, 29: 353-5.

Pan CC, Lin YM, Lee TS, Chou CH. Displacement of the distal radioulnar joint of clinically symptom-free patients. *Clin Orthop Relat Res.* 2003, 415: 148-56.

Park MJ, Kim JP. Reliability and normal values of various computed tomography methods for quantifying distal radioulnar joint translation. *J Bone Joint Surg Am.* 2008, 90: 145-53.

Pickering GT, Nagata H, Giddins GEB. In-vivo three-dimensional measurement of distal radioulnar joint translation in normal and clinically unstable populations. *J Hand Surg Eur.* 2016, 41: 521-6.

Stoffelen D, De Smet L, Broos P. The importance of the distal radioulnar joint in distal radial fractures. *J Hand Surg Br.* 1998, 23: 507-11.

Szabo RM. Distal radioulnar joint instability. *J Bone Joint Surg Am.* 2006, 88: 884-94.

Wechsler RJ, Wehbe MA, Rifkin MD, Edeiken J, Branch HM. Computed tomography diagnosis of distal radioulnar subluxation. *Skeletal Radiol.* 1987, 16: 1-5.

Wijffels M, Brink P, Schipper I. Clinical and non-clinical aspects of distal radioulnar joint instability. *Open Orthop J.* 2012, 6: 204-10.

Wijffels MM, Krijnen P, Schipper IB. Clinical DRUJ instability does not influence the long-term functional outcome of conservatively treated distal radius fractures. *Eur J Trauma Emerg Surg.* 2016. Epub ahead of print 29 January 2016. DOI: 10.1007/

**Table 1.** Comparison between results of stress and clunk test.

Clunk test	Stress test		
	Positive (n)	Negative (n)	Total (n)

Positive (n)	6	1	7
negative (n)	10	29	39
Total (n)	16	30	46

**Table 2.** Normal values based on the non-injured wrist, in pro- and supination for the four scoring methods for the whole group.

Method	Normal range	
	Pronation	Supination
Radioulnar line	-0.15-0.43	-0.39-0.08
Subluxation ratio	-0.25-0.34	-0.39-0.04
Epicenter	-0.35-0.06	-0.11-0.19
Radioulnar ratio	0.39-0.77	0.09-0.58



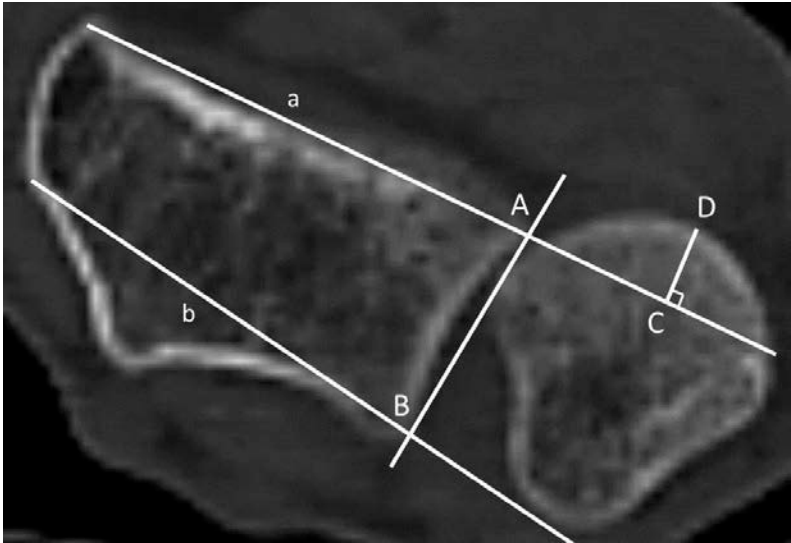
**Table 3.** Number of DRUJ instability found on CT when the injured wrist is compared to all normal non-injured wrists of the total group for all four methods

	Pronation	Supination
Radio ulnar line method	11	7
Subluxation ratio method	1	5
Epicenter method	0	8
Radio ulnar ratio method	3	3


**Table 4.** Number of DRUJ instability found on CT when the injured wrist is compared to patients' normal non-injured wrists for all four methods

	Pronation	Supination
Radio ulnar line method	21	25
Subluxation ratio method	26	29
Epicenter method	27	29
Radio ulnar ratio method	23	27

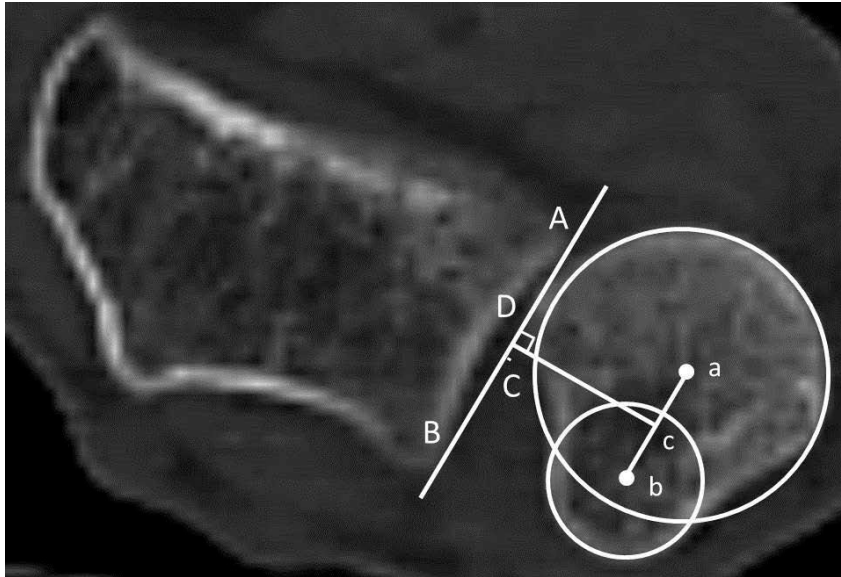
**Figure 1.** The Radio ulnar line method =  $CD/AB$ : the amount of ulnar head volar or dorsal from the ulnar line is measured (CD). The ratio of this length to the length of the sigmoid notch (AB) is calculated.



**Figure 2.** The Subluxation ratio method =  $CD/AB$ . The length of the sigmoid notch is defined by length AB. The distance of the ulnar head outside line a or b is measured perpendicular on this line (distance CD). The ratio between the length of extra-articular ulnar head and the sigmoid notch length is calculated ( $CD/ AB$ )



**Figure 3.** The Epicenter method =  $CD/AB$ . The centre of rotation (point D) is defined by the center of the ulnar head and ulnar styloid process (point a and b respectively). The distance between point D and the midpoint of the sigmoid notch, point C, is measured.



**Figure 4.** The radio ulnar ratio method =  $AD/AB$ . The length of the sigmoid notch is measured (length AB). A line perpendicular to line AB and the center of the ulnar head is defines point D.

