

Available online at www.sciencedirect.com

ScienceDirect

journal homepage: www.ejcancer.com

Review

Biology and treatment of renal tumours in childhood



Jesper Brok^{a,d,*}, Taryn D. Treger^{a,1}, Saskia L. Gooskens^{b,c},
Marry M. van den Heuvel-Eibrink^b, Kathy Pritchard-Jones^a

^a Cancer Section, University College London, Institute of Child Health, UK

^b Department of Paediatric Oncology, Princess Máxima Center for Pediatric Oncology and University of Utrecht, The Netherlands

^c Department of Paediatric Haematology and Oncology, Erasmus MC – Sophia Children's Hospital, Rotterdam, The Netherlands

^d Department of Paediatric Haematology and Oncology, Rigshospitalet, Copenhagen University Hospital, Denmark

Received 18 March 2016; received in revised form 25 August 2016; accepted 1 September 2016

Available online 29 October 2016

KEYWORDS

Renal tumour;
Wilms' tumour;
Clear cell sarcoma;
Rhabdoid tumour;
Renal cell carcinoma;
Paediatric;
Biology;
Targeted therapy;
SIOP-RTSG

Abstract In Europe, almost 1000 children are diagnosed with a malignant renal tumour each year. The vast majority of cases are nephroblastoma, also known as Wilms' tumour (WT). Most children are treated according to *Société Internationale d'Oncologie Pédiatrique* Renal Tumour Study Group (SIOP-RTSG) protocols with pre-operative chemotherapy, surgery, and post-operative treatment dependent on stage and histology. Overall survival approaches 90%, but a subgroup of WT, with high-risk histology and/or relapsed disease, still have a much poorer prognosis. Outcome is similarly poor for the rare non-WT, particularly for malignant rhabdoid tumour of the kidney, metastatic clear cell sarcoma of the kidney (CCSK), and metastatic renal cell carcinoma (RCC).

Improving outcome and long-term quality of life requires more accurate risk stratification through biological insights. Biomarkers are also needed to signpost potential targeted therapies for high-risk subgroups. Our understanding of Wilms' tumourigenesis is evolving and several signalling pathways, microRNA processing and epigenetics are now known to play pivotal roles. Most rhabdoid tumours display somatic and/or germline mutations in the *SMARCB1* gene, whereas CCSK and paediatric RCC reveal a more varied genetic basis, including characteristic translocations. Conducting early-phase trials of targeted therapies is challenging due to the scarcity of patients with refractory or relapsed disease, the rapid progression of relapse and the genetic heterogeneity of the tumours with a low prevalence of individual somatic mutations. A further consideration in improving population survival rates is the geographical variation in outcomes across Europe.

* Corresponding author: Cancer Section, University College London, Institute of Child Health, UK.

E-mail address: j.brok@ucl.ac.uk (J. Brok).

¹ These authors contributed equally.

This review provides a comprehensive overview of the current biological knowledge of childhood renal tumours alongside the progress achieved through international collaboration. Ongoing collaboration is needed to ensure consistency of outcomes through standardised diagnostics and treatment and incorporation of biomarker research. Together, these objectives constitute the rationale for the forthcoming SIOP-RTSG ‘UMBRELLA’ study.

© 2016 The Authors. Published by Elsevier Ltd. This is an open access article under the CC BY-NC-ND license (<http://creativecommons.org/licenses/by-nc-nd/4.0/>).

1. Introduction

Childhood renal tumours account for around 7% of all childhood cancers. The majority of cases (90%) are Wilms’ tumour (WT or nephroblastoma), with an annual incidence of approximately 1 in 100,000 children [1]. Thus, a large European country, such as Germany, will experience around 100 new cases a year, whereas a small country like Denmark diagnose less than 10 cases annually.

The median age at diagnosis of WT is 3 years but bilateral cases and those associated with congenital syndromes occur earlier. The most common presentation is that of an abdominal mass or swelling, and children are usually otherwise clinically well [2]. Other symptoms include abdominal pain, haematuria, fever, and symptoms related to hypertension. About 10% of WT have haematogenous spread, most commonly to the lungs (85%), liver (10%) and only very rarely to the bones and brain [1].

WT may occur as a part of a genetic predisposition syndrome in 5–10% of cases. The more common phenotypes include WAGR (WT, aniridia, genitourinary anomalies, and mental retardation), Denys–Drash syndrome, Beckwith–Wiedemann syndrome, asymmetric overgrowth, or family history of WT [3]. If predisposition is suspected prior to the diagnosis of WT, the tumour may be detected through a screening programme.

The most frequently occurring non-Wilms’ renal tumours (non-WT) include clear cell sarcoma of the kidney (CCSK) with an identical age distribution to WT, malignant rhabdoid tumour of the kidney (MRTK) with a peak incidence between the age of 10–18 months and renal cell carcinoma (RCC), which usually occurs in adolescence. Altogether, CCSK and MRTK comprise about 3–5% of all primary renal tumours in children, whereas RCC accounts for around 1% (Fig. 1) [4]. Other types of malignant renal tumours, such as anaplastic sarcoma and primitive neuroectodermal tumour of the kidney, are extremely rare. Overall non-WT have a poorer outcome than WT. Relatively benign renal tumours, such as congenital mesoblastic nephroma, are mainly diagnosed in newborns or during foetal anomaly scanning, and cure can usually be achieved with surgery alone.

There are two different approaches to the initial management of renal tumours in childhood. Most children in Europe are treated with pre-operative chemotherapy, according to the *Société Internationale d’Oncologie Pédiatrique* Renal Tumour Study Group (SIOP-RTSG) protocols. In North America, patients are treated with upfront surgery prior to administration of chemotherapy, as per the National Wilms’ Tumour Study/Children’s Oncology Group (COG) protocols. Although the SIOP and COG strategies differ in their upfront treatment approach, they have a similar overall survival (OS) of nearly 90% [5,6].

Despite the excellent prognosis for most children with WT, just under 15% of patients will relapse, usually within 2 years of diagnosis [5]. Furthermore, a proportion of patients will experience severe early and late treatment-related adverse events, e.g. cardiotoxicity secondary to doxorubicin (DOX) or radiotherapy-induced organ dysfunction, musculoskeletal abnormalities, infertility and secondary malignancies [7,8]. The current aims of treatment optimisation are to standardise diagnosis, to improve risk stratification, to minimise side-effects of treatment and to improve relapse monitoring according to clinical, molecular, histopathological and imaging data.

The aim of this review is to provide the clinician with an overview of tumour biology, current treatment and research into more effective therapies for subgroups of paediatric renal tumours. Focus will be on WT, due to its relatively higher incidence, but other renal tumours will be discussed within the context of the SIOP-RTSG strategy.

2. Biology of sporadic WT and predisposition syndromes

2.1. Genetics

Despite our incomplete understanding of the pathogenesis of WT, there is increasing evidence that several signalling pathways, microRNA processing, and epigenetics all play pivotal roles (Table 1). In general, WT represent a genetically heterogeneous group, displaying a low prevalence of known somatic alterations and a high degree of intra-tumoural heterogeneity [9].

The first WT-related gene to be characterised was *WT1*, a zinc finger DNA-binding transcription factor,

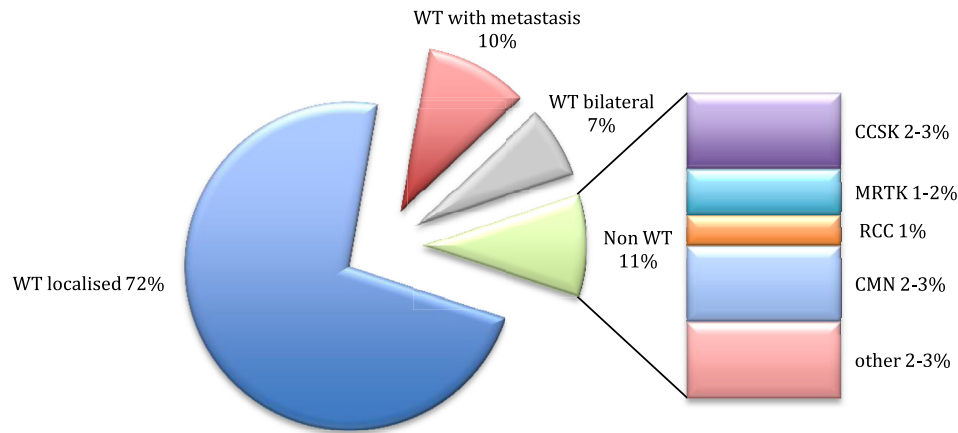


Fig. 1. Distribution of renal tumours in children registered in the SIOP-RTSG WT 2001 trial and study. Note that MRTK and RCC are underrepresented in this clinical database, compared to population-based cancer registration [165]. CCSK, clear cell sarcoma of the kidney; CMN, congenital mesoblastic nephroma; MRTK, malignant rhabdoid tumour of the kidney; RCC, renal cell carcinoma; WT, Wilms’ tumour.

Table 1
Most frequently identified somatic changes in childhood renal tumours.

Genetics	Tumour	Approximate incidence	Clinicopathological associations	References
<i>WT1</i> (11p13)	WT	10–20%	Early event, found in ILNR; associated with stromal histology	[11,15]
<i>CTNNB1</i> (3p21)	WT	15%	Late event, not in NR	[16]
<i>MLLTI</i> (19p13)	WT	4% in one series	Early event, found in ILNR; younger age	[18]
<i>WTX</i> (Xq11)	WT	15–20%	No clinicopathological associations	[19,21]
<i>IGF2</i> (11p15)	WT	69%	Early event, found in PLNR; associated with epithelial/blastemal histology	[14,38]
Loss of 1p, 16q	WT	1p 11%; 16q 17%; 1p/16q 5%	Combined LOH associated with reduced EFS and OS	[6]
Gain of 1q	WT	27%	Reduced EFS, possible reduced OS	[106,107,108]
<i>TP53</i> (17p13)	WT	70% of anaplastic tumours	Reduced EFS and OS; rarely found in tumours without diffuse anaplasia	[24,27]
<i>MYCN</i> (2p24)	WT	13%	Reduced EFS, OS; associated with anaplastic histology	[31]
miRNAPG: <i>DROSHA</i> , <i>DGCR8</i> , <i>DICER1</i> , <i>TARBP2</i> , <i>DIS3L2</i> and <i>XPO5</i>	WT	18% of SIOP high-risk blastema tumours 15% pre-therapy FHWT	Found in PLNR in FHWT; <i>DGCR8</i> has a female bias (88% of cases) reduced EFS, OS when found in combination with <i>SIX1/2</i> mutations	[25,32,42]
<i>SIX1</i> (14q23), <i>SIX2</i> (2p21)	WT	18% of SIOP high-risk blastema tumours 7% pre-therapy FHWT	Found in PLNR in FHWT; reduced EFS and OS when found in combination with <i>miRNAPG</i> mutations	[25,32]
<i>SMARCA4</i> (19p13)	WT ATRT	4.5% in one series 1 case report	Not known	[42,69]
<i>SMARCB1</i> (22q11)	MRTK ATRT	95%	Mutation found in almost all patients	[64,65]
<i>YWHAE-NUTM2</i> t(10;17) (q22;p13)	CCSK	12%	No clinicopathological associations	[54,58]
<i>ITD BCOR</i> (Xp11)	CCSK	85–100%	Not known	[59,60]
<i>TFE3</i> (Xp11) to <i>ASPL</i> (17q25), <i>PRCC</i> (1q21), <i>PSF</i> (1p34), <i>NonO</i> (Xq12), and <i>CLTC</i> (17q23)	RCC	20–40%	Translocation-type RCC	[72]
<i>TFEB</i> t(6;11) (p21;q12)	RCC	Case reports	Translocation-type RCC	[73]

ATRT, atypical teratoid/rhabdoid tumour; CCSK, clear cell sarcoma of the kidney; EFS, event-free survival; FHWT, favourable histology Wilms’ Tumour; ILNR, intralobar nephrogenic rests; LOH, loss of heterozygosity; OS, overall survival; PLNR, perilobar nephrogenic rests; PLNR, perilobar nephrogenic rests; RCC, renal cell carcinoma; SIOP, Société Internationale d’Oncologie Pédiatrique; WT, Wilms’ tumour.

with a vital role in nephrogenesis and glomerular function in the mature kidney [10–12]. Germline *WT1* mutations lead to a range of genitourinary malformations and underlie tumour development in both WAGR and Denys–Drash syndromes [13]. Approximately 5–20% of sporadic tumours also exhibit somatic *WT1* loss, with incidence dependent on patient ethnicity [14]. Mutations in *WT1* are also found in precursor lesions known as intralobar nephrogenic rests (ILNR), suggesting that they are early events in tumourigenesis [15].

WT1 negatively regulates the WNT pathway and mutations in the *CTNNB1* gene, coding for the crucial protein beta-catenin, often occur alongside *WT1* loss [16,17]. Recently, somatic mutations in the *MLLT1* gene were identified in 4% of WT, frequently accompanied by *CTNNB1* mutations and WNT pathway activation [18]. *MLLT1* plays a critical role in transcriptional regulation during early renal developmental and patients with the mutation present at a younger age with a high prevalence of ILNR.

Beta-catenin is targeted for degradation by the ‘destruction complex’ which includes the WTX (AMER1) protein, this is itself inactivated in 18% of WTs [19–21]. The role of somatic *WTX* mutations in tumour development is unclear and germline mutations, found in sclerosing skeletal dysplasia, confer no increased risk of WT [22]. *WTX* interacts with the tumour suppressor protein p53, enhancing its role in cell cycle arrest and apoptosis [23].

Somatic mutations in *TP53* are only found in approximately 70% of the rare high-risk group of anaplastic cases [24]. These tumours have a characteristically unstable genome with multiple copy number aberrations and chromothripsis [25]. In addition to the classical role of p53 as a tumour suppressor protein, gain-of-function mutations are now thought to drive cell migration and invasion [26]. In WT, mutations in *TP53* are an independent indicator of poor prognosis [27]. Another protein thought to hold tumour suppressor function is the RE1 Silencing Transcription Factor (REST) transcription factor, and inactivating mutations have been identified in both sporadic and familial WT [28]. REST is a transcriptional repressor that is essential for embryonic development and truncations in the protein occur in several cancers [29].

Regarding driver genes, gain of the proto-oncogene *MYCN* is associated with poor outcome in several childhood embryonal cancers including WT, neuroblastoma, medulloblastoma and rhabdomyosarcoma [30]. Gain of *MYCN* is predominantly a somatic event but germline aberrations have also been reported [31]. *SIX1* and *SIX2* were also recently identified as other prognostically relevant candidate oncogenes, with somatic mutations found in both low- and high-risk histological subtypes [25,32]. These transcription factors are known to be involved in nephron development, with

SIX2 maintaining mesenchyme progenitor cells in an undifferentiated blastema state and *SIX1*-knockout mice displaying renal agenesis [33,34].

2.2. Epigenetics

Disruption of epigenetic processes, such as DNA methylation and histone modification, is now known to contribute to the development and progression of many childhood solid tumours including WT [35,36].

Through analysis of patients with Beckwith–Wiedemann and related overgrowth syndromes, aberrant imprinting at 11p15 was implicated in WT development. The two principal abnormalities at this locus are paternal uniparental disomy and maternal *H19* epimutation, both resulting in activation of the insulin-like growth factor (IGF) signalling pathway [37]. This is the most common pathway that is deregulated in WT, with somatic aberrations found in 70% of sporadic tumours, and is considered to occur early in tumour development [14,38]. These WT are a clinically distinct group from those without the mutation and are associated with blastema/epithelial histology and perilobar nephrogenic rests [39]. The IGF pathway is involved in cell proliferation, inhibition of apoptosis and protein synthesis, via activation of the phosphatidylinositol 3-kinase/Akt/mammalian target of rapamycin (P13K/Akt/mTOR) and ras–raf–mitogen-activated protein kinases (MAPK) signalling [40].

Many other changes to the epigenome have been identified in WT. Whole-exome sequencing has demonstrated mutations in the chromatin remodelers *SMARCA4* and *ARID1A*, previously identified in childhood medulloblastoma [41,42]. Analysis of methylation profiles shows significant variation between normal kidney, nephrogenic rests and tumour [43]. In addition, promoters for *SIX2* and *WT1* are hypomethylated in WT and foetal kidneys; in contrast, hypermethylation of these sequences is described in mature kidneys [44]. *WT1* itself can directly affect methylation through transcriptional regulation of the enzymes DNA methyltransferase 3A and DNA methyltransferase 1 [45,46]. *WT1* also recruits Polycomb proteins to reduce Pax2 expression, a transcriptional regulator that is critical for urogenital development and mesenchymal-to-epithelial transition (MET) [47]. Polycomb genes (*EZH2*, *BMI-1* and *SUZ12*) are upregulated in WT xenografts and reduced when tumour cells undergo differentiation, suggesting that they may maintain malignant renal progenitor cells [44].

2.3. MicroRNA processing pathway

MicroRNAs (miRNAs) are small non-coding RNAs involved in post-transcriptional gene silencing [48]. Mutations in several miRNA-processing genes (*DROSHA*, *DICER1*, *DGCR8*, *XPO5* and *TARBP2*) have

been identified in sporadic WT, both in chemotherapy-naïve tumours and post chemotherapy [25,32,42]. *DROSHA* and *DICER1* mutations reduce expression of the tumour-suppressor Let7 family and lead to failure of epithelial differentiation [42]. Disruption of miRNA biogenesis through germline mutations in *DIS3L2* underlies Perlman syndrome, a rare congenital overgrowth syndrome with susceptibility to WT [49]. In addition to tumour development, specific miRNAs can predict response to chemotherapy and are associated with metastasis, suggesting a role in disease progression [50,51]. Several groups have explored their use as a diagnostic biomarker, demonstrating that serum miRNA profiles can reliably differentiate WT from other solid tumours and healthy controls [52,53].

3. Biology of non-WT

3.1. Clear cell sarcoma of the kidney

CCSK is not associated with genetic predisposition syndromes and familial CCSK cases have not been reported. One of the recurring genetic changes is the translocation t(10;17) (q22;p13), occurring in about 12% of tumours [54]. This involves the fusion of *YWHAE* and *NUTM2B/E* genes on chromosome 17 and 10, respectively. The *YWHAE* gene encodes an epsilon protein, which modulates phosphoserine-containing proteins and plays a role in various signal transduction pathways including P13K/Akt and MAPK [55–57]. This translocation does not appear to be correlated with either tumour characteristics or patient outcome [58].

Recently, recurrent internal tandem duplications (ITD) of the X-linked BCL-6 co-repressor (*BCOR*) gene have been described and are found to be mutually exclusive to t(10;17) (q22;p13) [59,60]. Until recently, all reported CCSK patients without t(10;17) (q22;p13) were thought to harbour the *BCOR* ITD and vice versa, but a subset of tumours have been identified with neither mutation [61]. Finally, although CCSK is a genomically stable tumour, over-expression of several genes has been reported, including neural markers (e.g. nerve growth factor receptor) and genes involved in both the Sonic hedgehog pathway and the P13K/Akt cell proliferation pathway [62,63].

3.2. Malignant rhabdoid tumour of the kidney

More than 95% of rhabdoid tumours have bi-allelic inactivating mutations of *SMARCB1*. Up to 35% of patients also have a germline mutation in one allele of *SMARCB1*, which is an additional adverse prognostic indicator [64–68]. *SMARCA4* mutations have been identified in a smaller subset of patients with the closely related atypical teratoid/rhabdoid tumour of the brain [69]. *SMARCB1* encodes a member of the SWItch/

Sucrose Non-Fermentable (SWI/SNF) chromatin remodelling complex, which regulates transcription of specific targets. Germline analysis is recommended for individuals of all ages with rhabdoid tumours and prenatal diagnosis can be performed in families with a known *SMARCB1* alteration. Surveillance guidelines for patients with a germline mutation have been developed [70]. Gene expression studies of rhabdoid tumour have identified multiple other genes and pathways with altered expression [71].

3.3. Renal cell carcinoma

In children, translocation RCC is the most common subtype of RCC and is characterised by translocations involving the *transcription factor E3* gene (*TFE3*) on chromosome Xp11. This gene can fuse to several partners including *ASPL* (17q25), *PRCC* (1q21), *PSF* (1p34), *NonO* (Xq12), and *CLTC* (17q23) [72]. Another less-common translocation is t(6;11) (p21;q12) involving a fusion of *Alpha* (11q12) and *transcription factor EB* (*TFEB*) (6p21) that leads to overexpression of *TFEB* [73]. Of interest, 15% of patients with translocation RCC have previously been treated with chemotherapy [74].

Several genetic syndromes are associated with a predisposition to RCC. The best described is von Hippel-Lindau (VHL), caused by mutations or deletions in the *VHL* gene. *VHL* is a tumour suppressor gene that regulates the level of the hypoxia-inducible factor family of transcription factors and is involved in many cellular processes that are dysregulated in human cancer [75]. Affected individuals are mainly susceptible to clear cell type RCC. Tumours usually develop in adulthood, only rarely in childhood, and annual screening is recommended [70].

Tuberous sclerosis (TS) is another rare genetic syndrome that carries an increased risk of both RCC of the clear cell type and angiomyolipoma. The syndrome is caused by mutations in the *TSC1* and *TSC2* genes, which encode key regulators of the mTOR pathway [76]. Mutations in the *FLCN* gene, encoding the protein folliculin which interacts with the mTOR pathway, underlie the Birt–Hogg–Dubé syndrome [77]. Individuals with this syndrome are at risk of developing hybrid oncocytoma/chromophobe RCC. Mutations in the *MET* oncogene, encoding the hepatocyte growth factor receptor, lead to hereditary papillary RCC [78]. Children with germline mutations of two tricarboxylic acid (Krebs) cycle genes, fumarate hydratase (FH) and succinate dehydrogenase (*SDH*), are also susceptible to RCC [79].

4. Current models of tumours

4.1. Genetically modified mouse models

Much effort has been directed towards preclinical models to further characterise Wilms' tumourigenesis

and to guide drug discovery. The identification of *WT1* in 1990 led to the development of early *WT1*-knockout mouse models [80]. Mice with homozygous loss displayed complete renal agenesis, dying prematurely, whilst those with a heterozygous genotype did not develop tumours. The first sustainable WT mouse model was developed in 2011 with *WT1* loss, leading to failure of MET of the metanephric blastema, and upregulation of *IGF2* resulting in arrested differentiation and cellular proliferation [81]. A second murine model arose from the finding that *Lin28* overexpression during kidney development prevents the final stage of differentiation, leading to WT formation in mice [82]. *Lin28* is an RNA-binding protein that suppresses *Let-7* miRNA processing and has also been implicated in the development of neuroblastoma and type II germ cell tumours [83,84].

4.2. Cell lines

Development of cell lines with a sustained life span that are representative of the triphasic histological pattern of Wilms has been challenging, with many attempts found to represent other tumour types. The WiT49 anaplastic cell line, from a xenograft of a human WT lung metastasis, is stable with biphasic histology. It carries a *TP53* mutation, overexpresses *IGF2* and has wild-type *WT1*, with a high tumour occurrence rate when transplanted into recipient mice [85]. The cell line has been used to demonstrate that overexpression of *SIX2* shifts WNT/ β -catenin signalling away from differentiation and towards stem cell survival and that the sphingosine-1-phosphate (S1P) pathway stimulates cell migration and invasion [86,87]. Initial testing of novel compounds has been carried out on WT and rhabdoid cell lines, predominantly by the paediatric preclinical testing programme, a North American initiative that evaluates novel compounds in solid tumour and leukaemia *in vivo* models. Encouraging results have recently been reported for WT with inhibitors of JAK1/2, topoisomerase II and exportin 1 [88–90]. The exportin 1 inhibitor selinexor demonstrated additional cytotoxic activity with rhabdoid cell lines, although all rhabdoid xenografts had progressive disease [90]. Unfortunately, for CCSK, it has not yet been feasible to grow cell lines.

4.3. Novel models

Organoids are 3D adult organ-derived epithelial structures that contain self-renewing and organ-specific stem or progenitor cells, as well as differentiated cells [91]. Organoid cultures have proven to be of value for basic research, for the study of healthy tissue homeostasis and biology of disease. Kidney organoid systems are currently being developed for functional validation studies and preclinical drug testing of paediatric renal tumours [92].

In addition, the zebrafish has emerged as an excellent model for studies of vertebrate biology. External development and optical transparency during embryogenesis allow for visual analysis of early developmental processes, and high fecundity and short-generation time facilitate genetic analysis. The organisms have been used to study the effect of WT-related gene knockdowns on nephrogenesis and have confirmed the essential roles of *WT1* and *SIX2* [93,94]. More recently, zebrafish have provided insight into many human tumours and their role as a WT model remains promising [95].

5. Upcoming European SIOP-RTSG clinical study

For more than a decade, the SIOP-RTSG WT-2001 has been the main clinical trial and study enrolling children with renal tumours in Europe. This randomised clinical trial (RCT) has further optimised risk-stratified chemotherapy to omit DOX in stage II/III, intermediate-risk histology WT. It also highlighted the need to incorporate biomarker and imaging research into a standardised diagnostic and treatment protocol, the SIOP-RTSG ‘UMBRELLA 2016’ study [96]. The main research objective of this upcoming study is to understand the prognostic impact of somatic genetic biomarkers (including 1q gain, *TP53* mutation and *MYCN* aberrations). Another aim is to optimise the definition of high-risk ‘blastemal type’ WT by quantifying the volume of blastemal components that survives pre-operative chemotherapy and determining the correlation between absolute blastemal volume, biomarkers and clinical outcome [97]. A related aim is to identify molecular targets for novel therapeutic approaches, particularly for the high-risk groups. Central pathology review will be expanded across Europe in order to standardise diagnostics. Likewise, centralised radiology review will be introduced, with a focus on better definition of computed tomography (CT)-identified lung lesions and metastatic response. Expanding the number of countries and centres that participate is fundamental to collect sufficient biological material and clinicopathological data.

6. Management of WT

6.1. Treatment

According to the SIOP-RTSG strategy, all patients with WT aged over 6 months receive pre-operative chemotherapy with actinomycin D (ACT-D) and vincristine (VCR). DOX is added in metastatic cases [5]. Pre-operative chemotherapy reduces the risk of tumour rupture thereby downstaging the tumour and decreasing the overall burden of therapy [98]. Radical nephrectomy is the current standard surgical treatment for children with unilateral WT. For bilateral tumours or children at high risk of bilateral disease, nephron sparing surgery

(NSS) should be attempted if feasible. NSS for unilateral disease, in order to preserve renal function without compromising oncological risk, may play a role for carefully selected patients in the future and guidelines have been defined in consensus with the surgical experts of the SIOP-RTSG group [96,99].

Following surgery, the histopathological features of the tumour stratify patients into three prognostic groups: low risk, intermediate risk and high risk (Table 2). The intensity of treatment is directed according to these prognostic groups, based on previous studies demonstrating the association between histopathology and survival [97]. Post-operative chemotherapy and the need for radiotherapy are further dictated by tumour stage (Table 3 and Supplementary Fig. 1).

Survival rate for WT is nearly 90%. Nevertheless, approximately 10% of patients with intermediate-risk histology and up to 25% of patients with high-risk tumours will relapse (Table 4) [5,100]. OS amongst relapsed patients is around 50% but with a large variance depending on the initial treatment, relapse site and tumour histology. These parameters guide future relapse treatment into three risk categories (standard, high and very high risk), where high-dose melphalan and autologous stem cell rescue are recommended as consolidation in both the high- and very high-risk groups [101]. Relapse treatment, in contrast to first line treatment, is not based on evidence from RCTs, but solely on prospective single-arm studies and, in very high-risk relapse, on case series [102–104].

6.2. Biomarkers

Currently, there is an increased focus on identifying better prognostic molecular markers for WT. Recommendations

of potential molecular markers in other tumour types are mushrooming due to the low cost, speed and ease of current genetic sequencing methods. Any potential prognostic indicators require prospective validation and assessment of intra-tumoural heterogeneity in a suitably powered cohort of patients. Furthermore, even if a biological marker is independently found to be significantly associated with clinical outcomes, the optimal adjustment of treatment in subgroups of patients with and without such markers is unknown.

Recently, the COG group assessed intensified (the addition of etoposide [ETO]/cyclophosphamide [CYC] to VCR/ACT-D and DOX) treatment for stage III/IV WT with loss of heterozygosity (LOH) of 16q and 1p (~5% of WT), which is associated with reduced OS [6,105]. Compared with a historical control group, they found that the new 5 drug regimen significantly improved event-free survival (EFS) and the intensified treatment is likely to continue as standard for favourable histology WT displaying LOH of 16q and 1p. Treatment was likewise intensified for stage I and II patients, with DOX added to VCR/ACT-D, though this did not significantly affect outcome. This is the first group to use molecular biomarkers to direct therapy in WT. A more common cytogenetic abnormality is gain of 1q, which is present in about 30% of tumours and associated with worse EFS and possible worse OS [106–108]. Likewise, MYCN gain and 17p loss (the TP53 locus), limited to anaplastic WT, may independently predict poor survival [27,31].

6.3. Late effects

Although associated with fewer late effects compared to other solid malignant tumours, WT survivors still reveal

Table 2

Comparison between histological subtyping and risk classification of WT according to the SIOP and COG treatment approaches, with % of patients in each subgroup.

Histopathology Risk Group	SIOP Histological subtype post preoperative chemotherapy ^a		Histopathology Risk Group	COG Histological subtype post immediate nephrectomy					
	L%	M%		L%	M%				
LOW	4	10	FAVOURABLE	90	80				
INTERMEDIATE	80	65	UNFAVOURABLE	10	20				
						Completely necrotic	3	10	No evidence of anaplasia
						Cystic partially differentiated	1	0	
						Regressive	32	44	
Stromal	12	6							
Epithelial	7	3	Focal anaplasia						
Mixed	27	10							
Focal anaplasia	2	2	Diffuse anaplasia						
HIGH	13	13		Diffuse anaplasia	4	8			
			Blastemal				9	5	

L = local; M = metastatic

^a 3% of localised and 12% of metastatic tumours were not classified

Source: SIOP WT 2001 database for all patients with stage I–IV WT, 5731 patients were registered from 2001 to 2015. Data provided by Harm van Tinteren, trial statistician. COG data from Ref. [166].

Table 3

Comparison between staging classification for WT according to the SIOP and COG approaches.

Stage	SIOP	COG
I	Tumour limited to kidney or surrounded with fibrous pseudocapsule and completely resected. Intrarenal vessel involvement may be present, no involvement of renal sinus vessels. Presence of necrotic tumour in the renal sinus or peri-renal fat does not upstage to stage II providing it does not reach the resection margins. Percutaneous cutting needle biopsy is allowed.	Tumour limited to kidney with intact renal capsule and completely resected with no evidence of the tumour at or beyond the margins of resection. Intrarenal vessel involvement may be present, no involvement of renal sinus vessels. No biopsy has been performed.
II	Tumour extension beyond kidney or renal pseudocapsule but completely resected. Infiltration of renal sinus and/or blood and lymphatic vessels outside renal parenchyma but completely resected. Local invasion of adjacent structures or extension into the vena cava is allowed providing resection is performed en bloc and there is no evidence of tumour at or beyond the resection margins.	Tumour extension beyond kidney or penetration of renal capsule but completely resected. Local invasion of adjacent structures or extension into the vena cava is allowed providing resection is performed en bloc and there is no evidence of tumour at or beyond the resection margins. Absence of tumour rupture or spillage, even confined to the flank. No biopsy has been performed.
III	Any of the following reasons, either individually or collectively, assign a tumour to stage III: (1) tumour extends to or beyond resection; margins microscopically or there is macroscopic incomplete excision, (2) positive abdominal lymph nodes; (3) tumour rupture before or intra-operatively including diffuse peritoneal contamination by the tumour or where peritoneal implants are present; (4) piecemeal removal of intravascular tumour thrombus; (5) open biopsy prior to pre-operative chemotherapy or surgery.	Any of the following reasons, either individually or collectively, assign a tumour to stage III: (1) tumour extends to or beyond resection margins microscopically or there is macroscopic incomplete excision; (2) positive abdominal lymph nodes; (3) tumour rupture before or intra-operatively including spillage confined to the flank or diffuse peritoneal contamination by the tumour or where peritoneal implants are present, (4) piecemeal removal of intravascular tumour thrombus; (5) any biopsy is performed prior to surgery.
IV	Haematogenous metastases or distant lymph node metastases	Haematogenous metastases or distant lymph node metastases
V	Bilateral renal involvement at the time of initial diagnosis. Each side's tumour should be substaged separately according to above criteria	Bilateral renal involvement at the time of initial diagnosis Each side's tumour should be substaged separately according to above criteria.

COG, Children's Oncology Group; SIOP, Société Internationale d'Oncologie Pédiatrique; WT, Wilms' tumour.

a high frequency (25%) of severe chronic and life-threatening health conditions in adult life [8]. The late sequelae may include renal and cardiac dysfunction, hypertension, musculoskeletal abnormalities, metabolic syndrome, impaired fertility, reduced pulmonary function and secondary malignancies [7,109,110]. End-stage renal failure is reported in 1% of unilateral WT and about 10% of patients with bilateral disease at long-term follow-up [111]. The risk of congestive heart failure increases with the cumulative dose of DOX administered, with a critical threshold of 240 mg/m². Cardiotoxicity is potentiated by the concurrent use of radiotherapy, with females and infants more susceptible [109]. Similarly, DOX seems to potentiate the adverse effects related to radiotherapy, likely due to its radiosensitisation of cells. These effects include abnormal tissue growth within the target area and secondary malignancies. In this context, omission of agents likely to cause late effects is important to consider in treatment optimisation. As mentioned previously, the last trial, to demonstrate that a reduction in intensity was acceptable, found DOX does not need to be added in the treatment of stage II–III intermediate-risk WT [5]. Although this reduction marginally increases the risk of

Table 4

Two-year EFS and 5-year overall survival for WT in the SIOP 2001 protocol.

Histopathology	Stage I	Stage II	Stage III	Stage IV	All risk group
Low (N)	95	6	23	61	185
2 y EFS (%)	97	100	100	91	95
5 y OS (%)	99	100	100	94	98
Intermediate (N)	1352	625	514	389	2880
2 y EFS (%)	92	89	88	81	89
5 y OS (%)	98	97	94	89	96
High (N)	163	115	141	75	494
2 y EFS (%)	91	84	68	31	74
5 y OS (%)	97	82	70	35	76
All (N)	1610	746	678	525	3559
2 y EFS (%)	92	88	84	76	87
5 y OS (%)	98	94	90	82	93

EFS, event-free survival; N, number of patients; OS, overall survival; SIOP, Société Internationale d'Oncologie Pédiatrique; WT, Wilms' tumour.

Source: SIOP WT 2001 database for all patients with stage I–IV Wilms' tumour treated as per-protocol with pre-op chemotherapy, 5731 patients were registered from 2001 to 2015. Analysis provided by Harm van Tinteren, trial statistician.

relapse, it likely outweighs the increased risk of severe late effects as the small subset of children that relapse can be rescued. Likewise, omission of lung radiotherapy may also be an acceptable treatment approach for lung lesions that have clearly responded to post-operative chemotherapy [112].

6.4. Targeted therapy and immunotherapy

With our increased understanding of the aberrant molecular pathways that contribute to tumourigenesis comes the drive to identify targeted therapeutics and introduce a more personalised medicine approach.

Preclinical testing has shown that targeting the IGF signalling pathway results in cell cycle arrest, with a consequent reduction in tumour volume in transplanted WT xenografts [113,114]. Despite these encouraging results, a phase II study assessing cixutumumab monotherapy (a monoclonal antibody [mAb] to IGF1R) showed no objective response in refractory or relapsed WT [115]. As this was a single-agent trial, the poor response may be due to the complexity of IGF signalling and its interaction with other oncogenic pathways [116]. As mentioned previously, the WNT/ β -catenin pathway is also frequently activated in WT and its downstream effectors play a general role in cancer progression [117]. Although drugs targeting WNT signalling have huge potential, preclinical and clinical studies have not yet been performed. Another promising target is MYCN, as amplification of the oncogene is associated with reduced survival in several childhood cancers including WT [31]. MYCN proteins have been considered undruggable until the recent introduction of a class of inhibitors of Aurora A [30]. These inhibitors destabilise interactions between Aurora A and MYCN and are being tested in several adult phase I and II studies. The sole paediatric phase II study using an Aurora A kinase inhibitor alisertib showed an objective response in only 1 in 10 WT patients [118].

Despite the disappointing results from previous early-phase studies in WT, there are several studies currently recruiting for children with relapsed and refractory solid tumours. Current trials include erlotinib, an epidermal growth factor receptor (EGFR) inhibitor, ramucirumab, a vascular endothelial growth factor receptor (VEGF) inhibitor, talazoparib, a PARP inhibitor and selinexor [119].

The field of immuno-oncology includes a spectrum of interventions that encompass mAbs, cancer vaccines and genetically engineered lymphocytes [120]. Early-phase testing of immunotherapy for refractory and relapsed childhood solid tumours is advancing. One class of therapy to have garnered much attention is antibody–drug conjugates [121]. Lorvotuzumab mertansine, a conjugate between a cytotoxic and an mAb to CD56, showed impressive anti-tumour activity against CD56-positive WT xenografts [122]. CD56 (NCAM-1) is expressed in WT, enriched in blastema, and CD56⁺

ALDH-1⁺ cells may act as cancer-initiating stem cells in a subset of tumours [123]. A phase II trial in children has recently commenced [124]. A phase I study of the immune checkpoint inhibitor ipilimumab, an anti-CTLA4 antibody that blocks the inhibitory signal to cytotoxic T cells, has already been undertaken [125]. Finally, *N*-glycosylated gangliosides, including NGcGM3 are an attractive target, due to their expression on several cancers including WT [126]. A phase I trial testing racotumomab, a vaccine targeting NGcGM3, showed immunogenicity and low toxicity, but further trials are needed to assess response as the one patient with anaplastic WT had progressive disease [127]. WT1 is a major target for immunotherapy, given its oncogenic role in several adult cancers, and promising results have been demonstrated with dendritic cell vaccines and gene-modified T-cell therapy [128,129]. Whether these approaches are transferrable to childhood WT remains to be seen. To our knowledge, no trials have been conducted in WT using adoptive engineered T or NK cells.

7. Treatment of non-WT

Overall, these tumours and their respective subtypes are very rare and it remains challenging to gather robust evidence for treatment recommendations. Hence, cross-Atlantic collaboration, phase I/II studies and multinational RCTs are extremely important to obtain useful clinical data for these patients.

7.1. Clear cell sarcoma of the kidney

As per WT, patients registered on the SIOP-2001 trial were treated with pre-operative chemotherapy. Post-operative treatment consisted of ACT-D/VCR/DOX for patients with local stage I disease and of ifosfamide(IFO)/ETO/carboplatin(CDC)/DOX for patients with stage II–IV disease, with irradiation of the flank for stage II and III patients [130]. The 5-year overall EFS of SIOP 93-01/2001 was 79% and the OS was 86%. Stage IV disease and young age were significant adverse prognostic factors for EFS [130–132].

The planned treatment for CCSK in the upcoming ‘UMBRELLA 2016’ study considers the best available treatment to be ETO/CDC/DOX with alternating CYC/IFO for any tumour stage. Flank radiotherapy will be given to all patients with local stage II and III tumours since the UK-WT-2 study revealed a high local relapse rate in stage II patients treated without radiotherapy [133]. For stage IV patients, if metastases are unresectable, irradiation to metastatic sites will be given; similarly, flank irradiation will be according to local stage.

Although outcomes for CCSK have improved, a subgroup of patients do not fare well, including young patients and those with advanced stage or relapsed disease. As treatment for CCSK is approaching the

maximum tolerated intensity of traditional cytotoxic agents, new targeted therapies are necessary. Possible targets include the Sonic Hedgehog signalling pathway (SMO/GLI1 inhibitors), the PI3K–Akt signalling pathway (PI3K inhibitors, Akt inhibitors, mTOR inhibitors), *EGFR* (erlotinib/ gefitinib), *BCOR* (inhibition of *BCOR*) and demethylating agents (e.g. decitabine). Another possibility may be to inhibit the *YWHA E–NUTM2B/E* fusion transcript but targeting fusion transcripts has thus far proven to be difficult.

7.2. Malignant rhabdoid tumour of the kidney

Historically, patients with MRTK were treated as high-risk WT, but currently, they are managed according to rhabdoid tumour protocols. In SIOP 93-01/2001 trials, most patients received pre-operative therapy with ACT-D/VCR followed by post-operative chemotherapy, consisting of ETO/CDC/IFO/DOX, and radiotherapy but OS rates remained poor (25–30%) [134]. Similar results have been observed using the North American 1–5 protocols [135]. Younger age was an important adverse prognostic indicator and OS in infants was only 9% [135]. Overall, 30% of patients progressed during initial therapy. A few case reports have demonstrated effectiveness of regimens containing IFO/CDC/ETO alternating with VCR/DOX/CYC in advanced disease and some centres suggest high-dose therapy with stem cell rescue based on these few patients [136–139]. MRTK patients will be treated according to the European Rhabdoid Registry (EU-RHAB) protocol with DOX/IFO/CDC/ETO and VCR/CYC/Dactinomycin. Children under 18 months of age will receive additional CDC/thiotepa and stem cell rescue. Early complete resection is important in the treatment of MRTK.

Novel therapeutic approaches are urgently required to improve outcomes for patients with MRTK. Accumulating evidence suggests that in its native form, the SWI/SNF complex inhibits cell cycle progression by transcriptionally repressing *CCND1* (encodes cyclin D1) and activating p16^{INK4A} and p21^{CIP} [140–142]. Based on this observation, therapies targeting cyclin D1 and CDK4 have been tested in pre-clinical models of MRTK with some evidence of activity [143]. Loss of *SMARCB1* has also been shown to activate expression of the mitotic regulator Aurora A kinase and the Sonic hedgehog pathway [144,145]. In addition, targets such as *EZH2*, *CXCR4*, *IGF2*, *PD-1/PD-L1* and the *INI1* pathway should be considered for future treatment strategies [146].

7.3. Renal cell carcinoma

Irrespective of subtype, the mainstay of therapy for paediatric RCC is resection. Many patients with localised, completely resected disease are cured without adjuvant therapy. In translocation RCC, morphology (Fuhrman grade) and distant metastatic disease were

associated with poor survival [147]. In children, local lymph node involvement seems not to be associated with unfavourable outcome, even without adjuvant therapy [148]. The need for radical node dissection still remains to be determined [149]. Patient survival outcomes reported in paediatric RCC patients are above 90% for stage I and II, around 60% for stage III and around 30% for stage IV [150,151].

Although there is no standard treatment for unresectable metastatic RCC in children, the approach is in alignment with recently published adult RCC guidelines [152]. High-dose interleukin-2 has had some success but response is only observed for clear cell RCC [147,153]. Recent data on translocation RCC suggest that VEGF-targeted therapy may be the best therapeutic option, with sunitinib probably being the most effective [154,155]. Another relevant target is the mTOR pathway as high levels of phosphorylated S6, a marker for mTOR activity are found in RCC [73]. Patients who had progressive disease on VEGF therapy and were switched to mTOR inhibitors (everolimus, temsirolimus) showed at least transient disease stabilisation, including one with a partial response. The fusion protein *ASPL–TFE3* transactivates the promoter of the *MET* receptor tyrosine kinase (RTK), therefore inhibiting this RTK may be a potential therapy for this type of translocation RCC [156]. Indications for chemotherapy are extremely rare, but responses to gemcitabine/DOX/oxaliplatin have been observed [148].

8. Adult WT

WT is rare in patients over 16 years of age, with only 70 adults diagnosed in Europe each year [157]. The clinical presentation in older patients is commonly flank pain and weight loss. There are no specific adult treatment protocols but cure has been achieved using paediatric regimens [158,159]. Adults have higher treatment-related toxicity, with VCR neuropathy as the main adverse event. Five-year survival is stage dependent; the largest study showed variation from 74% for stage I disease to less than 15% for metastatic tumours [157]. The poorer prognosis may, in part, be explained by diagnostic delay. Many adult WT patients are initially misdiagnosed as there are no specific radiological findings to differentiate WT from RCC. Central pathology review is recommended as histological diagnosis can be challenging, particularly for pathologists unfamiliar with paediatric tumours. Best practice guidance, based on international consensus, has been published to hasten time to start adjuvant therapy and improve outcome [160].

9. Challenging renal tumours—a patient with WT

For challenging patients, national and international multidisciplinary expert panels are essential to advise on optimum treatment and to minimise inequalities

in childhood cancer survival across Europe. Through the upcoming European expert paediatric oncology reference network projects, centres with expertise in a particular treatment modality could be identified to provide cross-border treatment of complex renal and other tumours [161].

The most challenging renal tumours are predominantly the non-WT and WT that are high-risk histology, bilateral, relapsed or refractory, metastatic and/or with thrombus extension into the inferior vena cava. Each of these scenarios occurs in about one in ten cases and some patients may present with several concomitant complex features. In the following clinical example, we try to highlight some of the key decisions to consider during treatment of complicated WT.

Example: A child with a clinical history of extended abdomen, weight loss and haematuria. CT describes a large solid/necrotic mass (volume ~1100 ml) in the left kidney with thrombus extension into the inferior vena cava at suprahepatic level and three minor lesions in the right kidney. No signs of rupture or abnormal lymph nodes or spread to other organs. Chest considered clear but with a single polygonal minor lesion (3 mm) in lower right pulmonary lobe. Renal function is within the normal range.

Key issues at this stage would be 1) whether to treat pre-operatively as metastatic due to the lung lesion and add DOX to VCR/ACT-D, 2) to discuss surgical approach with an experienced team due to thrombus and bilateral disease, and 3) to consider diffusion weighted MRI in order to better characterise the right-sided renal lesions and the thrombus.

There remains great uncertainty surrounding the interpretation and treatment of minor lung lesions (<5 mm) detected on CT, despite many attempts to predict the likelihood of metastatic disease, based on size, number, appearance and location of nodules [162]. Accordingly, the decision to add DOX pre-operatively is debatable. Owing to this grey area, it is recommended to biopsy small lung lesions of uncertain significance if feasible.

In cases with bilateral disease, the goal is to preserve renal function without compromising the risk of relapse. An experienced surgical team should discuss NSS versus nephrectomy or biopsy of the right kidney for histology to assess if the lesions only contain nephrogenic rests, potentially negating the need for further surgery. For patients with inferior vena cava thrombus extension, in whom thrombectomy is considered, bypass support from cardiothoracic surgeons is essential. An additional high-quality diffusion-weighted MRI would be optimal to reliably assess the extent of disease and to plan surgery.

After chemotherapy, pre-operative MRI illustrated that the tumour size was unchanged and that liver lesions had appeared. CT showed that the lung lesion was slightly bigger (6 mm).

The key issue now is progressive disease. A decision needs to be made whether to operate now, considering the risks of challenging nephrectomy and thrombectomy,

or whether to change and intensify chemotherapy with the aim of reducing these risks. Pulmonary metastectomy in the same surgical séance should also be considered.

Left nephrectomy including thrombectomy at week 7 was performed. Histopathology showed 25% necrosis and viable tumour with mainly blastemal components (high-risk) and lymph node with viable tumour (stage III). The patient was started on the high-risk treatment protocol and received local radiotherapy. Lung and liver lesions were carefully monitored.

This patient represents a group with poor prognosis due to chemo-resistant progressive blastemal disease. Intensified chemotherapy, including DOX, and radiotherapy are essential. The choice of intensified chemotherapy, or even high-dose chemotherapy with stem cell rescue, remains in debate due to insufficient data from case series. In future, this group of patients may well benefit from a personalised medicine approach with sequencing of their tumours undertaken to identify actionable mutations and direct targeted therapy.

10. Discussion

The treatment of WT is one of the successes of paediatric oncology, with both the SIOP and COG approaches achieving cure in approximately 90% of patients. The focus has now shifted to reducing therapeutic burden and the late effects related to anthracyclines and radiotherapy. A recent analysis of late mortality in childhood cancer survivors showed that we have already made progress, with a reduction in secondary neoplasms and cardiac events corresponding to a reduction in treatment intensity [163]. Better risk stratification is required to identify which subgroups of patients can benefit from further treatment reduction.

In contrast, approximately 10% of children do not survive WT, corresponding to at least 100 annual deaths in Europe but with OS varying between European countries. Continued preclinical research is needed to identify new agents for relapsed and refractory WT, prior to testing their efficacy in early phase trials. Targeted therapy has, so far, had less promising results in clinical studies but the studies were limited to small numbers of patients with tumours that had not undergone genetic characterisation. Owing to the complex interactions between signalling pathways and resistance mechanisms, rational combination therapies are needed. Treatment strategies will be influenced by our improved understanding of Wilms' tumorigenesis, gained through upcoming international studies and the increasing numbers of tumours that will undoubtedly be sequenced over the next few years.

Genetic analysis of tumours and correlation with clinicopathological characteristics can identify both prognostic factors and potentially druggable targets.

However, the efficacy of any intervention should still be assessed through RCTs in order to gain robust evidence for clinical practice. In some subgroups, the feasibility of large trials is hampered by patient numbers, which further stresses the need for expanding the number of countries participating in SIOP and COG protocols and for continued cross-Atlantic collaboration. It is important that steering committees within each group collaborate, prioritise and support the most relevant research questions to be addressed. Treatment outcomes in non-WT renal cancer have lagged behind and in rhabdoid tumour, in particular, the prognosis remains dismal. The numbers of children with these high-risk tumours are insufficient to allow large RCTs, and to circumvent this, COG and SIOP are collaborating on a number of upcoming small studies.

Overall, more than half of all relapses in WT occur in children in the intermediate-risk group, which indicates that our current stratification methods need refinement. Work is ongoing to identify tumour and circulating biomarkers that have clinicopathological associations and to validate these markers in international studies. Follow-up for patients is currently limited to clinical assessment and imaging for 2–5 years depending on stage and histology. The question remains whether liquid biopsy has a role to play in non-invasive monitoring and whether in future, it may be used routinely to identify disease reoccurrence prior to clinical relapse [164].

For 9 in 10 children diagnosed with a WT in Europe, it is now a curable cancer. Continued effort is needed to improve the poorer outcomes in high-risk metastatic WT, relapsed WT and the high-risk non-Wilms' renal cancers. For this to be achieved requires the international community to work together, both in the laboratory and in paediatric oncology units.

Conflict of interest statement

None declared.

Acknowledgements

The authors thank the SIOP-RTSG, particularly Harm van Tinteren, trial statistician, for permission to present unpublished data from the group's overall registration database.

TT and KPJ are funded by Great Ormond Street Hospital Biomedical Research Council and TT receives additional funding from The Crick. JB is funded by Great Ormond Street Hospital Children's Charity (512899) and the European Expert Paediatric Oncology Reference Network for Diagnostics and Treatment (508475). SLMG was funded by the Pediatric Oncology Support Rotterdam Foundation (sKOCR) and DaDa Foundation.

Appendix A. Supplementary data

Supplementary data related to this article can be found at <http://dx.doi.org/10.1016/j.ejca.2016.09.005>.

References

- [1] Breslow N, Olshan A, Beckwith JB, Green DM. Epidemiology of Wilms tumor. *Med Pediatr Oncol* 1993;21:172–81.
- [2] Mullen E, Graf N. Clinical Presentation; Renal Tumors of Childhood – Biology and Therapy; Kathy Pritchard-Jones and Jeff Dome; Springer <http://www.springer.com/us/book/9783662440025> (Accessed 14 March 2016).
- [3] Dumoucel S, Gauthier-Villars M, Stoppa-Lyonnet D, Parisot P, Brisse H, Philippe-Chomette P, et al. Malformations, genetic abnormalities, and Wilms tumor. *Pediatr Blood Cancer* 2014;61:140–4.
- [4] Steliarova-Foucher E, Stiller C, Lacour B, Kaatsch P. International classification of childhood cancer, third edition. *Cancer* 2005;103:1457–67.
- [5] Pritchard-Jones K, Bergeron C, de Camargo B, van den Heuvel-Eibrink MM, Acha T, Godzinski J, et al. Omission of doxorubicin from the treatment of stage II–III, intermediate-risk Wilms' tumour (SIOP WT 2001): an open-label, non-inferiority, randomised controlled trial. *Lancet* 2015;386:1156–64.
- [6] Grundy PE, Breslow NE, Li S, Perlman E, Beckwith JB, Ritchey ML, et al. Loss of heterozygosity for chromosomes 1p and 16q is an adverse prognostic factor in favorable-histology Wilms tumor: a report from the National Wilms Tumor Study Group. *J Clin Oncol* 2005;23:7312–21.
- [7] Wright KD, Green DM, Daw NC. Late effects of treatment for Wilms tumor. *Pediatr Hematol Oncol* 2009;26:407–13.
- [8] Termuhlen AM, Tersak JM, Liu Q, Yasui Y, Stovall M, Weathers R, et al. Twenty-five year follow-up of childhood Wilms tumor: a report from the Childhood Cancer Survivor Study. *Pediatr Blood Cancer* 2011;57:1210–6.
- [9] Mengelbier LH, Karlsson J, Lindgren D, Valind A, Lilljebjörn H, Jansson C, et al. Intratumoral genome diversity parallels progression and predicts outcome in pediatric cancer. *Nat Commun* 2015;6:6125.
- [10] Guo J-K, Menke AL, Gubler M-C, Clarke AR, Harrison D, Hammes A, et al. WT1 is a key regulator of podocyte function: reduced expression levels cause crescentic glomerulonephritis and mesangial sclerosis. *Hum Mol Genet* 2002;11:651–9.
- [11] Pritchard-Jones K, Fleming S, Davidson D, Bickmore W, Porteous D, Gosden C, et al. The candidate Wilms' tumour gene is involved in genitourinary development. *Nature* 1990;346:194–7.
- [12] Pelletier J, Bruening W, Li FP, Haber DA, Glaser T, Housman DE. WT1 mutations contribute to abnormal genital system development and hereditary Wilms' tumour. *Nature* 1991;353:431–4.
- [13] Pelletier J, Bruening W, Kashtan CE, Mauer SM, Manivel JC, Striegel JE, et al. Germline mutations in the Wilms' tumor suppressor gene are associated with abnormal urogenital development in Denys–Drash syndrome. *Cell* 1991;67:437–47.
- [14] Scott RH, Murray A, Baskcomb L, Turnbull C, Loveday C, Al-Saadi R, et al. Stratification of Wilms tumor by genetic and epigenetic analysis. *Oncotarget* 2012;3:327–35.
- [15] Park S, Bernard A, Bove KE, Sens DA, Hazen-Martin DJ, Garvin AJ, et al. Inactivation of WT1 in nephrogenic rests, genetic precursors to Wilms' tumour. *Nat Genet* 1993;5:363–7.
- [16] Koesters R, Ridder R, Kopp-Schneider A, Betts D, Adams V, Niggli F, et al. Mutational activation of the {beta}-catenin proto-oncogene is a common event in the development of Wilms' tumors. *Cancer Res* 1999;59:3880–2.

- [17] Kim MS, Yoon SK, Bollig F, Kitagaki J, Hur W, Whye NJ, et al. A novel Wilms tumor 1 (WT1) target gene negatively regulates the WNT signaling pathway. *J Biol Chem* 2010;285:14585–93.
- [18] Perlman EJ, Gadd S, Arold ST, Radhakrishnan A, Gerhard DS, Jennings L, et al. MLLT1 YEATS domain mutations in clinically distinctive Favourable Histology Wilms tumours. *Nat Commun* 2015;6:10013.
- [19] Wegert J, Wittmann S, Leuschner I, Geissinger E, Graf N, Gessler M. WTX inactivation is a frequent, but late event in Wilms tumors without apparent clinical impact. *Genes Chromosomes Cancer* 2009;48:1102–11.
- [20] Major MB, Camp ND, Berndt JD, Yi X, Goldenberg SJ, Hubbert C, et al. Wilms tumor suppressor WTX negatively regulates WNT/beta-catenin signaling. *Science* 2007;316:1043–6. <http://dx.doi.org/10.1126/science.1141515>.
- [21] Rivera MN, Kim WJ, Wells J, Driscoll DR, Brannigan BW, Han M, et al. An X chromosome gene, WTX, is commonly inactivated in Wilms tumor. *Science* 2007;315:642–5.
- [22] Jenkins ZA, van Kogelenberg M, Morgan T, Jeffs A, Fukuzawa R, Pearl E, et al. Germline mutations in WTX cause a sclerosing skeletal dysplasia but do not predispose to tumorigenesis. *Nat Genet* 2009;41:95–100.
- [23] Kim WJ, Rivera MN, Coffman EJ, Haber DA. The WTX tumor suppressor enhances p53 acetylation by CBP/p300. *Mol Cell* 2012;45:587–97. <http://dx.doi.org/10.1016/j.molcel.2011.12.025>.
- [24] Bardeesy N, Falkoff D, Petrucci MJ, Nowak N, Zabel B, Adam M, et al. Anaplastic Wilms' tumour, a subtype displaying poor prognosis, harbours p53 gene mutations. *Nat Genet* 1994;7:91–7.
- [25] Wegert J, Ishaque N, Vardapour R, Geörg C, Gu Z, Bieg M, et al. Mutations in the SIX1/2 pathway and the DROSHA/DGCR8 miRNA microprocessor complex underlie high-risk blastemal type Wilms tumors. *Cancer Cell* 2015;27:298–311.
- [26] Muller PAJ, Vousden KH, Norman JC. p53 and its mutants in tumor cell migration and invasion. *J Cell Biol* 2011;192:209–18.
- [27] Maschietto M, Williams RD, Chagtai T, Popov SD, Sebire NJ, Vujanic G, et al. TP53 mutational status is a potential marker for risk stratification in Wilms tumour with diffuse anaplasia. *PLoS One* 2014;9:e109924.
- [28] Mahamdallie SS, Hanks S, Karlin KL, Zachariou A, Perdeaux ER, Ruark E, et al. Mutations in the transcriptional repressor REST predispose to Wilms tumor. *Nat Genet* 2015;47:1471–4.
- [29] Gopalakrishnan V. REST and the RESTless: in stem cells and beyond. *Future Neurol* 2009;4:317–29.
- [30] Beltran H. The N-myc oncogene: maximizing its targets, regulation, and therapeutic potential. *Mol Cancer Res* 2014;12:815–22.
- [31] Williams RD, Chagtai T, Alcaide-German M, Apps J, Wegert J, Popov S, et al. Multiple mechanisms of MYCN dysregulation in Wilms tumour. *Oncotarget* 2015;6:7232–43.
- [32] Walz AL, Ooms A, Gadd S, Gerhard DS, Smith MA, Guidry Auvil JM, et al. Recurrent DGCR8, DROSHA, and SIX homeodomain mutations in favorable histology Wilms tumors. *Cancer Cell* 2015;27:286–97.
- [33] Xu P-X, Zheng W, Huang L, Maire P, Laclef C, Silvius D. Six1 is required for the early organogenesis of mammalian kidney. *Development* 2003;130:3085–94.
- [34] Self M, Lagutin OV, Bowling B, Hendrix J, Cai Y, Dressler GR, et al. Six2 is required for suppression of nephrogenesis and progenitor renewal in the developing kidney. *EMBO J* 2006;25:5214–28.
- [35] Lawlor ER, Thiele CJ. Epigenetic changes in pediatric solid tumors: promising new targets. *Clin Cancer Res* 2012;18:2768–79.
- [36] Baylin SB, Jones PA. A decade of exploring the cancer epigenome—biological and translational implications. *Nat Rev Cancer* 2011;11:726–34.
- [37] Soejima H, Higashimoto K. Epigenetic and genetic alterations of the imprinting disorder Beckwith–Wiedemann syndrome and related disorders. *J Hum Genet* 2013;58:402–9.
- [38] Satoh Y, Nakadate H, Nakagawachi T, Higashimoto K, Joh K, Masaki Z, et al. Genetic and epigenetic alterations on the short arm of chromosome 11 are involved in a majority of sporadic Wilms' tumours. *Br J Cancer* 2006;95:541–7.
- [39] Gadd S, Huff V, Huang C-C, Ruteshouser EC, Dome JS, Grundy PE, et al. Clinically relevant subsets identified by gene expression patterns support a revised ontogenic model of Wilms tumor: a Children's Oncology Group Study. *Neoplasia* 2012;14:742–56.
- [40] Gallagher EJ, LeRoith D. The proliferating role of insulin and insulin-like growth factors in cancer. *Trends Endocrinol Metab* 2010;21:610–8.
- [41] Parsons DW, Li M, Zhang X, Jones S, Leary RJ, Lin JC-H, et al. The genetic landscape of the childhood cancer medulloblastoma. *Science* 2011;331:435–9.
- [42] Rakheja D, Chen KS, Liu Y, Shukla AA, Schmid V, Chang T-C, et al. Somatic mutations in DROSHA and DICER1 impair microRNA biogenesis through distinct mechanisms in Wilms tumours. *Nat Commun* 2014;2:4802.
- [43] Charlton J, Williams RD, Sebire NJ, Popov S, Vujanic G, Chagtai T, et al. Comparative methylome analysis identifies new tumour subtypes and biomarkers for transformation of nephrogenic rests into Wilms tumour. *Genome Med* 2015;7:11.
- [44] Metsuyanin S, Pode-Shakked N, Schmidt-Ott KM, Keshet G, Rechavi G, Blumental D, et al. Accumulation of malignant renal stem cells is associated with epigenetic changes in normal renal progenitor genes. *Stem Cells* 2008;26:1808–17.
- [45] Szemes M, Dallosso AR, Melegh Z, Curry T, Li Y, Rivers C, et al. Control of epigenetic states by WT1 via regulation of de novo DNA methyltransferase 3A. *Hum Mol Genet* 2013;22:74–83.
- [46] Xu B, Zeng D, Wu Y, Zheng R, Gu L, Lin X, et al. Tumor suppressor menin represses paired box gene 2 expression via Wilms tumor suppressor protein-polycomb group complex. *J Biol Chem* 2011;286:13937–44.
- [47] Torres M, Gómez-Pardo E, Dressler GR, Gruss P. Pax-2 controls multiple steps of urogenital development. *Development* 1995;121:4057–65.
- [48] Ambros V. The functions of animal microRNAs. *Nature* 2004;431:350–5.
- [49] Astuti D, Morris MR, Cooper WN, Staals RHJ, Wake NC, Few GA, et al. Germline mutations in DIS3L2 cause the Perlman syndrome of overgrowth and Wilms tumor susceptibility. *Nat Genet* 2012;44:277–84.
- [50] Kort EJ, Farber L, Tretiakova M, Petillo D, Furge KA, Yang XJ, et al. The E2F3-Oncomir-1 axis is activated in Wilms' tumor. *Cancer Res* 2008;68:4034–8.
- [51] Watson JA, Bryan K, Williams R, Popov S, Vujanic G, Coulomb A, et al. miRNA profiles as a predictor of chemoresponsiveness in Wilms' tumor blastema. *PLoS One* 2013;8:e53417.
- [52] Murray MJ, Raby KL, Saini HK, Bailey S, Wool SV, Tunnacliffe JM, et al. Solid tumors of childhood display specific serum microRNA profiles. *Cancer Epidemiol Biomarkers Prev* 2015;24:350–60.
- [53] Ludwig N, Nourkami-Tutdibi N, Backes C, Lenhof H-P, Graf N, Keller A, et al. Circulating serum miRNAs as potential biomarkers for nephroblastoma. *Pediatr Blood Cancer* 2015;62:1360–7.
- [54] O'Meara E, Stack D, Lee CH, Garvin AJ, Morris T, Argani P, et al. Characterization of the chromosomal translocation t(10;17)(q22;p13) in clear cell sarcoma of kidney. *J Pathol* 2012;227:72–80.
- [55] Tzivion G, Luo Z, Avruch J. A dimeric 14-3-3 protein is an essential cofactor for Raf kinase activity. *Nature* 1998;394:88–92.

- [56] Asaoka Y, Kanai F, Ichimura T, Tateishi K, Tanaka Y, Ohta M, et al. Identification of a suppressive mechanism for Hedgehog signaling through a novel interaction of Gli with 14-3-3. *J Biol Chem* 2010;285:4185–94.
- [57] Zuo S, Xue Y, Tang S, Yao J, Du R, Yang P, et al. 14-3-3 epsilon dynamically interacts with key components of mitogen-activated protein kinase signal module for selective modulation of the TNF-alpha-induced time course-dependent NF-kappaB activity. *J Proteome Res* 2010;9:3465–78.
- [58] Gooskens SL, Kenny C, Lazaro A, O'Meara E, van Tinteren H, Spreafico F, et al. The clinical phenotype of YWHAE-NUTM2B/E positive pediatric clear cell sarcoma of the kidney. *Genes Chromosomes Cancer* 2016;55(2):143–7.
- [59] Ueno-Yokohata H, Okita H, Nakasato K, Akimoto S, Hata J, Koshinaga T, et al. Consistent in-frame internal tandem duplications of BCOR characterize clear cell sarcoma of the kidney. *Nat Genet* 2015;47:861–3.
- [60] Karlsson J, Valind A, Gisselsson D. BCOR internal tandem duplication and YWHAE-NUTM2B/E fusion are mutually exclusive events in clear cell sarcoma of the kidney. *Genes Chromosomes Cancer* 2016;55:120–3.
- [61] Kenny C, Bausenwein S, Lazaro A, Furtwängler R, Gooskens SL, van den Heuvel Eibrink M, et al. Mutually exclusive BCOR internal tandem duplications and YWHAE-NUTM2B fusions in clear cell sarcoma of kidney: not the full story. *J Pathol* 2016;238:617–20.
- [62] Cutcliffe C, Kersey D, Huang CC, Zeng Y, Walterhouse D, Perlman EJ. Clear cell sarcoma of the kidney: up-regulation of neural markers with activation of the sonic hedgehog and Akt pathways. *Clin Cancer Res* 2005;11:7986–94.
- [63] Gooskens SL, Gadd S, Guidry Auvil JM, Gerhard DS, Khan J, Patidar R, et al. TCF21 hypermethylation in genetically quiescent clear cell sarcoma of the kidney. *Oncotarget* 2015;6:15828–41.
- [64] Versteeg I, Sevenet N, Lange J, Rousseau-Merck MF, Ambros P, Handgretinger R, et al. Truncating mutations of hSNF5/INI1 in aggressive paediatric cancer. *Nature* 1998;394:203–6.
- [65] Biegel JA, Zhou JY, Rorke LB, Stenstrom C, Wainwright LM, Fogelgren B. Germ-line and acquired mutations of INI1 in atypical teratoid and rhabdoid tumors. *Cancer Res* 1999;59:74–9.
- [66] Jackson EM, Sievert AJ, Gai X, Hakonarson H, Judkins AR, Tooke L, et al. Genomic analysis using high-density single nucleotide polymorphism-based oligonucleotide arrays and multiplex ligation-dependent probe amplification provides a comprehensive analysis of INI1/SMARCB1 in malignant rhabdoid tumors. *Clin Cancer Res* 2009;15:1923–30.
- [67] Bourdeaut F, Lequin D, Brugieres L, Reynaud S, Dufour C, Doz F, et al. Frequent hSNF5/INI1 germline mutations in patients with rhabdoid tumor. *Clin Cancer Res* 2011;17:31–8.
- [68] Eaton KW, Tooke LS, Wainwright LM, Judkins AR, Biegel JA. Spectrum of SMARCB1/INI1 mutations in familial and sporadic rhabdoid tumors. *Pediatr Blood Cancer* 2011;56:7–15.
- [69] Hasselblatt M, Gesk S, Oyen F, Rossi S, Viscardi E, Giangaspero F, et al. Nonsense mutation and inactivation of SMARCA4 (BRG1) in an atypical teratoid/rhabdoid tumor showing retained SMARCB1 (INI1) expression. *Am J Surg Pathol* 2011;35:933–5.
- [70] Teplick A, Kowalski M, Biegel JA, Nichols KE. Educational paper: screening in cancer predisposition syndromes: guidelines for the general pediatrician. *Eur J Pediatr* 2011;170:285–94.
- [71] Gadd S, Sredni ST, Huang CC, Perlman EJ. Rhabdoid tumor: gene expression clues to pathogenesis and potential therapeutic targets. *Lab Invest* 2010;90:724–38.
- [72] Argani P, Ladanyi M. Translocation carcinomas of the kidney. *Clin Lab Med* 2005;25:363–78.
- [73] Argani P, Hicks J, De Marzo AM, Albadine R, Illei PB, Ladanyi M, et al. Xp11 translocation renal cell carcinoma (RCC): extended immunohistochemical profile emphasizing novel RCC markers. *Am J Surg Pathol* 2010;34:1295–303.
- [74] Argani P, Lae M, Ballard ET, Amin M, Manivel C, Hutchinson B, et al. Translocation carcinomas of the kidney after chemotherapy in childhood. *J Clin Oncol* 2006;24:1529–34.
- [75] Linehan WM, Srinivasan R, Schmidt LS. The genetic basis of kidney cancer: a metabolic disease. *Nat Rev Urol* 2010;7:277–85.
- [76] Bjornsson J, Short MP, Kwiatkowski DJ, Henske EP. Tuberosclerosis-associated renal cell carcinoma. Clinical, pathological, and genetic features. *Am J Pathol* 1996;149:1201–8.
- [77] Nickerson ML, Warren MB, Toro JR, Matrosova V, Glenn G, Turner ML, et al. Mutations in a novel gene lead to kidney tumors, lung wall defects, and benign tumors of the hair follicle in patients with the Birt-Hogg-Dube syndrome. *Cancer Cell* 2002;2:157–64.
- [78] Schmidt L, Duh FM, Chen F, Kishida T, Glenn G, Choyke P, et al. Germline and somatic mutations in the tyrosine kinase domain of the MET proto-oncogene in papillary renal carcinomas. *Nat Genet* 1997;16:68–73.
- [79] Tomlinson IP, Alam NA, Rowan AJ, Barclay E, Jaeger EE, Kelsell D, et al. Germline mutations in FH predispose to dominantly inherited uterine fibroids, skin leiomyomata and papillary renal cell cancer. *Nat Genet* 2002;30:406–10.
- [80] Kreidberg JA, Sariola H, Loring JM, Maeda M, Pelletier J, Housman D, et al. WT-1 is required for early kidney development. *Cell* 1993;74:679–91.
- [81] Hu Q, Gao F, Tian W, Ruteshouser EC, Wang Y, Lazar A, et al. Wt1 ablation and Igf2 upregulation in mice result in Wilms tumors with elevated ERK1/2 phosphorylation. *J Clin Invest* 2011;121:174–83.
- [82] Urbach A, Yermalovich A, Zhang J, Spina CS, Zhu H, Perez-Atayde AR, et al. Lin28 sustains early renal progenitors and induces Wilms tumor. *Genes Dev* 2014;28:971–82.
- [83] Diskin SJ, Capasso M, Schnepf RW, Cole KA, Attiyeh EF, Hou C, et al. Common variation at 6q16 within HACE1 and LIN28B influences susceptibility to neuroblastoma. *Nat Genet* 2012;44:1126–30.
- [84] Gillis AJM, Stoop H, Biermann K, van Gurp RJHLM, Swartzman E, Cribbes S, et al. Expression and interdependencies of pluripotency factors LIN28, OCT3/4, NANOG and SOX2 in human testicular germ cells and tumours of the testis. *Int J Androl* 2011;34:e160–74.
- [85] Li M-H, Yamase H, Ferrer F. Characterization of a WiT49 cell line derived orthotopic model of Wilms tumor. *Pediatr Blood Cancer* 2010;54:316–8.
- [86] Li M-H, Sanchez T, Yamase H, Hla T, Oo ML, Pappalardo A, et al. S1P/S1P1 signaling stimulates cell migration and invasion in Wilms tumor. *Cancer Lett* 2009;276:171–9.
- [87] Pierce J, Murphy AJ, Panzer A, de Caestecker C, Ayers GD, Neblett D, et al. SIX2 effects on Wilms tumor biology. *Transl Oncol* 2014;7:800–11.
- [88] Houghton PJ, Kurmasheva RT, Lyalin D, Maris JM, Kolb EA, Gorlick R, et al. Initial solid tumor testing (stage 1) of AZD1480, an inhibitor of Janus kinases 1 and 2 by the pediatric preclinical testing program. *Pediatr Blood Cancer* 2014;61:1972–9.
- [89] Kurmasheva RT, Reynolds CP, Kang MH, Allievi C, Houghton PJ, Smith MA. Initial testing (stage 1) of the topoisomerase II inhibitor pixantrone, by the pediatric preclinical testing program. *Pediatr Blood Cancer* 2014;61:922–4.
- [90] Attiyeh EF, Maris JM, Lock R, Reynolds CP, Kang MH, Carol H, et al. Pharmacodynamic and genomic markers associated with response to the XPO1/CRM1 inhibitor selinexor (KPT-330): a report from the pediatric preclinical testing program. *Pediatr Blood Cancer* 2016;63(2):276–86.

- [91] Rookmaaker MB, Schutgens F, Verhaar MC, Clevers H. Development and application of human adult stem or progenitor cell organoids. *Nat Rev Nephrol* 2015;11:546–54.
- [92] Schutgens F, Verhaar MC, Rookmaaker MB. Pluripotent stem cell-derived kidney organoids: an in vivo-like in vitro technology. *Eur J Pharmacol* 2016;790:12–20.
- [93] Perner B, Englert C, Bollig F. The Wilms tumor genes *wt1a* and *wt1b* control different steps during formation of the zebrafish pronephros. *Dev Biol* 2007;309:87–96.
- [94] Weber S, Taylor JC, Winyard P, Baker KF, Sullivan-Brown J, Schild R, et al. *SIX2* and *BMP4* mutations associate with anomalous kidney development. *J Am Soc Nephrol* 2008;19:891–903.
- [95] White R, Rose K, Zon L. Zebrafish cancer: the state of the art and the path forward. *Nat Rev Cancer* 2013;13:624–36.
- [96] The International Society of Paediatric Oncology (SIOP) and Renal Tumor Study Group (RTSG) UMBRELLA. Guidelines for standardized diagnostics, integrated research and standard therapy. 2016 (Version 1.0 February 2016).
- [97] Dome JS, Perlman EJ, Graf N. Risk stratification for Wilms tumor: current approach and future directions. *Am Soc Clin Oncol Educ Book* 2014;215–23.
- [98] Mitchell C, Pritchard-Jones K, Shannon R, Hutton C, Stevens S, Machin D, et al. Immediate nephrectomy versus preoperative chemotherapy in the management of non-metastatic Wilms' tumour: results of a randomised trial (UKW3) by the UK Children's Cancer Study Group. *Eur J Cancer* 2006;42:2554–62.
- [99] Vanden Berg RNW, Bierman EN, Noord M Van, Rice HE, Routh JC. Nephron-sparing surgery for Wilms tumor: a systematic review. *Urol Oncol* 2016;34:24–32.
- [100] Harm van Tinteren Interim Statistical Report. SIOP-RTSG Annual Meeting Stockholm. 2015.
- [101] Ha TC, Spreafico F, Graf N, Dallorso S, Dome JS, Malogolowkin M, et al. An international strategy to determine the role of high dose therapy in recurrent Wilms' tumour. *Eur J Cancer* 2013;49:194–210.
- [102] Malogolowkin M, Cotton CA, Green DM, Breslow NE, Perlman E, Miser J, et al. Treatment of Wilms tumor relapsing after initial treatment with vincristine, actinomycin D, and doxorubicin. A report from the National Wilms Tumor Study Group. *Pediatr Blood Cancer* 2008;50:236–41.
- [103] Green DM, Cotton CA, Malogolowkin M, Breslow NE, Perlman E, Miser J, et al. Treatment of Wilms tumor relapsing after initial treatment with vincristine and actinomycin D: a report from the National Wilms Tumor Study Group. *Pediatr Blood Cancer* 2007;48:493–9.
- [104] Furtwängler R, Nourkami N, Alkassar M, von Schweinitz D, Schenk J-P, Rube C, et al. Update on relapses in unilateral nephroblastoma registered in 3 consecutive SIOP/GPOH studies—a report from the GPOH-Nephroblastoma Study Group. *Klin Pädiatr* 2011;223:113–9.
- [105] Dix DB, Fernandez CV, Chi Y-Y, Anderson JR, Mullen EA, Geller JI, et al. Augmentation of therapy for favorable histology Wilms tumor combined with loss of heterozygosity of chromosomes 1p and 16q: a report from the Children's Oncology Group studies AREN0532 and AREN0533. *J Clin Oncol* 2015;33: suppl. abstr 10009.
- [106] Chagtai T, Zill C, Dainese L, Wegert J, Savola S, Popov S, et al. Gain of 1q as a prognostic biomarker in Wilms tumours treated with pre-operative chemotherapy in the SIOP WT 2001 trial: a SIOP Renal Tumours Biology Consortium Study. *J Clin Oncol* 2016;34(26):3195–203.
- [107] Gratias EJ, Jennings LJ, Anderson JR, Dome JS, Grundy P, Perlman EJ. Gain of 1q is associated with inferior event-free and overall survival in patients with favorable histology Wilms tumor: a report from the Children's Oncology Group. *Cancer* 2013;119:3887–94.
- [108] Segers H, van den Heuvel-Eibrink MM, Williams RD, van Tinteren H, Vujanic G, Pieters R, et al. Gain of 1q is a marker of poor prognosis in Wilms' tumors. *Genes Chromosom Cancer* 2013;52:1065–74.
- [109] Green DM, Grigoriev YA, Nan B, Takashima JR, Norkool PA, D'Angio GJ, et al. Congestive heart failure after treatment for Wilms' tumor: a report from the National Wilms' Tumor Study Group. *J Clin Oncol* 2001;19:1926–34.
- [110] Lee JS, Padilla B, DuBois SG, Oates A, Boscardin J, Goldsby RE. Second malignant neoplasms among children, adolescents and young adults with Wilms tumor. *Pediatr Blood Cancer* 2015;62:1259–64.
- [111] Breslow NE, Collins AJ, Ritchey ML, Grigoriev YA, Peterson SM, Green DM. End stage renal disease in patients with Wilms tumor: results from the National Wilms Tumor Study Group and the United States Renal Data System. *J Urol* 2005;174:1972–5.
- [112] Dix DB, Gratias EJ, Seibel N, Anderson JR, Mullen EA, Geller JI, et al. Omission of lung radiation in patients with stage IV favorable histology Wilms Tumor (FHWT) showing complete lung nodule response after chemotherapy: a report from Children's Oncology Group Study AREN0533. *J Clin Oncol* 2015;33: suppl. abstr 10011.
- [113] Bielen A, Box G, Perryman L, Bjerke L, Popov S, Jamin Y, et al. Dependence of Wilms tumor cells on signaling through insulin-like growth factor 1 in an orthotopic xenograft model targetable by specific receptor inhibition. *Proc Natl Acad Sci USA* 2012;109:E1267–76.
- [114] Houghton PJ, Morton CL, Gorlick R, Kolb EA, Keir ST, Reynolds CP, et al. Initial testing of a monoclonal antibody (IMC-A12) against IGF-1R by the Pediatric Preclinical Testing Program. *Pediatr Blood Cancer* 2010;54:921–6.
- [115] Weigel B, Malempati S, Reid JM, Voss SD, Cho SY, Chen HX, et al. Phase 2 trial of cixutumumab in children, adolescents, and young adults with refractory solid tumors: a report from the Children's Oncology Group. *Pediatr Blood Cancer* 2014;61: 452–6.
- [116] Maschietto M, Charlton J, Perotti D, Radice P, Geller JI, Pritchard-Jones K, et al. The IGF signalling pathway in Wilms tumours—a report from the ENCCA Renal Tumours Biology-driven drug development workshop. *Oncotarget* 2014;5:8014–26.
- [117] Perotti D, Hohenstein P, Bongarzone I, Maschietto M, Weeks M, Radice P, et al. Is Wilms tumor a candidate neoplasia for treatment with WNT/β-catenin pathway modulators? A report from the renal tumors biology-driven drug development workshop. *Mol Cancer Ther* 2013;12:2619–27.
- [118] MLN8237: ADVL0921 Spring 2014 Study Progress Report, Children's Oncology Group.
- [119] Search at clinicaltrials.gov using the terms “Wilms” OR “nephroblastoma” AND “Phase I/II”.
- [120] Mackall CL, Merchant MS, Fry TJ. Immune-based therapies for childhood cancer. *Nat Rev Clin Oncol* 2014;11:693–703.
- [121] Peters C, Brown S. Antibody-drug conjugates as novel anti-cancer chemotherapeutics. *Biosci Rep* 2015;35.
- [122] Wood AC, Maris JM, Gorlick R, Kolb EA, Keir ST, Reynolds CP, et al. Initial testing (Stage I) of the antibody-maytansinoid conjugate, IMG901 (Lorvotuzumab mertansine), by the pediatric preclinical testing program. *Pediatr Blood Cancer* 2013;60:1860–7.
- [123] Pode-Shakked N, Shukrun R, Mark-Danieli M, Tsvetkov P, Bahar S, Pri-Chen S, et al. The isolation and characterization of renal cancer initiating cells from human Wilms' tumour xenografts unveils new therapeutic targets. *EMBO Mol Med* 2013;5: 18–37.
- [124] Lorvotuzumab mertansine in treating younger patients with relapsed or refractory Wilms tumor, rhabdomyosarcoma, neuroblastoma, pleuropulmonary blastoma, malignant peripheral nerve sheath tumor, or synovial sarcoma — ClinicalTrials.gov <https://clinicaltrials.gov/ct2/show/NCT02452554> (Accessed 19 December 2015).

- [125] Merchant MS, Wright M, Baird K, Wexler LH, Rodriguez-Galindo C, Bernstein D, et al. Phase I clinical trial of ipilimumab in pediatric patients with advanced solid tumors. *Clin Cancer Res* 2016;22:1364–70.
- [126] Scursoni AM, Galluzzo L, Camarero S, Pozzo N, Gabri MR, de Acosta CM, et al. Detection and characterization of N-glycosylated gangliosides in Wilms tumor by immunohistochemistry. *Pediatr Dev Pathol* 2010;13:18–23.
- [127] Cacciavillano W, Sampor C, Venier C, Gabri MR, de Dávila MTG, Galluzzo ML, et al. A phase I study of the anti-idiotypic vaccine racotumomab in neuroblastoma and other pediatric refractory malignancies. *Pediatr Blood Cancer* 2015;62:2120–4.
- [128] Fujiwara H, Ochi T, Ochi F, Miyazaki Y, Asai H, Narita M, et al. Antileukemia multifunctionality of CD4(+) T cells genetically engineered by HLA class I-restricted and WT1-specific T-cell receptor gene transfer. *Leukemia* 2015;29:2393–401.
- [129] Shimodaira S, Sano K, Hirabayashi K, Koya T, Higuchi Y, Mizuno Y, et al. Dendritic cell-based adjuvant vaccination targeting Wilms' tumor 1 in patients with advanced colorectal cancer. *Vaccines* 2015;3:1004–18.
- [130] Furtwangler R, Gooskens SL, van Tinteren H, de Kraker J, Schleiermacher G, Bergeron C, et al. Clear cell sarcomas of the kidney registered on International Society of Pediatric Oncology (SIOP) 93-01 and SIOP 2001 protocols: a report of the SIOP Renal Tumour Study Group. *Eur J Cancer* 2013;49:3497–506.
- [131] Kalapurakal JA, Perlman EJ, Seibel NL, Ritchey M, Dome JS, Grundy PE. Outcomes of patients with revised stage I clear cell sarcoma of kidney treated in National Wilms Tumor Studies 1-5. *Int J Radiat Oncol Biol Phys* 2013;85:428–31.
- [132] Argani P, Perlman EJ, Breslow NE, Browning NG, Green DM, D'Angio GJ, et al. Clear cell sarcoma of the kidney: a review of 351 cases from the National Wilms Tumor Study Group Pathology Center. *Am J Surg Pathol* 2000;24:4–18.
- [133] Mitchell C, Jones PM, Kelsey A, Vujanic GM, Marsden B, Shannon R, et al. The treatment of Wilms' tumour: results of the United Kingdom Children's cancer study group (UKCCSG) second Wilms' tumour study. *Br J Cancer* 2000;83:602–8.
- [134] van den Heuvel-Eibrink MM, van Tinteren H, Rehorst H, Coulombe A, Patte C, de Camargo B, et al. Malignant rhabdoid tumours of the kidney (MRTKs), registered on recent SIOP protocols from 1993 to 2005: a report of the SIOP renal tumour study group. *Pediatr Blood Cancer* 2011;56:733–7.
- [135] Tomlinson GE, Breslow NE, Dome J, Guthrie KA, Norkool P, Li S, et al. Rhabdoid tumor of the kidney in the National Wilms' Tumor Study: age at diagnosis as a prognostic factor. *J Clin Oncol* 2005;23:7641–5.
- [136] Waldron PE, Rodgers BM, Kelly MD, Womer RB. Successful treatment of a patient with stage IV rhabdoid tumor of the kidney: case report and review. *J Pediatr Hematol Oncol* 1999;21:53–7.
- [137] Wagner L, Hill DA, Fuller C, Pedrosa M, Bhakta M, Perry A, et al. Treatment of metastatic rhabdoid tumor of the kidney. *J Pediatr Hematol Oncol* 2002;24:385–8.
- [138] Yamamoto M, Suzuki N, Hatakeyama N, Mizue N, Hori T, Kuroiwa Y, et al. Treatment of stage IV malignant rhabdoid tumor of the kidney (MRTK) with ICE and VDCy: a case report. *J Pediatr Hematol Oncol* 2006;28:286–9.
- [139] Madigan CE, Armenian SH, Malogolowkin MH, Mascarenhas L. Extracranial malignant rhabdoid tumors in childhood: the Childrens Hospital Los Angeles experience. *Cancer* 2007;110:2061–6.
- [140] Betz BL, Strobeck MW, Reisman DN, Knudsen ES, Weissman BE. Re-expression of hSNF5/INI1/BAF47 in pediatric tumor cells leads to G1 arrest associated with induction of p16ink4a and activation of RB. *Oncogene* 2002;21:5193–203.
- [141] Versteeg I, Medjkane S, Rouillard D, Delattre O. A key role of the hSNF5/INI1 tumour suppressor in the control of the G1-S transition of the cell cycle. *Oncogene* 2002;21:6403–12.
- [142] Isakoff MS, Sansam CG, Tamayo P, Subramanian A, Evans JA, Fillmore CM, et al. Inactivation of the Snf5 tumor suppressor stimulates cell cycle progression and cooperates with p53 loss in oncogenic transformation. *Proc Natl Acad Sci USA* 2005;102:17745–50.
- [143] Katsumi Y, Iehara T, Miyachi M, Yagyu S, Tsubai-Shimizu S, Kikuchi K, et al. Sensitivity of malignant rhabdoid tumor cell lines to PD 0332991 is inversely correlated with p16 expression. *Biochem Biophys Res Commun* 2011;413:62–8.
- [144] Jagani Z, Mora-Blanco EL, Sansam CG, McKenna ES, Wilson B, Chen D, et al. Loss of the tumor suppressor Snf5 leads to aberrant activation of the Hedgehog-Gli pathway. *Nat Med* 2010;16:1429–33.
- [145] Lee S, Cimica V, Ramachandra N, Zagzag D, Kalpana GV. Aurora A is a repressed effector target of the chromatin remodeling protein INI1/hSNF5 required for rhabdoid tumor cell survival. *Cancer Res* 2011;71:3225–35.
- [146] Knutson SK, Warholc NM, Wigle TJ, Klaus CR, Allain CJ, Raimondi A, et al. Durable tumor regression in genetically altered malignant rhabdoid tumors by inhibition of methyltransferase EZH2. *Proc Natl Acad Sci USA* 2013;110:7922–7.
- [147] Malouf GG, Camparo P, Molinie V, Dedet G, Oudard S, Schleiermacher G, et al. Transcription factor E3 and transcription factor EB renal cell carcinomas: clinical features, biological behavior and prognostic factors. *J Urol* 2011;185:24–9.
- [148] Geller JI, Argani P, Adeniran A, Hampton E, De Marzo A, Hicks J, et al. Translocation renal cell carcinoma: lack of negative impact due to lymph node spread. *Cancer* 2008;112:1607–16.
- [149] Geller R, Hemal S, Manny T. Lymphadenectomy for renal cell carcinoma and urothelial carcinoma of the upper urinary tract: analysis of evidence in the minimally invasive era. *Minerva Med* 2013;104:261–72.
- [150] Selle B, Furtwangler R, Graf N, Kaatsch P, Bruder E, Leuschner I. Population-based study of renal cell carcinoma in children in Germany, 1980-2005: more frequently localized tumors and underlying disorders compared with adult counterparts. *Cancer* 2006;107:2906–14.
- [151] Varan A, Akyuz C, Sari N, Buyukpamukcu N, Caglar M, Buyukpamukcu M. Renal cell carcinoma in children: experience of a single center. *Nephron Clin Pract* 2007;105:c58–61.
- [152] Ljungberg B, Bensalah K, Canfield S, Dabestani S, Hofmann F, Hora M, et al. EAU guidelines on renal cell carcinoma: 2014 update. *Eur Urol* 2015;67:913–24.
- [153] Upton MP, Parker RA, Youmans A, McDermott DF, Atkins MB. Histologic predictors of renal cell carcinoma response to interleukin-2-based therapy. *J Immunother* 2005;28:488–95.
- [154] Choueiri TK, Lim ZD, Hirsch MS, Tamboli P, Jonasch E, McDermott DF, et al. Vascular endothelial growth factor-targeted therapy for the treatment of adult metastatic Xp11.2 translocation renal cell carcinoma. *Cancer* 2010;116:5219–25.
- [155] Malouf GG, Camparo P, Oudard S, Schleiermacher G, Theodore C, Rustine A, et al. Targeted agents in metastatic Xp11 translocation/TFE3 gene fusion renal cell carcinoma (RCC): a report from the Juvenile RCC Network. *Ann Oncol* 2010;21:1834–8.
- [156] Tsuda M, Davis IJ, Argani P, Shukla N, McGill GG, Nagai M, et al. TFE3 fusions activate MET signaling by transcriptional up-regulation, defining another class of tumors as candidates for therapeutic MET inhibition. *Cancer Res* 2007;67:919–29.
- [157] Mitry E, Cicolallo L, Coleman MP, Gatta G, Pritchard-Jones K. Incidence of and survival from Wilms' tumour in adults in Europe: data from the EURO CARE study. *Eur J Cancer* 2006;42:2363–8.

- [158] Kalapurakal JA, Nan B, Norkool P, Coppes M, Perlman E, Beckwith B, et al. Treatment outcomes in adults with favorable histologic type Wilms tumor—an update from the National Wilms Tumor Study Group. *Int J Radiat Oncol Biol Phys* 2004; 60:1379–84.
- [159] Reinhard H, Aliani S, Ruebe C, Stöckle M, Leuschner I, Graf N. Wilms' tumor in adults: results of the Society of Pediatric Oncology (SIOP) 93-01/Society for Pediatric Oncology and Hematology (GPOH) study. *J Clin Oncol* 2004;22:4500–6.
- [160] Segers H, van den Heuvel-Eibrink MM, Pritchard-Jones K, Coppes MJ, Aitchison M, Bergeron C, et al. Management of adults with Wilms' tumor: recommendations based on international consensus. *Expert Rev Anticancer Ther* 2011;11:1105–13.
- [161] European Expert Paediatric Oncology Reference Network for Diagnostics and Treatment Available at: (ExPO-r-Net) <http://www.expornet.eu/>.
- [162] Smets AM, van Tinteren H, Bergeron C, De Camargo B, Graf N, Pritchard-Jones K, et al. The contribution of chest CT-scan at diagnosis in children with unilateral Wilms' tumour. Results of the SIOP 2001 study. *Eur J Cancer* 2012;48:1060–5.
- [163] Armstrong GT, Chen Y, Yasui Y, Leisenring W, Gibson TM, Mertens AC, et al. Reduction in late mortality among 5-year survivors of childhood Cancer. *N Engl J Med* 2016;374(9): 833–42.
- [164] Charlton J, Pavasovic V, Pritchard-Jones K. Biomarkers to detect Wilms tumors in pediatric patients: where are we now? *Future Oncol* 2015;11:2221–34.
- [165] Charles A. Stiller, Andrew F. Olshan, *Epidemiology of Renal Tumours of Childhood; Renal Tumors of Childhood – Biology and Therapy*; Kathy Pritchard-Jones and Jeff Dome; Springer <http://www.springer.com/us/book/9783662440025> [Accessed 14 March 2016].
- [166] Dome JS, Cotton CA, Perlman EJ, Breslow NE, Kalapurakal JA, Ritchey ML, et al. Treatment of anaplastic histology Wilms' tumor: results from the Fifth National Wilms' Tumor Study. *J Clin Oncol* 2006;24:2352–8.