

# Acta Orthopaedica

ISSN: 1745-3674 (Print) 1745-3682 (Online) Journal homepage: <http://www.tandfonline.com/loi/iort20>

## Preaxial polydactyly of the foot

Elise B Burger, Martijn Baas, Steven E R Hovius, A Jeannette M Hoogeboom & Christianne A van Nieuwenhoven

To cite this article: Elise B Burger, Martijn Baas, Steven E R Hovius, A Jeannette M Hoogeboom & Christianne A van Nieuwenhoven (2017): Preaxial polydactyly of the foot, Acta Orthopaedica, DOI: [10.1080/17453674.2017.1383097](https://doi.org/10.1080/17453674.2017.1383097)

To link to this article: <http://dx.doi.org/10.1080/17453674.2017.1383097>



© 2017 The Author(s). Published by Taylor & Francis on behalf of the Nordic Orthopedic Federation.



[View supplementary material](#)



Published online: 26 Sep 2017.



[Submit your article to this journal](#)



Article views: 64



[View related articles](#)



[View Crossmark data](#)

Full Terms & Conditions of access and use can be found at  
<http://www.tandfonline.com/action/journalInformation?journalCode=iort20>

# Preaxial polydactyly of the foot

## Clinical and genetic implications for the orthopedic practice based on a literature review and 76 patients

Elise B BURGER<sup>1</sup>, Martijn BAAS<sup>1</sup>, Steven E R HOVIUS<sup>1</sup>, A Jeannette M HOOGEBOOM<sup>2</sup>, and Christianne A VAN NIEUWENHOVEN<sup>1</sup>

<sup>1</sup> Departments of Plastic and Reconstructive Surgery and Hand Surgery and <sup>2</sup> Clinical Genetics, Erasmus MC, University Medical Center, Rotterdam, the Netherlands

Correspondence: e.burger@erasmusmc.nl

Submitted 2017-05-23. Accepted 2017-08-21.

**Background and purpose** — Preaxial polydactyly of the foot is a rare malformation and clinicians are often unfamiliar with the associated malformations and syndromes. In order to give guidelines for diagnostics and referral to a clinical geneticist, we provide an overview of the presentation using a literature review and our own patient population.

**Patients and methods** — The literature review was based on the Human Phenotype Ontology (HPO) project. From the HPO dataset, all phenotypes describing preaxial polydactyly were obtained and related diseases were identified and selected. An overview was generated in a heatmap, in which the phenotypic contribution of 12 anatomical groups to each disease is displayed. Clinical cases were obtained from our hospital database and were reviewed in terms of phenotype, genotype, heredity, and diagnosed syndromes.

**Results** — From the HPO dataset, 21 diseases were related to preaxial polydactyly of the foot. The anatomical groups with the highest phenotypic contribution were lower limb, upper limb, and craniofacial. From our clinical database, we included 76 patients with 9 different diseases, of which 27 had a *GLI3* mutation. Lower limb malformations (n = 55), upper limb malformations (n = 59), and craniofacial malformations (n = 32) were most frequently observed. Malformations in other anatomical groups were observed in 27 patients.

**Interpretation** — Preaxial polydactyly of the foot often presents with other upper and lower limb malformations. In patients with isolated preaxial polydactyly of the foot, referral to a clinical geneticist is not mandatory. In patients with additional malformations, consultation with a clinical geneticist is recommended. When additional limb malformations are present, analysis of *GLI3* is most feasible.

Polydactyly of the foot is a congenital malformation which can be classified as preaxial: extra hallux; postaxial (most common): extra fifth toe; and central (rarest): middle 3 toes involved. Despite the high prevalence of hand and foot polydactyly in newborns, preaxial polydactyly of the foot is rare. A recent report on congenital limb defects in the northern part of the Netherlands estimated a birth prevalence of 0.4 patients per 10,000 births in preaxial polydactyly of the foot compared with 2.1 patients per 10,000 births in preaxial polydactyly of the hand (Vasluian et al. 2013).

Although rare, knowledge about the presentation of preaxial polydactyly of the foot is important, because in almost half of the cases multiple congenital anomalies, such as syndactyly and atrial septum defects, have been reported (Vasluian et al. 2013). Furthermore, preaxial polydactyly of the foot may be associated with syndromes, including more severe malformations, such as craniosynostosis or corpus callosum agenesis (Anderson et al. 1996, Speksnijder et al. 2013). Due to the low prevalence, most clinicians are unfamiliar with these additional malformations and associated syndromes, which may therefore not be recognized.

The surgical literature mainly addresses the surgical treatment of preaxial polydactyly (Venn-Watson 1976, Masada et al. 1987, Belthur et al. 2011), whereas geneticists mainly focus on the genetic background of polydactyly, such as studies on *GLI3* and *HOXD13* (Biesecker 2011, Malik 2014). The lack of a clear overview of phenotypes that present with preaxial polydactyly of the foot makes it difficult for the surgeon to identify associated malformations and to recognize related syndromes. Associated malformations may be minimal or their detection requires additional diagnostic methods, such as an echocardiogram for cardiovascular anomalies. Therefore, a clear overview of the phenotypic and genotypic characteristics would be helpful.

To clarify the phenotypic and genotypic characteristics of syndromes and diseases that can present with preaxial polydactyly of the foot, we combined a review of genetic databases with clinical evaluation of a large surgical population with preaxial polydactyly of the foot. The combination of information from genetic databases and a case series will lead to a more complete overview of the malformation, together with a practical guideline for referral to the clinical geneticist.

## Methods

### Review of the human phenotype ontology (HPO) database

We extracted all diseases which can present with preaxial polydactyly of the foot from the HPO dataset (Kohler et al. 2017). Data extraction was performed according to the CulaPhen protocol (Baas et al. 2017), which was modified to select only phenotypes related to preaxial polydactyly of the foot. The protocol uses the HPO annotation files accessible at the HPO's Jenkins page. Accession date, search terms used for this extraction and the URL are available in Appendix 1 (see Supplementary data). A wide spectrum of HPO terms were used (from "broad hallux" to "mirror image polydactyly") to ensure inclusion of all possible diseases. Both subclasses and parental classes were included to assure that all related diseases were included. All diseases that were obtained through this search were manually reviewed by MB and EB to confirm the presence of preaxial polydactyly in the phenotypic descriptions of that disease in literature. For each of the diseases that passed manual review, a list of standardized phenotypes according to HPO nomenclature was available. These HPO phenotypes were categorized based on the Rotterdam registration form for congenital upper anomalies and the CulaPhen protocol (12 groups: CULA, Circulatory, Respiratory, Digestive, Urogenital, Nervous System, Vertebral Column, Musculoskeletal, Head/Neck, Lower Limb, Skin, Others) (Luijsterburg et al. 2003, Baas et al. 2017). For each disease, the number of phenotypes among the 12 different anatomical groups was counted and was expressed in a ratio reflecting the contribution of that anatomical group to the total disease presentation. The obtained ratios can be converted to a heatmap in which the contribution of that anatomical group to the total disease presentation is expressed by a color gradient (0 = white, 1 = red). If multiple subtypes of a disease were present, the individual diseases were grouped. In addition, when possible the diseases in the heatmap were grouped according to the classification of genetic skeletal disorders.

### Review of clinical patients

Our hospital database was retrospectively searched for patients with preaxial polydactyly of the foot diagnosed between 1993 and 2016. All subjects were reviewed in terms of phenotype, sex, heredity, and present gene mutations and syndromes. Assessment of phenotypes in these patients was

done based on review of documentation on clinical examination performed by the clinical geneticist and other specialized clinicians. Also, documentation of medical imaging and blood tests were used to identify internal congenital malformations. Because children repeatedly visit the hospital for follow-up of their foot problems until the age of 18, additional verification of malformations presenting at a later age was also performed using medical documentation. Congenital malformations were classified in 12 different anatomical groups, similar to the groups used in the classification of phenotypes in the genetic databases.

At first consultation at our department, a clinical geneticist decided if genetic testing was indicated. Genetic testing usually consisted of array analysis and targeted sequencing of candidate genes (such as *GLI3*, *FGFR2*, etc.). Alternatively, if a first-degree relative with the same congenital condition was already diagnosed with a genetic disease, this diagnosis was considered valid for the included patient as well. Patients without gene mutations documented in the patient documentation were classified as test not indicated, results not present in patient documentation, or no mutation found in genetic testing.

### Ethics, funding, and potential conflicts of interest

The institutional medical ethics committee (MEC) reviewed the protocol and agreed that MEC approval was not needed for this study (MEC-2015-679), November 10, 2015. The project was funded by the Esser Foundation. No competing interests were declared.

## Results

### Review of the HPO database

We selected 13 HPO phenotypes that could match preaxial polydactyly of the foot from the HPO database (Appendix 1, see Supplementary data). Using these phenotypes, we extracted 123 different diseases. By manual literature review, we excluded 83 diseases. The remaining 40 diseases included 9 diseases with multiple subtypes. Combining the different subtypes in 1 disease group led to a total of 21 unique diseases. The related genes to these diseases are presented in Appendix 2 (see Supplementary data). Most of these diseases (18/21) can be grouped in 3 main categories: polydactyly/syndactyly/triphalangeal syndromes, syndromes with craniofacial malformations (including craniosynostosis), and syndromes with mental retardation as a key aspect (Bonafe et al. 2015). Of the 3 remaining diseases, 2 are ciliopathies and 1 is a dysplasia syndrome (Bonafe et al. 2015). The anatomical groups that contributed most to the 21 diseases were lower limb, upper limb, craniofacial, and nervous system. Disease-specific contributions of the anatomical groups are presented in Figure 1. The phenotypic presentation of preaxial polydactyly of the foot and examples of the related phenotypes are presented in Figure 2.

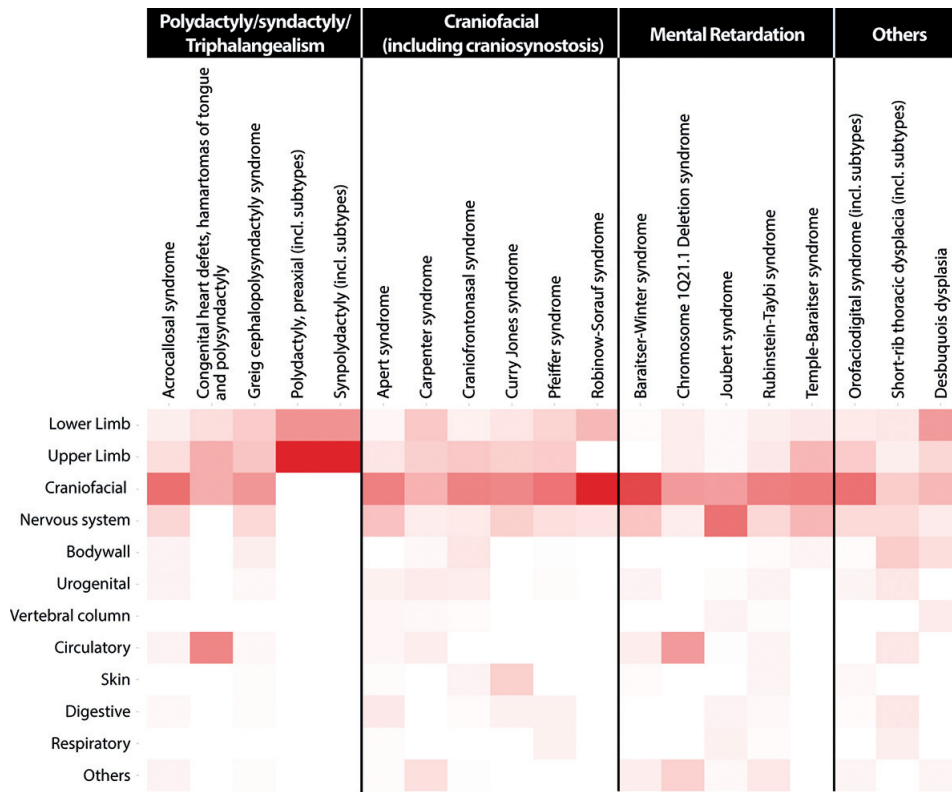


Figure 1. Heatmap showing the contribution of each anatomical group per disease related to preaxial polydactyly of the foot. The contribution of each anatomical group per disease is expressed by a red color gradient. No contribution = white; maximal contribution = red. The group of preaxial polydactyly consists of preaxial polydactyly type 1, preaxial polydactyly type 2, and preaxial polydactyly type 4. These subtypes are considered as independent disease entities, but are combined in one column because contribution of each anatomical group is similar in every type.

Table 1. Patient characteristics of the observed population with preaxial polydactyly of the foot.

Characteristics	n = 76
Sex	
Male	30
Female	46
Affected foot	
Right	15
Left	6
Bilateral	55
Hereditary	
Yes	41
No	32
Unknown	3

**Database Rotterdam**

Preaxial foot polydactyly was present in 76 patients (Table 1). 55 patients were bilaterally affected. Most cases (n = 41) were hereditary. In 3 patients familial occurrence could not be confirmed due to adoption (n = 2) or donor conception (n = 1).

9 out of 21 disease entities and syndromes reported in the HPO dataset were present in our population (Table 2). Besides syndrome diagnosis, 3 different subtypes of preaxial polydactyly (PPD) were used in clinic: type 1, 2, and 4 (Temtamy and McKusick 1978).

9 cases showed PPD type 1, characterized by only preaxial polydactyly of the feet and/or the hands. 3 cases showed PPD type 2, characterized by preaxial polydactyly of the feet and triphalangeal thumbs or halluces. 8 cases showed PPD type 4, characterized by “crossed polydactyly” (preaxial polydactyly of the feet with postaxial polydactyly of the hands). Preaxial polydactyly of the foot was often accompanied by hand, foot, and craniofacial malformations. 27 patients were affected with malformations in other anatomic groups (Table 2).

22 patients never received a genetic test or test results were not documented. In 5 of the 6 patients with unilateral PPD

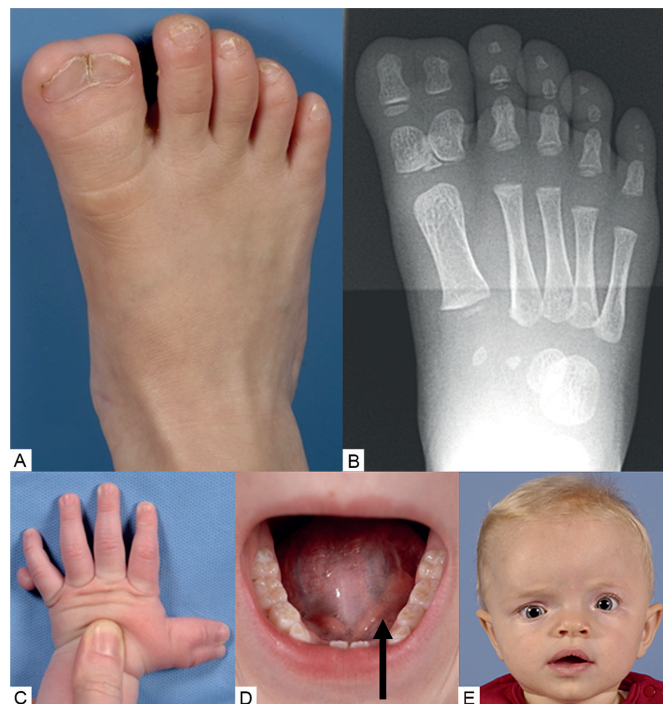

Figure 2. Example of preaxial polydactyly of the foot and some related phenotypes.

- A and B. Preaxial polydactyly of the foot.
- C. Typical hand malformation in Greig syndrome: Preaxial and postaxial polydactyly of the hand.
- D. Typical malformation in orofacial-digital syndrome: Tongue malformation indicated by the arrow.
- E. Typical craniofacial malformations in craniofrontonasal dysplasia syndrome: craniosynostosis, hypertelorism, and facial asymmetry.



Table 2. Phenotypes of the specific syndromes and diseases in the observed population

	A	B	C	D	E	F	G	H	I	J	K	L	Total n
Total n	1	26	9	3	8	7	2	2	1	2	2	13	76
Lower limb <sup>a</sup>	1	25	1	2	7	7	2	1	1	0	1	7	55
Upper limb	1	24	1	3	8	7	2	0	1	2	1	9	59
Craniofacial	1	11	0	0	0	7	2	2	1	2	2	4	32
Neurological	1	1	0	0	0	0	0	0	0	0	0	1	3
Body wall	1	0	0	0	0	0	0	1	0	1	1	3	7
Urogenital	0	0	0	0	0	0	2	0	1	0	0	1	4
Vertebral	0	0	0	0	0	0	0	0	0	0	0	0	0
Circulatory	0	1	0	0	0	2	2	0	1	0	1	4	11
Dermatological	0	1	0	0	0	0	0	0	0	1	0	3	5
Digestive	0	0	0	0	0	0	1	0	0	1	0	0	2
Respiratory	0	1	0	0	0	0	1	0	1	0	0	0	3
Other	0	1	0	0	0	5	0	1	1	1	0	2	11

<sup>a</sup> Other lower limb malformations than preaxial polydactyly of the foot.  
A. Acrocallosal syndrome, B. *GLI3*-mediated polydactyly, C. Preaxial polydactyly type I, D. Preaxial polydactyly type II, E. Preaxial polydactyly type IV, F. Apert syndrome, G. Carpenter syndrome, H. Craniofrontonasal dysplasia, I. Pfeiffer syndrome, J. Saethre-Chotzen syndrome, K. Orofacialdigital syndrome, L. Multiple malformations, no disease diagnosis

Table 3. Genetic testing and observed gene mutations

Genes	Total (n = 76)	Exclusively upper/lower limb malformations (n = 35)	Other anomalies besides upper/lower limb malformations (n = 41)
<i>EFBN1</i>	2	0	2
<i>FGFR2</i>	8	0	8
<i>GLI3</i>	27	14	13
<i>LMBR1</i>	1	1	0
<i>RAB23</i>	2	0	2
<i>TBX5</i>	1	1	0
<i>TWIST1</i>	2	0	2
Genetic test not performed	15	10	5
No mutation found	11	6	5
No test result documented	7	3	4

type 1, genetic testing was never performed. In contrast, all patients with a triphalangeal thumb and preaxial polydactyly (PPD type 2) were tested for genetic mutations.

In the cohort that was tested for genetic mutations, genetic testing was performed in 39 patients and in 15 affected parents of the patients. In 43 cases this resulted in confirmation of a mutation (Table 3). A *GLI3* mutation was confirmed in the largest part of the population (n = 27). In patients with only hand and foot malformations, 14 out of 16 confirmed mutations were in *GLI3*. In patients with anomalies in the different anatomical groups, 13 out of 27 confirmed mutations were in *GLI3*.

## Discussion

Evaluation of the genetic databases showed that 21 disease entities are associated with preaxial polydactyly of the foot. However, the spectrum of observed malformations and disease entities in our own population only included 9 disease entities. Our series mainly consisted of *GLI3*-mediated polydactyly, PPD type 1, and PPD type 4. This observation shows that patients with preaxial polydactyly of the foot commonly present without malformations in other anatomic groups. Therefore, the combination of genetic databases and patient populations in rare malformations or diseases is needed to create a thorough but also realistic picture for clinical practice.

When focusing on the phenotypic presentation of preaxial polydactyly of the foot, 3 main groups in our patient population can be distinguished. The first group includes patients with an isolated preaxial polydactyly without any other anomalies. The second group includes patients with combined hand and foot malformations, but without severe anomalies in other parts of the body. The third group includes patients with preaxial polydactyly of the foot and several anomalies in other parts of the body.

The first group, patients with an isolated preaxial polydactyly of the foot, are not commonly tested for genetic mutations in our clinic: most patients with a unilateral preaxial polydactyly in our population were never tested for genetic mutations. The reason for limited testing in isolated preaxial polydactyly is the low detection rate of mutations in patients with isolated limb anomalies (Furniss et al. 2009). Furthermore, Orioli and Castilla (1999) showed that most cases of isolated preaxial polydactyly of the foot occur sporadically. However, in a molecular review by Johnston et al. (2005) 2 patients from a *GLI3* family presented with bilateral isolated preaxial poly-

dactyly of the foot. Conclusively, genetic testing might be justified for bilateral and/or familial cases. Nevertheless, in most cases with isolated preaxial polydactyly of the foot testing for a mutation has little consequences for clinical practice.

The second distinctive group is formed by patients with additional limb malformations. Often occurring limb malformations in patients with preaxial polydactyly of the foot are preaxial and postaxial polydactyly of hands and feet, in combination with syndactyly, also named PPD type 4. These patients with multiple limb malformations are often successfully tested for *GLI3* mutations. When specific craniofacial features, such as frontal bossing, macrocephaly, hypertelorism, and a broad nasal bridge, are also present, this phenotype can be classified as Greig syndrome (Biesecker 2008). However, craniofacial malformations in patients with Greig syndrome can be minimal and easily missed, which makes the distinction between PPD type 4 and Greig syndrome difficult (Biesecker and Johnston 2005). Therefore, in our population we have chosen to classify patients with a *GLI3* mutation as *GLI3*-mediated polydactyly in order to avoid bias due to the retrospective character of this study and underreporting of craniofacial anomalies in our patient documentation.

The third group of patients with preaxial polydactyly of the foot is clinically distinctive by several malformations in different organ systems besides preaxial polydactyly of the foot. Specific features of these patients, such as craniosynostosis or cardiac septal defect, lead to a differential diagnosis resulting in a focused search for gene mutations and eventually syndrome diagnosis. Despite the focused search for gene mutations, a mutation cannot be found in all patients. This is illustrated in our population by the 13 (of 76) patients with multiple congenital anomalies, but without a disease diagnosis. The combination of malformations found in these patients could be coincidental. However, it is also possible that these patients suffer from a disease that was not recognized in counseling, or they might have a different genetic mutation not addressed in targeted analyses. In the end, based on our population study we would advise that any patient with several malformations in different organ systems should at least be referred to a clinical geneticist for evaluation.

Although our study provides an overview of the phenotypic and genotypic spectrum of patients with preaxial polydactyly of the foot, it cannot be used for any measure of risk or prevalence in this population because there is no birth registration for limb malformations in the southern part of the Netherlands. In addition, our distribution of included phenotypes could be influenced by selection bias. However, both isolated preaxial polydactyly of the foot and more complex phenotypes are present in our patient population, which makes selection bias based on patients' phenotypes less likely. Furthermore, the retrospective character might have led to underreporting of specific features due to absence of a standardized research protocol for clinical examination prior to the introduction of the Rotterdam registration form for congenital anomalies

(Luijsterburg et al. 2003). Nevertheless, previous literature reported that one-third of patients with preaxial polydactyly of the foot do have a recognized condition, which is comparable in our patient population. Lastly, the actual prevalence of genetic aberrations might be underestimated. Genetic testing in our population consisted of targeted tests of commonly affected genes. Next generation sequencing (NGS) would allow for all related genes to be tested at once, which might improve the diagnostic yield due to the detection of variants in the less commonly affected genes.

We distinguished the different phenotypes associated with preaxial polydactyly of the foot from both literature and our clinical experience. Our research is a starting point in the search for suspected syndromes presenting with preaxial polydactyly of the foot. Furthermore, we formulated a practical guideline for referral to a clinical geneticist. In patients with isolated preaxial polydactyly of the foot, referral to a clinical geneticist is not mandatory. Detection rate of gene mutations is low in these patients and the implications for clinical practice in the case of genetic mutations are limited. When additional limb malformations are present besides preaxial polydactyly of the foot, *GLI3* mutations are likely and consultation with a clinical geneticist should be considered to discuss genetic testing. In patients with multiple malformations in different parts of the body, referral to a clinical geneticist is advised to obtain a complete phenotypic description of the malformations, followed by specified genetic testing in order to confirm or exclude syndrome diagnosis.

### Supplementary data

Appendices 1 and 2 are available in the online version of this article, <http://dx.doi.org/10.1080/17453674.2017.1383097>

We thank the patients who have contributed to this study.

EBB: search of patient database, analysis and interpretation of acquired data, drafting and revising of the manuscript; MB: design and execution of literature search, analysis and interpretation of acquired data, drafting and revising of the manuscript; SERH: conception of the research project, revisions of the manuscript; AJMH: clinical genetic interpretation, revisions of the manuscript; CAN: conception of the research project, revisions of the manuscript.

*Acta* thanks Ketil Riddervold Heimdal and Bertil Romanus for help with peer review of this study.

Anderson P J, Smith P J, Jones B M, Hayward R D. Additional metatarsal bones in Apert's syndrome. *Foot* 1996; 6 (1): 37-8.

Baas M, Stubbs A P, van Zessen D B, Galjaard R H, van der Spek P J, Hovius S E R, van Nieuwenhoven C A. Identification of associated genes and diseases in patients with congenital upper-limb anomalies: A novel application of the OMT classification. *J Hand Surg Am* 2017; 42 (7): 533-45 e4.

Belthur M V, Linton J L, Barnes D A. The spectrum of preaxial polydactyly of the foot. *J Pediatr Orthop* 2011; 31 (4): 435-47.

- Biesecker L G. The Greig cephalopolysyndactyly syndrome. *Orphanet J Rare Dis* 2008; 3: 10.
- Biesecker L G. Polydactyly: How many disorders and how many genes? 2010 update. *Dev Dyn* 2011; 240 (5): 931-42.
- Biesecker L G, Johnston J. Syndromic and non-syndromic *GLI3* phenotypes. *Clin Genet* 2005; 68 (3): 284; author reply 5.
- Bonafe L, Cormier-Daire V, Hall C, Lachman R, Mortier G, Mundlos S, Nishimura G, Sangiorgi L, Savarirayan R, Sillence D, Spranger J, Superti-Furga A, Warman M, Unger S. Nosology and classification of genetic skeletal disorders: 2015 revision. *Am J Med Genet A* 2015; 167A (12): 2869-92.
- Furniss D, Kan S H, Taylor I B, Johnson D, Critchley P S, Giele H P, Wilkie A O. Genetic screening of 202 individuals with congenital limb malformations and requiring reconstructive surgery. *J Med Genet* 2009; 46 (11): 730-5.
- Johnston J J, Olivos-Glander I, Killoran C, Elson E, Turner J T, Peters K F, Abbott M H, Aughton D J, Aylsworth A S, Bamshad M J, Booth C, Curry C J, David A, Dinulos M B, Flannery D B, Fox M A, Graham J M, Grange D K, Guttmacher A E, Hannibal M C, Henn W, Hennekam R C, Holmes L B, Hoyme H E, Leppig K A, Lin A E, Macleod P, Manchester D K, Marcellis C, Mazzanti L, McCann E, McDonald M T, Mendelsohn N J, Moeschler J B, Moghaddam B, Neri G, Newbury-Ecob R, Pagon R A, Phillips J A, Sadler L S, Stoler J M, Tilstra D, Walsh Vockley C M, Zackai E H, Zadeh T M, Brueton L, Black G C, Biesecker L G. Molecular and clinical analyses of Greig cephalopolysyndactyly and Pallister-Hall syndromes: Robust phenotype prediction from the type and position of *GLI3* mutations. *Am J Hum Genet* 2005; 76 (4): 609-22.
- Kohler S, Vasilevsky N A, Engelstad M, Foster E, McMurry J, Ayme S, Baynam G, Bello S M, Boerkoel C F, Boycott K M, Brudno M, Buske O J, Chinnery P F, Cipriani V, Connell L E, Dawkins H J, DeMare L E, Devereau A D, de Vries B B, Firth H V, Freson K, Greene D, Hamosh A, Helbig I, Hum C, Jahn J A, James R, Krause R, SJ F L, Lochmuller H, Lyon G J, Ogishima S, Olry A, Ouwehand W H, Pontikos N, Rath A, Schaefer F, Scott R H, Segal M, Sergouniotis P I, Sever R, Smith C L, Straub V, Thompson R, Turner C, Turro E, Veltman M W, Vulliamy T, Yu J, von Ziegenweid J, Zankl A, Zuchner S, Zemojtel T, Jacobsen J O, Groza T, Smedley D, Mungall C J, Haendel M, Robinson P N. The Human Phenotype Ontology in 2017. *Nucleic Acids Research* 2017; 45 (D1): D865-D76.
- Luijsterburg A J, Sonneveld G J, Vermeij-Keers C, Hovius S E. Recording congenital differences of the upper limb. *J Hand Surg Br* 2003; 28 (3): 205-14.
- Malik S. Polydactyly: Phenotypes, genetics and classification. *Clin Genet* 2014; 85 (3): 203-12.
- Masada K, Tsuyuguchi Y, Kawabata H, Ono K. Treatment of preaxial polydactyly of the foot. *Plast Reconstr Surg* 1987; 79 (2): 251-8.
- Orioli I M, Castilla E E. Thumb/hallux duplication and preaxial polydactyly type I. *Am J Med Genet* 1999; 82 (3): 219-24.
- Speksnijder L, Cohen-Overbeek T E, Knapen M F, Lunshof S M, Hoogboom A J, van den Ouweland A M, de Coo I F, Lequin M H, Bolz H J, Bergmann C, Biesecker L G, Willems P J, Wessels M W. A de novo *GLI3* mutation in a patient with acrocallosal syndrome. *Am J Med Genet A* 2013; 161A (6): 1394-400.
- Temtamy S A, McKusick V A. The genetics of hand malformations. *Birth Defects Orig Artic Ser* 1978; 14 (3): i-xviii, 1-619.
- Vasluian E, van der Sluis C K, van Essen A J, Bergman J E, Dijkstra P U, Reinders-Messelink H A, de Walle H E. Birth prevalence for congenital limb defects in the northern Netherlands: A 30-year population-based study. *BMC Musculoskelet Disord* 2013; 14: 323.
- Venn-Watson E A. Problems in polydactyly of the foot. *Orthop Clin North Am* 1976; 7 (4): 909-27.